

# Raiders of the lost... plug. Percutaneous retrieval of embolized left atrial appendage occluder in an asymptomatic patient followed by reimplantation of a different type of device

Edyta Ćwiek-Rębowska, Jan Zbigniew Peruga, Ewa Szymczyk, Łukasz Jankowski, Jarosław Kasprzak

Department of Cardiology, Medical University of Lodz, Łódź, Poland

## Correspondence to:

Edyta Ćwiek-Rębowska, MD,  
Department of Cardiology,  
Medical University of Lodz,  
Kniażewicza 1/5, 91–347 Łódź,  
Poland,  
phone: +48 42 251 62 16,  
e-mail: edyta.cwiek@wp.pl

Copyright by the Author(s), 2021

Kardiologia Polska. 2021;  
79 (11): 1284–1285;  
DOI: 10.33963/KPa2021.0098

## Received:

June 21, 2021

## Revision accepted:

August 30, 2021

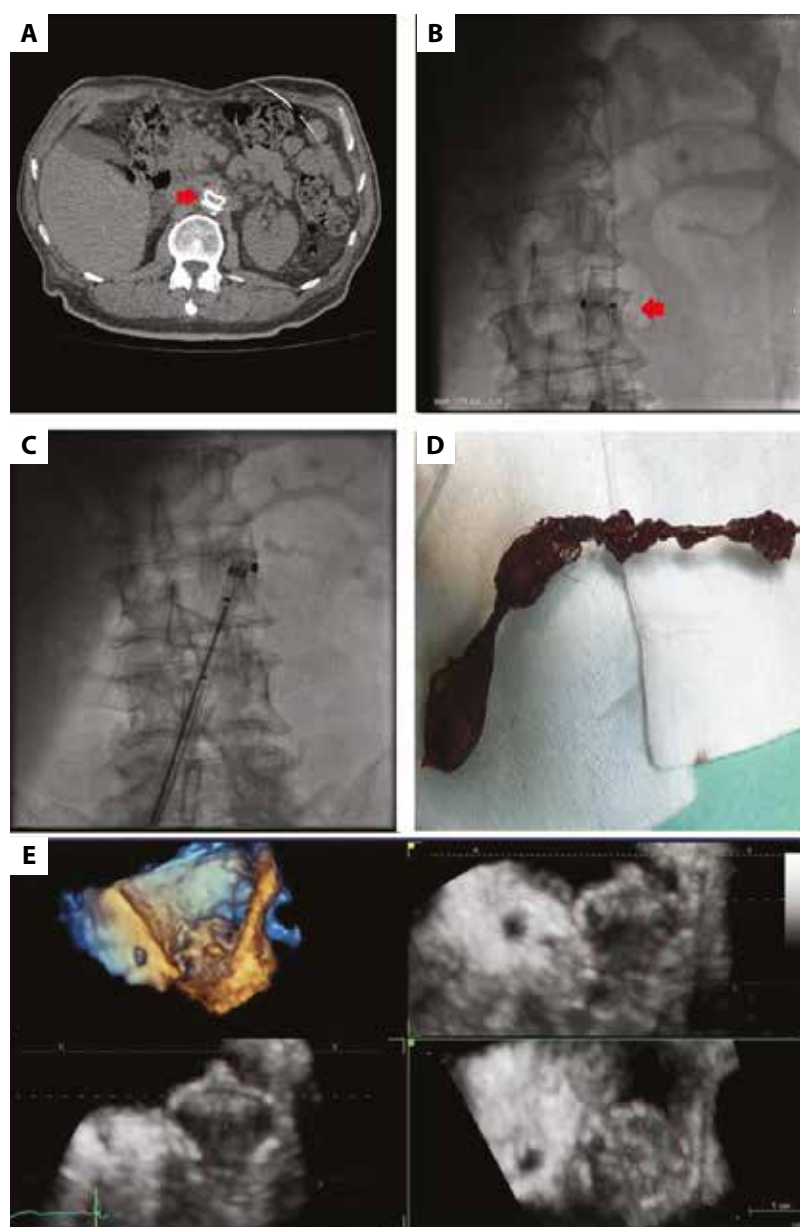
## Published online:

August 31, 2021

Percutaneous closure of the left atrial appendage (LAA) is a safe and effective alternative for stroke prevention in patients with atrial fibrillation (AF) and contraindications to long-term anticoagulation [1]. However, periprocedural and postprocedural complications (including cardiac tamponade, procedural stroke, embolization of device, or transient myocardial ischemia) may outweigh the benefits of avoiding anticoagulants [2]. Embolization of the LAA closure device has been reported with an average rate of less than 4% and occurred mainly in the early postprocedural period [2, 3]. We report the case of a 67-year-old male patient with paroxysmal AF and a history of 3 hemorrhagic strokes who was admitted for a percutaneous LAA closure procedure. Using transesophageal echocardiography (TOE) and fluoroscopy-guided angiography (diameter of the landing zone, 18 mm) the 22-mm Amplatzer Amulet was successfully implanted in the LAA. The correct position of the device was confirmed by the “tug-test”. The echocardiography examination did not reveal any features of a residual shunt or pericardial effusion. During follow-up, the patient remained asymptomatic. After 8 weeks, the scheduled echocardiography examination revealed an absence of the cardiac plug in the expected position with no signs of device entrapment in the left heart. Fluoroscopy and computed tomography angiography allowed to localize the LAA occluder in the abdominal aorta at the level of the renal arteries (Figure 1A). Since little is known about the equipment used during retrieval of dislodged LAA occluders, the eligibility for the percutaneous

procedure was the principal concern. Due to high surgical risk, percutaneous removal of migrated occluder with the surgery backup was chosen as the first-line intervention (Figure 1B, C). The dislocated device was removed using Maslanka grasping forceps and the MultiSnare via the femoral artery without its defragmentation (Figure 1D). Ten weeks after successful retrieval, uncomplicated LAA closure was repeated with a larger size Watchman 24 mm device (Figure 1E).

The previously described potential mechanisms causing LAA closure devices embolization included under-sizing, excessive oversizing, incorrect device apposition, or conversion from AF to sinus rhythm after the procedure [3]. In our patient, the reason for embolization was not clear as it occurred despite confirming the proper position of the device at the end of the implantation procedure. The diameter of the landing zone was measured during TOE and angiography, and the values taken were corresponding. In our case, the under-sizing due to the hypovolemia during measurements of the LAA with preserved contractile function was proposed as the underlying cause of device migration (although the left atrial pressure measured at the first procedure was 11 mm Hg). According to recent studies, the mean left atrial pressure >12 mm Hg favors correct estimation of a device size [5], thus, to avoid possible under-sizing due to the volume contraction at the second attempt of LAA closure, the additional infusion of 1000 ml of normal saline was ordered prior to the procedure. The presented case proves that percutaneous retrieval of migrated LAA



**Figure 1.** **A.** Computed tomography scan showing dislocation of Amplatzer Amulet (Abbott Vascular, Santa Clara, CA, USA) to the abdominal aorta (the red arrow). **B, C.** Fluoroscopic images of 16 Fr steerable sheath (Check Flo Performer Introducer [Cook Medical, Bloomington, IN, USA]) introduced into the femoral artery accompanied by the guide catheter 7F Launcher AR-1 (Medtronic Vascular, Minneapolis, MN, USA) introduced via the sheath with Maslanka grasping forceps (BVM Medical, Hinckley, United Kingdom) and MultiSnare (PFM medical, Cologne, Germany). The snare was used to change the direction of the device (red arrow), so it enabled the capture of the LAA occluder with grasping forceps. **D.** Amplatzer Amulet removed percutaneously without its defragmentation. **E.** Three-dimensional transesophageal echocardiographic image of the WATCHMAN left atrial appendage closure device after the second LAA closure procedure

Abbreviations: LAA, left atrial appendage

occluder via the femoral artery is technically feasible, safe, and leads to favorable results. Left atrial appendage closure procedure may be successfully repeated using a larger size or a different type of device.

### Article information

**Conflict of interests:** None declared.

**Open access:** This article is available in open access under Creative Commons Attribution-Non-Commercial-No Derivatives 4.0 International (CC BY-NC-ND 4.0) license, allowing to download articles and share them with others as long as they credit the authors and the publisher, but without permission to change them in any way or use them commercially. For commercial use, please contact the journal office at [kardiologiapolska@ptkardio.pl](mailto:kardiologiapolska@ptkardio.pl).

**How to cite:** Ćwiek-Rębowska E, Peruga JZ, Szymczyk E, et al. Raiders of the lost... plug. Percutaneous retrieval of embolized left atrial appendage occluder in an asymptomatic patient followed by reimplantation of a different type of device. *Kardiol Pol.* 2021; 79(11): 1284–1285, doi: 10.33963/KPa.2021.0098.

### REFERENCES

- Burysz M, Litwinowicz R, Burysz A, et al. Causes of death and morbidity in patients with atrial fibrillation after left atrial appendage occlusion. *Kardiol Pol.* 2019; 77(11): 1047–1054, doi: 10.33963/KP.14966, indexed in Pubmed: 31495824.
- Park JW, Bethencourt A, Sievert H, et al. Left atrial appendage closure with Amplatzer cardiac plug in atrial fibrillation: initial European experience. *Catheter Cardiovasc Interv.* 2011; 77(5): 700–706, doi: 10.1002/ccd.22764, indexed in Pubmed: 20824765.
- Bajaj NS, Parashar A, Agarwal S, et al. Percutaneous left atrial appendage occlusion for stroke prophylaxis in nonvalvular atrial fibrillation: a systematic review and analysis of observational studies. *JACC Cardiovasc Interv.* 2014; 7(3): 296–304, doi: 10.1016/j.jcin.2013.11.010, indexed in Pubmed: 24650403.
- Aminian A, Lalmand J, Tzikas A, et al. Embolization of left atrial appendage closure devices: a systematic review of cases reported with the watchman device and the amplatzer cardiac plug. *Catheter Cardiovasc Interv.* 2015; 86(1): 128–135, doi: 10.1002/ccd.25891, indexed in Pubmed: 25676316.
- Freixa X, Aminian A, Tzikas A, et al. Left atrial appendage occlusion with the Amplatzer Amulet: update on device sizing. *J Interv Card Electrophysiol.* 2020; 59(1): 71–78, doi: 10.1007/s10840-019-00699-5, indexed in Pubmed: 32166532.