

This is a provisional PDF only. Copyedited and fully formatted version will be made available soon.



**ISSN:** 0015-5659

**e-ISSN:** 1644-3284

## **Superficial lymphatic drainage of the vulva and its relation to the regional nodes: An experimental study**

**Authors:** D. Pavlista, O. Eliska

**DOI:** 10.5603/FM.a2021.0096

**Article type:** Original article

**Submitted:** 2021-05-29

**Accepted:** 2021-09-14

**Published online:** 2021-09-28

This article has been peer reviewed and published immediately upon acceptance. It is an open access article, which means that it can be downloaded, printed, and distributed freely, provided the work is properly cited.

Articles in "Folia Morphologica" are listed in PubMed.

# **Superficial lymphatic drainage of the vulva and its relation to the regional nodes: An experimental study**

D. Pavlista, O. Eliska, Lymphatic drainage of the vulva: A functional study

D. Pavlista<sup>1</sup>, O. Eliska<sup>2</sup>

<sup>1</sup>Gynecologic Oncology Center, Department of Obstetrics and Gynecology, First Faculty of Medicine, Charles University in Prague and General University Hospital in Prague, Czech Republic

<sup>2</sup>Institute of Anatomy, First Faculty of Medicine, Charles University in Prague, Czech Republic

Address for correspondence: MUDr. David Pavlišta, PhD, Oncogynecologic Center, Department of Obstetrics and Gynecology, First Faculty of Medicine, Charles University in Prague and General University Hospital, Apolinarska 18, 12801 Prague, Czech Republic, e-mail: [david.pavlista@vfn.cz](mailto:david.pavlista@vfn.cz); orcid: 0000-0002-0203-0890

## **Abstract**

**Background:** Sentinel node biopsy in vulvar cancer is associated with much less morbidity than inguinofemoral node dissection. Our study focused on describing the morphology of superficial lymphatic drainage of the vulva and its relationship to regional nodes, which may facilitate orientation during surgery.

**Materials and methods:** In 24 female cadavers, injections of patent blue (at various localizations medially, unilaterally and bilaterally) were used to visualize the lymphatic drainage of the vulva. After dissection of lymphatic vessels and nodes, their course was documented by photograph and then analyzed. Subsequently, a map of vulvar superficial lymphatics was created.

**Results:** The cutaneous and subcutaneous tissue of the vulva primarily drained to superficial inguinal nodes. There was no evidence of a solitary lymph node that drained the unilateral vulva. Each area of the vulva drained to its own lymph node, which was variably localized in the subcutaneous groin around the great saphenous vein. Anastomoses between individual inguinal superficial lymph nodes are likely. Right-left symmetry in the course of lymphatic

collectors was not detected. Natural drainage of the medial and paramedial areas to contralateral inguinal nodes was also not detected. The drainage pattern to ipsilateral inguinal nodes was consistent in cadavers without evidence of vulvar disease and may be applicable in the early stages of vulvar cancer.

**Conclusions:** There was no evidence of a solitary node that drained the unilateral vulva. Each part of the vulva may drain to a corresponding lymph node in a different localization of the groin. The surgeon should take this variability into account.

**Key words:** vulva, cancer, sentinel node, lymphatic mapping, anatomy

## **INTRODUCTION**

Vulvar cancer represents 3–5% of all gynecological tumors, but primarily affects women in the 7th and 8th decades of life [10]. Vulvar cancer primarily metastasizes via the lymphatics, and primary treatment in the initial stages is surgical. Due to the age of those primarily affected, patients with vulvar cancer are characterized by polymorbidity and a significantly higher risk of postoperative complications (lymphedema, wound disruption). Therefore, there is an effort to reduce the radicality of surgery and thus the occurrence of serious complications while preserving similar outcomes. Since the turn of the century, wide tumor excision and biopsy of the sentinel node has replaced radical vulvectomy in the early stages of vulvar cancer [15]. Sentinel lymph node biopsy is indicated for vulvar cancer up to 4 cm in size [14,15].

The present study primarily focused on describing the topography of the superficial lymphatic drainage of the vulva and its relationship to regional nodes, which may facilitate orientation during surgery.

### **Lymphatics of the vulva**

Anatomical descriptions of the lymphatic vessels of the external genital organs in women were predominantly made at the end of the 19th century and in the first half of the 20th century. The findings of these pioneering works showed that both the labia minora and labia majora share common lymphatic drainage [3, 4, 23, 24]. This drainage consists of a

network of lymphatic vessels in the internal and external superficial area of the labia minora and majora, which runs to the lymphatic collectors, continuing to the mons pubis and further towards the superficial inguinal nodes. Lymphatic collectors typically terminate in the superomedial node group, rarely in the inferomedial group [4] or in the lateral node group [21] of the superficial inguinal nodes.

The superficial inguinal lymph nodes are anatomically divided into four groups: superomedial, inferomedial, superolateral and inferolateral; determined by the localization of the great saphenous vein and its passage through the saphenous opening in the cribriform fascia. Some anatomists include a small group of 2–3 nodes around the saphenous opening [11]. This group has several names, most commonly referred to as the central group. Each node in these superficial groups may be a sentinel node. The superficial inguinal lymph nodes are connected to the deep inguinal lymph nodes by efferent lymphatic vessels.

### **Lymphatics of the medial part of the vulva**

Lymphatic drainage of the clitoris is described differently by individual authors. In 1909, Bartels divided the lymphatic vessels of the clitoris into superficial and deep vessels. Superficial lymphatics run to superomedial superficial inguinal nodes, deep lymphatics go through the lymphatic plexus pubicus and eventually through the small pubic nodes to the deep inguinal nodes. Poirer and Cuneo [17] described three lymphatic drainage pathways of the clitoris. From the preputium clitoris, lymph is drained by lymphatic vessels to the superficial inguinal nodes. From the body of the clitoris, lymph is drained by lymphatic vessels to the inguinal canal and to the pelvic nodes. And finally they described lymphatic vessels from the clitoris that run to the deep inguinal nodes and continue through the lacuna vasorum to the Clocquet node and the pelvic nodes. Reifenstuhl [21] provided the most detailed description of the lymphatic drainage of the clitoris. He also found three lymphatic drainage pathways, however, they differed from those described by Poirer. Part of the lymphatic vessels of the clitoris and the distal part of the urethra run to the superficial inguinal nodes. The second part of the lymphatic vessels of the clitoris run in the deep adipose tissue anterior to the mons pubis, and inferior to the inferior edge of the pubic symphysis they enter the interiliac and obturator lymph nodes. The third part of the lymphatic vessels from the deep part of the clitoris and urethra run to the anterior side of the symphysis, then cranially to the attachment site of rectus abdominis. The collector passes through the medial part of the rectus abdominis muscle and runs bilaterally along the superior edge of the pubic ramus laterally to

the node located at the beginning of the pelvis at the femoral anulus (to the medial lacunar node).

Lymphatic drainage of the middle part of the vulva and clitoris is important in the surgical treatment of vulvar cancer. According to NCCN guidelines, it is recommended that tumors occurring at a distance of 2 cm or less from the vulval midline undergo bilateral inguinal surgery.

The aim of the present study was to map the superficial lymphatic drainage of the vulva, including potential accessory lymphatic pathways and localization of the sentinel lymph node, which is not influenced by the presence of malignant tumor and which determines potential metastasis sites, in order to facilitate orientation during surgery. Special attention was paid to the lymphatic drainage of the midline and clitoris in order to show possible connections to the contralateral side.

## **MATERIALS AND METHODS**

The present study was performed on a total of 24 female cadavers with a mean age of 68 years (range 62–86 years; up to 12 hours after death from internal disease with a negative history of malignancy). After gradually warming the pubic and inguinal regions with warm water to 37 degrees Celsius, patent blue (Patent Blue V Sodium 2.5 %; Guebert, Villepinte, France) 2 ml was gradually applied subdermally:

- to 6 cadavers **paramedially at a distance of 2 cm to the right of the midline** of the body from the mons pubis to the level of the posterior commissure,
- to 6 cadavers as above but on **the left side** of the body,
- to 6 cadavers **along the circumference of the labia minora bilaterally simultaneously**, and
- to 6 cadavers **circularly periclitally** (up to a distance of 1 cm from the clitoris).

After imaging and gentle dissection of lymphatic vessels and nodes, their course was documented by photograph and then analyzed. Subsequently, a map of the superficial lymphatics of the vulva was created. The study was approved by the Ethics Committee and Institutional Review Board.

## **RESULTS**

After subcutaneous application of patent blue **along the circumference of the labia minora bilaterally, simultaneously**, a variable number (2–5) of lymphatic collectors were

visible, which were partially vertical and then arcuate in orientation in the area of the mons pubis, and then gradually deviated laterally and toward the inguinal nodes (see Figures 1–3). The dorsal parts of the vulva drained into inferomedial inguinal nodes, and the paraclitoral parts of the vulva drained into superomedial inguinal nodes. Irregular anastomoses were seen in the distal part of the collectors, and the course of the collectors did not exceed the inguinofemoral groove. Right-left symmetry of node localization and the course of lymphatic collectors was not detected.

After **unilateral application of contrast paramedially** at a distance of 2 cm from the mid-sagittal plane, in only one case, a smaller collector began to appear, which conducted contrast towards the contralateral groin. However, the contrast did not progress further than 2 cm from the midline. On the contralateral side, this collector was significantly thinner and less conspicuous compared to ipsilateral collectors. Thus, drainage into the contralateral inguinal nodes was not demonstrated. The pattern of contrast dispersion after unilateral application was identical to that after bilateral application, including imaging and localization of nodes.

In contrast, **periclitoral** application showed both bilateral collectors and inguinal superomedial nodes.

Lymphatic nodes were visualized inconsistently along the distal course of the collectors and their localization was dependent on the site of patent blue application. We did not detect a single node that drained the unilateral vulva. Each area of the vulva drained into its own node (Figures 2, 3). In 2 cases, fine collectors were also displayed that connected several superficial nodes together.

Right-left symmetry in the course and shape of the lymphatic collectors was not detected in any of the seven cadavers after bilateral application of contrast, nor did we demonstrate right-left symmetry in the localization of sentinel nodes. Assessment of other accessory pathways of lymphatic drainage by targeted dissection of the distal part of the vagina and perineum towards the anus failed due to technical difficulties (numerous varicose plexuses, inaccessible dissection area). The resulting lymphatic drainage model is shown in Figure 4.

## **DISCUSSION**

Inguinal node topography and localization of the sentinel node are essential issues in surgical treatment of vulvar cancer. The exact distribution and topography of superficial inguinal

nodes is almost impossible to determine during surgery. The only structure for anatomical orientation in the subcutaneous groin is the great saphenous vein. Other superficial veins in the groin exhibit broad anatomical variability. All of our observations showed that the dorsal parts of the vulva drain into inferomedial inguinal nodes, and the paraclitoral parts of the vulva drain into superomedial inguinal nodes. We are not aware of any up-to-date studies that have employed similar methodology in evaluating the topography and principles of vulvar drainage to the superficial inguinal lymph nodes *ex vivo*. Thus, other reports are from clinical observations of sentinel localization during surgery for early-stage vulvar cancer [9], and their disadvantage is that they do not describe the course of lymphatics between the application site and the groin. In most cases they also do not identify the site of tracer application on the vulva (presumably at the site of the tumor). Sentinel node detection in vulvar cancer surgery is performed by a variety of methods, including preoperative lymphoscintigraphy, intraoperative use of a gamma probe combined with blue dye, or blue dye alone [2, 12, 18]. Affected sentinel nodes in vulvar cancer are more frequently present ipsilateral to the tumor, but may also be found bilaterally [6, 8, 13]. The location of the sentinel node is also determined by the localization of the vulvar tumor. For a vulvar tumor positioned in the midline, the likelihood of bilateral metastasis is higher than for a tumor positioned laterally [20]. Midline or paramedial cancers of the vulva metastasize bilaterally in 30% of cases [1]. In the present study, a contralaterally-oriented collector was partially shown in one case, but after a short course the contrast did not spread further. Drainage to contralateral nodes in our work was not demonstrated, which is in line with current NCCN guidelines for the surgical treatment of vulvar cancer. This may be due to the fact that in cases of carcinoma of the vulva, due to metastatic involvement of the ipsilateral lymphatics, the lymphatic drainage is subsequently redirected to the contralateral groin.

Rough topographical localization of the sentinel node in vulvar cancer was described by Rob et al., who divided the superficial inguinal nodes into superomedial and central-intermediate groups [22]. In addition to the above-mentioned authors, Parry-Jones [16] also described the lymphatic drainage of the vulva, and performed intraoperative mapping with Evans Blue in patients prior to radical vulvectomy using an en bloc technique. They also focused on direct deep lymphatic drainage of the vulva, which they failed to elucidate, and did not describe sentinel nodes.

In the present *ex vivo* study, precise tissue dissection was used, not only with respect to the course of the collectors but also for more accurate visualization of superficial inguinal

lymphatic morphology, which surprisingly showed the course of the collectors very well. The collectors did not run from the application site directly to the lymph nodes, but rather arcuate and fan-shaped courses were seen. The results of the present study were discussed with two experienced onco-gynecological surgeons, who were surprised by such a markedly arcuate course of lymphatic collectors. In figure 4, it is shown that the vulva may drain into several sentinel nodes depending on the site of Patent Blue injection. Superficial lymph nodes are connected together by fine lymphatic collectors. It remains to be determined if larger tumors (3–4 cm) can be drained by two collectors into two differently-localized sentinel nodes.

The authors are aware of the limitations of the study, which is based on passive lymphatic mapping post mortem, and consider it experimental due to the fact that the lymphatic system may behave differently in vivo. The lymphatic system remains partially functional even after death. For example newly-described real-time *ex vivo* perfusion model for axillary lymph nodes (ALNs) in breast cancer patients, used for immuno-oncological investigations. This study has shown that perfused ALNs remain viable for up to 24 hours [19]. Passive lymphatic drainage is also functional *post mortem* provided body temperature is maintained, and a contrast agent of small particulate size (e.g., patent blue) with slow intradermal and subdermal administration is used [5, 7]. Recently, new post mortem lymphatic mapping techniques have been developed using modern contrast agents (microinjection technique with hydrogen peroxide, indocyanine green lymphography) [25].

## CONCLUSIONS

Our results suggest that the cutaneous and subcutaneous tissue of the vulva are drained primarily to superficial inguinal nodes. There was no evidence of a solitary node that drained the unilateral vulva. Each area of the vulva drained into its own single node, which was variably localized in the subcutaneous inguinal region around the great saphenous vein, primarily along its medial aspect. Anastomoses between individual superficial inguinal lymph nodes are likely. Right-left symmetry of sentinel node localization and the course of lymphatic collectors was not detected. Drainage into the contralateral inguinal nodes was also not demonstrated.

These observations do not exclude other lymphatic drainage pathways, which are likely to be secondary when lymphatic flow is restricted in the primary lymphatic pathway (tumor size and localization, greater metastatic involvement of the lymph nodes).



Our results show that lymphatic drainage from the vulva is complex and that there is no uniform pattern nor 100% certainty as to where and to how many lymph nodes the tumor will metastasize. Our observations focused on possible anatomical variations in the course of superficial lymphatic vessels of the vulva , and do not comprehensively address the conditions and causes of the diverse spread of vulvar cancer.

### **Ethical statement**

Approval was obtained from the ethics committee of the 1st Medical Faculty of Charles University and General hospital in Prague, No GACR 304/00/1157. The procedures used in this study adhere to the tenets of the Declaration of Helsinki.

### **Acknowledgements**

The authors wish to sincerely thank those who donated their bodies to science so that anatomical research could be performed. Results from such research may potentially improve patient care and increase mankind's overall knowledge. Therefore, these donors and their families deserve our highest gratitude.

This work was supported by Charles University in Prague (GACR 304/00/1157 and PROGRES Q28/LF1)

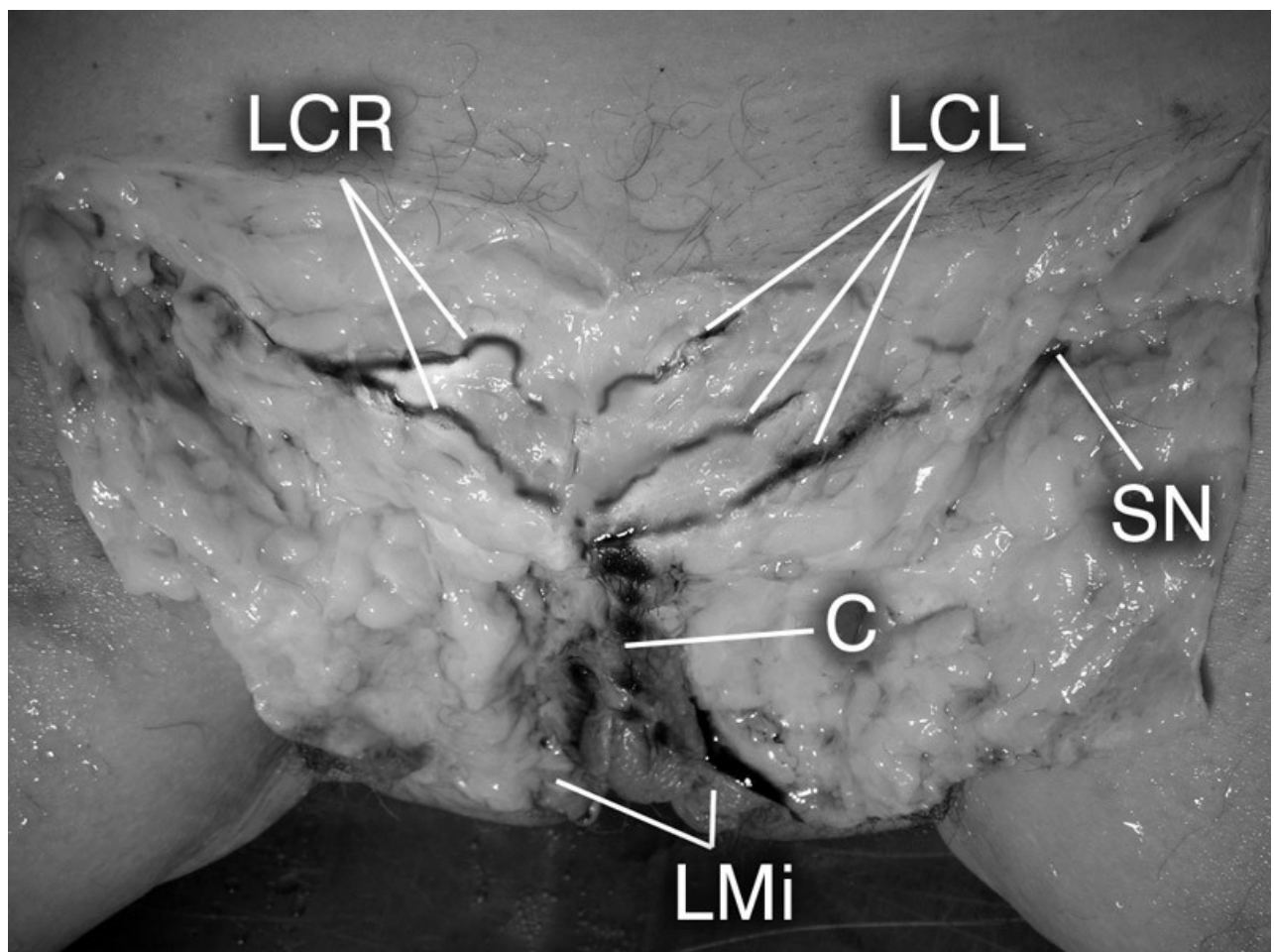
I would like to thank the academic painter Jan Kacvický for his assistance with graphic design.

### **REFERENCES**

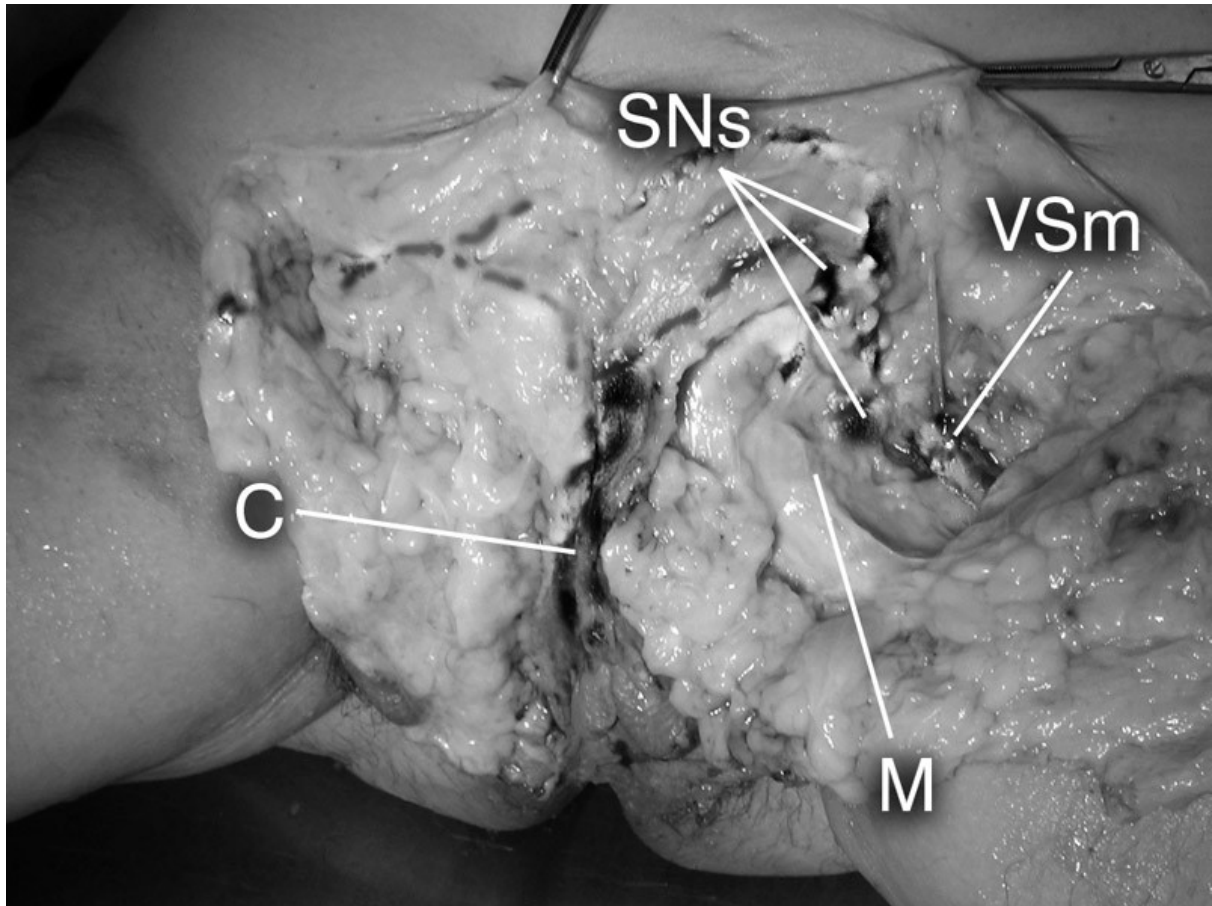
1. Adib T, Barton DPJ (2006) The sentinel lymph node :relevance in gynaecological cancers. *EJSO*, 32: 866-874.
2. Ansink AC, Sie-Go MD, van der Velden J (1999) Identification of sentinel lymph nodes in vulvar carcinoma patients with the aid of a Patent Blue V injection. *Cancer*, 86: 652-666.
3. Bartels P. Das Lymfgefasssystem. In *Handbuch der Anatomie des Menschen*. Ed. K. von Bardeleben .3.Band, Semper Bonis Artibus, Jena 1909.
4. Bruhns C (1898) Ueber die Lymphgefäse der weiblichen Genitalien , nebst einigen Bemerkungen über die Topographie der Leistendrüsen. *Arch f Anat U Phys Anat*, Abt. 57-80.

5. Eliska O, Eliskova M (2001) Morphology of lymphatics in human venous crural ulcers with lipodermatosclerosis. *Lymphology*, 34:111-123.
6. Fons G, ter Rahe B, Sloof G (2004) Failure in the detection of the sentinel lymph node with a combined technique of radioactive tracer and blue dye in a patient with cancer of the vulva and a single positive lymph node. *Gynecologic Oncology*, 92: 981-984.
7. Gerota D (1896) Zur Technik der Lymphgefassinjektion – Eine neue Injektionsmasse fuer Lymphgefasse-Polychrome Injektion. *Anat Anz.* 12: 216-224.
8. Gordinier ME, Malpica A, Burke TW (2003) Groin recurrence in patients with vulvar cancer with negative nodes on superficial inguinal lymphadenectomy. *Gynecologic Oncology*, 90: 625-628.
9. Hassanzade M, Attaran M, Treglia G (2013) Lymphatic mapping and sentinel node biopsy in squamous cell carcinoma of the vulva: systematic review and meta-analysis of the literature. *Gynecol Oncol*, 1: 237-45.
10. Judson et al (2006) Trends in the incidence of invasive and in situ vulvar carcinoma. *Obstet Gynecol*, 107: 1018-1022.
11. Kubik S, Manestar M (1995) Topographic relationship of the ventromedial lymphatic bundle and the superficial inguinal nodes to the subcutaneous veins. *Clin Anat*, 1: 25-8.
12. Levenback Ch, Burke T W, Morris M (1995) Potential applications of intraoperative lymphatic mapping in vulvar cancer. *Gynecologic Oncology*, 59: 216-220.
13. Levenback Ch, Coleman R, Burke T W (2001) Intraoperative lymphatic mapping and sentinel node identification with blue dye in patients with vulvar cancer. *Gynecologic Oncology*, 83: 276-281.
14. Levenback et al. (2012) Lymphatic mapping and sentinel lymph node biopsy in women with squamous cell carcinoma of the vulva: a gynecologic oncology group study. *J Clin Oncol*, 31: 3786-91.
15. Oonk et al (2017) European Society of Gynaecological Oncology Guidelines for the Management of Patients With Vulvar Cancer. *Int J Gynecol Cancer*, 4: 832-837.
16. Parry-Jones E (1963) Lymphatics of the vulva. *J of Obstetrics and Gynecology of the British Commonwealth*, 70: 751-765.
17. Poirer P, Cuneo B. Etude speciale des lymphatiques des differentes parties du corps. In Poirer P, Charpy A.: *Traite d'anatomie humaine Tom II, Les lymphatiques*, Masson et Cie Ed., Paris 1909.
18. Puig-Tintoré L M, Ordi J, Vidal-Sicart S (2003) Further data on the usefulness of sentinel lymph node identification and ultrastaging in vulvar squamous cell carcinoma. *Gynecologic Oncology*, 88: 29-34.
19. Qian Xu and James E Moore Jr (2020) Ex vivo perfusion of human lymph nodes. *J Pathol*, 251: 225–227, DOI: 10.1002/path.5454
20. Ramirez PT, Levenback Ch (2001) Sentinel nodes in gynecologic malignancies. *Curr. Opin. Oncol*, 13: 403-407.
21. Reiffenstuhl G. *Das Lymphsystem des weiblichen Genitale*. Ed. Urban & Schwarzenberg. Munchen Berlin Wien 1957.

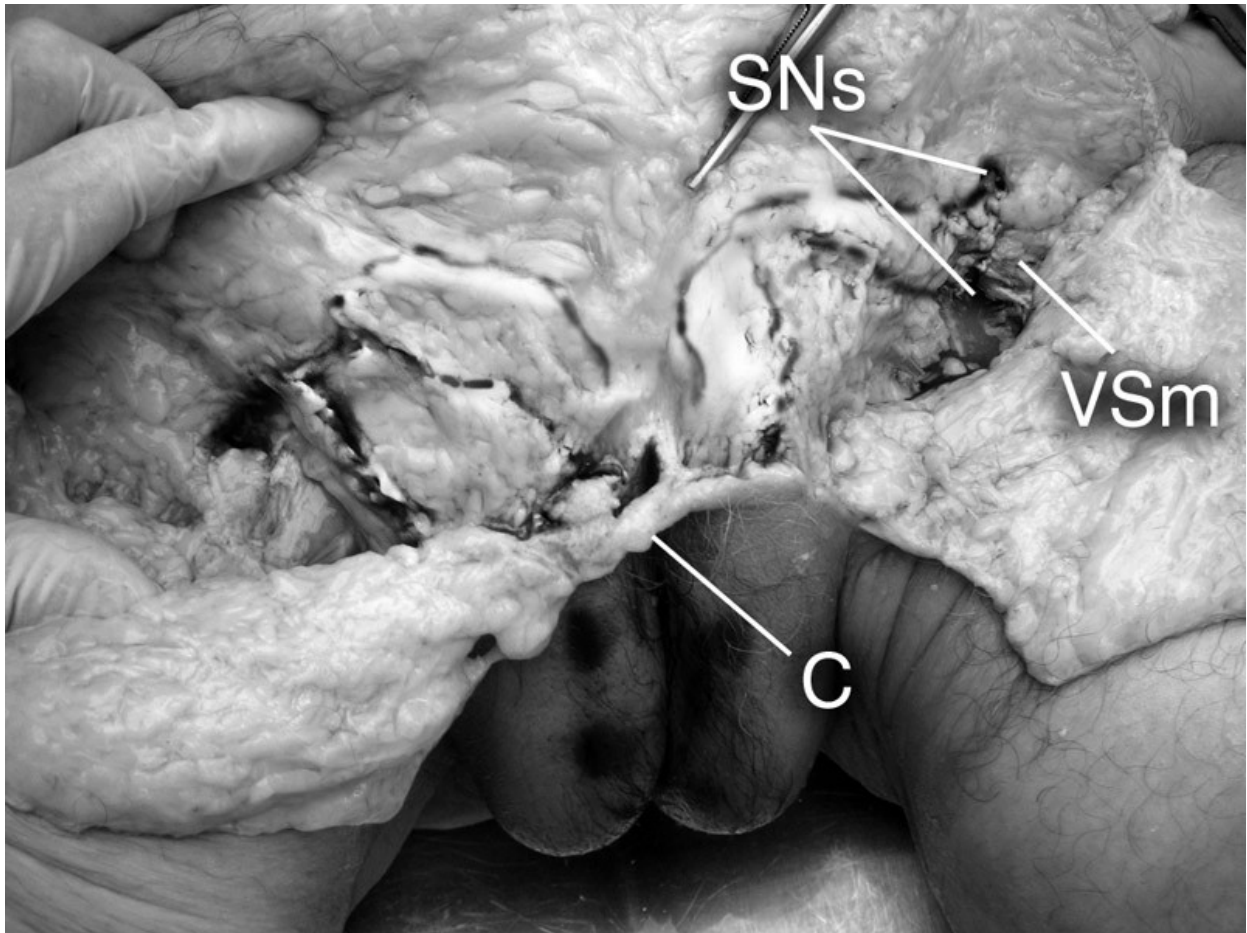
22. Rob L, Robová H, Pluta M (2007) Further data on sentinel lymph node mapping in vulvar cancer by blue dye and radiocolloid Tc 99. *Int. J Gynecol Cancer*, 17: 147-153.
23. Rouviere H. *Anatomie des lymphatiques de l'homme*. Masson, Paris 1932.
24. Sappey Ph C. *Traite de,anatomie descriptive Tome II Myologie Angiologie*. Adrien Delaheaye et Cie Libraire Editeurs, Paris 1876.
25. Suami H, Shinaoka A (2019) The methodology of lymphatic anatomy studies in a cadaver model: an overview. *Plast Aesthet Res*, 6: 33. <http://dx.doi.org/10.20517/2347-9264.2019.46>



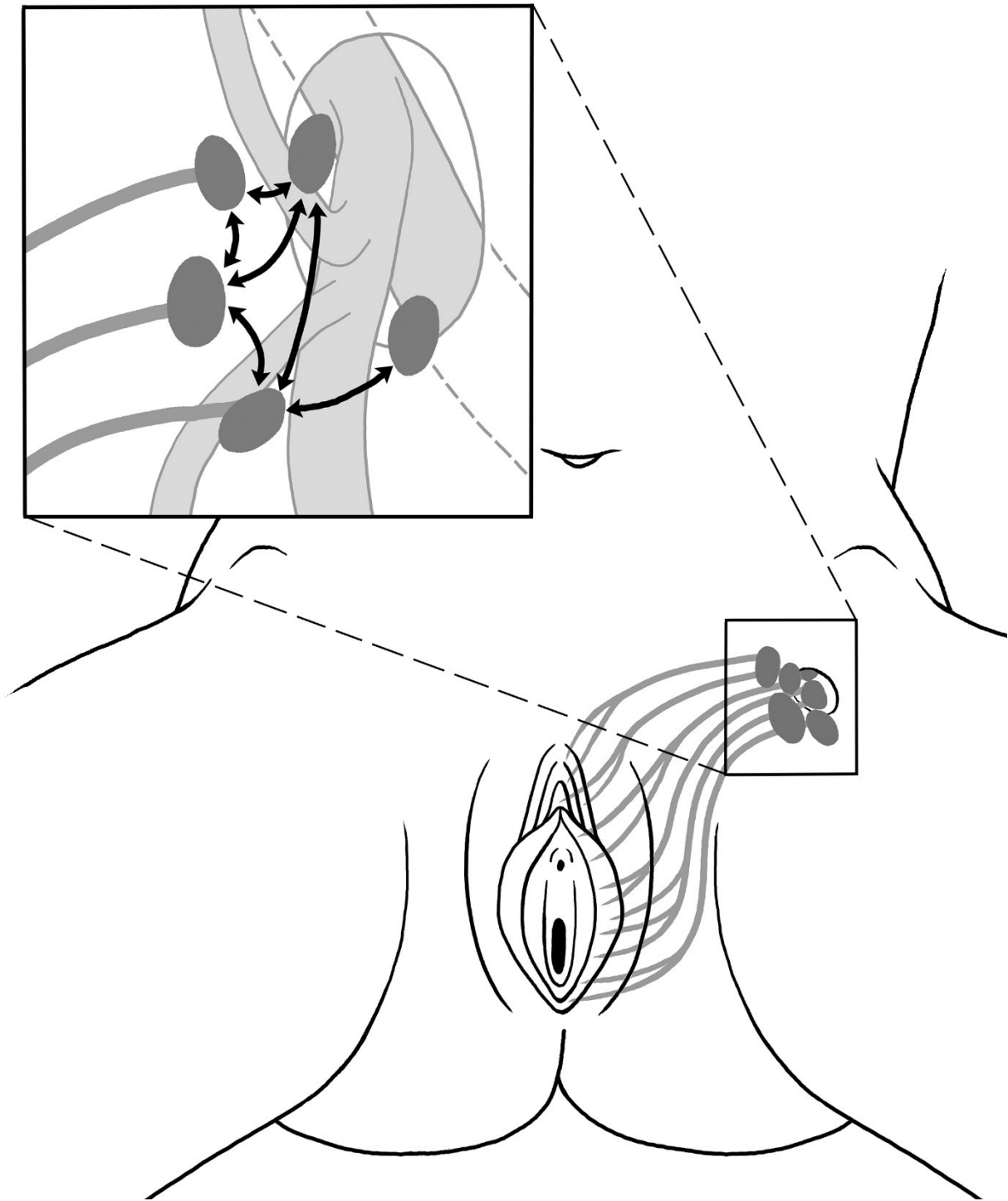
**Figure 1.** Superficial lymphatic collectors of the vulva. LCR - lymphatic collectors on the right side, LCL - lymphatic collectors on the left side, LMi – labia minora, C – clitoris, SN – sentinel node.



**Figure 2.** Superficially dissected groin on the left side. LCR - lymphatic collectors on the right side, LCL - lymphatic collectors on the left side, LM – labia majora, C – clitoris, SNs – sentinel nodes on the left side, M – musculus gracilis, VSm – vena saphena magna.



**Figure 3.** Dissected superficial lymphatic vessels of the vulva. C – clitoris, SNs – sentinel nodes on the left side, VSm – vena saphena magna.



**Figure 4.** Schematic of superficial lymphatics of the vulva. Dark gray – superficial lymphatics of the vulva, thin black arrow – thin connections between nodes.