

ONE-STAGE BILATERAL TOTAL HIP REPLACEMENT USING DIRECT ANTERIOR APPROACH VIA „BIKINI“ INCISION: A CASE REPORT

Trpimir Vrdoljak^{1,2}, Vilim Molnar¹, Željko Jeleč^{1,3}, Vid Matišić¹, Borut Dobričić^{1,4}, Igor Borić^{1,5,6,7,8}, Dragan Primorac^{1,5,6,7,9,10,11,12,13}

ABSTRACT

Background: Osteoarthritis (OA) is a musculoskeletal condition that is affecting an increasing number of individuals due to an aging population. The aim of our case report was to present one-stage bilateral efficient direct anterior total hip replacement via „bikini“ incision, to describe the course of the operation, as well as the advantages and the disadvantages of this procedure.

Case study: A 38-year old patient, without any comorbidities, presented with severe OA of both hips. Due to co-existing OA on both joints and the patient's motivation and desire for faster recovery, he underwent a one-stage bilateral hip replacement using a direct anterior approach via a „bikini“ incision. Physical therapy began immediately after the surgery and the patient was verticalized on the first postoperative day. Eight days after the procedure, the patient was discharged from the hospital.

Conclusion: One-stage total hip replacement should be considered for patients with OA of both hips to reduce the postoperative hospital stay and the need for long-term rehabilitation.

KEYWORDS: Total hip replacement, osteoarthritis, direct anterior approach, bikini incision

INTRODUCTION

Osteoarthritis (OA) is a highly prevalent disease, affecting 303 million people worldwide, making it the most common progressive musculoskeletal condition that affects joints [1].

Even though OA can affect any joint, it mainly affects the hips and knees as the predominant weight-bearing

joints [2,3]. Although novel treatments are emerging daily, modern medicine still hasn't found a treatment that would stop the progression of OA. Therefore, joint replacement surgery is the gold standard in OA treatment. Surgical techniques, as well as surgical implants, have constantly been improving.

The direct anterior approach (DAA) is a muscle-sparing technique associated with fewer surgical complications, shorter duration of postoperative rehabilitation and reduced chance of hip joint dislocation [4,5]. Efficient direct anterior (EDA) hip replacement represents a concept of the DAA approach to the hip with the use of specific instruments which enable shorter operating time and limited muscle damage. One-staged bilateral hip arthroplasty is a surgical procedure in which both hips are treated. It can be considered in patients suffering from bilateral severe hip OA, who are motivated and require combined surgery [6].

Here we describe a case of a patient with severe bilateral hip OA that underwent a one-staged bilateral total hip replacement using a DAA via „bikini“ incision.

CASE STUDY

A 38-year-old patient, who has been a professional handball player for 15 years, presented to an orthopaedic outpatient clinic with long-term pain in both hips that lasted for 11 years. The patient reported experiencing joint pain on a daily basis, which was more intense with exercise. Previous treatment included intra-articular applications of hyaluronic acid, platelet-rich plasma and mesenchymal stem cells, all of which were ineffective in long-term pain relief. Clinical examination marked a limitation of motion in both

¹ St. Catherine Specialty Hospital, 49210 Zabok/10000 Zagreb, Croatia

² Clinical Hospital „Sveti Duh“, 10000 Zagreb, Croatia

³ Department of Nursing, University North, 48000 Varaždin, Croatia

⁴ Department of Orthopaedics and Traumatology, University Hospital Dubrava, 10000 Zagreb, Croatia

⁵ Medical School, University of Split, 21000 Split, Croatia;

⁶ Medical School, University of Rijeka, 51000 Rijeka, Croatia

⁷ Medical School, University of Mostar, 88000 Mostar, Bosnia and Herzegovina

⁸ Department of Health Studies, University of Split, 21000 Split, Croatia

⁹ Eberly College of Science, The Pennsylvania State University, University Park, State College, PA 16802, USA

¹⁰ The Henry C. Lee College of Criminal Justice and Forensic Sciences, University of New Haven, West Haven, CT 06516, USA

¹¹ Faculty of Dental Medicine and Health, Josip Juraj Strossmayer University of Osijek, 31000 Osijek, Croatia

¹² Faculty of Medicine, Josip Juraj Strossmayer University of Osijek, 31000 Osijek, Croatia

¹³ Medical School REGIOMED, 96450 Coburg, Germany

Corresponding author: Trpimir Vrdoljak, St. Catherine Specialty Hospital, 49210 Zabok/10000 Zagreb, Croatia

e-mail: trpimir.vrdoljak@gmail.com

DOI: 10.5281/zenodo.5501489

joints. The flexion in the right hip was 80 degrees and in the left 100 degrees. Internal rotation was disabled on both sides, i.e., 0 degrees, while external rotation in the right hip was 20 degrees, and in the left 30 degrees. All the activities involving the hip joints were extremely painful. The radiographic assessment confirmed the diagnosis of severe OA of both hips (Figure 1). Due to severe osteoarthritic changes that complicated the patient's daily life and functions, the patient's good general health and his motivation to solve the problem with both hips in a single act surgery, it was decided to perform a one-staged bilateral total hip replacement.

After preoperative patient assessment and procedure planning, the patient was directed to the operating theatre. The operation was performed under general anesthesia with the patient positioned in the supine position. The right hip was approached first. After sterile operative field preparation and surgical draping, a „bikini“ incision, parallel to the inguinal skin crease, was made for the DAA to the hip. After retracting the skin both superiorly and inferiorly, a longitudinal dissection of the fascial layer of the tensor fascia latae (TFL) was made on the lateral side of the incision. By blunt dissection, an interval between the sartorius muscle and TFL was exposed. Followed by further retraction of rectus femoris muscle and TFL, the hip joint capsule was exposed and capsulotomy was performed. The femoral head was removed, and the acetabulum was processed according to preoperative planning. A cementless acetabular shell was implanted (Trilogy® Acetabular System, size 62 mm, Zimmer) together with an acetabular insert (Longevity® Highly Crosslinked Polyethylene, Elevated Rim Liner, Zimmer). Further preparation was made for the femoral component implantation by placing the leg, below the other leg, in adduction, extension and external rotation in the hip. After femoral processing, trial reposition, and stability assessment, an original femoral stem was implanted (Corail® Hip System, Cementless Femoral Stem, size 11, DePuy). The femoral head (BioloX® Delta Ceramic Femoral Head, size 32 mm + 5.0, DePuy) was placed and the reduction of the hip joint was performed. Drainage was placed before wound closure, which was performed using running sutures for TFL fascia, interrupted sutures for the subcutaneous tissue and intracutaneous suture for the skin. Successively, the same procedure was performed for the left hip. Following components were implanted: acetabular shell (Trilogy® Acetabular System, size 62 mm, Zimmer), acetabular insert (Longevity® Highly Crosslinked Polyethylene, Elevated Rim Liner, Zimmer), femoral stem (Corail® Hip System, Cementless Femoral Stem, size 12, DePuy) and the femoral head (BioloX® Delta Ceramic Femoral Head, size 32 mm + 5.0, DePuy). The sizes of the implanted components of both hips were equal to the preoperative planning. The leg lengths after the replacement of both hips were equal. The position of both hip prostheses is shown in Figure

2. It was decided not to change the patient's existing hip rotation center. In this way, multiple benefits were achieved: muscle tension remained unchanged, avoidance of acetabular medialization removed the possibility of ischiofemoral impingement in external rotation, and preserved bone thickness in the pelvis for future revision surgeries. Acetabular components were implanted following the existing bone block and pelvic shape. The higher inclination of the acetabulum on both sides was compensated by the use of an elevated polyethylene insert which preserved the stability of the prosthesis.

A total intraoperative blood loss, with the intravenous application of 2g of tranexamic acid, was 700 mL. On the first postoperative day, there were 560 ml of blood in the drainage system. The patient was mobilized using crutches and physical therapy began. The patient was receiving antibiotics and antithrombotic prophylaxis during his hospital stay. Postoperatively, the patient spent 8 days in the orthopedic department and was discharged home from the hospital. Two weeks after the surgery, the patient was walking without crutches and any pain. On the clinical examination, the flexion in both hips in the supine position was 120 degrees. The internal rotation in the right hip was 20 degrees and in the left 30 degrees, while the external rotation in both hips was 50 degrees.

DISCUSSION

In recent years, many studies were conducted to determine the potential superiority of the anterior approach over the posterior and lateral approaches to the hip. According to some researchers, EDA hip replacement provides better outcomes for the patient in terms of duration of postoperative rehabilitation, shorter average hospital length of stay, more rapid recovery with less pain and less use of narcotic pain medications [7–9]. The DAA minimizes damage to the surrounding soft tissues, resulting in lower inflammatory serum markers. Arguments raised against its use include lateral femoral cutaneous nerve (LFCN) neurapraxia and iatrogenic trochanteric fractures [7]. Also, due to the long learning curve, it takes a long time to educate surgeons and completely switch from a posterior and lateral approach to a DAA [5,10]. One-staged bilateral total hip arthroplasty was initially designed with the idea of reducing the postoperative number of days in the hospital and the need for long-term rehabilitation. A systematic review by Muskus and colleagues showed that there is no difference in mortality and incidence of systemic complications between separate and simultaneous surgeries when the surgery is performed in younger and healthy patients without cardiovascular comorbidities [6]. A 7-year data review by Johnston et al. proved that treatment costs are higher with staged surgery than with simultaneous bilateral hip replacement. Furthermore, there was no

difference in patient satisfaction rates and Harris Hip Scores improvements in pain and function between the groups [11]. What facilitates the performance of simultaneous bilateral total hip arthroplasty is the supine position of the patient for the direct anterior hip approach. Therefore, there is no need to turn the patient during surgery or to have a double sterile operative field preparation and surgical draping, as there would be for the lateral decubitus patient position for the lateral or posterior hip approach. Furthermore, in the supine position for DAA, it is much easier to compare the length of the patient's legs.

After bilateral hip joint replacement, it is impossible to walk with a partial load because there is no unoperated leg that can serve as a support. However, a meta-analysis by Tian et al. concluded that early full weight-bearing after cementless total hip arthroplasty is safe and without increased risks of postoperative complications compared to partial weight-bearing [12]. Therefore, we allowed our patient to walk at full load and to discard crutches at his own discretion. Even though, in this case report we did not follow the patient for a longer period, the patient's condition 2 weeks after the surgery, range of motion and ability to walk without crutches gave us the confidence in showing the operative technique and short term follow-up of this patient.

After the development of the DAA, there was a demand for a type of incision that would leave a minor cosmetic defect compared to the longitudinal incision. Also, one of the potential concerns about the DAA performed via longitudinal incision was inferior wound healing [13,14]. „Bikini“ incision provides greater patient satisfaction due to cosmetic reasons (Figure 3). The main issue with the longitudinal incision is presented in not following the anatomic cleavage lines and its perpendicularity to the relaxed skin tension lines, which can result in scar widening [13]. Uncomfortable symptoms related to both longitudinal and bikini stitching include pruritus, pain and paresthesia [13]. Potential complications after a „bikini“ incision include an increased possibility of infection and an increased risk of LFCN injury. Also, one of the concerns associated with „bikini“ incision is in reduced intraoperative visibility of components, which can disrupt orientation and make component management difficult [13].

CONCLUSION

OA is the most common chronic joint condition that correlates with age. The outcome of surgical treatment is greatly influenced by the patient's comorbidities. With a multimodal approach, based on further advances in surgical technique and careful patient selection, pain control management, reduced blood loss and even more effective thromboprophylaxis one-stage surgery for bilateral total hip replacement will

potentially become the future of orthopedic treatment. Furthermore, every patient with multiple joint OA should be accessed based on an individual approach. One-stage bilateral hip replacement surgeries require shorter, but more intensive rehabilitation. Therefore, it is important to recognize a determined and motivated patient whose attitude will improve the success of the operation.

CONFLICT OF INTEREST:

The authors declare that there is no conflict of interest.

The patient gave his informed consent prior to his inclusion in case report.

REFERENCES

1. Kloppenburg M, Berenbaum F. Osteoarthritis year in review 2019: epidemiology and therapy. *Osteoarthr Cartil.* 2020;28:242–8.
2. Mabey T. Cytokines as biochemical markers for knee osteoarthritis. *World J Orthop.* 2015;6:95.
3. Bortoluzzi A, Furini F, Scirè CA. Osteoarthritis and its management - Epidemiology, nutritional aspects and environmental factors. *Autoimmun Rev.* 2018;17:1097–104.
4. Meermans G, Konan S, Das R, Volpin A, Haddad FS. The direct anterior approach in total hip arthroplasty. *Bone Joint J.* 2017;99-B:732–40.
5. Kyriakopoulos G, Poultsides L, Christoflopoulos P. Total hip arthroplasty through an anterior approach. *EFORT Open Rev.* 2018;3:574–83.
6. Muskus M, Rojas J, Gutiérrez C, Guio J, Bonilla G, Llinás A. Bilateral Hip Arthroplasty: When Is It Safe to Operate the Second Hip? A Systematic Review. Vol. 2018, *BioMed Research International.* Hindawi Limited; 2018. p. 1–10.
7. Martin CT, Pugely AJ, Gao Y, Clark CR. A Comparison of Hospital Length of Stay and Short-term Morbidity Between the Anterior and the Posterior Approaches to Total Hip Arthroplasty. *J Arthroplasty.* 2013;28:849–54.
8. Agten CA, Sutter R, Dora C, Pfirrmann CWA. MR imaging of soft tissue alterations after total hip arthroplasty: comparison of classic surgical approaches. *Eur Radiol.* 2017;27:1312–21.
9. Parvizi J, Restrepo C, Maltenfort MG. Total Hip Arthroplasty Performed Through Direct Anterior Approach Provides Superior Early Outcome. *Orthop Clin North Am.* 2016;47:497–504.
10. Zawadsky MW, Paulus MC, Murray PJ, Johansen MA. Early Outcome Comparison Between the Direct Anterior Approach and the Mini-Incision Posterior Approach for Primary Total Hip Arthroplasty: 150 Consecutive Cases. *J Arthroplasty.* 2014;29:1256–60.
11. Johnston LR, Clift BA, Abboud RJ. Bilateral simultaneous hip replacement versus bilateral sequential hip replacement: A 7-year data review. *Orthop Nurs.* 2011;30:119–23.
12. Tian P, Li ZJ, Xu GJ, Ma XL. Partial versus early full weight bearing after uncemented total hip arthroplasty: a meta-analysis. *J Orthop Surg Res.* 2017;12:31.
13. Leunig M, Huttmacher JE, Ricciardi BF, Impellizzeri FM, Rüdiger HA, Naal FD. Skin crease 'bikini' incision for the direct anterior approach in total hip arthroplasty. *Bone Joint J.* 2018;100-B:853–61.
14. Leunig M, Faas M, von Knoch F, Naal FD. Skin Crease 'Bikini' Incision for Anterior Approach Total Hip Arthroplasty: Surgical Technique and Preliminary Results. *Clin Orthop Relat Res.* 2013;471:2245–52.

FIGURES

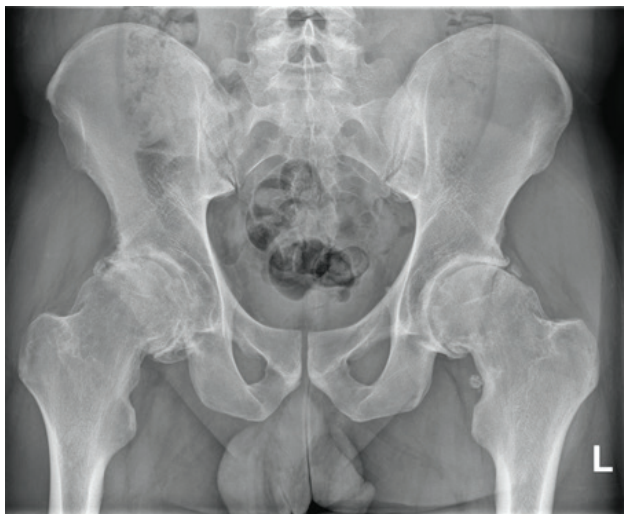

Figure1. Anteroposterior X-ray image of the patient's hips showing severe bilateral coxarthrosis.

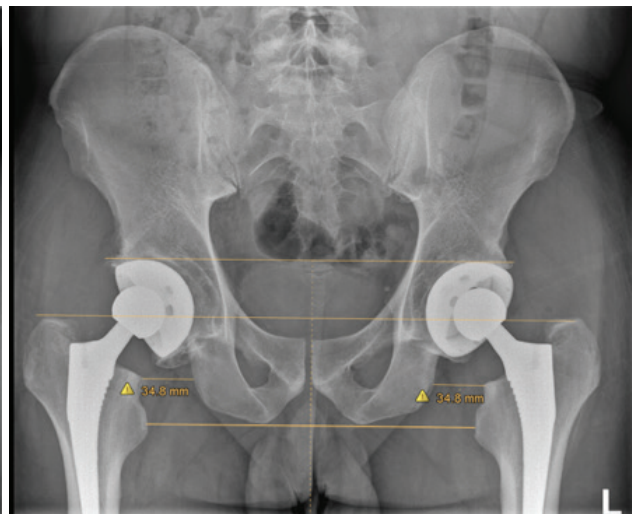


Figure2. Anteroposterior X-ray image after bilateral hip replacement surgery. The line that connects the tops of two acetabular components and the line that connects two tops of greater trochanters (through the center of implanted femoral heads) are parallel to the bottom pelvic line that connects two lesser trochanters. The higher inclination of the acetabulum was compensated by the use of an elevated polyethylene insert not to damage the stability of the prosthesis.

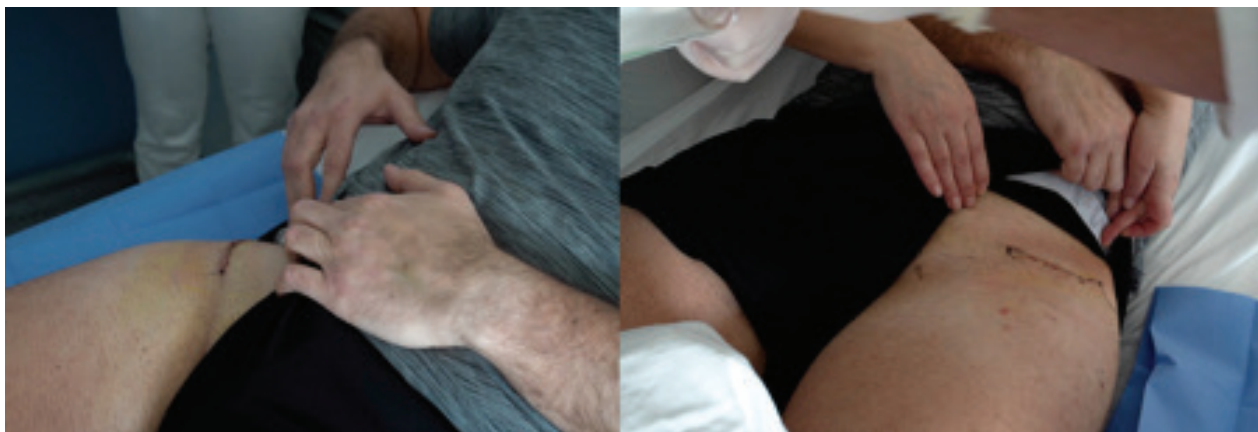


Figure3. Skin scars eight days after one-stage bilateral total hip replacement using direct anterior approach via "bikini" incision.