

A false positive FDG PET/CT result in a patient with prosthetic heart valve disease

 Petra Grubić Rotkvić¹,
 Zrinka Planinić^{*},
 Ines Zadro Kordić¹,
 Ognjen Čančarević¹,
 Tea Friščić¹,
 Ante Pašalić¹,
 Jozica Šikić^{1,2}

¹University Hospital "Sveti Duh", Zagreb, Croatia

²University of Zagreb, School of Medicine, Zagreb, Croatia

KEYWORDS: infective endocarditis, Duke criteria, prosthetic valve, positron emission tomography.

CITATION: *Cardiol Croat.* 2021;16(9-10):303. | <https://doi.org/10.15836/ccar2021.303>

***ADDRESS FOR CORRESPONDENCE:** Zrinka Planinić, Klinička bolnica „Sveti Duh“, Sv. Duh 64, HR-10000 Zagreb, Croatia. / Phone: +385-91-3714-308 / E-mail: zrinkaplaninic@gmail.com

ORCID: Petra Grubić Rotkvić, <https://orcid.org/0000-0002-2587-1932> • Zrinka Planinić, <https://orcid.org/0000-0001-8664-3338>
Ines Zadro Kordić, <https://orcid.org/0000-0002-0754-7194> • Ognjen Čančarević, <https://orcid.org/0000-0002-1285-8042>
Tea Friščić, <https://orcid.org/0000-0003-3189-8661> • Ante Pašalić, <https://orcid.org/0000-0001-5989-6495>
Jozica Šikić, <https://orcid.org/0000-0003-4488-0559>

Introduction: Prosthetic valve endocarditis (PVE) represents 10-30% of all cases of endocarditis, occurring in 1 – 6% of patients with prosthetic valves. Diagnosis of PVE is made according to the modified Duke criteria that are less sensitive than for native valve endocarditis (NVE) given limitation of echocardiography¹. Even though ¹⁸F-fluorodeoxyglucose positron emission tomography/computed tomography (FDG-PET/CT) is a more accurate diagnostic tool for PVE included as a major criterion in the

European Society of Cardiology (ESC) Guidelines for the management of infective endocarditis (IE), increased periprosthetic FDG uptake not always reflects infection².

Case report: 75-year-old male patient with a prior history of Bentall procedure in 2013 has been hospitalized for fever of unknown origin. Blood cultures came positive on *Streptococcus pluranimalium* and a high suspicion of PVE was raised. Transesophageal echocardiography (TEE) showed a suspected vegetation on mechanical aortic valve without compromising valve function (**Figure 1**). No other signs of septic embolization were found, except subconjunctival hemorrhage. Since two major and two minor Duke criteria for definite IE were met, the patient was started on standard antibiotic treatment according to ESC guidelines. Despite completed targeted antibiotic treatment, the patient remained subfebrile without clear clinical manifestation of infection with repeated negative blood cultures and no signs of vegetation on TEE. FDG PET/CT was performed and showed diffuse perivalvular FDG uptake pattern consistent with inflammation. While awaiting for the PET/CT result, the patient became afebrile with no laboratory or clinical signs of infection. In consultation with cardiac surgeon a strategy of watchful waiting was taken. The patient remained stable during one year follow-up.

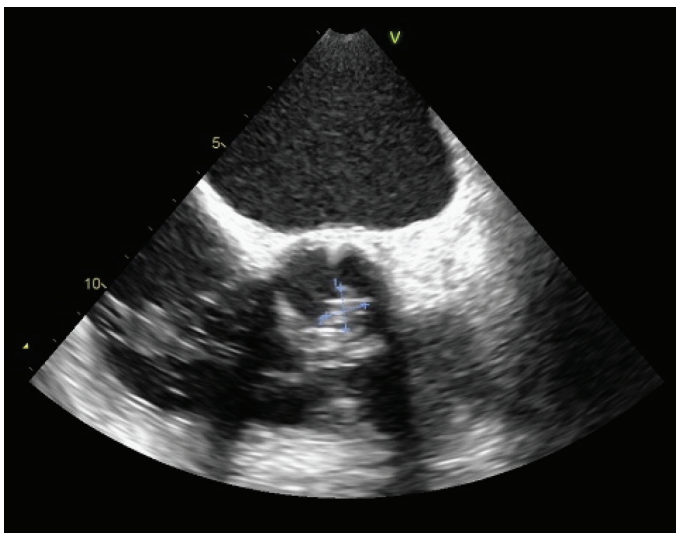


FIGURE 1. Transesophageal echocardiography showing suspected vegetation on an mechanical aortic valve.

Conclusion: Homogenous FDG uptake may be present in the perivalvular area in the absence of PVE, even years after valve implantation¹. Since the factors used to distinguish normal and abnormal FDG uptake patterns are not yet standardized², clinical judgement and multidisciplinary treatment approach are still crucial in decision making.

RECEIVED:
July 24, 2021

ACCEPTED:
August 5, 2021



LITERATURE

1. Mathieu C, Mikaili N, Benali K, Lung B, Duval X, Nataf P, et al. Characterization of ¹⁸F-Fluorodeoxyglucose Uptake Pattern in Noninfected Prosthetic Heart Valves. *Circ Cardiovasc Imaging.* 2017 Mar;10(3):e005585. <https://doi.org/10.1161/CIRCIMAGING.116.005585>
2. Erba PA, Slart RHJA. Pattern recognition on fluorodeoxyglucose positron emission tomography/computed tomography in infective endocarditis: within the normal limits? *Eur Heart J Cardiovasc Imaging.* 2020 Jan 1;21(1):34-35. <https://doi.org/10.1093/ehjci/jez254>