

THE DIAGNOSTICS AND TREATMENT OF CERVICAL CANCER

ZLATKO HRGOVIĆ¹, RAJKO FUREŠ^{2,3,4}, ŽANA STANIĆ^{2,3,4}

¹*Frauenklinik, J.W. Goethe Universität, Frankfurt am Main, Germany;* ²*Josip Juraj Strossmayer University of Osijek, Faculty of Dental Medicine and Health, Osijek, Croatia;* ³*Josip Juraj Strossmayer University of Osijek, Department of Integrative Gynecology, Obstetrics and Minimally Invasive Gynecologic Surgery, Faculty of Dental Medicine and Health, Osijek, Croatia;* ⁴*Zabok General Hospital and Croatian Veterans Hospital, Department of Gynecology and Obstetrics, Zabok, Croatia*

Cervical cancer is the second most commonly diagnosed cancer among women in less developed countries with the incidence of about half million new cases and a quarter million deaths worldwide. Croatian cervical cancer epidemiological data lie in the European average and reflect current social characteristics of the society. Important key is that about 40% of targeted population do not respond to the national strategies proposed for prevention and early detection of cervical cancer. Traditional, well established Croatian preventive programs provide appropriate ground to detect preinvasive and early stages of cervical cancer, which should be regularly updated and refreshed with new discoveries and modern guidelines. Special strategies to motivate and encourage women to use preventive measures should be created and aggressively advertised in all aspects of social life. The objective of this review is to compare several current international guidelines for diagnosis and treatment of cervical cancer, and to present the homogenized management of these patients.

Key words: cervical cancer, guidelines, cervix, surgery, chemotherapy, radiotherapy

Address for correspondence: Prof. Zlatko Hrgović, MD, PhD
Frauenklinik, J.W. Goethe Universität Frankfurt
Theodor-Stern-Kai 7
Frankfurt am Main, 60590, Germany
E-mail: info@hrgovic.de

INTRODUCTION

In 2014, cervical cancer accounted for about 3% of all malignancies in Croatia, representing a major public health problem with estimated 310 new cervical intraepithelial neoplasia (CIN III) cases and 307 new cervical cancer cases annually. In the same year, there were 130 cervical cancer related deaths, placing Croatia in the middle of the European five-year relative survival rate (1). The average European survival rate shows sustainable geographic variations due to remarkable differences in the prevalence of human papillomavirus (HPV) infection, and availability of screening and HPV vaccination among European countries (2). The connection of HPV chronic infection with development of cervical cancer is well documented. History of smoking, parity, oral contraceptive use, early age at onset of sexual activity, numerous sexual partners, history of sexually transmitted disease, certain autoimmune diseases, and chronic immunosuppression are

other possible epidemiological risk factors associated with cervical cancer (3). Squamous cell carcinoma accounts for approximately 80% and adenocarcinoma for approximately 20% of all cervical cancers (4). Globally, about 80% of women experience HPV infection during life span, but the infection has a subclinical course in about 75% of infected women (5). The peak incidence of HPV infection in young women is observed between age 20 and 25. In 80% of previously infected women, after one year the virus cannot be detected with biomolecular tests available (6) (Table 1).

Table 1.
Biomolecular tests for HPV detection

Test name	Methodology	HPV type
Hybrid capture test	HPV DNA-hybridization	13 high-risk viral types and additional 5 low-risk types
Cobas 4800 test	DNA-PCR	14 high-risk types of HPV, special accent on types 16 and 18

Persistent HPV infection presents a ground for development of cervical cancer. After discovery of the HPV role in cervical cancer oncogenesis, emphasis was put on systematic prevention. Active immunization is performed with vaccines consisting of several types of dead viruses prepared by biotechnology in order to prevent HPV infection and subsequent development of genital condylomas and cervical neoplasia (2) (Table 2).

Table 2.
 HPV vaccination modalities

Vaccine	HPV types	Vaccination schedule
Cervarix	16,18	0, 1, 6 months i.m.
Gardasil	6,11,16 and 18	9-14 years: 0, 4-5 months (if second dose delayed after 5 months, 3 rd dose mandatory) Older than 15: 0, 2, 6 months
Gardasil 9	6, 11, 16, 18, 31, 33, 46, 52, 58	9-14 years: 0, 4-5 months (if second dose delayed after 5 months, 3 rd dose mandatory) Older than 15: 0, 2, 6 months

Current approach is to vaccinate children of both sexes to achieve the best immunity status prior to the onset of sexual maturity (7). The Croatian national cervical cancer screening program offers Papanicolaou (PAP) cervical smears each three years. However, recent statistics show that in Croatia only about 40% of targeted population are really covered with the program, responding to the proposed screening recommendations, which affects national statistics (8). On the other hand, it is also clear that PAP smear alone has important limitations due to its rather low sensitivity (about 51%). Its accuracy can be affected by errors in sampling (proper sampling from transformational zone), subjectivity of the cytologist interpretation of the smear, effect of fatigue, and objective technical appropriateness of the smear (9). Adding HPV-DNA typing besides PAP smear improves the accuracy up to 70%, making it highly recommendable, especially in women with epidemiological risks, mainly those older than 30 years (10). Abnormal cervical cytology mandates further evaluation following the protocol presented in Figure 1.

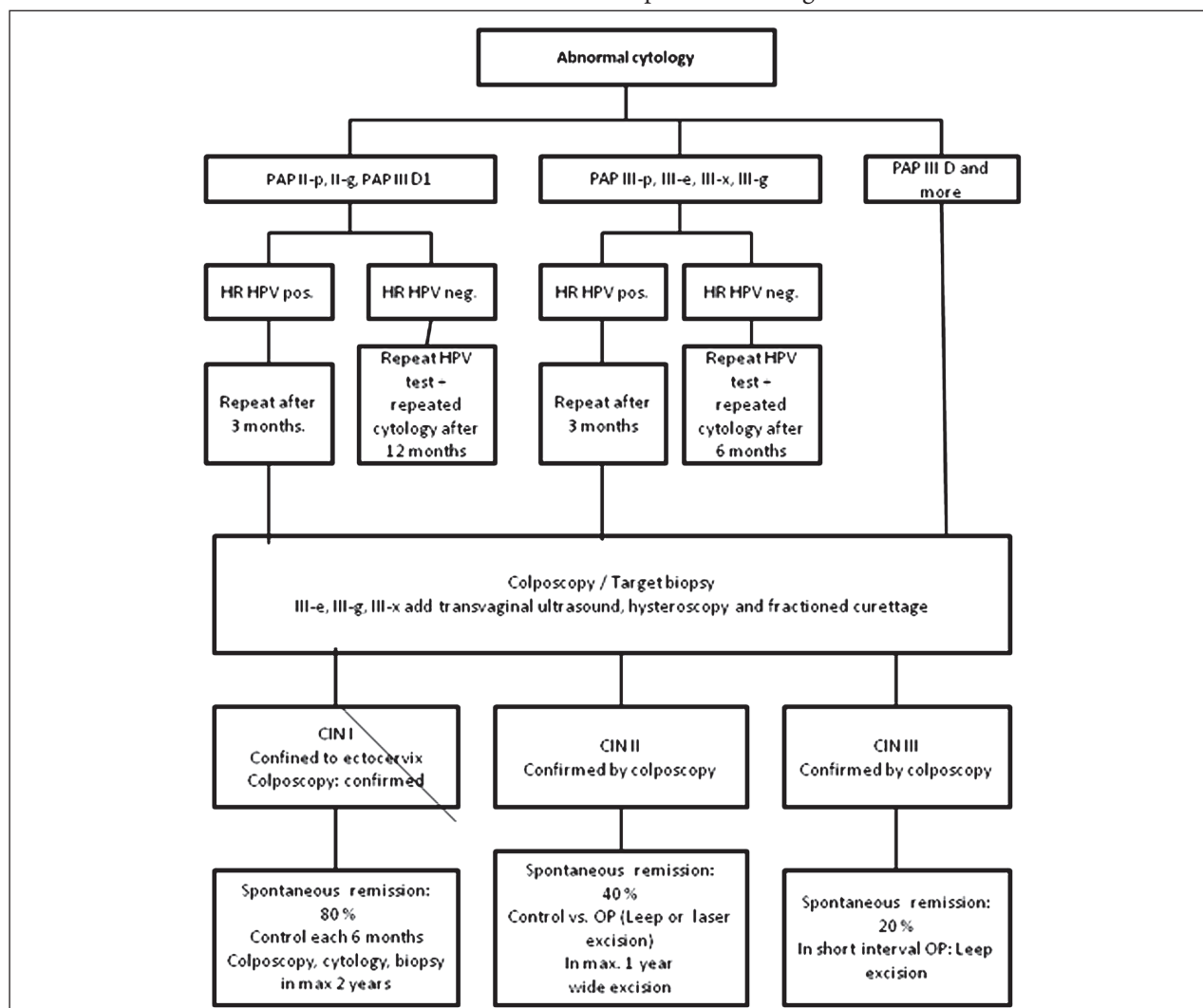


Fig. 1. Management flow chart of cervical intraepithelial neoplasia - CIN I-III.

Cervical cancer accounts for about 30% of gynecologic malignancies, holding the third position after endometrial and ovarian cancer. It is the second most common cancer in young women (25-29 age group), just after breast cancer (8). The apparent rising trend in the incidence of cervical cancer in this age group is of high importance. Although it is observed that cervical cancer in younger women has better prognosis and better survival indices (10), it remarkably affects the quality of life and eventual fertility wishes of the patient. Special concern is paid to the treatment of cervical neoplasia in pregnancy. Numerous obstetricians still have doubts regarding accurate strategy of pregnancy management and treatment of cervical malignancies when conjoined. The increasing trends of cervical cancer incidence in younger women of generative age warrant clear and reasonable rules for the management of cervical pathology in reproductive age and in pregnancy. Besides classic guidelines for the management of cervical cancer, we have also presented a segment of fertility sparing therapy (11), which enables safe preservation of fertility and successful family planning in selected patients.

Vaccination

The anti-HPV vaccination is usually provided by public health services for children aged 9-14 with two doses five months apart. If the second dose is applied after five months, the third dose must be administered. After the age 15, three doses are necessary, administered according to the following schedule: at 0, 2 and 6 months apart (12). The vaccination is recommendable for all women, especially younger population. It has been observed that the cumulative risk of fresh HPV infection declines with advancing age. In women above 45 years, the risk is about 15% (13). The vaccine was originally designed for girls. However, recently, it has been demonstrated that achievement of HPV immunity in communities which vaccinate both boys and girls leads to remarkable drop in the incidence of cervical cancer, and shows its maximal effects three years after vaccination (14). Permanent HPV infection in unvaccinated young men presents a threat of horizontal spread of the infection. Furthermore, sexual contact with infected partner carries the risk of re-infection for the women who have already been treated due to HPV-related pathology. After cervical conization, the gynecologist should offer HPV vaccination. In vaccinated patients, the risk of recurrent disease in the next ten years declines by 80% (15). Pregnancy and existing CIN both present contraindications for HPV vaccination.

Cervical intraepithelial neoplasia in pregnancy

The prevalence of suspicious smears in pregnancy is 2%-5%. The incidence of CIN in pregnant women

does not differ from the one in non-pregnant age-matched population and ranges between 0.2% and 0.4% (16). Invasive cervical cancer in pregnancy appears in 0.01%-0.05% of cases. Pregnancy does not enhance progression of cervical dysplasia (8). All inconclusive and suspicious cytologic smears in pregnancy require colposcopy and targeted biopsy. Generally, biopsy can be performed throughout pregnancy, but the most suitable period for it falls between the 16th and 20th week of pregnancy. Endocervical curettage is contraindicated throughout pregnancy. Clinical and colposcopic follow-ups should be repeated each 8 weeks up to 36th week of pregnancy. Histologic re-evaluation should be performed in any suspicion of the progress (17).

If dysplasia is histologically confirmed and cervical cancer excluded, surgical procedure should be delayed until postpartum. Still, due to the high incidence of complications and increased mortality rate in every case with potential malignancy that cannot be excluded by histology (or in overt histologic evidence of microinvasive cancer), it must be individually decided if the intervention can be postponed until delivery.

Cervical intraepithelial neoplasia presents no contraindication for spontaneous vaginal delivery. In patients with cervical cancer in pregnancy, it is advised to terminate pregnancy by cesarean section. Puerperae with CIN diagnosed during pregnancy should be re-evaluated 6-8 weeks after delivery; cytologic smears, colposcopy and repeated biopsy should be performed. Remission of HPV infection after delivery is experienced by 25%-70% of patients (16).

Diagnostics of cervical cancer

In these patients, meticulous social history should be retrieved, and patient independence status, occupation and care should be clarified. It is important to determine duration of the disease and identify contact person or legal guardian of the patient (if present). The patient should be informed in detail about the disease and therapeutic options (surgical procedures, conization). The issues of partnership and sexuality should be discussed in detail. Gynecologic history should provide all the necessary data regarding patient reproduction, menarche, menopause, pregnancies, deliveries, lactation, contraception, conception wishes, and history of regular/irregular vaginal bleeding. Previous morbidities should be discussed with special reference to the history of radiotherapy or/and other concomitant neoplasia. In a previously irradiated patient, effort should be made to retrieve the irradiation plan performed. Patients with previous surgical interventions should be asked when and why was the last abdominal surgical procedure. Thorough insight into the previous operative and histology reports is mandatory. It is

important to determine the status of HPV infection and vaccination. The presence of herpes simplex virus (HSV), human immunodeficiency virus (HIV), chlamydial adnexitis, and condylomas must be determined (18). Detailed history of medication and possible allergies should be obtained as well. Description of patient symptoms should be in the center of our interest, as follows: When pain, bleeding, micturition appeared? For how long does it last? Is there any pattern?

The information regarding previous check-ups should be gathered, as follows: regular PAP smear? When was the last one? HPV-DNA typing? Biopsy/histology? It is of utmost importance to retrieve cytology and histology results from the referring physician (16). Abbreviations of the often used terms are listed in Table Supplement 1.

Table – Supplement 1.
Acronyms and abbreviations

AChRT	adjuvant chemoradiotherapy
ARH	abdominal radical hysterectomy
ART	adjuvant radiotherapy
BRT	brachytherapy
CBC	complete blood count
CCIP	cervical cancer in pregnancy
CCRT	concurrent chemoradiotherapy
ChT	chemotherapy
CIN	cervical intraepithelial neoplasia
CKC	cold knife conization
CRS	conventional radical surgery
CS	cesarean section
CT	computed tomography
DVT	deep venous thrombosis
EBRT	external beam radiotherapy
ESGO	European Society of GynaecologicalOncology
ESMO	European Society of Medical Oncology
ESP	European Society of Pathology
ESTRO	European Society of Radiotherapy and Oncology
EVGF	epithelial vascular growth factor
FIGO	Fédération internationale de gynécologie et d'obstétrique

FSS	fertility sparing surgery
FST	fertility sparing treatment
GIT	gastrointestinal tract
HDR	high-dose rate
HE	hysterectomy
H&E	hematoxylin and eosin
HIV	human immunodeficiency virus
HPV	human papillomavirus
HSV	herpes simplex virus
ICG	indocyanine green
IGABT	image guided adaptive brachytherapy
IGRT	image guided radiotherapy
IMRT	intensity modulated radiotherapy
LACC	locally advanced cervical cancer
LARVH	laparoscopic-assisted radical vaginal hysterectomy
LDR	low-dose rate
LEEP	loop electrosurgical excision procedure
LH	laparoscopic hysterectomy
LLETZ	large loop excision of the transformation zone
LN	lymph node
LN+	positive lymph nodes
LND	lymph node dissection
LVSI	lymphovascular space involvement
MDR	medium-dose rate
MRI	magnetic resonance imaging
NACHT	neoadjuvant chemotherapy
NART	neoadjuvant radiotherapy
OS	overall survival
OT	ovarian transposition
PAP	Papanicolaou smear
PALN	para-aortic lymph node
PALND	para-aortic lymph node dissection
PET	positron emission tomography
PET-CT	positron emission tomography-computed tomography

PLN	pelvic lymph node
PLND	pelvic lymph node dissection
pPROM	preterm spontaneous rupture of membranes
PROM	premature rupture of membranes
RH	radical hysterectomy
RT	radiation therapy
SCC	squamous cell carcinoma
SH	simple hysterectomy
SLN	sentinel lymph node
SLNB	sentinel lymph node biopsy
SLND	sentinel lymph node dissection
Tru-cut (core cut)	capture of high-quality biopsy tissue samples with minimal trauma to the patient

Examination

Examination of a patient with suspicion of cervical cancer should follow these steps (19):

- general health assessment
- laboratory analyses: complete blood count (CBC), liver and renal tests
- gynecologic examination: bimanual, rectovaginal left and right pelvic examination
- axillary, supraclavicular and inguinal lymph node check-up
- differential colposcopy with histologic examination of targeted biopsy samples
- sonography: vaginal (sonomorphology of the cervix) + abdominal (parametria, kidneys)
- radiography: thoracic x-ray or thorax computed tomography (CT) scan with upper thoracic aperture (scalene lymph nodes) for higher *Federation Internationale de Gynecologie et d'Obstetrique* (FIGO) stages
- abdominal magnetic resonance imaging (MRI) or CT scan, pelvic MRI
- if symptoms are present, skeletal scintigraphy and x-ray should be added
- examination in anesthesia
- cystoscopy/rectoscopy (in suspicion of bladder/bowel extension), possibly hysteroscopy with abrasion or biopsy
- in selected cases, positron emission tomography-computed tomography (PET CT) scan (suspicion of locally advanced and spread disease)
- HIV test

A combination of these clinical and radiological results leads to final clinical diagnosis and FIGO stage of cervical cancer (Table 3).

Table 3.
T-classification and FIGO staging (2018)

T category	FIGO stage	Definition
TX	/	Primary tumor cannot be assessed
T0	/	No evidence for primary tumor
T1	I	Cervical carcinoma strictly confined to the uterus (extension to corpus should be disregarded)
T1a	IA	Invasive carcinoma that can be diagnosed only by microscopy, with maximum depth of invasion less than 5.0 mm measured from the base of the epithelium: horizontal spread, vascular space involvement, venous or lymphatic, does not affect classification
T1a1	IA1	Measured stromal invasion <3.0 mm
T1a2	IA2	Measured stromal invasion of more than 3.0 mm and not more than 5.0 mm
T1b	IB	Clinically visible invasive lesion confined to the cervix or microscopic lesion greater than T1a2/IA2. Includes all macroscopically visible lesions, even those with superficial invasion. Lesions limited to the cervix
T1b1	IB1	Invasive carcinoma with 5 mm or more deep stromal invasion, less than 2 cm in greatest dimension
T1b2	IB2	Lesion greater than 2 cm but smaller than 4.0 cm in greatest dimension
T1b3	IB3	Invasive carcinoma bigger than 4 cm in greatest dimension
T2	II	Cervical carcinoma invading beyond the uterus but not to the pelvic wall or to the lower third of the vagina
T2a	IIA	Involvement limited to the upper 2/3 of vagina, without parametrial invasion
T2a1	II A1	Clinically visible lesion of 4.0 cm or less in greatest dimension
T2a2	IIA2	Clinically visible lesion of more than 4.0 cm in greatest dimension
T2b	IIB	Tumor with parametrial invasion, but not up to the pelvic wall
T3	III	Tumor extending to the pelvic sidewall* and/or involving the lower third of the vagina and/or causing hydronephrosis or nonfunctioning kidney, and/or involves PLN or PaLN
T3a	IIIA	Tumor involving the lower third of the vagina but not extending to the pelvic wall
T3b	IIIB	Tumor extending to the pelvic wall and/or causing hydronephrosis or nonfunctional kidney
T3c	IIIC	Involvement of PLN and/or PaLN, irrespective of tumor size and extent
T3c1	IIIC1	PLN metastasis only
T3c2	IIIC2	PaLN metastasis
T4	IV	Tumor outside the true pelvis, or affection of the rectum/bladder mucosa
T4a	IVA	Tumor invading the mucosa of the bladder or rectum and/or extending beyond the true pelvis (bullous edema is not sufficient to classify a tumor as T4)
T4b	IVB	Tumor invading distant organs (including extrapelvic lymph nodes)

*The pelvic sidewall is defined as the muscle, fascia, neurovascular structures and skeletal portions of the bony pelvis

The only exception is FIGO stage IA: pT1a1/1a2 (in which the diagnosis/stage is based on the histopathology report), All patients should be advised on smoking cessation. Young women with reproductive wishes should be referred to reproductive health center to determine the possibilities of fertility sparing treatment (20).

Cervical cancer staging

The diagnosis of cervical cancer and cervical cancer stage is reached by summing the results of clinical and radiological tools, and further corrected by histopathology (additional data are obtained after surgical procedure). Clinical staging is based on the following:

- tumor size
- vaginal/parametrial involvement
- bladder/rectum extension
- presence of distant metastases

The tumor is classified according to FIGO criteria and Union for International Cancer Control TNM classification, 8th edition (21,22).

Relevant diagnostics for FIGO classification:

- bimanual pelvic and bilateral rectovaginal examination under general anesthesia
- endoscopies (colpo-, hystero-, cysto- and rectoscopy)
- thoracic x-ray, IV urography
- biopsy/curettage

Helpful but irrelevant for FIGO classification:

- MRI
- sonography
- lymphangiography
- angiography
- laparoscopy as a staging procedure (can eventually serve for the para-aortic lymph node (PLN) assessment)

Nodal/distant metastatic diagnostic workup:

- In early stage (T1a, T1b1, T2a1), surgical/pathologic staging of PLNs is the criterion standard to assess the prognosis and guide treatment (except for T1a1 and no LVSI).
- In LACC (T1b2 and higher, except for T2a1), or in early-stage disease with suspicious LNs on imaging, PET-CT, or chest/abdomen CT is recommended for assessment of nodal and distant disease.
- PET-CT is the preferred option for treatment planning before chemoradiotherapy with curative intent (20).
- PALN dissection, at least up to inferior mesenteric artery, may be considered in LACC with negative PALNs on imaging for staging purposes.

- Equivocal extrauterine disease is to be considered for biopsy to confirm or rule out metastatic disease and to avoid inappropriate treatment. Tru-Cut (core-cut) biopsy is the option preferred to fine-needle aspiration biopsy because it allows histologic assessment of the tissue (20).

Tumor risk assessment

- Tumor size
- Tumor stage
- Depth of invasion
- LN status
- LVSI
- Histologic subtype of the tumor

Presence or absence of positive LN is the most important prognostic factor. Histologic type is of high importance; adenocarcinomas have worse prognosis than squamous cell carcinomas with 10%-20% (23) worse results on 5-year overall survival, microcellular and neurocrine carcinomas even more. Patients with pathologic risk factors (e.g., positive LNs, tumor-positive surgical margins, depth of invasion, vascular thrombosis, interstitial infiltration depth, higher tumor stage, and tumor differentiation) have a higher frequency of recurrence when compared to patients without these factors (24). At the same time, especially recent studies have found that the size of tumors over 2 cm may also be a poor prognostic factor (25).

Primary therapy

Types of primary therapy:

- primary surgical therapy, possibly in combination with AChT
- staging surgery, possibly with RChT
- primary RChT, possibly followed by ChT
- surgery after NACHT
- surgery to treat symptoms, before palliative therapy, i.e. repair of fistulas

The optimal therapeutic sequence should be chosen. Risk factors should be taken into account in decision process (Table 4).

Table 4.

Risk factors for disease progression (require higher order of radicality in therapeutic approach)

Risk factors
Lymph node status positive
Resection status R1, R2
Parametria positive
Tumor diameter >4 cm
Distant lymphangiosis (satellite LVSI) or hemangiosis
Malignancy grade G3
Up-staging (TNM>FIGO) after the surgery

It should be considered and decided if they define the necessary therapeutic mode (for instance, to decide on RChT). RChT and surgery are proven to be equally effective in the treatment of early stages of cervical carcinoma. However, surgery (up to FIGO II A) is proven as a better solution due to the decreased rate of morbidities (10). Trimodal therapy (surgery with ChT and irradiation, all three together) should be avoided if possible because it does not improve overall survival and exhibits increased toxicity (20).

A) Surgical therapy

The first-line treatment of cervical cancer, if possible, is surgical (9). However, there are several therapeutic strategies in cervical cancer treatment, depending on

the disease stage, histologic characteristics of the tumor, patient preferences and general health condition (26). In surgical approach, the first step is to decide whether there is an indication for surgical procedure. There are several types of surgical procedures, defined by their goals:

- staging surgical procedures
- curative surgery
- fertility-preservation surgery
- palliative surgery (i.e. urine and stool derivation procedures)

Decision should be made on what surgical procedure and which technique to use. Furthermore, the degree of radicality must be defined, e.g., staging lymphadenectomy, SH or RH (Tables 5 and 6).

Table 5.
Operative therapy classification

Querleu/Morrow (Q/M) radical hysterectomy classification					
	Mobilization of ureters	Dissection of lateral parametria	Vagina	Sacruterine ligaments	Vesicouterine ligaments
A Extrascapular HE	Mobilization of ureters	Near the cervix	Minimal resection	Dissection near the cervix	Dissection near the cervix
B Modified radical HE	Partial	Medial from the tunnel of the ureter	>10 mm	Partial resection	Partial resection
C** Classical radical HE	Partial resection	Partial resection	15-20 mm	Dissection near the rectum, after preparation of the plexus of the hypogastric artery	Remove near the bladder, with preservation of neural structures
D Laterally widened dissection	Complete	Resection of the branch of the internal iliac artery, dissection of the root of the ischiadic nerve			
** C 1: surgical procedure with dissected and spared nerves; C2 nerves cannot be dissected and spared					
Classification of lymphadenectomy according to Querleu/Morrow (Q/M) classification					
Level 1	Internal and external iliac arteries				
Level 2	Common iliac artery				
Level 3	Aorta below the upper mesenteric artery				
Level 4	Aorta below the renal vein				

Table 6.
Suggested type(s) of radical hysterectomy according to prognostic factors and risk groups

Risk group	Tumor size	LVSI	Stromal invasion	Type of RH*
Low risk	<2 cm	Negative	Inner 1/3	B1 (A)
Intermediate risk	≥2 cm <2 cm	Negative Positive	Any Any	B2 (C1)
High risk	≥2 cm	Positive	Any	C1(C2)

*According to Querleu-Morrow classification

Preparation for the procedure starts with blood type screen (to order two units of blood). Physical preoperative preparation consists of thromboprophylactic pneumatic stockings and operative field shaving). Perioperative antibiotic prophylaxis should be administered, i.e. cefuroxime + metronidazole. The potential complications of the procedure should be clarified in

detail to the patient, i.e. the need to insert the suprapubic catheter, drainage, infusions, development of lymphedema/thrombosis (embolism), the need for blood transfusions. The risk of infection, effects of the procedure on fertility, difficulties of wound healing, scarring, development of hernias should also be discussed.

A1. Surgical procedures

Prior to surgery, after meticulous consideration of tumor staging, patient general health, wishes and risk factors, proper surgical strategy is chosen. Every surgical procedure starts with exploration of the operative site and reconsideration of the indication for surgical procedure. For cervical cancer treatment, metastatic spread is the key point, so every procedure begins with checking the LN status, as follows:

1. Clinically unsuspecting lymph nodes, SND as the only test has its place in bilateral demarcation with ICG or demarcation with patent blue and radioactive tracer (27)
2. If the SN does not mark and the tumor is smaller than 2 cm, systematic pelvic lymphadenectomy should follow, with *ex tempore* histopathology. The procedure should follow the histopathology results
3. In tumors smaller than 2 cm, the SND is convenient as a single procedure, and it can be optimally offered for tumors up to 4 cm (28)
4. If *ex tempore* histopathology is negative, the procedure should be continued with SH, RH, or radical trachelectomy
5. Perioperative/intraoperative conspicuous LN (PLN/PALN)
6. Targeted extirpation of the tumor with *ex tempore* examination
7. Systemic pelvic LND and *ex tempore* histopathology
8. If *ex tempore* histopathology is positive, PALND without SH, RH, or radical trachelectomy
9. Cancellation of the procedure, or its modification should follow after intraoperative up-standing
10. In case of debulking, LND and clip demarcation of the highest cranially positioned positive LN, not RH I
11. In planned irradiation, ovariopexy (29) with clip marking, or bilateral adnexectomy, depending on menstrual status
12. In cervical adenocarcinoma >4 cm, check the potentially suspicious ovaries (ovarian cancer often has the same histopathology as cervical adenocarcinoma) (16)

Exception

Microcellular cervical carcinoma: NACHT followed by modified radical surgery and lymphadenectomy

A2. Surgical procedure reporting

Documentation

Patient list should contain the type of procedure, special remarks, type of drainage
OP report: preoperative OP site, surgical procedure description, post OP site

Tumor FIGO stage
Tumor histopathology

Minimally invasive procedures

- Intraoperative staging using conventional, robotically assisted laparoscopy
- Combined vaginal operations + laparoscopy (LARVH, laparoscopically assisted radical vaginal hysterectomy)
- TLH

A3. Fertility sparing treatment (FST)

- Before starting FST, consultation at a fertility center is recommended
- Available for selected patients with stages T1a or T1b with tumor ≤ 2 cm in the largest diameter
- The patient should be counselled about the possibility of FST abandonment if there are positive margins or LN involvement, and to be informed regarding oncologic and obstetric risks related to this type of management
- Conization and simple trachelectomy are appropriate fertility sparing procedures for stages T1a1 and T1a2, LN-negative, LVSI-negative patients
- FST should not be recommended for rare histologic subtypes of cervical cancer including neuroendocrine carcinomas, microcellular cancer, adenocarcinomas with minimal deviation (malignant adenoma) and non-HPV-related adenocarcinomas, which tend to exhibit aggressive behavior
- Negative PLN status is a precondition for any FST. Therefore, PLN (SLN) staging should always be the first step in each FST procedure
- Radical trachelectomy (type A) can be considered for stages T1a1 and T1a2, LN-negative, LVSI positive
- Radical trachelectomy (type B) should be performed in patients with cervical cancer stage T1b1 ≤ 2 cm in the largest diameter, LN-negative, LVSI \pm
- Intraoperative placement of permanent cerclage should be performed during simple or radical trachelectomy
- Therapy without fertility preservation in patients with neuroendocrine tumors or in extended surgical procedures (i.e. adnexectomies, para-aortic LN dissections (type Q/M 2-4), partial colpectomy, inguinal/supraclavicular LN dissections, and kidney and bowel derivation surgical procedures)
- Any pregnancy following FST should be considered as a high-risk pregnancy, and delivery should be performed in a perinatal center. Following simple or radical trachelectomy with its inherent

placement of a permanent cerclage, delivery can be performed only by cesarean section

- Routine hysterectomy after finishing fertility plans is not necessary (20)

B) Non-surgical treatment

B1. Primary radiochemotherapy (RChT)

Radiochemotherapy is used in the treatment of LACC for bulky tumors from stages FIGO IB2 to IVA. FIGO III stage is always an indication for primary RChT. In alternation to surgery, it can be used in FIGO IIB-IV A and every N1, and as primary or postoperative treatment for FIGO IB2 and IIA stage patients with risk factors. In patients with stage FIGO IA, FIGO IB1 RChT can be applied if there are contraindications for surgery (10,30,31). After an indication has been established, the next step is to make a plan with irradiation therapist.

Principles of radiotherapy (RT)

EBRT before surgery to reduce tumor volume, NART after surgery to destroy the metastases ART. EBRT, radioactive source out of the body, 80-100 cm away, exposure to 1.6-2 Gy daily/5X weekly, in combination with cisplatin standard RChT/6-7 weeks, ART.

BRT, intracavitary therapy, uterine cavity and vaginal fornices, afterloading LDR (low dose rate) 2 Gy/h; MDR 2-12 Gy/h; HDR >12 Gy/h. The goal is to deliver 80-85 Gy to point A in 6-8 weeks (32). Technical advances in imaging/RT planning have facilitated precision in BRT and enabled dose escalation with reduction of toxicity to the surrounding normal tissue (bladder, rectum, vagina, GIT) (24).

Definitive RChT and brachytherapy (BRT) consist of concomitant pelvic platinum based chemoradiotherapy and brachytherapy or pelvic external beam RT (EBRT) alone and BRT. Overall treatment time for definitive treatment should not exceed 7 to 8 weeks, while it is estimated that every day of extension lowers disease control by 0.5% to 1% (19).

Procedure:

1. if possible, once a week RChT with cisplatin
2. combination of percutaneous (EBRT) and BRT (HDR, afterloading), followed by two cycles of cisplatin/gemcitabine (33)
3. the curative therapeutic approach without BRT is impossible (the necessary cumulative dose on the tumor cannot be reached)

Stereotactic procedures are not adequate substitutes

Total duration of therapy should not exceed 8 weeks

Exceptions:

1. Primary combined irradiation only in selected cases with contraindications to cisplatin application
2. In patients with inability to probe cervical canal (extremely rare), only percutaneous irradiation with adequate boost (final decision is reached on examination after application of 50% of external radiotherapy)

B2. Neoadjuvant chemotherapy (NACHT):

- Reduces the primary tumor size allowing operability
- Eradicates micrometastases
- Increases tumor vascularization and diminishes the number of hypoxic cells
- Followed by radical surgery
- Decreases mortality rate by about 35% (10)
- NACHT + radical surgery proven better than RChT alone (34)
- Reduces the need for ART after radical surgery
- FIGO stage IB2 and II B, if radiotherapy is impossible, in pregnancy wish, or fertility-sparing surgical procedure

Procedure:

1. Perform pelvic MRI, abdominal CT scan/thoracic x-ray with the upper aperture before therapeutic plan
2. In positive LNs on preoperative radiologic staging, laparoscopic staging:
 - LNs negative, NACHT
 - LNs positive, R(Ch)T
3. Clinical control of therapeutic effect before every cycle
4. 2-4 cycles of carboplatin/paclitaxel weekly
5. In limited general health condition alternative TC weekly
6. In progression under NACHT-RChT or irradiation

B3. Adjuvant radiochemotherapy (ARChT) (35,36):

- Presence of one high-risk factor
- Affection of lymph nodes
- Affection of parametria
- *Non in sano* – resection
- Adequate lymphadenectomy has not been performed
- Presence of three or more intermediary risk factors
- Lymphangiosis carcinomatosa
- Hemangiosis carcinomatosa
- Tumor greater than 4 cm in diameter
- Stromal invasion deeper than 2/3
- Presence of one or two risk factors except for G3: individual evaluation (16)

Performance

- If possible as RChT with cisplatin weekly

Exceptions:

- Only radiotherapy in cisplatin contraindications
- Radiation after neoadjuvant therapy
- Special cases

Management of cervical carcinoma – detailed clinical guidelines

Overall management of cervical cancer is graphically presented in Figures 2 and 3.

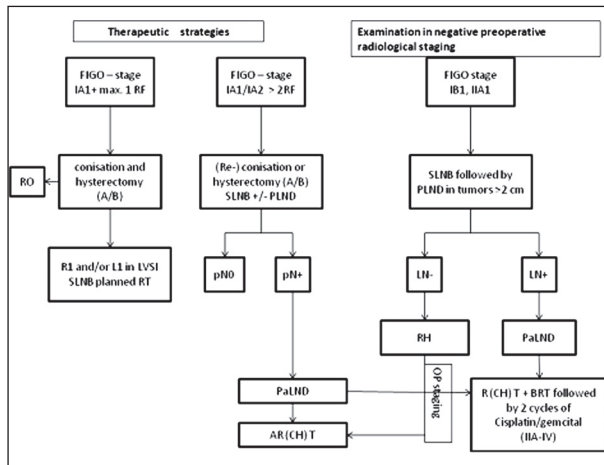


Fig. 2. Treatment algorithm for cervical cancer.

RO – negative surgical margins; R1 – positive surgical margins; L1 – positive LVSI; pN0 – no nodal metastasis in histopathology report; pN+ – nodal metastasis present; A/B – A and B type of RH according to Querleu-Morrow classification

1) Management of stage T1a (T1a1 and T1a2)

Diagnosis of T1a cancer is reached through examination of the specimen obtained by conization by an expert pathologist. The report must contain accurate measures of horizontal spread and depth of invasion, as well as status of surgical margins. Special stress should be put on the reliable status of the lymphovascular space invasion (LVSI), which is the main predictor of local recurrence and growth of distant metastases after surgical treatment for early-stage cervical cancer (37). LVSI is defined as the presence of malignant cells within small lymphatics and small vascular spaces (blood vessels). Metastatic ability of cervical carcinoma is associated with the lymphovascular spread. During invasion of the interstitium, tumor cells exfoliate into the vascular system and form tumor thrombi. The deeper the stromal infiltration, the more LVSI will appear. Tumor thrombi spread to various tissues and organs of the body causing metastatic growth. When tumor differentiation is worse, the rate of cancer malignancy is higher and LVSI is more likely to occur (38).

Conization is the main diagnostic and therapeutic procedure. CKC is preferred by the pathologists due to clear surgical margins, without thermal artifacts. Loop or laser conization is preferable to CKC in women desiring fertility preservation (39). Surgical margins of the cone specimen should be clear of both invasive and preinvasive disease. Intraoperative staining of the cervix with Lugol solution may be helpful (40).

The management of T1a1 stage depends on age, desire for fertility preservation, and LVSI status. In case

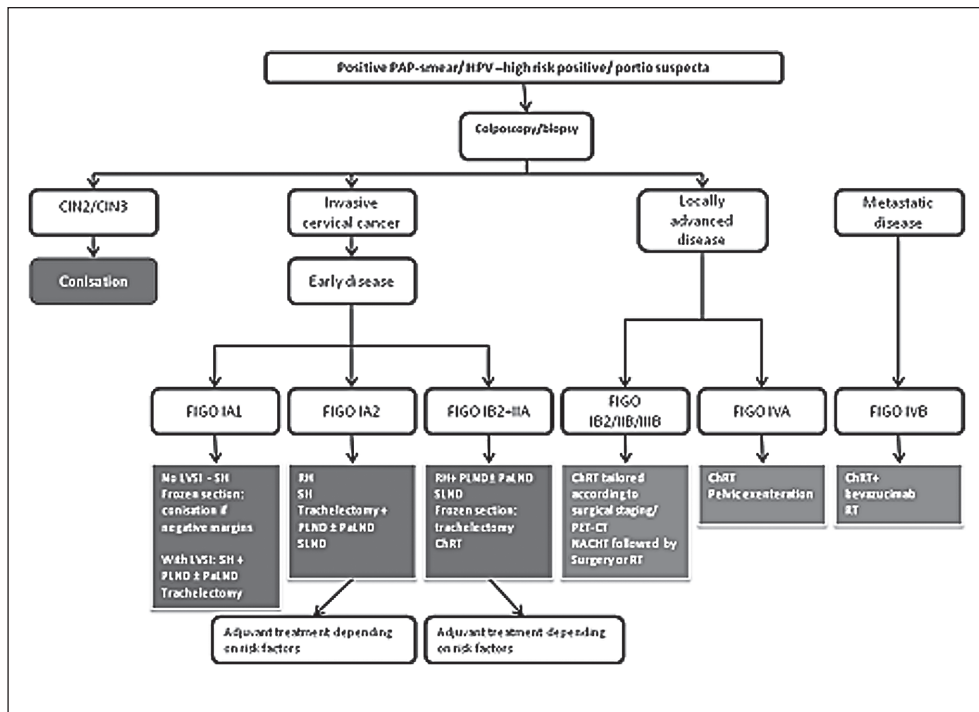


Fig. 3. Treatment algorithm for cervical cancer (modified according to Marth C, Landoni F, Mahner S, McCormack M, Gonzalez-Martin A, Colombo N; ESMO Guidelines Committee. Cervical cancer: ESMO Clinical Practice Guidelines for diagnosis, treatment and follow-up. Ann Oncol. 2017;28(Suppl_4):iv72-iv83. doi: 10.1093/annonc/mdx220. Erratum in: Ann Oncol. 2018 Oct 1;29(Suppl 4):iv262).

of positive margins (except for preinvasive disease in ectocervix), repeat conization should be performed to rule out more extensive invasive disease. In LVSI-negative patients LN staging is not indicated, but it can be considered in T1a1 LVSI positive patients. SLN biopsy (without additional PLN dissection) is an acceptable method of LN staging. There is no need for simple or radical hysterectomy or parametrectomy because they do not improve the outcome, and represent overtreatment for patients with T1a1 disease. The management of stage T1a2 disease is similar, i.e. conization or simple hysterectomy is an appropriate treatment option. There is no need for parametrial resection. LN staging is positioned one step higher than in T1a1 stage; it may be considered in LVSI-negative patients but should always be performed in LVSI-positive patients. SLN biopsy alone (without additional PLN dissection) seems to be an acceptable method of LN staging (20).

2) Management of T1b1/T2a1 stages

Therapeutic strategy mainly depends on radiological staging. Patients with negative lymph nodes on preoperative radiological staging are preferably treated by radical surgery. At this stage, good patient selection is of utmost importance. It is generally recommended to avoid combination of radical surgery and RT because of the highest morbidity after combined treatment. If surgical option is elected, minimally invasive approach is favored. The procedure begins with LN staging in the form of systematic PLND. SN biopsy before pelvic lymphadenectomy is preferable using demarcation with blue dye with radiocolloid or (better) indocyanine green dye (41). Intraoperative LN frozen section assessment should be performed, i.e. bilateral pelvic SNs and all suspicious LNs. If intraoperative LN assessment reveals no positive LNs, the procedure continues with PLND (removal of lymphatic tissue from the regions with the most frequent occurrence of positive LNs including obturator fossa, external iliac regions, common iliac regions bilaterally, and presacral region). Distal external iliac LNs (circumflex iliac LNs) should be spared if they are not macroscopically suspicious (42). Subsequent radicality of surgical procedure is guided by preoperative assessment of the potential risk factors. Tumor size, maximum stromal invasion, and LVSI divide patients into high-, intermediate- and low-risk category of treatment failure. The 2017 modification of the Querleu-Morrow classification presents the extent of parametrial resection recommended for different risk combinations. Ovarian preservation with bilateral salpingectomy should be offered to premenopausal patients with squamous cell carcinoma and HPV-related adenocarcinoma (43) (Table 6). Adjuvant RT should be considered in the presence of a combination of risk factors at final pathology, such as tumor size, LVSI, and depth of stromal invasion. After primary radical sur-

gery, ARChT is indicated in patients with metastatic involvement of PLNs, parametrial involvement, and patients with positive surgical margins (vagina/parametria) in whom BRT boost may be considered (44).

If intraoperative LN assessment reveals positive LNs (including macrometastases or micrometastases), further PLND and radical hysterectomy should be avoided. Patients should be referred for definitive RChT. PALND, at least up to the inferior mesenteric artery, may be considered for staging purposes. If the risk factors are known at diagnosis and mandate adjuvant therapy, surgical treatment may be abandoned and the patient treated solely with RChT and BRT. PLN dissection should be avoided. PALN dissection, at least up to the inferior mesenteric artery, may be considered in patients with negative PALN on imaging. NACHT followed by surgery is not recommended (20). Patients with positive lymph nodes on preoperative radiological staging are preferably treated by definitive RChT. As above, PALN dissection, at least up to the inferior mesenteric artery, may be considered in patients with negative PALN on imaging. Debulking of suspicious PLNs may be considered (20).

3) Management of locally advanced cervical cancer (LACC)

Stage T1b2/T2a2

Generally, patients with negative lymph nodes on radiological staging should be treated with definitive platinum-based RChT and BRT. The main goal is to avoid the combination of radical surgery and postoperative EBRT as this combination does not improve survival and leads to serious morbidity. PALN dissection prior to RT can be considered. PLN dissection is of no value (45). In selected patients with low-risk status, radical surgery (type C2) may be an alternative option. The principle is the same as above, i.e. if intraoperative assessment of LNs reveals no positive LNs, the procedure continues with systematic dissection of PNS and radical hysterectomy, but if it does, surgery is abandoned and treatment switched to platinum-based RChT and BRT. Patients with positive lymph nodes on radiological staging should be treated with definitive platinum-based RChT and BRT. An additional radiation boost to the involved LNs should be applied. PALN dissection, at least up to the inferior mesenteric artery, may be considered before treatment for staging purposes in patients with negative PALN on imaging. Debulking of suspicious PLNs may be considered (20).

Stage T2b, T3a/b, T4a

Therapeutic strategy is the same as for patients with T1b2/T2a2 stage with positive lymph nodes on radio-

logical staging. Pelvic exenteration is an option in selected cases with stage T4 N0 M0 disease (46).

4) Distant metastatic disease at presentation – 4b stage

Patients with widespread distant metastatic disease at presentation (visceral +/- nodal)

- Confirm the histologic stage FIGO IVB, and then
- Primary ChT- cisplatin-paclitaxel or cisplatin-topotecan or platin mono in contraindications to platin-combinations
- Addition of bevacizumab to standard chemotherapy is recommended in patients with good performance status and where the risk of significant gastrointestinal/genitourinary toxicity has been carefully assessed and discussed with the patient; if no contraindication: cisplatin-paclitaxel or topotecan-paclitaxel in combination with bevacizumab (cave! risk of fistulization 8%) (47)

In response to distant metastases (partial remission, complete remission)

- local operative sanitation, or
- local therapy with RChT of the pelvis, or
- local therapy of singular or local distant metastases
- patients with supraclavicular LN as the only site of distant disease can be considered for RChT with curative intent. Treatment algorithm may include additional ChT
- AChT may be considered in cases carrying a high risk of recurrence such as positive margins, positive LN, or LVSI-positive tumors
- oligometastatic disease with only nodal metastasis in PLN, PALN – high dose RT- long term disease control with prolonged progression free interval

If distant metastases **do not respond**

- second line/supportive therapy – individually-adapting palliative therapy
- derivation of the urine/stool (fistulas)
- modified radiation/BRT (bleeding)

5) Local recurrence

Treatment of recurrent disease with curative intent requires referring patients with recurrence for treatment to highly specialized units. Patients with multiple nodal/distant metastases or multifocal local disease with extensive pelvic wall involvement are usually not considered as candidates for curative treatment. The prognostic factors should be carefully evaluated and balanced in relation to major morbidity caused by the

treatment. Patient should be carefully counseled regarding not only treatment options but also the involved risks and consequences. A full diagnostic package consisting of relevant imaging is recommended to establish the status of the disease locally, regionally, and systemically. RChT in curative dosage is the treatment of choice if the patient was not previously irradiated:

- In central pelvic recurrence after primary surgery – definitive RChT combined with image guided adaptive BRT is the treatment of choice
- For BRT, small superficial lesions (<5-mm thickness) in the vagina may be treated using a vaginal cylinder, ovoids, or mold, whereas other lesions usually require combined intracavitary-interstitial techniques
- In pelvic sidewall recurrence, after primary surgery definitive RChT is the preferred option. Definitive RT or RChT followed by stereotactic ablative boost/image guided interstitial BRT/particle beam therapy is an emerging option
- In central pelvic or pelvic sidewall recurrence, after RT or RChT pelvic exenteration is recommended if there is no involvement of the pelvic sidewall and extrapelvic nodes
- Laterally extended endopelvic resection may be considered for a recurrence that extends close to or involves the pelvic sidewall
- Alternatively, in patients unfit for or refusing exenteration surgery reirradiation with image guided adaptive BRT for central recurrences
- In nodal and oligometastatic recurrences (localized para-aortic, mediastinal, and/or periclavicular recurrences above the previously irradiated fields) may be treated by radical EBRT, if possible, in combination with concomitant chemotherapy. It is recommended to electively irradiate the immediate regional nodal stations below and upstream

Indications for surgical procedure in selected cases:

- Presumptions: good general health, patient's wish
- Depends on localization and previous therapies
- After exclusion of distant metastases
- Exenteration procedures or extended resection of the pelvic wall
- Cooperation with radiotherapist to insert the applicator for brachytherapy (20)

When the surgery or irradiation are not the option:

- Complex ChT regimens
- Cisplatin/carboplatin-paclitaxel or topotecan-paclitaxel in combination with bevacizumab
- Addition of bevacizumab prevents tumor angiogenesis (blocks EVGF) but causes rise in hypertension, DVT risk and fistulization (48)

Recurrence out of the pelvis/distant metastases

- If there was no platin therapy, cisplatin, paclitaxel or topotecan-paclitaxel + bevacizumab or cisplatin-topotecan
- After cisplatin therapy, if there are no contraindication: cis- or carboplatin-paclitaxel or topotecan-paclitaxel in combination with bevacizumab
 - monotherapy (topotecan, paclitaxel, vinorelbine, ifosfamide)
 - pembrolizumab

Individual adaptative palliative treatment

- Palliative ChT – classic monotherapy cisplatin 50 mg/m² every 3 weeks/low response rate
 - cisplatin based doublets/cisplatin + topotecan or paclitaxel
 - TIP/paclitaxel-ifosfamide-cisplatin/acceptable toxicity
- urine/stool derivation procedures (fistulas)
- modified irradiation/brachytherapy (bleeding)
- pain therapy

6) Invasive cervical cancer in pregnancy (CCIP)

The main principle: multidisciplinary approach (obstetrics, neonatology, radiotherapy, psycho-oncology, pelvic care nurse). Primary aims of recommended treatment plan are oncologic safety of the pregnant woman, as well as survival without additional morbidity of the fetus. Preferred imaging modalities for clinical staging in patients with CCIP include MRI or expert ultrasound. Because of limited experience and inherent radioactivity, PET-CT (PET-MRI) should be indicated only under very selected circumstances (20).

Tumor involvement of suspicious nodes should be verified histologically because of its prognostic significance and the impact on the management up to 24th week of gestation (fetal viability), preferably by minimally invasive approach. Factors important for decision: gestational age, tumor stage, histopathology, family planning wish of the patient (49). The issue of pregnancy termination does not depend on tumor characteristics, but on patient preferences after thorough counseling. Depending on tumor stage and gestational week, the following treatment options have to be discussed with the patient including risks and benefits of individual approaches:

- Adapted surgery including removal of the tumor: conization, trachelectomy, and LN staging according to the stage of the disease with the intent to preserve pregnancy.
- Radical surgery or definitive RChT as recommended for the stage of the disease without preservation of pregnancy, with or without previous pregnancy termination.

- Delay of oncologic treatment until fetal maturity (if possible >32 weeks of gestation) and beginning of cancer-specific treatment immediately after delivery by cesarean section.
- ChT until fetal maturity and beginning of cancer specific treatment immediately after delivery by cesarean section. Treatment after delivery must consider application of previous ChT. In patients with locally advanced stage or with residual tumor after conization that cannot be completely excised (risk of premature rupture of membranes (PROM) and/or cervical insufficiency), platinum-based chemotherapy can be considered starting at 14 weeks of gestation at the earliest.
- Spontaneous delivery seems to have negative prognostic impact in patients with CCIP. Thus, cesarean section after 32nd week of gestation (if possible) is the recommended mode of delivery. At the time of or following cesarean section, definitive stage-adjusted oncologic therapy has to be performed corresponding to that of nonpregnant women, taking into account therapy that has already been administered during pregnancy (20).

7) Follow-up

- Primary goals of follow-up in patients with cervical cancer are early detection of recurrent disease and patient education and support (50).
- Follow-up intervals of 3 to 4 months for the first 2 years and then 6 to 12 months for up to 5 years are recommended.
- At each visit, patient general condition, appearance of new symptoms or late treatment side effects should be evaluated, together with physical examination. Patient should be educated or referred to appropriate expert for counseling and treatment.
- Imaging and laboratory tests should be performed based on symptoms or findings suggestive of recurrence or morbidity. In symptomatic women, MRI or CT should be considered to assess the potential clinical recurrence; PET-CT can be added if necessary. Pathologic confirmation of any persistent or recurrent tumor should be considered.
- Following FST, all women remain at risk of tumor recurrence and must be carefully followed up. Follow-up should include HPV testing (with or without cytology). Colposcopy in combination with HPV testing in parallel performed by an experienced colposcopist is an option. The incorporation of high-risk HPV testing at 6, 12, and 24 months after treatment is advocated. If HPV testing is negative, then every 3 to 5 years as long as the follow-up is indicated.

- Follow-up after definitive RChT should use the same imaging method for evaluation of tumor response as was used at baseline. Imaging should be performed not earlier than 3 months following completion of treatment. In dubious cases, re-evaluation should be performed not before 8 weeks thereafter. For re-evaluation purposes, the optimal diagnostic workup for local extent is pelvic MRI, and for distant spread, it is chest/abdomen CT or PET-CT. Cytology is not recommended in these patients.
- Providers should inform and educate patients about sexual and vaginal health because vaginal stenosis and dryness may occur. Vaginal dilation should be offered, as well as vaginal lubricants and local estrogen (20,51).

CONCLUSION

Cervical cancer presents today as a preventable and easily detectable disease in the societies which encourage vaccination and public early-stage screening programs. However, when diagnosed, the disease mandates expert treatment and follow-up according to updated clinical guidelines. The best results are achieved in specialized departments where patients are managed by multidisciplinary teams in close cooperation of different specialties.

REFERENCES

1. Dedić Pavetić N, Silovski T *et al.* Smjernice za provođenje dijagnostičkih pretraga prije početka liječenja onkološkog bolesnika – kliničke preporuke Hrvatskog društva za internističku onkologiju HLZ-a; II. dio: Rak dojke, ginekološki tumori (rak jajnika, rak tijela maternice, rak vrata maternice), rak pluća, maligni melanom, sarkomi, tumori središnjega živčanog sustava, rak glave i vrata. Lijec Vjesn 2018; 140: 92-105. (in Croatian)
2. World Health Organization. Human Papillomavirus Vaccines: WHO Position Paper, 2017. Wkly Epidemiol Rec 2017; 92: 241-68.
3. https://www.bvf.de/fileadmin/Bilder_PDF_BVF/pdf/wichtige_dokumente/richtlinien_des_G-BA/2018-11-22_oKFE-RL_Zervixkarzinom_TrG.pdf
4. World Health Organization. Cervical Cancer: Estimated Incidence, Mortality and Prevalence Worldwide in 2012. Lyon: International Agency for Research on Cancer, 2012.
5. Small Jr W, Bacon MA, Bajaj A *et al.* Cervical cancer: a global health crisis. Cancer 2017; 123: 2404-12.
6. Kjaer SK, Frederiksen K, Munk C, Iftner T. Long-term absolute risk of cervical intraepithelial neoplasia grade 3 or worse following human papillomavirus infection: role of persistence. J Natl Cancer Inst 2010; 102: 1478-88.
7. Arbyn M, Dillner J. Review of current knowledge on HPV vaccination: an appendix to the European Guidelines for Quality Assurance in Cervical Cancer Screening. J Clin Virol 2007; 38: 189-97.
8. Vujić G, Ćorušić A. Zloćudni tumori vrata maternice. Medix 2004; 10(5): 110-5. (in Croatian)
9. HDGO. HDGO postupnik – Cervikalne intraepitelne lezije. S3 smjernice za dijagnostiku i liječenje. Zagreb: Algoritmi, 2012. (in Croatian)
10. Marth C, Landoni F, Mahner S, McCormack M, Gonzalez-Martin A, Colombo N; ESMO Guidelines Committee. Cervical cancer: ESMO Clinical Practice Guidelines for diagnosis, treatment and follow-up. Ann Oncol 2017; 28(Suppl_4): iv72-iv83. doi: 10.1093/annonc/mdx220. Erratum in: Ann Oncol 2018 Oct 1; 29(Suppl 4): iv262.
11. Bentivegna E, Gouy S, Maulard A, Chargari C, Lery A, Morice P. Oncological outcomes after fertility-sparing surgery for cervical cancer: a systematic review. Lancet Oncol 2016; 17: e240-53.
12. Ault KA. Effect of prophylactic human papillomavirus L1 virus-like particle vaccine on risk of cervical intraepithelial neoplasia grade 2, grade 3, and adenocarcinoma in situ: a combined analysis of four randomised clinical trials. Lancet 2007; 369: 1861-8.
13. Rodriguez AC, Schiffman M, Herrero R *et al.* Longitudinal study of human papillomavirus persistence and cervical intraepithelial neoplasia grade 2/3: critical role of duration of infection. J Natl Cancer Inst 2010; 102: 315-24.
14. Markowitz LE, Liu G, Hariri S, Steinau M, Dunne EF, Unger ER. Prevalence of HPV after introduction of the vaccination program in the United States. Pediatrics 2016; 137: e20151968.
15. Petrosky E, Bocchini JA Jr, Hairi S, Chesson H, Curtis CR, Saraiya M, Unger ER, Markowitz LE, Centers for Disease Control and Prevention (CDC). Use of 9-valent human papillomavirus (HPV) vaccine: updated HPV vaccination recommendations of the Advisory Committee on Immunization Practices. MMWR Morb Mortal Wkly Rep 2015; 64: 300-4.
16. https://www.bvf.de/fileadmin/Bilder_PDF_BVF/pdf/wichtige_dokumente/richtlinien_des_G-BA/Praxisinfo_Fr_herkennung_Geb_rmutterhalskrebs.pdf
17. <https://www.g-ba.de/beschluesse/3597/> Beschluss des Gemeinsamen Bundes-ausschusses über eine Änderung des Krebs-früherkennungs-Richtlinie für organisierte Krebs-früherkennungsprogramme: Programm zur Früherkennung von Zervixkarzinomen.
18. <https://www.awmf.org/leitlinien/detail/ll/032-033OL.html>
19. Vrdoljak E, Haller H, Ćorušić A *et al.* Kliničke upute za dijagnostiku, liječenje i praćenje bolesnica oboljelih od raka vrata maternice Hrvatskoga onkološkog društva i Hrvatskoga društva za ginekologiju i opstetriciju Hrvatskoga liječničkog zbora, te Hrvatskoga ginekoonkološkog društva. Lijec Vjesn 2013; 135: 225-9. (in Croatian)
20. Cibula D, Pötter R, Planchamp F *et al.* The European Society of Gynaecological Oncology/European Society for Ra-

diotherapy and Oncology/European Society of Pathology Guidelines for the Management of Patients with Cervical Cancer. *Int J Gynecol Cancer* 2108; 28(4): 641-55.

21. National Comprehensive Cancer Network® (NCCN®). NCCN Guidelines for Treatment of Cervical Cancer, 2019.

22. Bhatla N, Berek JS, Cuello Fredes M *et al.* Revised FIGO staging for carcinoma of the cervix uteri. *Int J Gynaecol Obstet* 2019; 145: 129-35.

23. Sala E, Micco M, Burger IA *et al.* Complementary prognostic value of pelvic magnetic resonance imaging and whole-body fluorodeoxyglucose positron emission tomography/computed tomography in the pretreatment assessment of patients with cervical cancer. *Int J Gynecol Cancer* 2015; 25: 1461-7.

24. Cibula D, Pötter R, Planchamp F *et al.* The European Society of Gynaecological Oncology/European Society for Radiotherapy and Oncology/European Society of Pathology Guidelines for the Management of Patients with Cervical Cancer. *Virchows Arch* 2018; 472: 919-36.

25. Kato T, Takashima A, Kasamatsu T *et al.* Clinical tumor diameter and prognosis of patients with FIGO stage IB1 cervical cancer (JCOG0806-A). *Gynecol Oncol* 2015; 137: 34-9.

26. Monk BJ, Tewari KS, Koh W-J. Multimodality therapy for locally advanced cervical carcinoma: state of the art and future directions. *J Clin Oncol* 2007; 25: 2952-65.

27. Diab Y. Sentinel lymph nodes mapping in cervical cancer – a comprehensive review. *Int J Gynecol Cancer* 2017; 27: 154-8.

28. Bats AS, Mathevet P, Buenerd A *et al.* The sentinel node technique detects unexpected drainage pathways and allows nodal ultrastaging in early cervical cancer: insights from the multicenter prospective SENTICOL study. *Ann Surg Oncol* 2013; 20: 413-22.

29. Pahisa J, Martinez-Roman S, Martinez-Zamora MA *et al.* Laparoscopic ovarian transposition in patients with early cervical cancer. *Int J Gynecol Cancer* 2008; 18: 584-9.

30. Im JH, Yoon HI, Kim S *et al.* Tailored radiotherapeutic strategies for disseminated uterine cervical cancer patients. *Radiat Oncol* 2015; 10: 77.

31. Forrest JL, Ackerman I, Barbera L *et al.* Patient outcome study of concurrent chemoradiation, external beam radiotherapy, and high-dose rate brachytherapy in locally advanced carcinoma of the cervix. *Int J Gynecol Cancer* 2010; 20: 1074-8.

32. Sturdza A, Pötter R, Fokdal LU *et al.* Image guided brachytherapy in locally advanced cervical cancer: improved pelvic control and survival in RetroEMBRACE, a multicenter cohort study. *Radiother Oncol* 2016; 120: 428-33.

33. Cetina L, Gonzalez-Enciso A, Cantu D *et al.* Brachytherapy versus radical hysterectomy after external beam chemoradiation with gemcitabine plus cisplatin: a randomized, phase III study in IB2-IIB cervical cancer patients. *Ann Oncol* 2013; 24: 2043-7.

34. https://ascopubs.org/doi/10.1200/JCO.2019.37.15_suppl.5503. European Organisation for Research and Treatment of Cancer – EORTC. Chemotherapy followed by surgery vs radiotherapy plus chemotherapy in patients with stage Ib or II cervical cancer. EORTC Protocol 55994.

35. Kokka F, Bryant A, Brockbank E *et al.* Hysterectomy with radiotherapy or chemotherapy or both for women with locally advanced cervical cancer. *Cochrane Database Syst Rev* 2015; 4: CD010260.

36. Trifiletti DM, Swisher-McClure S, Showalter TN *et al.* Postoperative chemoradiation therapy in high-risk cervical cancer: re-evaluating the findings of Gynecologic Oncology Group Study 109 in a large, population-based cohort. *Int J Radiat Oncol Biol Phys* 2015; 93: 1032-44.

37. Chernofsky MR, Felix JC, Muderspach LI *et al.* Influence of quantity of lymph vascular space invasion on time to recurrence in women with early-stage squamous cancer of the cervix. *Gynecol Oncol* 2006; 100: 288-93.

38. Morice P, Piovesan P, Rey A *et al.* Prognostic value of lymphovascular space invasion determined with hematoxylin-eosin staining in early stage cervical carcinoma: results of a multivariate analysis. *Ann Oncol* 2003; 14: 1511-7.

39. Greenspan DL, Faubion M, Coonrod DV *et al.* Compliance after loop electrosurgical excision procedure or cold knife cone biopsy. *Obstet Gynecol* 2007; 110: 675-80.

40. Miroshnichenko GG, Parva M, Holtz DO *et al.* Interpretability of excisional biopsies of the cervix: cone biopsy and loop excision. *J Low Genit Tract Dis* 2009; 13: 10-2.

41. Kadkhodayan S, Hasanzadeh M, Treglia G *et al.* Sentinel node biopsy for lymph nodal staging of uterine cervix cancer: a systematic review and meta-analysis of the pertinent literature. *Eur J Surg Oncol* 2015; 41: 1-20.

42. Ramirez PT, Pareja R, Rendon GJ *et al.* Management of low-risk early-stage cervical cancer: should conization, simple trachelectomy, or simple hysterectomy replace radical surgery as the new standard of care? *Gynecol Oncol* 2014; 132: 254-9.

43. Querleu D, Morrow CP. Classification of radical hysterectomy. *Lancet Oncol* 2008; 9: 297-303.

44. Gouy S, Morice P, Narducci F *et al.* Prospective multicenter study evaluating the survival of patients with locally advanced cervical cancer undergoing laparoscopic para-aortic lymphadenectomy before chemoradiotherapy in the era of positron emission tomography imaging. *J Clin Oncol* 2013; 31: 3026-33.

45. Frumovitz M, Querleu D, Gil-Moreno A *et al.* Lymphadenectomy in locally advanced cervical cancer study (LiLACS): phase III clinical trial comparing surgical with radiologic staging in patients with stages IB2-IVA cervical cancer. *J Minim Invasive Gynecol* 2014; 21: 3-8.

46. Graves S, Seagle BL, Strohl AE *et al.* Survival after pelvic exenteration for cervical cancer: a national cancer database study. *Int J Gynecol Cancer* 2017; 27: 390-5.

47. Rosen VM, Guerra I, McCormack M *et al.* Systematic review and network meta-analysis of bevacizumab plus first-line topotecan-paclitaxel or cisplatin-paclitaxel versus non-bevacizumab-containing therapies in persistent, recurrent, or metastatic cervical cancer. *Int J Gynecol Cancer* 2017; 27: 1237-46.

48. Tewari KS, Sill MW, Penson RT *et al.* Bevacizumab for advanced cervical cancer: final overall survival and adverse event analysis of a randomised, controlled, open-label, phase

3 trial (Gynecologic Oncology Group 240). *Lancet* 2017; 390: 1654-63.

49. Fukushima K, Ogawa S, Tsukimori K *et al.* Can we diagnose invasive cervical cancer during pregnancy as precise as in nonpregnant women? Maternal and perinatal outcome in pregnancies complicated with cervical cancers. *Int J Gynecol Cancer* 2009; 19: 1439-45.

50. Salani R, Khanna N, Frimer M *et al.* An update on post-treatment surveillance and diagnosis of recurrence in women with gynecologic malignancies: Society of Gynecologic Oncology (SGO) recommendations. *Gynecol Oncol* 2017; 146: 3-10.

51. Elit L, Reade CJ. Recommendations for follow-up care for gynecologic cancer survivors. *Obstet Gynecol* 2015; 126: 1207-14.

S A Ž E T A K

DIJAGNOSTIKA I LIJEČENJE RAKA VRATA MATERNICE

Z. HRGOVIĆ¹, R. FUREŠ²⁻⁴, Ž. STANIĆ²⁻⁴

¹Sveučilište J.W. Goethea, Klinika za ženske bolesti i porođaje, Frankfurt na Majni, Njemačka; ²Sveučilište Josipa Jurja Strossmayera u Osijeku, Fakultet dentalne medicine i zdravstva, Osijek, Hrvatska; ³Sveučilište Josipa Jurja Strossmayera u Osijeku, Fakultet dentalne medicine i zdravstva, Institut za integrativnu ginekologiju, opstetriciju i minimalno invazivnu ginekološku kirurgiju, Osijek, Hrvatska; ⁴Opća bolnica Zabok i Bolnica hrvatskih veterana, Odjel ginekologije i porodništva, Zabok, Hrvatska

Rak vrata maternice drugi je najčešći oblik raka među ženama iz nerazvijenih zemalja. Diljem svijeta od njega svake godine oboli oko pola milijuna, a od njega umre četvrt milijuna žena. Hrvatska se prema epidemiološkim parametrima povezanima s rakom cerviksa nalazi u sredini europske ljestvice, što je u skladu sa slojevitom strukturom hrvatskog društva. Važan parametar je slab odaziv žena u Hrvatskoj na nacionalne preventivne programe i mjere ranog otkrivanja ovog raka. Iako tradicionalni preventivni programi u Hrvatskoj u pravilu nude dobar temelj za otkrivanje i liječenje preinvazivnih i ranih stadija raka vrata maternice, potrebno ih je osuvremenjivati i dopunjavati novim saznanjima u skladu s aktualnim svjetskim smjernicama. Poseban je zadatak iznalaženje odgovarajućih mjera za motivaciju žena na korištenje nacionalnih preventivnih mjera i rane dijagnostike, što bi trebalo intenzivno promovirati u svim segmentima društvenog života. Cilj ovog pregleda je usporedba domaćih i aktualnih inozemnih smjernica za dijagnostiku i liječenje raka vrata maternice te prezentacija homogeniziranog stava i prijedloga modernog pristupa liječenju ove bolesti.

Ključne riječi: rak vrata maternice, smjernice, cerviks, kirurgija, kemoterapija, radioterapija