

## BREAST SURGERY

OPEN

Management of Gynecomastia in Patients  
With Different Body Types*Considerations on 312 Consecutive Treated Cases**Alessandro Innocenti, MD,\* Dario Melita, MD,\* Francesco Mori, MD,\*  
Francesco Ciancio, MD,† and Marco Innocenti, MD\**

**Background:** Gynecomastia is a common finding in male subjects which incidence varies widely in the world population. In adolescents, it is frequently temporary but, if it becomes persistent, it generates considerable embarrassment, inducing the patients to seek surgical consultation. Even in patients with good body contour, gynecomastia creates even greater distress considering the special attention given by these subjects to their physical appearance. The authors present their experience in the treatment of gynecomastia comparing different body types of patients with the aim to investigate dissimilar expectations, needs and surgical outcomes thus optimizing the management of the pathological condition, achieving high levels of agreement and reducing unsatisfied patients arising from cosmetic surgery.

**Materials and Methods:** Between January 2007 and January 2015, 312 selected patients have been treated surgically for gynecomastia. Patients were grouped according to their physical aspect: 97 were classified as high muscle mass body type (group A), 106 as normal (group B) and 109 as overweight patients (group C). All of them were adults ranging in age between 18 and 52 years. Follow-up ranged from 12 to 60 months. In all cases, an excision of the gland in the form of a subcutaneous mastectomy was performed; the most common surgical access was in the inferior part of the areola.

**Results:** No breast cancers were found at the histological examinations. Also, no skin or areola necrosis have been referred, and no recurrence of gynecomastia disorder has been reported. Six cases of seroma (limited to the fatty gynecomastia) and 3 cases of hematomas (requiring immediate surgical revision) were found. Although the patients in group B resulted more distressed by the disorder, higher levels of postoperative satisfaction were recorded in this group.

**Conclusions:** The study demonstrates the importance of the different management of the same disorder according to the different patients' expectations, related to the different body type. Our experience demonstrated that most of the cases did not require extensive skin incisions, reducing the risk of unpleasant scars and that direct excision of glandular tissue ensures stable and satisfactory results.

**Key Words:** gynecomastia, male breast, patients satisfaction outcome study, subcutaneous mastectomy

(*Ann Plast Surg* 2017;78: 492–496)

Gynecomastia is a benign enlargement of the mammary region<sup>1,2</sup> which may affect men with different body types: muscular subjects,<sup>3</sup> normal physiques or overweight patients. Its incidence ranges widely

in the world population ranging from 32% up to 65%.<sup>9</sup> In male subjects, the gland can be schematically represented by three different parts: the head, located in the medial expansion, the body, immediately deep to the nipple-areola complex and the tail usually represented by a long and narrow extension toward the axilla. The causes are often idiopathic although sometimes gynecomastia may be secondary to various metabolic or endocrine disorders (such as alcoholic cirrhosis, hypogonadism, adrenal cortical hyperplasia, hypothyroidism), acquired or congenital hypogonadal states (Klinefelter syndrome), drug-induced by estrogen-increasing medications or anabolic steroids. In adolescents, it is frequently a temporary finding but, if it becomes permanent, it often requires treatment. Histologically, 3 different patterns were identified: florid (showing high numbers of budding ducts), fibrous (minimal ductal proliferation), and intermediate (overlapping of both previous patterns).<sup>4</sup> Clinically, 3 different forms have been described: the glandular called true, the fatty named false and the composite in which both components are present. Considering the degree of lipodystrophy and skin excess, Rohrich et al<sup>5</sup> in 2003 proposed a new classification identifying four different subtypes: *grade I*, with minimal hypertrophy without ptosis (<250 g of breast tissue); *grade II*, with moderate hypertrophy without ptosis (250–500 g of breast tissue); *grade III*, with severe hypertrophy and moderate ptosis (>500 g of breast tissue); and *grade IV*, with severe hypertrophy and severe ptosis (>500 g of breast tissue). Even when affected by minor forms, patients are very upset with the disorder and required treatment for aesthetic purposes with different expectations according to the lifestyle and their personal perception of the disorder. Even if medical therapy may be administered, surgical treatment is often necessary. Several surgical techniques have been described in literature, including ultrasound-assisted liposuction technique.<sup>5</sup> Given the growing demand for gynecomastia correction coming from patients with different body types and adhering to the strengthening reporting observational studies statement, a large retrospective study of our experience with gynecomastia is presented with the aim to investigate the dissimilar expectations, needs, surgical outcomes, complications and surgical strategies thus to perform the most appropriate surgical planning according to the different body types.

## MATERIALS AND METHODS

In the authors' practice, between January 2007 and January 2015, 312 consecutive patients have been treated surgically for gynecomastia. Eligibility criteria were identified in: adult age, breast hypertrophy, ultrasound investigation, no history of hormonal disorders or testicular dysfunction and no use of anabolic steroids hormones or drugs. Assessing the physical aspect of the body, 3 different groups of patients have been identified (Fig. 1):

- group A: subjects with athletic physique, BMI < 25, with high muscle mass and body fat < 9% (Fig. 2);
- group B: subjects with normal physique, not particularly muscular, BMI < 25 (Fig. 3);
- group C: overweight subjects with BMI > 25 (Fig. 4).

Received August 8, 2016, and accepted for publication, after revision September 21, 2016. From the \*Plastic and Reconstructive Microsurgery, Careggi Universital Hospital, Florence; and †Department of Plastic and Reconstructive Surgery, University of Bari, Foggia, Italy.

Conflicts of interest and sources of funding: none declared.

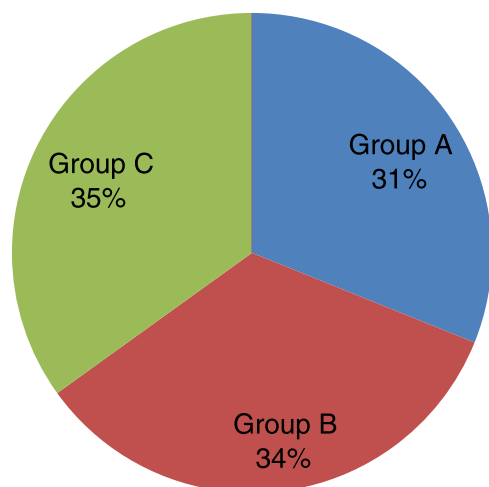
Reprints: Alessandro Innocenti, MD, Viale Giacomo Matteotti 42-50132, Firenze, Italy. E-mail: [innocentialessandro@alice.it](mailto:innocentialessandro@alice.it).

Copyright © 2017 The Author(s). Published by Wolters Kluwer Health, Inc. This is an open-access article distributed under the terms of the Creative Commons Attribution-Non Commercial-No Derivatives License 4.0 (CCBY-NC-ND), where it is permissible to download and share the work provided it is properly cited. The work cannot be changed in any way or used commercially without permission from the journal.

ISSN: 0148-7043/17/7805-0492

DOI: 10.1097/SAP.0000000000000940

## Groups of patients



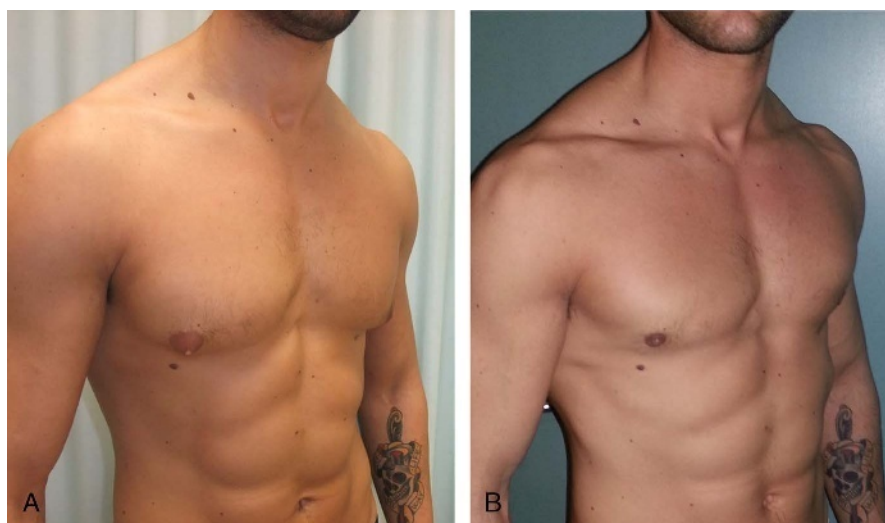**FIGURE 1.** Subdivision of 312 patients surgically treated for gynecomastia in 3 groups according to their body types.

Personal data were collected and preoperative and 12 months postoperative photographs were taken using digital support. Patients were followed up for a minimum of 12 months and up to 5 years clinically and through an ultrasound examination (Fig. 5).

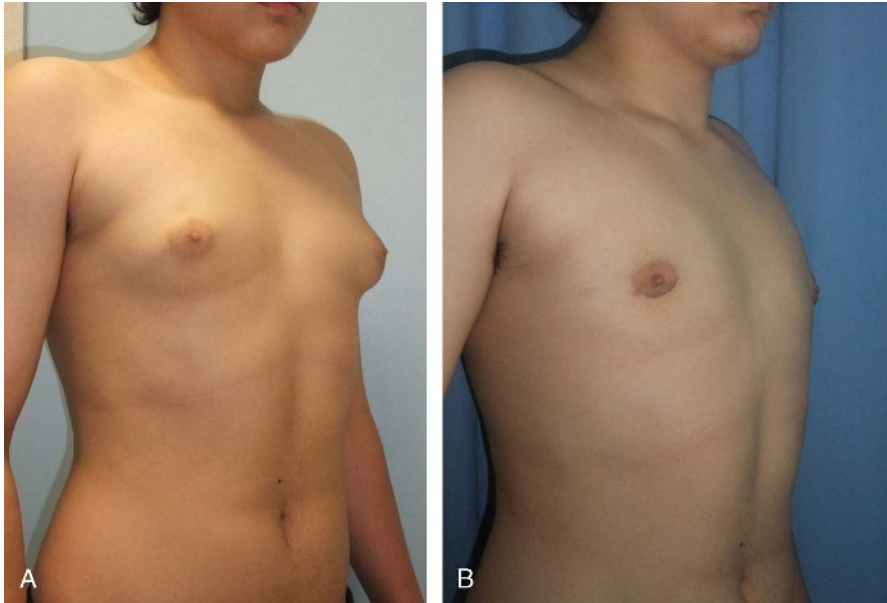
### Surgical Technique

Three hundred nine surgical procedures were performed under local anesthesia. Tumescence solution consisting of: 10 mL of lidocaine 2%, 20 mL carbocaine 2%, 10 mL naropine 10%, 1 mg adrenaline, 100 mL of saline solution. Three cases underwent general anesthesia because of psychological and intellectual disorders. In all cases, an excision of the gland was performed using a periareolar approach.

The surgical procedure consisted of a skin incision located in the inferior part of the areola,<sup>6</sup> ranging from 2 up to 4 cm in length; otherwise, the areola was incised to the entire circumference when a skin reduction or a correction of ptosis had to be performed.<sup>7</sup> Under direct vision, using a scissor, an adipocutaneous flap was harvested as thin as possible but a layer of fat beneath the dermis, about a couple of mm at least, was strictly maintained thus to avoid direct adhesion between muscular fascia and dermis. Thicker flaps were performed in normal and overweight patients to get a more suitable contouring according to the patients' chest profile. When a wide adipocutaneous flap was completely dissected the regularity of its thickness was checked, also comparing the 2 sides. Starting from 3 or 4 mm above, the inferior border of the pectoralis muscle, a full thickness incision was performed through the gland until the pectoralis fascia was found. Deeply, the gland dissection has been maintained strictly above the fascia. Once the parenchyma was completely free, both superficially and deeply, a back cut was performed starting from 6 to 12 o'clock counterclockwise first and successively clockwise to release the border along which it was still attached. To allow a satisfactory visibility through the periareolar access, the gland was maintained inside the skin envelope during the procedure until it was completely released. Only when completely free, it was pulled out. Complete en bloc excisions of glandular tissue were performed in all cases. When necessary, liposuctions of the peripheral fatty tissue were usually performed using the contralateral periareolar incision.<sup>3</sup> However, the cannula, even without suction, was used to undermine a larger flap to obtain a better contouring of the skin to the chest profile. Wider flaps have been distributed and fixed by quilting stitches to the deep fascia to get a better recontouring of the redundant skin. In 87 of the cases, a drain was placed through the axilla for 12 to 24 hours. In the remaining cases, no drainage was used. At the end of the procedure, an elastic compressive jersey was applied for 3 to 5 days.<sup>8</sup> Minimal activity was suggested for the first week. 12 months postoperative patients were asked to respond to a satisfaction ratings questionnaire suggested in 2009 by Ridha et al.<sup>9</sup> It also included the evaluation of the degree of the patients' own perception of the gynecomastia and limitations, if any, to their lifestyle caused by the disorder. Patients' satisfaction, chest profile, numbness, symmetry, nipple/areola contouring, and scarring value were assessed



**FIGURE 2.** A 22-year-old man with high definition muscle body type: (A) preoperative lateral view showing wide areola, (B) postoperative lateral view showing a better definition of pectoralis area with a significant decreasing of areola diameter.



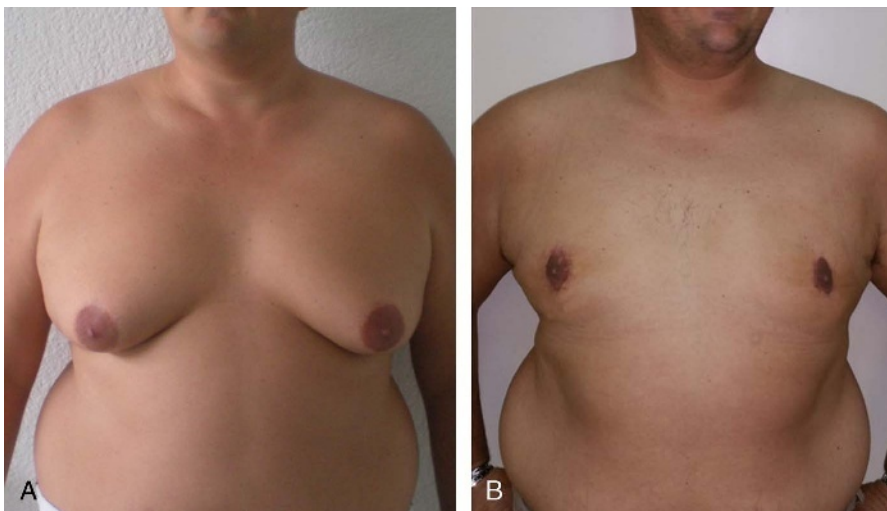
**FIGURE 3.** An 18-year-old man with normal body type: (A) preoperative lateral view showing an evident female appearance of the pectoralis region; (B) postoperative lateral view showing a significant disappearance of female aspect.

using a 5-point Likert scale (1, very dissatisfied; 2, dissatisfied; 3, neither; 4, satisfied; 5, very satisfied).

### RESULTS

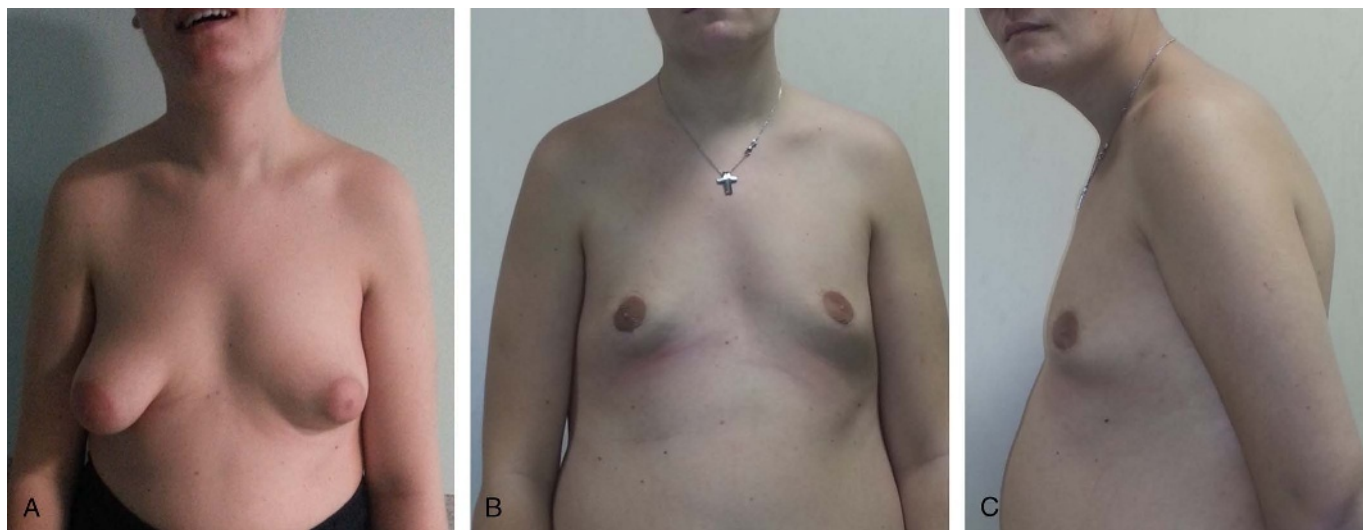Ninety-seven patients belonged to group A, 106 to group B, and 109 to group C. Routine laboratory tests did not demonstrate any hematocrit or hemoglobin anomalies, even renal, thyroid, and liver functionality were in range. Ages ranged between 18 and 52 years. Average follow-up period was 32 months ranging from 12 up to 60 months. Operative time ranged from 25 minutes up to 120 minutes. Hospitalization time ranged from 1 to 3 days. Two hundred forty-one surgical accesses were located in the inferior part of the areola, a

circumareolar approach was performed in 53 cases, whereas vertical incision, as in standard vertical reduction mammoplasty, was reserved to 18 cases of overweight patients in which the amount of breast tissue was greater than 240 g and inelastic sagging skin was present. Excised glandular tissue weight ranged from 45 to 385 g per side. No breast cancer was found at the histological examinations. Three high muscle mass patients (2.91%) had a pathological report of atypical intraductal hyperplasia. Recurrences of the disorders have not been observed at all. We found 6 seroma (1.9%) limited to overweight patients in whom large amounts of fat were removed. Seromas lasted from minimum 10 up to a maximum of 25 days and have required a weekly percutaneous drainage. Three hematomas (0.9%) requiring immediate revision of the surgical theater were reported. Severe bleeding (0.32%), in a



**FIGURE 4.** A 45-year-old man with overweight body type presented a severe gynecomastia since his early teenage years. His gynecomastia became more pronounced at age of 16. Good quality of skin texture was observed. A, Preoperative frontal view showing significant female ptotic breasts with wide areola. B, Postoperative frontal view showing a satisfactory resolution of the gynecomastia disorder obtained through a full-circle areola approach with a significant decreasing of areola diameter.





**FIGURE 5.** A 21-year-old man presented a severe gynecomastia related to Klinefelter Syndrome. A, preoperative frontal view; (B) postoperative frontal (C) and lateral view showing a satisfactory result.

hemophilic patient, was promptly resolved by our hemophilic center. Other 5 hemophilic patients were operated by the authors without any problems.

Depressions, deforming the contour profile of the mammary region, were visible postoperatively during muscular contraction in 18 patients (18.5%) belonging to group A. Seven (6.06%) similar irregularities were observed also in group B, and these were always visible even without muscular contraction. Although in overweight patients, depressions have not been observed, in 22 patients, a crescent ptotic tissue at the lower border of the pectoralis muscle was present at the follow-up. Only 3 of these cases required further correction through a secondary periareolar approach, whereas the other excluded wider scars. The main reason for undergoing surgery resulted: in group A, lack of self confidence because of unsatisfactory contouring of the pectoralis area (93.81%); in group B, emotional distress due to feminine appearance (92.45%); and in group C, weight disorder (83,48%). Results are shown in Figure 6.

The mean Likert score for patients' satisfaction of chest appearance ranged preoperatively between 0.6 and 2.2, with lower

satisfaction in group B. Postoperatively, it ranged between 3.7 and 4.6. The higher increase of postoperative satisfaction score was recorded in group B (Fig. 7).

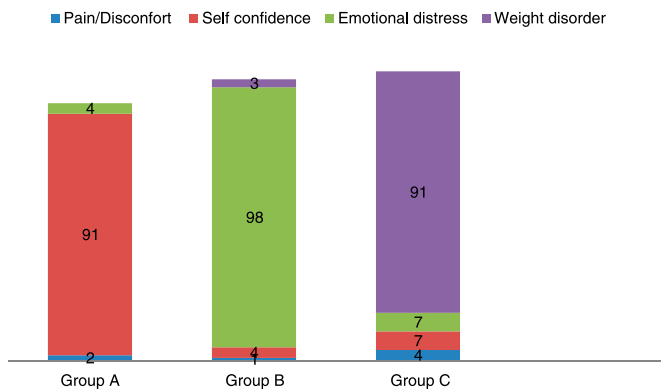### DISCUSSION

Patients' satisfaction is the key determinant of success of any cosmetic procedure. Because the commonest reason for claims arising from cosmetic surgery is dissatisfaction with the final aesthetic result, the management of patients' expectations is important in order to achieve a high level of satisfaction. Therefore, studies are important to understand patients' preoperative expectations, ensuring that these expectations are realistic, and a correct evaluation of postoperative surgical outcomes.

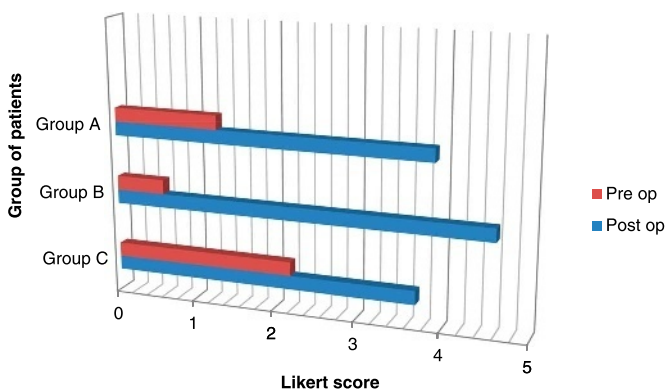
The present study has demonstrated that all the patients declared they were very distressed by gynecomastia especially in adolescence. More specifically:

- The low percentage of fat tissue, in high muscle mass patients, renders the gland even more pronounced and thus these patients seek surgical consultation to ensure a better definition of the pectoralis area that cannot be obtained by simple physical training. In

### Reasons for undergoing surgery



**FIGURE 6.** Causes of emotional distress in patients affected by gynecomastia, with identification of different causes among the 3 body types groups.



**FIGURE 7.** Analysis of preoperative and postoperative satisfaction with chest appearance using the likert score.

addition, their chest is more scrutinized as compared with the general population, especially in body builders, who are sensitive to the problem and so have higher expectations.<sup>10,11</sup>

- In normal body type patients, gynecomastia caused heavy social lifestyle limitations due to their female appearance, so they ask to resolve the feminine appearance of their chest so as to eliminate social embarrassment, improve their own self esteem, and gain a more masculine chest appearance.
- Overweight patients suffered from heavy chest-wall appearance and feel gynecomastia as a weight disorder rather than a female appearance. Their aim is to get a slimmer aspect. Usually, they are less interested in the surgical planning and less afraid of the scars.

The most attractive standard of male chest shows extreme definition of the pectoralis major especially at the inferior lateral border of the muscle, where the muscle clearly imprints the skin with an edge which marks the chest obliquely from the sternum upward up to the axilla. To respect this standard, the adipocutaneous flap must be as thin as possible to get the maximum contouring of the pectoralis area even if the low percentage of fatty tissue leaves any postoperative irregularities more visible and, consequently, more frequent in groups A and B rather than in overweight patients. In this group, the thickness of the flap must take into consideration the rest of the pectoralis area so as to place the nipple areola complex in an appropriate position. However, direct adhesion between the dermis and the muscular fascia must be strictly avoided to reduce the incidence of postoperative irregularities, especially during muscular contraction. Liposuction is absolutely helpful to regularize the surrounding area reducing the recurrence of irregularities. To achieve a more masculine appearance of the chest, all the patients required small areolas with low nipple projection. When the skin elasticity is optimal, it may be achieved through an aggressive thinning of the subdermal tissue that usually makes it shrink almost instantly, so that the need of full-circle incision is less frequent.<sup>12</sup> Obviously, the respect of the dermal plexus is mandatory in order to avoid necrosis. This procedure also decreases modifications of the areola in terms of widening and shrinking related to temperature variations. Complete excision of the gland seems to be the most appropriate treatment of gynecomastia in order to avoid recurrence. Incomplete excision means that the remaining breast tissue may continue to act as a hyperactive target organ in the face of continued endogenous hormonal stimulation.<sup>11</sup> We retain that en bloc excision helps to perform the complete removal of the gland allowing, at the same time, a more regular harvesting of the adipocutaneous flap. Postoperative scarring may represent a very sensitive issue for the patients and may cause permanent embarrassment. Wide undermining of the skin flap ensures better readaptation of the flap to the new pectoralis profile even in case of abundant skin.<sup>8</sup> The exuberant skin may be fixed to the deep fascia through 3 quilting polyglactin absorbable stitches, placed at 9 to 12 o'clock to 3 o'clock above the areola, distributing the redundancy onto the wider area, reducing at the same

time the dead space, namely, hematomas, seroma, and the recurrence to extra-areola scars. Maintaining the gland inside the pocket, until completely detached, makes also the shortest surgical access comfortable for the surgeon during the procedure. A circumareolar approach may be reserved to lift upwards the nipple areola complex in case of ptosis, to shrink wider areolas or to reduce redundant skin in case of inelastic tissue thus limiting the vertical incision to a small number of cases.

## CONCLUSIONS

The higher attention towards the chest shape and position paid by men requires a more critical analysis of this particular aspect by plastic surgery community. The concept of an ideal chest may be dissimilar among different subjects and may be influenced by age, personal preference, different lifestyle, and different physical structure. Our experience has demonstrated that most of the cases did not require extensive skin incisions, reducing the risk of unpleasant scars, and that direct excision of glandular tissue, in the form of subcutaneous mastectomy, in correction of gynecomastia disorders can ensure stable and satisfactory results.

## REFERENCES

1. Guenther D, Ha RY, Rohrich RJ, et al. Treatment of gynecomastia. In: Nahai F, ed. *The Art of Aesthetic Surgery: Principles and Techniques*. Vol. III. 2nd ed. St Louis: QualityMedical; 2011:2647.
2. Lazala C, Saenger P. Pubertal gynecomastia. *J Pediatr Endocrinol Metab*. 2002; 15:553–560.
3. Aiache AE. Surgical treatment of gynecomastia in the body builder. *Plast Reconstr Surg*. 1989;83:61–66.
4. Bannayan GA, Hajdu SI. Gynecomastia: clinicopathologic study of 351 cases. *Am J Clin Pathol*. 1972;57:431–7.
5. Rohrich RJ, Ha RY, Kenkel JM, et al. Classification and management of gynecomastia: defining the role of ultrasound-assisted liposuction. *Plast Reconstr Surg*. 2003;111:909–923.
6. Webster JP. Mastectomy for gynecomastia through a semicircular intra-areolar incision. *Ann Surg*. 1946;124:557–575.
7. Huang TT, Hidalgo JE, Lewis SR. A circumareolar approach in surgical management of gynecomastia. *Plast Reconstr Surg*. 1982;69:35–40.
8. Innocenti A, Andretto Amodeo C, Ciancio F. Wide-undermining neck liposuction: tips and tricks for good results. *Aesthetic Plast Surg*. 2014;38: 662–9.
9. Ridha H, Colville RJ, Vesely MJ. How happy are patients with their gynecomastia reduction surgery? *J Plast Reconstr Aesthet Surg*. 2009;62:1473–1478.
10. Reyes RJ, Zicchi S, Hamed H, et al. Surgical correction of gynecomastia in bodybuilders. *Br J Clin Pract*. 1995;49:177–179.
11. Babigian A, Silverman RT. Management of gynecomastia due to use of anabolic steroids in bodybuilders. *Plast Reconstr Surg*. 2001;107:240–242.
12. Blau M, Hazani R. Correction of gynecomastia in body builders and patients with good physique. *Plast Reconstr Surg*. 2015;135:425–432.