



AKADÉMIAI KIADÓ

Acta Veterinaria  
Hungarica

69 (2021) 2, 161-168

DOI:


10.1556/004.2021.00018

© 2021 Akadémiai Kiadó, Budapest

## RESEARCH ARTICLE



# Investigation of possible aetiological/triggering factors in porcine ear necrosis syndrome at a farrow-to-feeder pig system

BRANISLAV KURELJUŠIĆ<sup>1\*</sup> , BOŽIDAR SAVIĆ<sup>1</sup>,  
VESNA MILIĆEVIĆ<sup>1</sup>, NEMANJA JEZDIMIROVIĆ<sup>1</sup>,  
OLIVER RADANOVIĆ<sup>1</sup>, JADRANKA ŽUTIĆ<sup>1</sup> and  
CHRISTIANE WEISSENBACHER-LANG<sup>2</sup>

<sup>1</sup> Institute of Veterinary Medicine of Serbia, Janisa Janulisa 14, 11000, Belgrade, Serbia

<sup>2</sup> Institute of Pathology, Department of Pathobiology, University of Veterinary Medicine Vienna, Vienna, Austria

Received: 16 March 2021 • Accepted: 26 April 2021

Published online: 7 June 2021

## ABSTRACT

At a commercial farrow-to-feeder pig system with 2,100 sows in Serbia, lesions resembling porcine ear necrosis syndrome were observed in 80% of the weaned pigs at 45–50 days of age. Pathomorphological examinations were carried out on 10 pigs that had been found dead. The gross lesions ranged from mild, superficial dermatitis to severe, deep inflammation with exudation, ulceration and necrosis. Histopathological examination revealed erosive and ulcerative dermatitis of the pinna with neutrophilic and lymphocytic infiltration and bacterial colonies in the crusts. *Staphylococcus aureus* (MRSA strain), *Staphylococcus hyicus* and *Streptococcus* group C were cultivated from eight, *S. hyicus* from two ear tissue scraping samples. All 10 samples were positive for treponemes and phylogenetic analysis of two polymerase chain reaction products confirmed the relationship to *Treponema (T.) medium/vincentii* and *Treponema pedis*. Treponemes were also detected in seven oral swabs that were analysed to obtain evidence of the transmission of this bacterium by ear biting. The contribution of non-infectious factors to this misbehaviour could not be ruled out as the crude protein concentration of the feed was inappropriate and the climate of the pig house was suboptimal. The concentrations of selected mycotoxins in the feed were not elevated. However, the contribution of both infectious and non-infectious factors to the onset of disease was most probable.

## KEYWORDS

porcine ear necrosis syndrome, histopathology, bacteriology, treponemes, mycotoxins

## INTRODUCTION

Although porcine ear necrosis syndrome (PENS) is widely distributed in countries with intensive pig farming, it has only been scantily studied in the past and is challenging for veterinarians because of its multifactorial aetiology (Park, 2011; Papatsiros, 2012; Malik et al., 2021). Infectious agents as well as non-infectious factors can be involved in the aetiopathogenesis of PENS (Papatsiros, 2012; Kondrák and Albert, 2019). Furthermore, ear biting is commonly suggested as a cause of ear necrosis in pigs (Pringle et al., 2009; Weissenbacher-Lang et al., 2012), but PENS may also appear without any evidence of ear biting. The number of affected pigs can range from sporadic occurrence (Petersen et al., 2008) to a highly prevalent and clinically relevant disease (Pringle et al., 2009), and the clinical signs may occur after weaning and during fattening (Weissenbacher-Lang et al., 2013; Torrison and Cameron, 2019).

Typical necrotic and erosive lesions are located on the tip of the pinna and are referred to as ‘ear tip necrosis’ (Richardson et al., 1984), but necrotic lesions on the lower margin of the

\*Corresponding author.  
Tel.: 00381-64-3559128;  
fax: 00381-11-2851096.  
E-mail: branislavkureljusic@yahoo.com

ear starting from the junction of the ear and neck have also been described (Karlsson et al., 2013). Histologically, ear necrosis lesions can be divided into a milder stage with acanthosis and mild mononuclear infiltration of the epidermis and a more severe stage with ulceration and granulocytic inflammation (Mirt, 1999).

Various bacterial and viral pathogens have been discussed to act as causative agents in the past. While Park et al. (2013) confirmed the partly concomitant presence of *Staphylococcus aureus* and *Staphylococcus hyicus* in samples originating from pigs with ear necrosis, Richardson et al. (1984) discussed synergistic effects between these two bacteria. Other pathogens such as *Mycoplasma suis* were previously implicated (Mirt, 1999). Recent studies have proposed the transmission of treponemes by ear biting (Pringle et al., 2009; Svartström et al., 2013). However, experimental inoculation with the *Treponema (T.) pedis* strain T A<sub>4</sub> failed to induce ear necrosis in pigs (Karlsson et al., 2017). In addition to bacteria, some viruses, such as porcine circovirus type 2 (PCV2) or porcine reproductive and respiratory syndrome virus (PRRSV) may also be associated with PENS (Thibault et al., 1998; Pejsak et al., 2011; Papatsiros, 2012). In addition to infectious agents, non-infectious management and environmental factors, such as early weaning, high pig density in pens, high ammonia concentration, high humidity, high ambient temperature, poor hygiene and slatted flooring without straw can facilitate the occurrence of ear necroses (Busch et al., 2008). Also the impact of feeding factors, such as the use of dry feed, magnesium and copper deficiencies, and increased mycotoxin concentrations, has already been discussed (Torrison and Cameron, 2019).

In the year 2019, we observed a severe case of PENS during one of our farm visits. This gave us the opportunity for a detailed description of gross and histopathological lesions and extended laboratory analyses, particularly of staphylococci, streptococci and treponemes, with the aim of contributing to the knowledge of this still enigmatic disease.

## MATERIALS AND METHODS

### Pig herd

At a commercial farrow-to-feeder pig system with 2,100 sows in Serbia during the autumn of 2019, lesions resembling PENS were detected in weaned pigs. One year before, comparable lesions had been observed, but no additional laboratory examination was launched at that time. At the farm, weekly farrowing was conducted on an all-in/all-out management basis. After weaning at the age of 21 days, pigs were transferred to a weaning barn. Twenty-eight pigs were kept per pen on complete slatted floor with an approximate floor space of 0.33 m<sup>2</sup> per pig. Weaned pigs were fed a dry pelleted feed *ad libitum* and kept in the same group composition until sale at approximately 25–30 kg body weight and 80 days of age. The chemical composition and microbiological quality of the feed corresponded to standard diets except for the crude protein level which was lower than

required and amounted to  $16.79 \pm 0.67\%$ . The sows and the piglets were vaccinated with a modified live porcine reproductive and respiratory syndrome virus (PRRSV) vaccine (Ingelvac ReproCyc<sup>®</sup> PRRS EU and PRRSflex<sup>®</sup> EU, Boehringer Ingelheim Vetmedica Ltd., Germany). In addition, the piglets were vaccinated with a commercial PCV2 vaccine (Ingelvac CircoFLEX<sup>®</sup>, Boehringer Ingelheim Vetmedica Ltd., Germany) and the sows with commercial vaccines against *Escherichia coli* and *Clostridium perfringens* C and *C. novyi* B (Suiseng, Laboratorios Hipra S.A., Spain), porcine parvovirus and erysipelas (Eryseng Parvo, Laboratorios Hipra S.A., Spain) and classical swine fever (Kilapin, Veterinarski Zavod Subotica, Serbia). During the farm visit, pig density, temperature and air velocity were all within the recommended guidelines. Air humidity ranged from 70 to 85%, whereas ammonia concentration from 1.4 to 4 ppm. The recommended relative humidity level in swine production facilities is between 60 and 80%, whereas the most commonly recommended threshold level for ammonia is 20 ppm. Anamnestic and clinical data were obtained from the farm veterinarian.

### Sampling and applied methods

Gross pathological examinations were carried out on ten pigs found dead with ear lesions, originating from five different pens of the weaning barn. For the histopathological investigation, tissue samples from the dividing line between healthy and necrotic tissue were fixed in 10% neutral buffered formalin and embedded in paraffin. In addition to the standard haematoxylin and eosin (HE) stain, Warthin–Starry silver stain was also used.

Tissue scrapings were taken from the auricles with sterile scalpel blades for bacteriological and molecular analysis. In addition to the standard bacteriological investigation, serotyping of streptococci was done using a rapid latex agglutination slide test (Strep latex test, Microgen Bioproducts, UK). For the identification of the isolated *S. aureus*, the API Staph strip test (bioMérieux SA, Marcy l’Etoile, France) was applied. Methicillin-resistant strains were primarily identified by the cefoxitin disk diffusion test and confirmed by a latex agglutination test for the detection of PBP2 (Slidex MRSA Detection, bioMérieux SA, Marcy l’Etoile, France) and a conventional PCR on the *mecA* gene (Geha et al., 1994). For the identification of three different groups of treponemes (*Treponema medium*/*T. vincentii* group, *Treponema phagedenis* group and *Treponema denticola*/*T. putidum* group), a nested PCR protocol on the 16S ribosomal RNA gene with subsequent Sanger sequencing was used as described previously (Evans et al., 2009). To examine the possible transmission of treponemes by ear biting, oral swabs were additionally analyzed. Evolutionary analyses were conducted in MEGA X (<https://www.megasoftware.net/>) using the Neighbour-Joining method. The optimal tree with the sum of branch length = 0.44624480 is shown. The percentage of replicate trees in which the associated taxa clustered together in the bootstrap test (1,000 replicates) are shown next to the branches. The tree is drawn to scale, with

branch lengths in the same units as those of the evolutionary distances used to infer the phylogenetic tree. The evolutionary distances were computed using the Maximum Composite Likelihood method and are expressed in units of the number of base substitutions per site. This analysis involved 9 nucleotide sequences. All ambiguous positions were removed for each sequence pair with the pairwise deletion option. There were a total of 484 positions in the final dataset. *M. suis* was detected in the ear tissue scraping samples by conventional PCR (van Kuppeveld et al., 1992).

The mycotoxins deoxynivalenol (DON), T-2 toxin, zearalenone, aflatoxin, and ochratoxin were determined in the feedstuff by commercial ELISA tests according to the manufacturer's instructions (Neogen, Michigan, USA).

## RESULTS

According to the data obtained by the farm veterinarian, ear lesions were first detected in pigs between 45 and 50 days of age from all pens at the farm. More than 80% of the pig population was affected, making this disease highly prevalent. The lesions ranged from mild, superficial dermatitis to severe, deep inflammation with exudation, ulceration and necrosis (Fig. 1a). Initial lesions appeared on the tip of the pinna as brown and dry crusts, which later extended along the rim of the ear and became necrotic and ulcerated. Mild oedema and erythema were present around the lesions. Later, necrotic lesions became larger and deeper and showed crusts, fibrinohaemorrhagic exudates and necrotic material located on the surface (Fig. 1b). The lesions were usually bilateral. In some cases, the necrotic tissue was sloughed and parts of the pinna were missing. Rarely, lesions were localised at the base of the pinna (Fig. 1c). Although the lesions were in different stages at the time of sampling, general signs of inflammation such as reddening and swelling were prominent.

The necrotic lesions were a triggering factor for biting by penmates. At that time, treatment by local administration of iodine tincture and Virkon S during routine disinfection proved to be effective and led to a regression of the lesions. Additionally, in pens with cases of cannibalism the commercial product 'NoBite' (VetPlanet, Serbia) with denatonium benzoate was used for the prevention of ear biting by

spraying of the ear pinna. Denatonium benzoate is known as the most bitter chemical compound which is used to control cannibalism among pigs. For the treatment of ear lesions doxycycline was applied via the feed. No signs of spontaneous resolution were observed until the age of 80 days except in cases with mild lesions. At the same time, the general health status of the pigs was already affected and respiratory signs such as coughing, as well as diarrhoea and wasting appeared. The growth rate was lower and the feed conversion ratio was higher. At necropsy, in six pigs exudative, fibrinopurulent bronchopneumonia was the main pathological lesion, whereas in three pigs acute catarrhal enteritis was observed. In one pig, the cause of death remained unclear.

In general, histopathological examination revealed erosive and ulcerative dermatitis of the pinna with neutrophilic and lymphocytic infiltration, fibroplasia and bacterial colonies in the crusts (Fig. 2a and 2b). In two samples, plant material was observed in the crusts and the superficial cell debris (Fig. 2c). Hyperaemia and tissue oedema were also observed. Acute mild lesions, observed in four cases, were characterised by acanthosis and hyperkeratosis with scant erosions. On the surface coccoid bacteria of basophilic staining were detected. In the lamina propria a severe inflammatory reaction was noticed (Fig. 2d). The infiltrate predominantly consisted of neutrophils, with scant lymphocytes. Severe chronic lesions, observed in 6 cases, were characterized by epithelial erosion and ulceration. Severe lymphocytic and plasma cell inflammatory reaction was seen in the lamina propria, extending to the dermis. Multiple microabscesses were scattered in the dermis (Fig. 2e), and were often located near the cartilage tissue. Proliferation of connective tissue around the microabscesses was also observed. Additionally, in four samples with chronic lesions necrotising vasculitis or overt thrombosis was observed (Fig. 2f). The blood vessel walls were thickened and endothelial cell proliferation was noticed. Dermal fibrous tissue was prominent in all six cases, underlining the chronicity of the disease process. In sections stained with Warthin–Starry, no argyrophilic spirochaetes were observed.

In eight ear tissue scraping samples, *S. aureus* (MRSA strain), *S. hyicus* and *Streptococcus* group C were isolated. In two samples only *S. hyicus* was detected. All ear tissue scraping samples tested positive for the *T. denticola*/*T.*

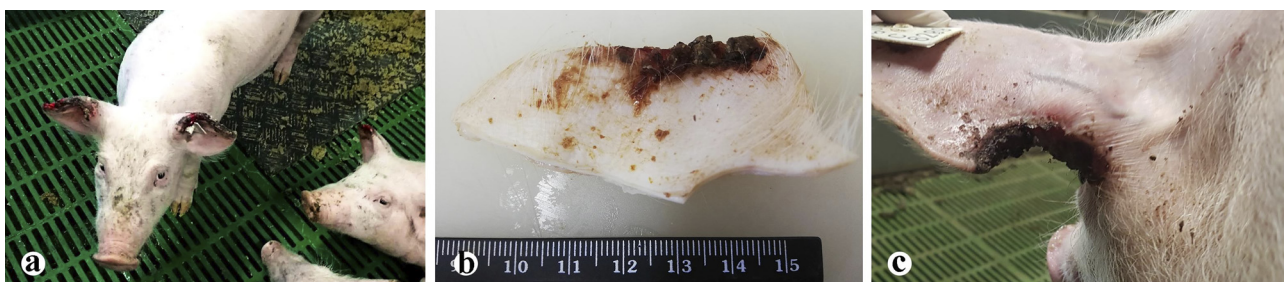


Fig. 1. Gross lesions of the ear. (a) Necrotic lesions of the ear pinna, the entire dorsal margin of both auricles is affected. (b) Fibrinonecrotic crusts located on the surface of the pinnal edge. (c) Necrotic lesions on the base of the pinna; a large part of the ear is missing



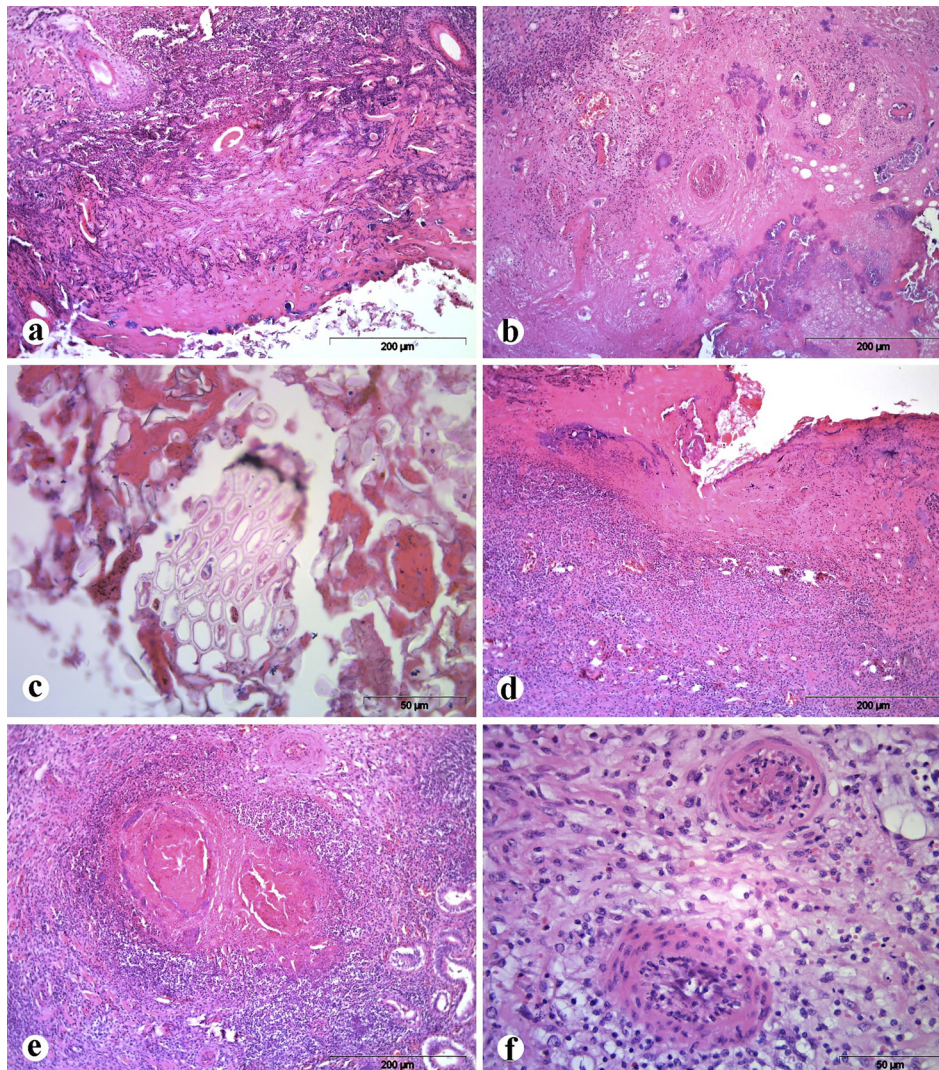


Fig. 2. Ear of a pig, haematoxylin and eosin (HE) stain. (a) Erosive and ulcerative dermatitis of the pinna. (b) Dermal neutrophilic and lymphocytic infiltration, fibroplasia and bacterial colonies in the crusts. (c) Plant material in the crusts and superficial cell debris is present. (d) Severe inflammatory reaction in the lamina propria. (e) Multiple microabscesses are scattered in the dermis. (f) Vasculitis and thrombosis of the blood vessels

*putidum* group and negative for *M. suis*. Seven out of ten oral swabs were positive for the *T. denticola*/*T. putidum* group. Two of the PCR products were sequenced and the phylogenetic analysis showed a genetic relationship of the treponeme nucleotide sequences to the *T. medium*/*T. vincentii* group and *Treponema pedis* (Fig. 3). The nucleotide sequences obtained in this study were deposited in the NCBI gene bank under the accession numbers MW380648 and MW380649.

Mycotoxin concentrations obtained by an ELISA test are shown in Table 1. All tested mycotoxin concentrations were in accordance with the national legislation.

## DISCUSSION

Although many causative agents for the development of ear lesions have been suggested by investigators studying the

potential microbial, nutritional and toxicological as well as aetiological factors, no definitive aetiology has been identified so far (Richardson et al., 1984; Weissenbacher-Lang et al., 2012; Malik et al., 2021).

In this study, a case of PENS at a farrow-to-feeder pig system in Serbia is presented. The clinical occurrence of PENS was detected between 45 and 50 days of age and more than 80% of the weaning pigs were affected, indicating a very high prevalence in the examined population. In other herds, as much as 70% of the pigs were affected (Pringle et al., 2009). Petersen et al. (2008) detected 4.44% prevalence of ear lesions in animals from 90 commercial finisher herds in Denmark, which is a lower prevalence, but this significant difference can be a consequence of differences in the examined age categories. In another investigation, the median prevalence of severe ear necrosis in 31 Irish farrow-to-finish pig farms was 5.4% (van Staaveren et al., 2018). As long as the lesions are mild to moderate, overall pig

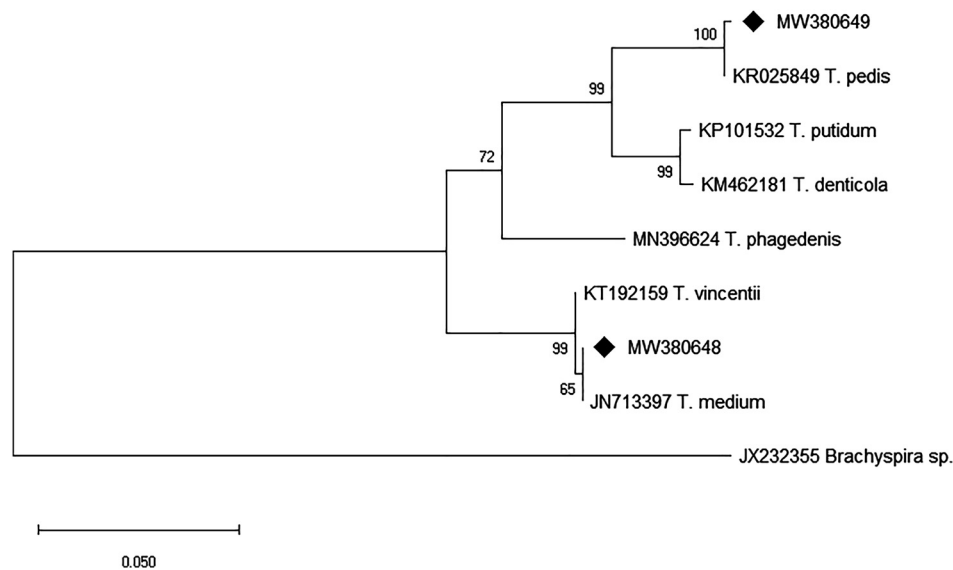


Fig. 3. Phylogenetic tree illustrating the relationships among different *Treponema* species. The tree is constructed from two sequences of the present study (acc. no. MW380648 and MW380649, labelled with a diamond) and 6 reference sequences of different *Treponema* species (acc. no. JN713397, KM462181, KP101532, KR025849, KT192159 and MN396624) of the 16S ribosomal RNA gene. A *Brachyspira* sp. sequence (acc. no. JX232355) was used as outgroup. There were a total of 484 positions in the final dataset

Table 1. Mycotoxin concentrations in the feed

Mycotoxin	Value (mg/kg)	Reference value (mg/kg)*
Deoxynivalenol (DON)	0.79 ± 0.33	< 0.9
T-2 toxin	< 0.025	–
Zearalenone	0.033 ± 0.014	< 0.2
Aflatoxin	< 0.0010	< 0.005
Ochratoxin	< 0.0010	< 0.1

\*Reference values are taken from the national legislation

performance is not affected (Busch et al., 2010). In the present report, respiratory signs such as coughing, as well as diarrhoea and wasting appeared, which were most probably a consequence of concomitant viral or bacterial infection. Hence, the growth rate was lower and the feed conversion ratio was higher, suggesting a negative economic impact. As a matter of fact, the pigs could not be sold due to the severity of the ear lesions, which resulted in noticeable economic consequences for the farmer. Even if the pigs can be sold, economic losses may occur due to the reduced carcass value after trimming or condemnation or early slaughter of the affected pigs (Svartström et al., 2013).

In the present study, early ear lesions were described as acute mild lesions characterised by superficial dermatitis predominantly on the tip of the ear. Later, the ear lesions became more necrotic and deep inflammation developed. In one study, pathological lesions were described as superficial vesicular dermatitis associated with superficial auricular trauma, which can bleed and become attractive to penmates to start biting. The localised lesions slowly healed, whereas extended lesions led to massive necrosis of the pinna, cellulitis, vasculitis and thrombosis of blood vessels with

consequent ischaemia (Richardson et al., 1984). Spirochaetes were not demonstrated in the typical lesions by the Warthin–Starry staining method as described by Richardson et al. (1984). Similar lesions such as necrosis, coccoid bacteria, various inflammatory cells and granulation tissue were seen in the histological sections in a study conducted by Weissenbacher-Lang et al. (2012). This was in accordance with our findings. Additionally, Weissenbacher-Lang et al. (2012) noted thrombus formation and re-epithelisation, which were also observed in the present study. Whether these vascular lesions are a consequence of some viral infection such as PRRSV and PCV2 or are immune-mediated is still to be elucidated.

The impact of PENS on pig welfare should not be underestimated either (Karlsson et al., 2014; Blömke et al., 2020). In the present case report, necrotic lesions were the triggering factor for ear biting by penmates. In two samples, plant material was confirmed histologically in the crusts and the presence of superficial cell debris suggested that licking by penmates had occurred. It is well known that blood is very attractive to penmates and can easily provoke ear biting. Additionally, low sanitary conditions and a reduction of dietary protein, as also determined in the present study, may trigger destructive behaviour in pigs (van der Meer et al., 2017). Clinical experience obtained in this case provided useful information about the treatment of this disease. It was proved that treatment by the local administration of iodine tincture and Virkon S during routine disinfection as well as doxycycline in the feed were effective and led to regression of the lesions.

The infectious aetiology of PENS has been discussed repeatedly (Weissenbacher-Lang et al., 2012; Svartström et al., 2013; Karlsson et al., 2014), and also in the present study *S. aureus* (MRSA strain), *S. hyicus* and *Streptococcus*



group C were isolated. Those bacteria can either act as primary pathogens or their presence may reflect secondary involvement as described by Richardson et al. (1984). A synergistic effect has also been proposed, suggesting a first epidermal damage caused by staphylococcal toxins that is consecutively enabling the entry of destructive streptococci (Richardson et al., 1984). In the early stage of the disease, large numbers of *S. hyicus* but only small numbers of  $\beta$ -haemolytic streptococci were isolated from the ear lesions. In more advanced stages of necrosis and ulceration, the number of streptococci increased (Richardson et al., 1984).

The presence of different treponemes in the necrotic ear lesions has already been demonstrated by special stains or molecular methods (Blandford et al., 1972; Pringle et al., 2009; Svartström et al., 2013; Karlsson et al., 2014). Spirochaetes may be determined using the Warthin–Starry silver stain (Blandford et al., 1972; Richardson et al., 1984; Park, 2011; Karlsson et al., 2013). Nevertheless, the reliability of this method might be affected by its low sensitivity but also its low specificity due to an intensive background staining of various cell and tissue types. In the present study, spirochaetes could not be detected on the Warthin–Starry stained slides, whereas their detection by highly sensitive PCR methods was possible in all ear tissue scraping samples. Similar findings have already been reported by Karlsson et al. (2013). Treponemes show a close relationship in the 16S ribosomal RNA gene and cross-reactions between the species have to be expected (Evans et al., 2009). Sanger sequencing and phylogenetic analysis revealed infections with representatives of the *T. medium*/*T. vincentii* group and *T. pedis*, the second a recently annotated novel *Treponema* species. In the past, treponemes have been associated with periodontal infections in humans as well as with digital dermatitis and ulcerous mammary dermatitis in cattle, and apparently concurrent infections by different *Treponema* species can increase the severity of the lesions (Choi et al., 1997; Evans et al., 2009; Pringle and Fellström, 2010; Toholj et al., 2015). However, the role of treponemes in the progression of ear necroses is still unknown and should be elucidated. In the course of a PENS screening, 59% samples were treponeme positive. *Treponema pedis* was the unequivocally predominant species, typically constituting more than 90% of the treponemes in a lesion assessed visually by microscopy (Karlsson et al., 2014). *Treponema medium*/*T. vincentii* was present in a significantly lower amount in 8.2% of the cases (Karlsson et al., 2014). Since in the present study both *Treponema* species were detected not only in the ear tissue scraping samples but also in the oral swab samples, it can be assumed that the bacterium can be transmitted by ear biting or licking as described by Karlsson et al. (2013). The lower prevalence of treponemes in oral swab samples may have been influenced by the sampling method and the possible lower proportion of treponemes in young pigs as discussed by Karlsson et al. (2013). Since spirochaetes were only occasionally observed during histological examination and therefore are not likely a primary cause, further studies are needed to explore this in more detail (Park, 2011). In

addition, to detect treponemes it is necessary to choose methods of higher sensitivity such as molecular methods. This is especially of paramount importance because we do not know if treponemes have a clinical relevance at all. In contrast, the involvement of staphylococci and streptococci is more likely (Park, 2011). *Mycoplasma suis* was described to be implicated in PENS (Mirt, 1999). However, this microorganism, which belongs to the haemotropic mycoplasmas, was not detected in the present case. Although it was not performed in the present study, metagenomics analysis has recently found increased numbers of bacteria belonging to the *Actinobacillus* and *Haemophilus* genera in pigs affected by acute PENS compared with the unaffected controls. However, their role in the pathogenesis of ear necrosis remains unclear (Torrison and Cameron, 2019). It will be useful to determine if those agents can cause blood vessel thrombosis as detected in this study, which can lead to the development of porcine ear necrosis.

Lang et al. (2010) have investigated the association between mouldy feed and ear necrosis and suggested the relevance of mycotoxins. In the present work all examined mycotoxin concentrations were in accordance with the national legislation. However, we succeeded to detect deoxynivalenol (DON), T-2 toxin, zearalenone, aflatoxin, and ochratoxin. Although their concentrations were low, the combinations of mycotoxins may have an additive or synergistic effect (CAST, 2003). Mycotoxins that occur most frequently together are aflatoxin B<sub>1</sub> with fumonisin B<sub>1</sub> and DON with zearalenone (CAST, 2003), but it remains unclear whether this concomitant occurrence has a synergistic effect. T-2 toxin directly induces dermal irritation or necrosis (Ensley and Radke, 2019), which may also have been the case in the present study. Aflatoxins and trichothecenes are known to be immunosuppressive agents in swine (Ensley and Radke, 2019), and immunosuppression can certainly facilitate infections of the skin and enable the development of PENS (Park, 2011).

In the present report, the severe and highly prevalent occurrence of PENS in a farrow-to-feeder pig system is described. Although bacterial agents such as *S. aureus* (MRSA strain), *S. hyicus*, *Streptococcus* group C, *T. medium*/*T. vincentii* group and *T. pedis* were determined successfully in ear tissue scraping samples, non-infectious triggering factors including high humidity levels and crude protein deficiencies may also have been involved in the development of PENS. The concurrent detection of treponemes in both ear tissue scrapings and oral swab samples might indicate the transmission of the bacterium during ear biting. The present case once again highlights the multifactorial character of PENS that renders the control and prevention of this disease difficult.

## ACKNOWLEDGEMENT

The study was funded by the Ministry of Education, Science and Technological Development, Republic of Serbia (Contract No. 451-03-9/2021-14/200030).



## REFERENCES

- Blandford, T. B., Bygrave, A. C., Harding, J. D. and Little, T. W. (1972): Suspected porcine ulcerative spirochaetosis in England. *Vet. Rec.* **90**, 15.
- Blömke, L., Volkmann, N. and Kemper, N. (2020): Evaluation of an automated assessment system for ear and tail lesions as animal welfare indicators in pigs at slaughter. *Meat Sci.* **159**, 107934.
- Busch, M. E., Jensen, I. M. and Korsgaard, J. (2010): The development and consequences of ear necrosis in a weaner herd and two growing-finishing herds. *Proc. Inter. Pig Vet. Soc. Cong.* **45**.
- Busch, M. E., Wachmann, H., Nielsen, E. O. and Baekbo, P. (2008): Risk factors for ear necrosis and tail lesions in weaners. *Proc. Inter. Pig. Vet. Soc. Cong.* **277**.
- CAST (Council for Agricultural Science and Technology) (2003): Mycotoxins of animals. In: Richard, J. L. and Payne, G. A. (eds) *Mycotoxins: Risks in Plant, Animal and Human Systems*. Task Force Report 139. Council for Agricultural Science and Technology, Ames, IA. pp. 58–85.
- Choi, B. K., Nattermann, H., Grund, S., Haider, W. and Gobel, U. B. (1997): Spirochetes from digital dermatitis lesions in cattle are closely related to treponemes associated with human periodontitis. *Int. J. Syst. Bacteriol.* **47**, 175–181.
- Ensley, S. M. and Radke, S. L. (2019): Mycotoxins in grains and feeds. In: Zimmerman, J. J., Locke, A. K., Ramirez, A., Schwartz, K. J., Stevenson, G. W. and Zhang, J. (eds) *Diseases of Swine*. 11th ed. Blackwell Publishing, Ames, Iowa. pp. 1055–1071.
- Evans, N. J., Brown, J. M., Demirkan, I., Singh, P., Getty, B., Timofte, D., Vink, W. D., Murray, R. D., Blowey, R. W., Birtles, R. J., Hart, C. A. and Carter, S. D. (2009): Association of unique, isolated treponemes with bovine digital dermatitis lesions. *J. Clin. Microbiol.* **47**, 689–696.
- Geha, D. J., Uhl, J. R., Gustafarro, C. A. and Persing, D. H. (1994): Multiplex PCR for the identification of methicillin-resistant staphylococci in the clinical laboratory. *J. Clin. Microbiol.* **32**, 1768–1772.
- Karlsson, F., Klitgaard, K. and Jensen, T. K. (2014): Identification of *Treponema pedis* as the predominant *Treponema* species in porcine skin ulcers by fluorescence *in situ* hybridization and high-throughput sequencing. *Vet. Microbiol.* **171**, 122–131.
- Karlsson, F., Rosander, A., Fellström C. and Backhans, A. (2017): Experimental inoculation of *Treponema pedis* T A4 failed to induce ear necrosis in pigs. *Porc. Health Manag.* **3**, 26.
- Karlsson, F., Svartström, O., Belák, K., Fellström, C. and Pringle, M. (2013): Occurrence of *Treponema* spp. in porcine skin ulcers and gingiva. *Vet. Microbiol.* **165**, 402–409.
- Kondrák, L. and Albert, M. (2019): Porcine ear necrosis syndrome in a swine herd – case report [in Hungarian]. *Magy. Allatorvosok* **141**, 281–287.
- Lang, C., Volmayr, T., Waxenecker, F., Hofstetter, U., Weissenböck, H., Ogris, M., Bruns, G. and Ritzmann, M. (2010): Etiology of the ear necrosis syndrome – investigation of bacteria, fungi and mycotoxins in feeding stuff. *Proc. Inter. Pig. Vet. Soc. Cong.* **899**.
- Malik, M., Chiers, K., Boyen, F., Croubels, S. and Maes, D. (2021): Porcine ear necrosis. *Vet. J.* **271**, 105655.
- Mirt, D. (1999): Lesions of so-called flank biting and necrotic ear syndrome in pigs. *Vet. Rec.* **144**, 92–96.
- Papatsiros, V. (2012): Ear necrosis syndrome in weaning pigs associated with PCV2 infection: a case report. *Vet. Res. Forum* **3**, 217–220.
- Park, J. (2011): Investigation of Exudative Epidermitis and Ear Necrosis in Pigs. Thesis Presented to the University of Guelph in Partial Fulfilment of Requirements for the Degree of Doctor of Veterinary Sciences in Population Medicine. Guelph, Ontario, Canada.
- Park, J., Friendship, R. M., Poljak, Z., DeLay, J., Slavic, D. and Dewey, C. E. (2013): An investigation of ear necrosis in pigs. *Can. Vet. J.* **54**, 491–495.
- Pejsak, Z., Markowska-Daniel, I., Pomorska-Mól, M., Porowski, M. and Kołacz, R. (2011): Ear necrosis reduction in pigs after vaccination against PCV2. *Res. Vet. Sci.* **91**, 125–128.
- Petersen, H. H., Nielsen, E. O., Hassing, A., Ersbøll, A. K. and Nielsen, J. P. (2008): Prevalence of clinical signs of disease in Danish finisher pigs. *Vet. Rec.* **162**, 377–382.
- Pringle, M. and Fellström, C. (2010): *Treponema pedis* isolated from a sow shoulder ulcer. *Vet. Microbiol.* **142**, 461–463.
- Pringle, M., Backhans, A., Otman, F., Sjölund, M. and Fellström, C. (2009): Isolation of spirochetes of genus *Treponema* from pigs with ear necrosis. *Vet. Microbiol.* **139**, 279–283.
- Richardson, J. A., Morter, R. L., Rebar, A. H. and Olander, H. J. (1984): Lesions of porcine necrotic ear syndrome. *Vet. Pathol.* **21**, 152–157.
- Svartström, O., Karlsson, F., Fellström, C. and Pringle, M. (2013): Characterization of *Treponema* spp. isolates from pigs with ear necrosis and shoulder ulcers. *Vet. Microbiol.* **166**, 617–623.
- Thibault, S., Drolet, R., Germain, M.-C., D’Allaire, S., Larochelle, R. and Magar, R. (1998): Cutaneous and systemic necrotizing vasculitis in swine. *Vet. Pathol.* **35**, 108–116.
- Toholj, B., Spasojević, J., Cvetojević, Đ., Kureljušić, B., Cincović, M., Jankov, D., Nikolić, B., Stevančević, M., Smolec, O. and Risteovski, M. (2015): Ulcerous mammary dermatitis – old cause at a new location [in Serbian]. *Proceedings of 26<sup>th</sup> Veterinary Congress in Serbia; Zlatibor, Serbia.* pp. 95–98.
- Torrison, J. and Cameron, R. (2019): Integumentary system: skin, hoof and claw. In: Zimmerman, J. J., Locke, A. K., Ramirez, A., Schwartz, K. J., Stevenson, G. W., Zhang, J., (eds) *Diseases of Swine*. 11th ed. Blackwell Publishing, Ames, Iowa. pp. 292–313.
- van der Meer, Y., Gerrits, W. J. J., Jansman, A. J. M., Kemp, B. and Bolhuis, J. E. (2017): A link between damaging behaviour in pigs, sanitary conditions, and dietary protein and amino acid supply. *PLoS One* **12**, e0174688.
- van Kuppeveld, F. J., van der Logt, J. T., Angulo, A. F., van Zoest, M. J., Quint, W. G., Niesters, H. G., Galama, J. M. and Melchers, W. J. (1992): Genus- and species-specific identification of mycoplasmas by 16S rRNA amplification. *Appl. Environ. Microbiol.* **58**, 2606–2615.
- van Staaveren, N., Calderón Díaz, J. A., García Manzanilla, E., Hanlon, A. and Boyle, L. A. (2018): Prevalence of welfare outcomes in the weaner and finisher stages of the production cycle on 31 Irish pig farms. *Ir. Vet. J.* **71**, 9.
- Weissenbacher-Lang, C., Voglmayr, T., Waxenecker, F., Hofstetter, U., Weissenböck, H., Hoelzle, K., Hoelzle, L. E., Welle, M., Ogris, M., Bruns, G. and Ritzmann, M. (2012): Porcine ear necrosis syndrome: a preliminary investigation of putative

infectious agents in piglets and mycotoxins in feed. *Vet. J.* **194**, 392–397.

Weissenbacher-Lang, C., Voglmayr, T., Weissenböck, H., Pyrek, R., Waxenecker, F., Hofstetter, U., Hoelzle, K., Hoelzle, L. E.,

Welle, M., Bruns, G. and Ritzmann, M. (2013): Untersuchung möglicher Ursachen von Ohrrandnekrosen: unterschiedliche Studien designs – vergleichbare Resultate? [in German]. *Berl. Munch. Tierarztl. Wochenschr.* **126**, 378–387.