

## A novel dysphagia screening method using panoramic radiography

Emi Ito, Yukiko Matsuda\*, Migiwa Kuroda  
and Kazuyuki Araki

Received: 17 September 2020 / Accepted: 24 February 2021

### Abstract

The purpose of this study was to establish a screening method for dysphagia using panoramic radiography. Seventy patients who had undergone panoramic radiography and videofluorographic swallowing study (VF) were selected. Exclusion criteria were surgery related to tumors, jaw deformity, and poor-quality panoramic radiograph images. Patients were diagnosed with dysphagia based on VF findings and accordingly categorized into Dysphagia (+) or Dysphagia (–) groups. The control group consisted of 129 individuals who had undergone panoramic radiography for dental treatment. Exclusion criteria were the same as in the Dysphagia (+) and Dysphagia (–) groups. Two maxillofacial radiologists assessed the vertical and horizontal position of the hyoid bone and measured the distance from the tongue to the palate. The vertical hyoid bone position was significantly lower in the Dysphagia (+) group than in the control group. The distance from the tongue to the palate was significantly shorter in the control group, measuring  $8.5 \pm 5.9$  mm as compared to  $15.0 \pm 9.5$  in the Dysphagia (+) group and  $14.9 \pm 10.0$  in the Dysphagia (–) group. At least 77% of patients were diagnosed with dysphagia or suspected of dysphagia because the hyoid body was below the mandibular line on panoramic radiography. Panoramic radiography may be a useful tool for predicting the risk of dysphagia as it reveals the vertical hyoid bone position and the distance from the tongue to the palate.

**Key words** :panoramic radiograph, dysphagia, screening, hyoid bone, tongue

### Introduction

The functional ability to swallow, i.e., the ability to propel food safely and efficiently from the mouth through the pharynx and into the esophagus, is highly relevant to quality of life (QOL). Azzolino *et al.*<sup>1</sup> have reported that aging causes several significant changes in oropharyngeal swallowing. Age-related swallowing changes first appear at around 50 years and progress over the following decades, with notable differences developing by 60, 70, 80, and 90 years<sup>2</sup>. Aging also gradually affects the swallowing motion and significantly reduces swallowing efficiency<sup>3</sup>.

Oral dysfunction, which occurs frequently in the elderly, can result in poor nutrition and QOL, as well

as serious morbidity and mortality. Comprehensive evaluation of oral function is a fairly common practice in the care of the elderly. Yet current methods allow us to detect dysphagia only after it is already present, rather than predicting it before it occurs. In this study, we aim to improve clinicians' ability to predict dysphagia before the patient becomes aware of the symptoms based on panoramic radiographs of the sort frequently used in general dentistry.

The ability to predict the risk of dysphagia using panoramic radiography may also be useful in assessing the risk of other conditions and complications. Aspiration, for example, is a dangerous complication that is sometimes related to swallowing disorders. Hou *et al.*<sup>4</sup> found that the accidental aspiration and ingestion of foreign objects during dental procedures were more frequent in patients 60 to 79 years old and 10 to 19 years old, respectively. The higher frequency of foreign object aspiration in older patients may be related to the higher incidence of swallowing disorders in this population. The ability to predict

\* Corresponding author

✉ Yukiko Matsuda  
ymatsuda@dent.showa-u.ac.jp

swallowing disorders before they occur will therefore help us to predict future risk of foreign object aspiration.

Sarcopenia is another condition related to swallowing disorders. Sarcopenia and malnutrition both occur frequently in the elderly. Fujishima *et al.*<sup>5</sup> summarized the research on sarcopenia and dysphagia and found that aging and sarcopenia are important risk factors for dysphagia. They defined sarcopenic dysphagia as dysphagia caused by sarcopenia of the whole body including the swallowing muscles. They suggested that resistance training, which is typically applied to treat sarcopenia in the lower extremities, may also help to improve sarcopenic dysphagia. Detecting early changes that are indicative of sarcopenia and starting resistance training may help prevent or improve sarcopenia-related dysphagia.

Dysphagia is generally assessed based on tongue position and hyoid bone position. Tsushima *et al.*<sup>6</sup> confirmed that pathological hyoid bone movement is suggestive of dysphagia. Accordingly, our previous study focused on age-related changes in hyoid bone position as seen on lateral cephalometry. We noted that the horizontal position of the hyoid bone was significantly lower in elderly males than in young males, young females, or elderly females<sup>7</sup>.

Interestingly, lateral cephalometry may not be the only imaging modality that reveals these relevant changes. As Kuroda *et al.*<sup>8</sup> have shown, hyoid bone position on lateral cephalometric radiography is consistent with hyoid bone position on panoramic radiography. Panoramic radiography is commonly used in dental treatment and offers several advantages, including reduced patient stress and the ability to image not only all of the teeth but also the maxillary sinus and the temporomandibular joint. We hypothesized that information related to the risk of dysphagia could be observed on panoramic radiography, and thus that panoramic radiography could be used as a screening tool for dysphagia. As many elderly individuals undergo panoramic radiography as part of their regular dental examinations, the ability to use panoramic radiographic images to predict dysphagia would eliminate the need for additional imaging, reducing both cost and patient radiation exposure. The purpose of this study, therefore, was to establish a screening method for dysphagia using panoramic radiographic images.

## Materials and methods

### 1. Ethical considerations

This study was carried out with the advance approval of the Ethics Committee of Showa University

Dental Hospital (approval number: SUDH0003 and SUDH0034).

### 2. Study population

#### 1) Dysphagia (+) and Dysphagia (–) groups

The study period was between July 2013 and September 2019. Patients who had undergone both videofluorographic swallowing study (VF) panoramic radiography were identified. All of these patients had been recommended for VF because staff at a nursing home or hospital had suspected that they had dysphagia. Surgical cases, maxillofacial tumor cases, and syndrome cases were excluded, as were patients who were unable to maintain correct positioning during panoramic radiography. This left 70 patients who were selected for inclusion in the study.

In this population, the mean and standard deviation of body mass index (BMI) was  $19.4 \pm 3.4$ . The details of the patients' medical histories are shown in Table 1.

The VF protocol required each patient to swallow 1–3 ml of a standard meal containing barium without any specific instructions regarding how they should swallow. We then examined the videofluorographic images for evidence of penetration or aspiration.

In this study, evidence of penetration or aspiration on VF findings was considered to indicate dysphagia, and the patient was classified as Dysphagia (+).

Based on the VF findings, 44 patients were diagnosed with dysphagia and were categorized into the Dysphagia (+) group. The remaining 26 patients were not diagnosed with dysphagia and were categorized into the Dysphagia (–) group.

#### 2) Control group

Another group of 129 patients who had 20 or more remaining teeth, who met the same inclusion criteria

Table 1. Previous or comorbid conditions related to suspected dysphagia in VF patients

Conditions	
Cerebrovascular disease	15
Other brain disorders* <sup>1</sup>	32
Disuse syndrome	5
Traffic accident	3
Cleft-palate disease	2
No known cause of suspected dysphagia	11
Others* <sup>2</sup>	2

\*<sup>1</sup> Includes encephalitis, brain tumor, convulsions, Parkinson's disease, Parkinson's syndrome, epilepsy, schizophrenia, neurological disease, depression and dementia.

\*<sup>2</sup> Includes thyroidectomy and Eagle syndrome.

as the Dysphagia (+) and Dysphagia (-) groups, and who had undergone panoramic radiography at our dental hospital during the same study period was selected as the control group. None of these patients had a history of aspiration or foreign object ingestion during dental treatment.

Table 2 presents the details of the overall study population. A total of 112 males and 87 females were analyzed. The mean age was  $63.8 \pm 17.3$  yrs, and the range was 30 to 95 yrs.

3) Panoramic radiography

A Hyper-XF radiography machine (Asahi Roentgen Ind. Co., Ltd., Kyoto, Japan) was used. Exposure parameters were set to 78 to 82 kV, 10 mA, and 12 s. When taking the radiographs, the Frankfort horizontal (FH) plane of the patient was set parallel to the floor.

4) Image evaluation and measurements

Panoramic radiographs were assessed using a Windows computer (HP Compaq 6300 Pro, Hewlett-Packard, Palo Alto, CA, USA), with a 21.1-inch, 2 M-pixel medical color LED monitor RX240 (EIZO, Tokyo, Japan). All images were evaluated by two oral and maxillofacial radiologists. Three observation points were assessed: (1) the vertical position of the hyoid bone, (2) the horizontal position of the hyoid bone, and (3) the distance from the tongue to the palate.

① Vertical position (Fig. 1)

Two lines were defined as landmarks for assessing the vertical position of the hyoid bone:

- The bilateral mandible line: A virtual line connecting the right and left maximum lateral points of the angles of the mandible.
- The midline: A vertical line connecting the anterior nasal spines and the interproximal point of the upper incisors, extend to the mandibular lower border.
- The mandibular border line: A line parallel to the bilateral mandibular line but translated downward until the line overlaps the point where the midline and the mandibular inferior edge overlap.

Table 2. Age and gender distribution in the study population

Age (yr)	Dysphagia (+)		Dysphagia (-)		Control	
	Male	Female	Male	Female	Male	Female
30-39	2	1	2	0	22	1
40-49	2	1	3	1	15	2
50-59	1	1	2	2	8	13
60-69	5	2	3	3	2	8
70-79	6	5	2	2	13	26
80-89	12	1	4	2	5	12
90-99	1	4	0	0	2	0

The position of the hyoid bone body and the greater horn greater horn were assessed and categorized according to the proportion of the bone that was visible in the area between the bilateral mandible line and the mandibular border line on the panoramic image. The following six groups were identified:

- Type 0: no part of the hyoid bone was observed
- Type 1: the greater horn was observed but the hyoid body was not observed
- Type 2: less than half of the hyoid body was observed
- Type 3: half of the the hyoid body was observed
- Type 4: all of the hyoid body was observed
- Type 5: the hyoid body overlapped with the mandible

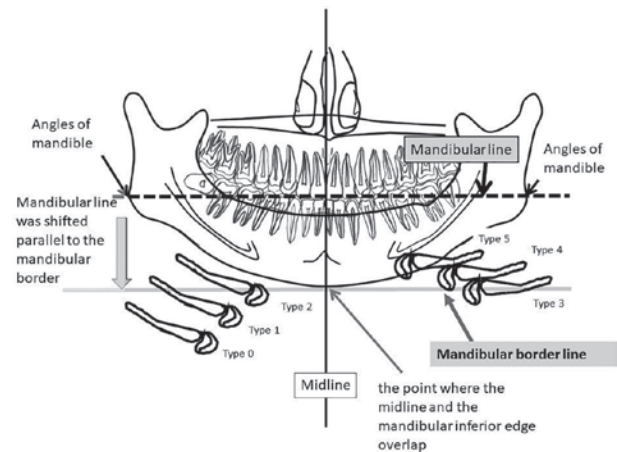


Fig. 1. Assessment of the vertical position of the hyoid bone on panoramic radiography. Two lines were defined as landmarks for assessing the vertical position of the hyoid bone:

- The bilateral mandible line: A virtual line connecting the right and left maximum lateral points of the angles of the mandible.
- The midline: A vertical line connecting the anterior nasal spines and the interproximal point of the upper incisors, extend to the mandibular lower border.
- The mandibular border line: A line parallel to the bilateral mandibular line but translated downward until the line overlaps the point where the midline and the mandibular inferior edge overlap.

The position of the hyoid bone body and the greater horn were assessed and categorized according to the proportion of the bone that was visible in the area between the bilateral mandible line and the mandibular border line on the panoramic image. The following six groups were identified:

- Type 0: no part of the hyoid bone was observed
- Type 1: the greater horn was observed but the hyoid body was not observed
- Type 2: less than half of the hyoid body was observed
- Type 3: half of the hyoid body was observed
- Type 4: all of the hyoid body was observed
- Type 5: the hyoid body overlapped with the mandible

When the vertical position of the hyoid bone differed between the right and left sides, the side with the lower position was recorded.

When the vertical position of the hyoid bone differed between the right and left sides, the side with the lower position was recorded.

## ② Horizontal position (Fig. 2)

Two points were defined as landmarks for assessing the horizontal position of the hyoid bone:

H: The most superior-anterior point of hyoid bone. This point was defined by Hosoda *et al.*<sup>9</sup>

The mandibular border of hyoid point (MBH): A point which is the shortest distance from the point of anterior end of the hyoid body to mandibular border.

Hyoid bone position was assessed following steps.

1) A vertical line, which is connected between H to MBM, was extended to the tooth.

2) horizontal hyoid bone position was classified it

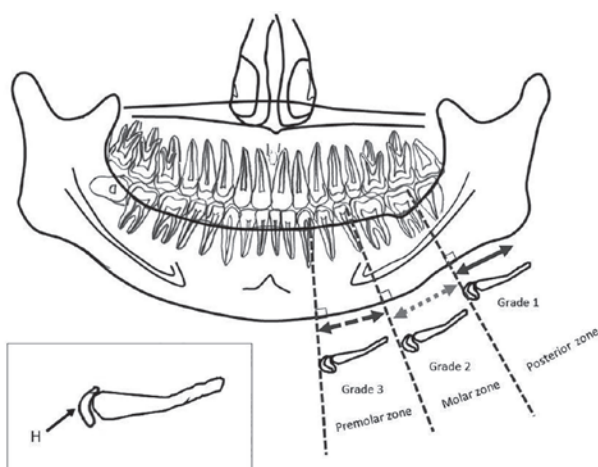


Fig. 2. Two points were defined as landmarks for assessing the horizontal position of the hyoid bone:

H: The most superior-anterior point of hyoid bone. This point was defined by Hosoda *et al.*<sup>9</sup>

The mandibular border of hyoid point (MBH): A point which is the shortest distance from the point of anterior end of the hyoid body to mandibular border.

Hyoid bone position was assessed following steps.

1) A vertical line, which is connected between H to MBM, was extended to the tooth.

2) horizontal hyoid bone position was classified it depends on the following zone, (1) the premolar zone is the area between the mesial 1st premolar and the distal 2nd premolar, (2) the molar zone is the area between 1st molar and the distal 2nd molar, (3) the posterior zone is the area posterior to the 3rd molar.

When the relevant tooth or its neighboring tooth was missing, the landmark line was drawn with reference to the upper tooth.

Using these landmarks, the horizontal position of the hyoid bone was classified into one of three grades:

Grade 1: The most anterior part of the hyoid body was observed in the premolar zone.

Grade 2: The most anterior part of the hyoid body was observed in the molar zone.

Grade 3: The most anterior part of the hyoid body was observed in the posterior zone.

depends on the following zone, (1) the premolar zone is the area between the mesial 1st premolar and the distal 2nd premolar, (2) the molar zone is the area between 1st molar and the distal 2nd molar, (3) the posterior zone is the area posterior to the 3rd molar.

When the relevant tooth or its neighboring tooth was missing, the landmark line was drawn with reference to the upper tooth.

Using these landmarks, the horizontal position of the hyoid bone was classified into one of three grades:

Grade 1: The most anterior part of the hyoid body was observed in the premolar zone.

Grade 2: The most anterior part of the hyoid body was observed in the molar zone.

Grade 3: The most anterior part of the hyoid body was observed in the posterior zone.

③ Distance from the tongue to the palate at the midline (mm) (Fig. 3)

The distance from the tongue to the palate at the midline was measured in images on the monitor. The midline was defined as the line connecting the anterior nasal spines and the interproximal point of the upper incisors.

## 5) Statistical analysis

The differences among all the groups were assessed for statistical significance. SPSS Statistics Ver. 24.0 (International Business Machines Corporation, Chicago, IL, USA) was used for statistical analysis.

The Kruskal-Wallis test was used for analysis of the horizontal and vertical position of the hyoid bone. Welch's *t*-test was used for analysis of the distance from the tongue to the palate. When Welch's *t*-test indicated significance, Dunnett's test was applied as a *post hoc* test. The statistical significance level was set at  $p = 0.05$ .

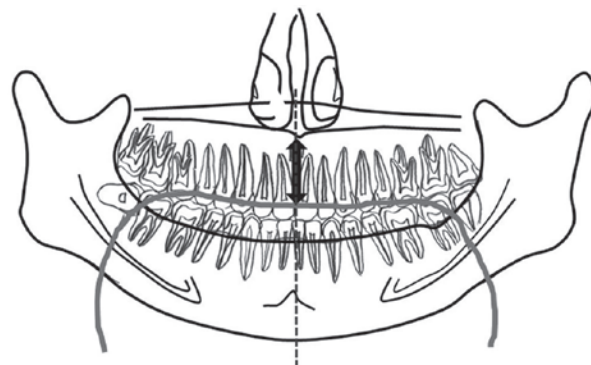


Fig. 3. Distance from tongue to palate on the midline (mm). The distance from the tongue to the palate at the midline was measured in images on the monitor. The midline was defined as the line connecting the anterior nasal spines and the interproximal point of the upper incisors.



To determine the strength of the relationship between the vertical hyoid bone position and the distance between the tongue and the palate, regression analysis was used.

## Results

### 1. Vertical position

Table 3 presents our findings related to the vertical position of the hyoid bone. A statistically significant difference was observed between the Dysphagia (+) group and the control group. This suggests that the Dysphagia (+) group had a significantly lower hyoid bone position than the control group.

Compared to the control group, the Dysphagia (+) group contained a larger proportion of cases in which

neither the hyoid bone nor the greater horn were observed above the mandibular border line, and a larger proportion of cases in which the greater horn was observed above the mandibular border line while the hyoid bone was not observed.

### 2. Horizontal position

Table 4 presents our findings regarding the horizontal position of the hyoid bone. Cases in which the hyoid body was positioned too low to be observed were excluded. A total of 161 cases were assessed. No statistically significant differences were observed.

### 3. Distance from the tongue to the palate

Table 5 presents our findings regarding the distance from the tongue to the palate. The distance from the

Table 3. Distribution of the vertical position of the hyoid bone

	Vertical position					
	Type 0	Type 1	Type 2	Type 3	Type 4	Type 5
Dysphagia (+) <sup>a</sup>	18	10	3	7	3	3
Dysphagia (-)	2	8	5	7	1	4
Control <sup>a</sup>	7	12	23	33	23	31

A statistically significant difference was observed between the Dysphagia (+) group and the control group. <sup>a</sup>:  $p < 0.000000$  according to the Kruskal-Wallis test.

Table 4. Distribution of the horizontal position of the hyoid bone

	Horizontal position		
	Grade 1	Grade 2	Grade 3
Dysphagia (+)	5	14	2
Dysphagia (-)	8	11	3
Control	17	90	11

Cases in which the hyoid body could not be seen were excluded. No statistically significant difference was observed.  $p = 0.271$  according to the Kruskal-Wallis test.

Table 5. Distribution of the distance from tongue to palate

	Distance from tongue to palate (mm)		
	N	Mean	SD
Dysphagia (+) <sup>a</sup>	44	15	9.5
Dysphagia (-) <sup>b</sup>	26	14.9	10
Control <sup>a, b</sup>	129	8.5	5.9

Means and standard deviations (SD) of the distance from tongue to palate.  $p < 0.000000$  according to Welch's *t*-test.

<sup>a</sup>:  $p < 0.000000$  and <sup>b</sup>:  $p < 0.000000$  according to the Dunnett test as a post hoc test.

tongue to the palate was significantly shorter in the control group than in the Dysphagia (+) group or the Dysphagia (-) group.

#### 4. Relationship between hyoid bone position and distance between the tongue and the palate

Fig. 4 shows the regression analysis between hyoid bone position and the distance between the tongue and the palate. The correlation coefficient ( $R^2$ ) was 0.28, which suggests that there is no relationship between hyoid bone position and the distance between the tongue and the palate.

## Discussion

Most research related to dysphagia has assessed hyoid bone movement<sup>6,10-17</sup> by examining VF images<sup>2,3,6,10-17</sup>. Yet VF may not be available for all patients, as it requires a large X-ray machine housed in a dedicated room. Other measurement methods for assessing hyoid bone position, such as cephalometric radiography<sup>18-21</sup> and computed tomography (CT), have also been examined<sup>22</sup>. Yet these methods are not optimal either, partly because they are not commonly used in general dental treatment, and therefore require additional imaging, which leads to higher costs and increased radiation exposure. Furthermore, the requirement that patients must lie down during CT casts doubt on the accuracy of CT for assessing

dysphagia, as lying down significantly changes the natural swallowing position.

Panoramic radiography, in contrast, is widely used in general dental practice and allows patients to maintain a head position similar to that employed during eating. Panoramic radiography could therefore be used for both dental treatment and dysphagia screening, making it even more useful than it already is. This study is the first to explore the use of panoramic radiography to screen for current dysphagia and predict its future likelihood.

#### 1. Vertical position

The position of the hyoid bone serves as a useful reference point in the assessment of oral function. One of the major pathologies in dysphagia is larynx and hyoid ptosis. Lower hyoid bone position is related to a delay in swallowing timing. Specifically, reduced vertical excursion of the hyolaryngeal complex contributes to incomplete airway closure, which is associated with risk of aspiration.

In the present study, the vertical position of the hyoid bone was lower in the Dysphagia (+) and (-) groups than in the control group. This suggests that lower hyoid bone position as seen on panoramic radiography might be related to dysphagia or suspected dysphagia.

#### 2. Horizontal position

Our study revealed no statistically significant difference in horizontal hyoid bone position among the groups. Logemann *et al.*<sup>10</sup> have suggested that the hyoid bone shifts horizontally during swallowing. Curtis *et al.*<sup>12</sup> concluded that the anterior position of the hyoid bone during swallowing is significantly affected by bolus size, and that there is no statistically significant difference associated with age or sex. Feng *et al.*<sup>22</sup> assessed hyoid bone position and concluded that a more posterior position of the hyoid bone is correlated with aspiration in older males. Steele *et al.*<sup>13</sup> assessed hyoid bone movement using VF images and concluded that reduced anterior hyoid bone displacement was linked to a higher risk of post-swallow pharyngeal residue. These findings suggest that the hyoid bone shifts to an anterior position during optimal swallowing; if, in contrast, the hyoid bone stays in a more posterior position, the timing of swallowing might be delayed, which could cause aspiration.

In the present study, we did not detect a difference in horizontal hyoid bone position, but this may have been because our categorization method was not sufficiently sensitive.

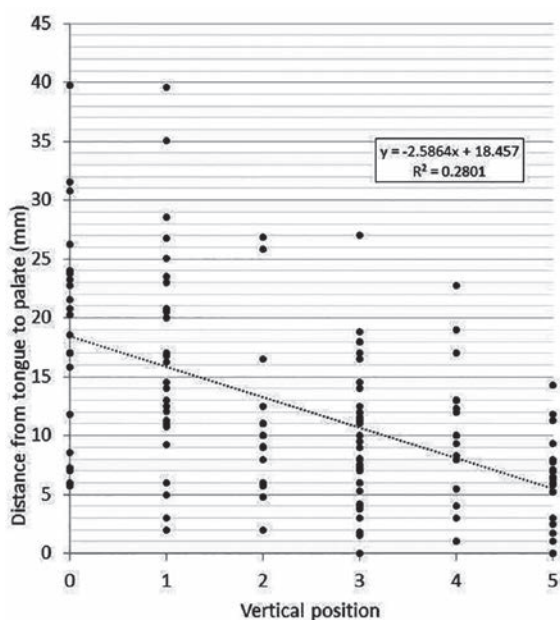


Fig. 4. Regression analysis of the correlation between hyoid bone position and distance between tongue and palate. The correlation coefficient ( $R^2$ ) was 0.28, which suggests that there is no relationship between hyoid bone position and distance between the tongue and the palate.

### 3. Distance from the tongue to the palate

In our study, the distance from the tongue to the palate was significantly shorter in the control group than in the Dysphagia (+) and Dysphagia (-) groups. This suggests that the distance from the tongue to the palate might be related to the muscular function of the tongue. To clarify this point, we plan to assess the relationship between the position of the hyoid bone and the distance from the tongue to the palate as well as tongue pressure.

Fujishima *et al.*<sup>5</sup> have proposed that swallowing disorders are related to sarcopenia. Sarcopenia of the swallowing muscles plays an important role in swallowing disorders. The widening of the distance between the tongue and the palate, for example, may be related to the loss of tongue muscle tone. This change may delay the sealing of the laryngeal vestibule and the opening of the cricopharyngeal muscle. Namiki *et al.*<sup>14</sup> assessed the difference in hyoid position before and after tongue-pressure resistance training (TPRT). They concluded that TPRT improved tongue strength, dexterity, both anterior and superior tongue elevation, and swallowing functions. This suggests that TPRT could improve both tongue function and suprahyoid muscle function simultaneously, thereby helping to prevent sarcopenic dysphagia.

### 4. Relationship between hyoid bone position and distance from the tongue to the palate

In this study, the relationship between the distance from the tongue to the palate and the hyoid bone position was assessed by regression analysis. The value of  $R^2$  was less than 0.3, suggesting that there is no relationship between them. The distance from the tongue to the palate may increase as a result of atrophy of the tongue muscle, and thus may not be related to the hyoid bone position.

### 5. Study limitations

When taking panoramic radiograph, patient have to keep centric occlusion. This position was different from normal occlusion. This study has some limitations. First, because the hyoid bone does not connect to any other bone and the tongue is flexible, the hyoid bone can move during panoramic radiography, which takes almost 12 seconds. This study excluded all cases in which the hyoid bone or the tongue moved during panoramic radiography.

Second, this study defined the Dysphagia (+) group as patients with penetration or aspiration in their VF findings. All patients who had undergone

VF had been suspected by staff at a nursing home or clinic of having dysphagia or aspiration pneumonia. Yet patients assigned to the Dysphagia (-) group may also experience aspiration in their daily life, although it was not captured on VF.

Our VF procedure examines each patient in detail for any sign of a swallowing disorder, including atypical timing, aspiration with any etiology, and the presence of residue in the oral cavity, on the pharyngeal walls, or in the vallecular or pyriform sinuses. If we had defined the Dysphagia (+) group as patients with any of these signs, all patients examined by VF would have been classified as Dysphagia (+). Our decision to restrict the Dysphagia (+) group to patients with penetration or aspiration may be one reason why there was no significant difference between the Dysphagia (+) and Dysphagia (-) groups in this study.

Finally, it was not possible to perform VF in all patients in the control group. Although we referred to clinical charts to ensure that patients in the control group did not have dysphagia and had not experienced aspiration or ingestion of foreign objects during dental treatment, it remains possible that the control group included some individuals with undiagnosed dysphagia.

## Conclusion

In comparison with the control group, the Dysphagia (+) group had a significantly lower vertical hyoid bone position, while both the Dysphagia (+) and the Dysphagia (-) groups had a significantly greater distance from tongue to palate. These results suggest that vertical hyoid bone position and distance from the tongue to the palate might be useful screening tools for predicting dysphagia.

## Acknowledgements

This work was financially supported by KAKENHI (16K11523 and 20K10169).

## Conflict of interest disclosure

The authors declare that they have no conflict of interest.

## References

1. Azzolino D, Damanti S, Bertagnoli L, *et al.* Sarcopenia and swallowing disorders in older people. *Aging Clin Exp Res.* 2019;**31**:799-805.
2. Daggett A, Logemann J, Rademaker A, *et al.* Larynx-

- geal penetration during deglutition in normal subjects of various ages. *Dysphagia*. 2006;**21**:270–274.
3. Tracy JF, Logemann JA, Kahrilas PJ, et al. Preliminary observations on the effects of age on oropharyngeal deglutition. *Dysphagia*. 1989;**4**:90–94.
  4. Hou R, Zhou H, Hu K, et al. Thorough documentation of the accidental aspiration and ingestion of foreign objects during dental procedure is necessary: review and analysis of 617 cases. *Head Face Med*. 2016;**12**:23. (accessed 2020 Oct 28) Available from: [https://www.ncbi.nlm.nih.gov/pmc/articles/PMC4957346/pdf/13005\\_2016\\_Article\\_120.pdf](https://www.ncbi.nlm.nih.gov/pmc/articles/PMC4957346/pdf/13005_2016_Article_120.pdf)
  5. Fujishima I, Fujii-kurachi M, Arai H, et al. Sarcopenia and dysphagia: position paper by four professional organizations. *Geriatr Gerontol Int*. 2019;**19**:91–97.
  6. Tsushima C, Saitoh E, Baba M, et al. Hyoid movement and laryngeal penetration during sequential swallowing. *J Med Dent Sci*. 2009;**56**:113–121.
  7. Matsuda Y, Ito E, Kimura Y, et al. Hyoid bone position related to gender and aging using lateral cephalometric radiographs. *Orthod Waves*. 2018;**77**:226–231.
  8. Kuroda M, Matsuda Y, Ito E, et al. Potential of panoramic radiography as a screening method for oral hypofunction in the evaluation of hyoid bone position. *Showa Univ J Med Sci*. 2019;**31**:227–235.
  9. Hosoda K, Yamaguchi M, Kasai K, et al. Hyoid bone position in relation to skeletal malocclusion using cephalograms. *Nihon Univ J Oral Sci*. 1996;**22**:262–270. (in Japanese).
  10. Logemann JA, Pauloski BR, Rademaker AW, et al. Temporal and biomechanical characteristics of oropharyngeal swallow in younger and older men. *J Speech Lang Hear Res*. 2000;**43**:1264–1274.
  11. Logemann JA, Pauloski BR, Rademaker AW, et al. Oropharyngeal swallow in younger and older women: videofluoroscopic analysis. *J Speech Lang Hear Res*. 2002;**45**:434–444.
  12. Curtis J, Langenstein J, Schneider S. Superior and anterior hyoid displacement during swallowing in non-dysphagic individuals. *Dysphagia*. 2018;**33**:602–609.
  13. Steele CM, Bailey GL, Chau T, et al. The relationship between hyoid and laryngeal displacement and swallowing impairment. *Clin Otolaryngol*. 2011;**36**:30–36.
  14. Namiki C, Hara K, Tohara H, et al. Tongue-pressure resistance training improves tongue and suprahyoid muscle functions simultaneously. *Clin Interv Aging*. 2019;**14**:601–608.
  15. Logemann JA, Curro FA, Pauloski B, et al. Aging effects on oropharyngeal swallow and the role of dental care in oropharyngeal dysphagia. *Oral Dis*. 2013;**19**:733–737.
  16. Zhang Z, Perera S, Donohue C, et al. The prediction of risk of penetration-aspiration via hyoid bone displacement features. *Dysphagia*. 2020;**35**:66–72.
  17. Zhang Z, Coyle JL, Sejdic E. Automatic hyoid bone detection in fluoroscopic images using deep learning. *Sci Rep*. 2018;**8**:12310. (accessed 2020 Oct 28) Available from: [https://www.ncbi.nlm.nih.gov/pmc/articles/PMC6097989/pdf/41598\\_2018\\_Article\\_30182.pdf](https://www.ncbi.nlm.nih.gov/pmc/articles/PMC6097989/pdf/41598_2018_Article_30182.pdf)
  18. Gulati A, Chate RA, Howes TQ. Can a single cephalometric measurement predict obstructive sleep apnea severity? *J Clin Sleep Med*. 2010;**6**:64–68.
  19. Kim SJ, Kim YS, Park JH, et al. Cephalometric predictors of therapeutic response to multilevel surgery in patients with obstructive sleep apnea. *J Oral Maxillofac Surg*. 2012;**70**:1404–1412.
  20. Cho HW, Kim IK, Cho HY, et al. Retrospective study of changes in pharyngeal airway space and position of hyoid bone after mandibular setback surgery by cephalometric analysis. *Maxillofac Plast Reconstr Surg*. 2015;**37**:38. (accessed 2020 Oct 28) Available from: [https://www.ncbi.nlm.nih.gov/pmc/articles/PMC4620125/pdf/40902\\_2015\\_Article\\_39.pdf](https://www.ncbi.nlm.nih.gov/pmc/articles/PMC4620125/pdf/40902_2015_Article_39.pdf)
  21. Chauhan R, Bagga DK, Agrawal P, et al. Radiographic evaluation of the hyoid bone position and pharyngeal airway depth in anteroposterior dysplasia. *Int J Clin Pediatr Dent*. 2019;**12**:101–106.
  22. Feng X, Todd T, Hu Y, et al. Age-related changes of hyoid bone position in healthy older adults with aspiration. *Laryngoscope*. 2014;**124**:E231–E236.