

2021

A Rare Entity: Case Report of Recurrent Hypertrophic Pyloric Stenosis

Astrid A. Gleaton
Maine Medical Center

Et al.

Follow this and additional works at: <https://knowledgeconnection.mainehealth.org/jmmc>

 Part of the [Pediatrics Commons](#), and the [Surgery Commons](#)

Recommended Citation

Gleaton, Astrid A. and Pandya, Kartikey (2021) "A Rare Entity: Case Report of Recurrent Hypertrophic Pyloric Stenosis," *Journal of Maine Medical Center*. Vol. 3 : Iss. 2 , Article 13.

Available at: <https://knowledgeconnection.mainehealth.org/jmmc/vol3/iss2/13> <https://doi.org/10.46804/2641-2225.1085>

The views and thoughts expressed in this manuscript belong solely to the author[s] and do not reflect the opinions of the Journal of Maine Medical Center or MaineHealth.

This Case Report is brought to you for free and open access by Maine Medical Center Department of Medical Education. It has been accepted for inclusion in the Journal of Maine Medical Center by an authorized editor of the MaineHealth Knowledge Connection. For more information, please contact Dina McKelvy mckeld1@mmc.org.

A Rare Entity: Case Report of Recurrent Hypertrophic Pyloric Stenosis

Authors

Astrid A. Gleaton and Kartikey Pandya

CASE REPORT

A Rare Entity: Case Report of Recurrent Hypertrophic Pyloric Stenosis

Astrid A. Gleaton, MD¹, Kartik A. Pandya, MD²

¹Maine Medical Center, Department of Surgery, Portland, ME, ²Maine Medical Partners, Pediatric Surgery, Portland ME

Introduction: Hypertrophic pyloric stenosis (HPS) is well known in pediatric surgery and has good outcomes after pyloromyotomy.¹ Emesis in the immediate postoperative period occurs in 40% of patients with HPS and is attributed to gastroparesis from prolonged gastric distention.² Emesis presenting weeks to months after pyloromyotomy prompts an evaluation that often yields pathology unrelated to HPS. Because recurrent HPS is rare, making this diagnosis highlighted the importance of practicing broad differential diagnoses, ruling out most common causes, and including obscure etiologies.

Clinical Findings: A 3-week-old male born after full-term gestation with a history of HPS underwent an uncomplicated laparoscopic pyloromyotomy. He had an uneventful initial recovery but then presented with recurrent projectile nonbilious emesis 7 weeks postoperatively. Between presentations, the patient consistently tolerated feeds and gained weight. Informed consent was obtained.

Clinical Course: The patient was evaluated with an abdominal ultrasound, which revealed a hypertrophic pyloric channel, and an upper gastrointestinal contrast (UGI) study, which showed a partial gastric outlet obstruction. He underwent laparoscopy, which revealed a thickened pyloric channel, prompting a repeat pyloromyotomy. Postoperatively, his diet was advanced, and he was discharged on postoperative day 1.

Conclusions: Emesis after pyloromyotomy for HPS is common and usually self-limited. Recurrent emesis after normal feeding for weeks or months often yields a diagnosis unrelated to HPS. However, if other more common causes of emesis are excluded, then recurrent HPS can be evaluated with abdominal ultrasound and an UGI study. Once diagnosed, laparoscopic repeat pyloromyotomy is an appropriate treatment option.

Keywords: hypertrophic pyloric stenosis, recurrent hypertrophic pyloric stenosis, laparoscopic pyloromyotomy, case report

A male neonate born after 39 weeks and 2 days gestation was diagnosed with hypertrophic pyloric stenosis (HPS) and underwent laparoscopic pyloromyotomy at 3 weeks old. By postoperative day 1, he was tolerating feeds and was discharged. At a follow-up visit at 7 weeks old, he was doing well, taking in approximately 120 mL of infant formula every 3 to 4 hours and gaining 0.3 to 0.6 kg/week. At 11 weeks old, he presented to the hospital with projectile nonbilious emesis and hypochloremic metabolic alkalosis.

His symptoms continued despite hydration and metabolic derangement correction. An abdominal ultrasound revealed a hypertrophic pylorus nearly

identical to his ultrasound at initial presentation (Figure 1A and 1B). He was also evaluated with an upper gastrointestinal contrast (UGI) study, which showed a partial gastric outlet obstruction. We consulted pediatric gastroenterology, who recommended a nasoduodenal tube to see if post-pyloric feeds were tolerated, which would provide nutrition and rule out a duodenal web. The tube could not pass the obstructed pyloric channel. Diagnostic laparoscopy showed a thickened pylorus (Figure 2A), prompting repeat pyloromyotomy (Figure 2B). He was again treated by our standard post-pyloromyotomy protocol, such that after 4 hours of bowel rest, he was fed 20 mL/kg of formula every 3 hours. After tolerating 2 sequential feeds, he was advanced to ad lib feeds and discharged on postoperative day 1. On postoperative day 4, he had an emesis of feeds more than 20 mL/kg. However, by postoperative day 7, he was tolerating larger feeds without emesis nor any other concerns.

Correspondence: Astrid A. Gleaton MD
Department of Surgery, Maine Medical Center
22 Bramhall Street, Portland, ME 04102
AAGleaton@mmc.org

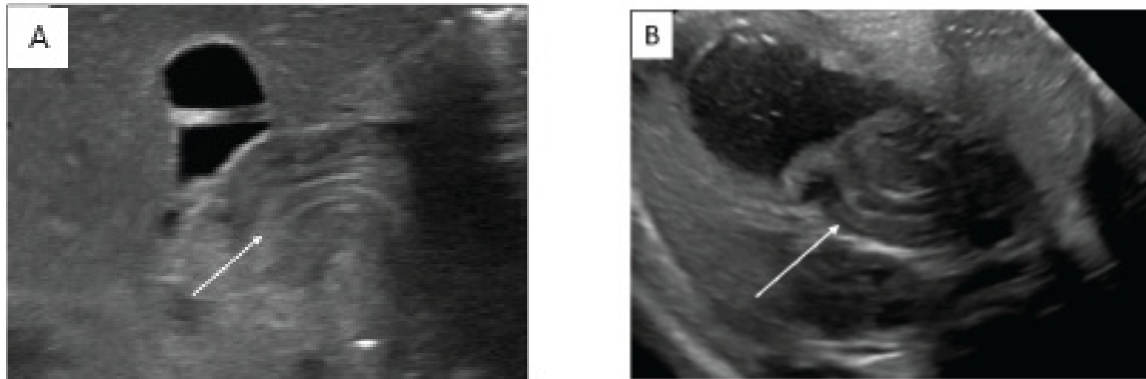


Figure 1. Abdominal Ultrasound. A, Abdominal ultrasound at 3 weeks of age shows a pyloric wall thickness of 4 mm, a pyloric channel length of 19 mm, and no passage with feeds. White arrow indicates the pylorus. B, Abdominal ultrasound at 11 weeks of age shows a pyloric wall thickness of 5 mm, a pyloric channel length of 19 mm, and no passage of feeds. White arrow indicates the pylorus

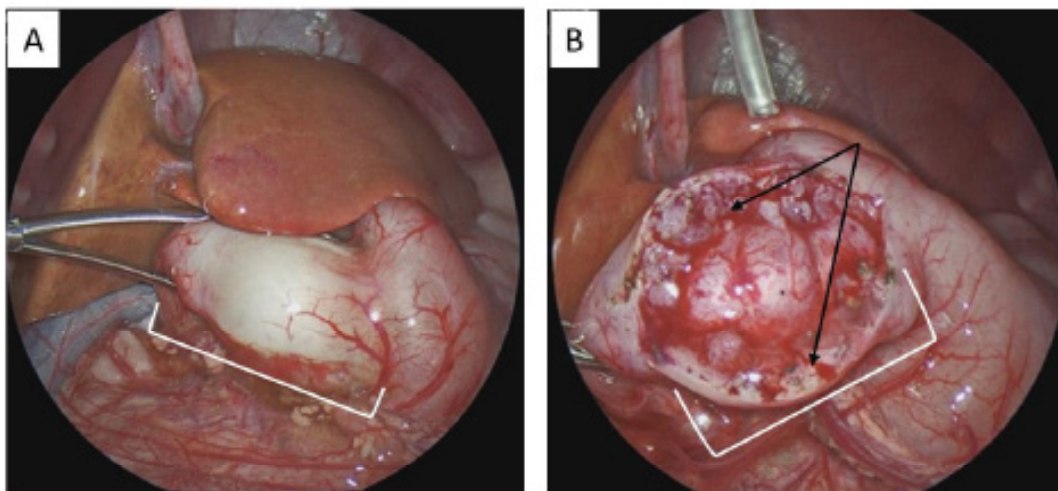


Figure 2. Intraoperative Findings During Diagnostic Laparoscopy. A, Pale, thickened pylorus (white bracket). B, Repeat pyloromyotomy with mucosa lining intact (white bracket) and widely separated muscle edges (black arrows).

DISCUSSION

HPS is a common disease in pediatric surgery and has good postoperative outcomes (low risks of mucosal perforation and incomplete myotomy, and prompt resumption of feedings).³ At our institution, most patients are discharged 1 to 2 days after a pyloromyotomy (open or laparoscopic). Recurrent HPS (rHPS), however, rarely occurs after pyloromyotomy, with an estimated incidence of 0.07%.⁴ Because rHPS is rare, our initial differential was quite broad, including formula intolerance, gastroesophageal reflux, over-feeding, gastroparesis, and perforated duodenal web.

Incomplete pyloromyotomy was also considered;

<https://knowledgeconnection.mainehealth.org/jmmc/vol3/iss2/13>
DOI: 10.46804/2641-2225.1085

however, multiple weeks of feeding well and weight gain was inconsistent with this diagnosis. The ultrasound and UGI study ruled out many of these considerations by showing a mechanical obstruction. Even so, we were not confident in our diagnosis before going to the operating room, in part because ultrasound can show an abnormal pylorus for months after pyloromyotomy.⁵ We anticipated that if a normal pylorus was found intraoperatively, pediatric gastroenterology would perform an upper endoscopy to look for a duodenal web at the same anesthetic event. Although making this diagnosis posed a challenge, the exercise was good for practicing a broad differential.

The literature does not well define rHPS, as most publications on the topic are limited to sparse case reports.^{3,4,6-8} In 2018, a case report defined recurrence as a period of weeks post-pyloromyotomy without significant emesis and adequate weight gain before presenting again with nonbilious emesis.⁶ This clear, symptom-free interval after the first pyloromyotomy was similarly seen in our patient and described in other case reports.^{3,4,6,7} Although not formally established, this interval appears to be a defining characteristic of this disease process. Also, this study population should exclude patients with incomplete myotomy because they likely have immediate persistent emesis and will not tolerate full-volume feeds or consistently gain weight.

With such an uncommon diagnosis, treatment of rHPS is unclear. Repeat laparoscopic and open pyloromyotomy have been successful.^{6,7} One institution successfully treated 1 patient with endoscopic balloon dilation, although this approach failed in another patient who then required repeat open pyloromyotomy.⁴ In another case report, rHPS did not improve after a repeat open pyloromyotomy, which prompted a third surgical exploration and removal of part of the pyloric muscle.⁸ We do not know whether the third operation was for recurrent pyloric stenosis or incomplete pyloromyotomy, because a symptom-free interval did not occur between the second and third operation. A novel approach to treating pyloric stenosis, although not yet trialed in rHPS, is endoscopic pyloromyotomy. In one study, a gastroenterologist successfully treated 10 patients with HPS using endoscopic pyloromyotomy with no reported complications.⁹ An endoscopic pyloromyotomy in rHPS may lead to higher mucosal perforation because, presumably on one side of the pylorus, the longitudinal and circular muscles have been divided, leaving only the intact pyloric mucosa. Overall, multiple modalities can address rHPS, although no procedure is superior to another.

The pathophysiology of HPS is currently unknown. It may be related to poorly controlled pylorospasm, possibly due to diminished nitric oxide synthase activity that leads to hypertrophy.¹⁰ Even less is

known about the mechanism for rHPS. One case report speculated that recurrence could represent either operating early on a pylorus that continues to hypertrophy or an acquired insult that causes a second hypertrophic event.⁶ The latter process is favored, given several case reports of adults presenting with hypertrophic pyloric stenosis.^{11,12} Overall, despite having multiple modalities of treatment, more information is needed to better understand both HPS and rHPS.

Conflict of Interest: None

REFERENCES

1. Linnaus ME, Ostlie DJ. Complications in common general pediatric surgery procedures. *Semin Pediatr Surg.* 2016;25(6):404-411. doi:10.1053/j.sempedsurg.2016.10.002
2. Castellani C, Peschaut T, Schipping M, Saxena AK. Postoperative emesis after laparoscopic pyloromyotomy in infantile hypertrophic pyloric stenosis. *Acta Paediatr.* 2014;103(2):e84-e87. doi:10.1111/apa.12460
3. Taqi E, Boutros J, Emil S, et al. Evaluation of surgical approaches to pyloromyotomy: a single-center experience. *J Pediatr Surg.* 2007;42(5):865-68. doi.org/10.1016/j.jpedsurg.2006.12.051
4. Nasr A, Ein SH, Connolly B. Recurrent pyloric stenosis: to dilate or operate? A preliminary report. *J Pediatr Surg.* 2008;43(2):e17-e20. doi:10.1016/j.jpedsurg.2007.10.039
5. Yoshizawa J, Eto T, Higashimoto Y, Saitou T, Maie M. Ultrasonographic features of normalization of the pylorus after pyloromyotomy for hypertrophic pyloric stenosis. *J Pediatr Surg.* 2001;36(4):5882-586. doi:10.1053/jpsu.2001.2287
6. Hendricks CM, Edgerton CA, Leshner AP. Recurrent pyloric stenosis. *Am Surg* 2018;84(9):e354-e356. doi:10.1177/000313481808400905
7. Ankermann T, Engler S, Pa-tsch C-J. Repyloromyotomy for recurrent infantile hypertrophic pyloric stenosis after successful first pyloromyotomy. *J Pediatr. Surg.* 2002;37(11):E40. doi:10.1053/jpsu.2002.36213
8. Louati H, Zitouni H, Belhajmansour M, et d. A difficult recurrent hypertrophic pyloric stenosis. *J Neonatal Sur.* 2017;6(2):48. doi:10.21699/jns.v6i2.484
9. Ibarguen-Secchia E. Endoscopic pyloromyotomy for congenital pyloric stenosis. *Gastrointest Endos.* 2005;61(4):598-600. doi:10.1016/s0016-5107(05)00075-1
10. Vanderwinden JM, Mailleux P, Schiffmann SN, Vanderhaeghen JJ, De Laet MHH. Nitric oxide synthase activity in infantile hypertrophic pyloric stenosis. *N Engl J Me.* 1992;327(8):5115-115. doi:10.1056/NEJM199208203270802
11. Hassan SM, Mubarak A, Muddassir S, Haq F. Adult idiopathic hypertrophic pyloric stenosis - a common presentation with an uncommon diagnosis. *J Community Hosp Intern Med Perspect.* 2018;8(2):64-67. doi:10.1080/20009666.2018.1444905
12. Graadt van Roggen JF, van Krieken JH. Adult hypertrophic pyloric stenosis: case report and review. *J Clin Pathol.* 1998;51(6):479-480. doi:10.1136/jcp.51.6.479