

## REVIEW

## X-Linked Parkinsonism: Phenotypic and Genetic Heterogeneity

Giulia Di Lazzaro, MD,<sup>1,2\*</sup> Francesca Magrinelli, MD,<sup>1,3</sup> Carlos Estevez-Fraga, MD,<sup>4</sup>  
Enza M. Valente, MD, PhD,<sup>5,6</sup> Antonio Pisani, MD, PhD,<sup>6,7</sup> and Kailash P. Bhatia, MD, FRCP\*<sup>1</sup>

<sup>1</sup>Department of Clinical and Movement Neurosciences, UCL Queen Square Institute of Neurology, University College London, London, United Kingdom

<sup>2</sup>Department of Systems Medicine, Tor Vergata University of Rome, Rome, Italy

<sup>3</sup>Department of Neurosciences, Biomedicine and Movement Sciences, University of Verona, Verona, Italy

<sup>4</sup>Department of Neurodegenerative Disease, UCL Queen Square Institute of Neurology, University College London, London, United Kingdom

<sup>5</sup>Department of Molecular Medicine, University of Pavia, Pavia, Italy

<sup>6</sup>IRCCS Mondino Foundation, Pavia, Italy

<sup>7</sup>Department of Brain and Behavioral Sciences, University of Pavia, Pavia, Italy

**ABSTRACT:** X-linked parkinsonism encompasses rare heterogeneous disorders mainly inherited as a recessive trait, therefore being more prevalent in males. Recent developments have revealed a complex underlying panorama, including a spectrum of disorders in which parkinsonism is variably associated with additional neurological and non-neurological signs. In particular, a childhood-onset encephalopathy with epilepsy and/or cognitive disability is the most common feature. Their genetic basis is also heterogeneous, with many causative genes and different mutation types ranging from “classical” coding variants to intronic repeat expansions. In this review, we provide an updated overview of the phenotypic and genetic spectrum of the most relevant X-linked parkinsonian syndromes, namely X-linked dystonia-parkinsonism (XDP, Lubag disease), fragile X-associated tremor/ataxia syndrome (FXTAS), beta-propeller protein-associated neurodegeneration (BPAN, NBIA/PARK-WDR45), Fabry disease, Waisman syndrome, methyl CpG-binding protein 2 (MeCP2) spectrum disorder, phosphoglycerate kinase-1 deficiency syndrome (PGK1) and X-linked

parkinsonism and spasticity (XPDS). All clinical and radiological features reported in the literature have been reviewed. Epilepsy occasionally represents the symptom of onset, predating parkinsonism even by a few years; action tremor is another common feature along with akinetic-rigid parkinsonism. A focus on the genetic background and its pathophysiological implications is provided. The pathogenesis of these disorders ranges from well-defined metabolic alterations (PGK1) to non-specific lysosomal dysfunctions (XPDS) and vesicular trafficking alterations (Waisman syndrome). However, in other cases it still remains poorly defined. Recognition of the phenotypic and genetic heterogeneity of X-linked parkinsonism has important implications for diagnosis, management, and genetic counseling. © 2021 The Authors. *Movement Disorders* published by Wiley Periodicals LLC on behalf of International Parkinson and Movement Disorder Society

**Key Words:** X-linked parkinsonism; BPAN; XDP; FXTAS; MeCP2

Since the identification of the first mutation in the SNCA gene causing Parkinson’s disease (PD) in 1997, many other genes have been associated with PD. They range from common susceptibility loci with moderate to weak effect sizes to highly penetrant rare disease loci,

where the presence of mutations is sufficient to cause the disease with mendelian inheritance.<sup>1</sup> To date, monogenic forms account for only ~5% to 10% of patients with PD, usually characterized by an earlier disease onset.

This is an open access article under the terms of the Creative Commons Attribution License, which permits use, distribution and reproduction in any medium, provided the original work is properly cited.

\*Correspondence to: Dr. K.P. Bhatia, Department of Clinical and Movement Neurosciences, UCL Queen Square Institute of Neurology, Box 13, National Hospital for Neurology and Neurosurgery, Queen Square, London, WC1N 3BG, UK; E-mail: k.bhatia@ucl.ac.uk  
Dr. G. Di Lazzaro, Department of Systems Medicine, Tor Vergata University of Rome, Via Montpellier 1, Rome 00133, Italy; E-mail: giulia.dilazzaro@gmail.com

**Relevant conflicts of interest/financial disclosures:** The authors declare no financial disclosures/conflict of interest related to the present study.

**Funding agencies:** The authors declare no funding sources for the present study.

**Received:** 7 November 2020; **Revised:** 23 February 2021; **Accepted:** 26 February 2021

**Published online 7 May 2021 in Wiley Online Library (wileyonlinelibrary.com). DOI: 10.1002/mds.28565**

Yet, a parkinsonian phenotype is also a prominent feature in several syndromic conditions, whose genetic causes have been largely uncovered in recent years because of next generation sequencing efforts. Although many syndromic conditions follow an autosomal recessive pattern of inheritance, a growing number of disorders are being associated with pathogenic variants affecting genes that lie on the X chromosome. Following the classical rules of Mendelian genetics, X-linked disorders have long been considered to follow either a dominant or recessive inheritance. In X-linked dominant disorders, affected individuals are mainly heterozygous females, with hemizygous males showing a much more severe or even non-viable phenotype; conversely, in X-linked recessive disorders, hemizygous males are affected, whereas heterozygous females are either healthy carriers or show highly attenuated phenotypes. Yet, these classical Mendelian concepts have been challenged by recent observations, showing a much more complex scenario, with several X-linked disorders showing intermediate penetrance and variable expressivity in both males and females.<sup>2</sup> Mechanisms such as cell autonomous expression, skewed X-inactivation, clonal expansion, and somatic mosaicism play an important role in determining the clinical phenotype, making the standard definitions of X-linked recessive and dominant inheritance inadequate. Therefore, all such disorders should be simply described as following “X-linked” inheritance.

Here, we will review all known X-linked diseases in which parkinsonism is a relevant feature. These conditions represent a good model to highlight the phenotypic heterogeneity of parkinsonian syndromes and associated movement disorders. Furthermore, they also represent interesting examples of the genetic background and mechanisms of disease, ranging from point mutations in coding sequences to hexanucleotide intronic expansions. Finally, they provide useful insight into pathophysiologic mechanisms, which are advocated in the pathogenesis of idiopathic neurodegenerative diseases.

Table 1 provides a summary of the main characteristics of the syndromes described, and Table 2 illustrates the diagnostic red flags. Figure 1 shows the localization of the disease loci on the X chromosome and recapitulates the underlying pathophysiological mechanisms. Figure 2 is a schematic representation of X-linked parkinsonism’s gene products functions and localizations.

## X-Linked Dystonia-Parkinsonism: Intronic Repeat Expansion Disease Prevalent in Males

### Epidemiology

X-linked dystonia parkinsonism (XDP, OMIM 314250), also known as Lubag disease/DYT3, is an

inherited neurodegenerative condition characterized by a progressive parkinsonism along with dystonic features.

It was firstly described as endemic in the Panay Island in the Philippines, particularly in the region of Capiz.<sup>3</sup> Its estimated prevalence in the Panay Island is 4.77/100,000, dropping to 0.36/100,000 considering the whole country.<sup>4</sup> Most reported cases are males, but some female patients have also been reported, usually with later onset and milder forms of the disease (male:female ratio = 99:1). Cases of affected Filipinos have been reported also in other countries.<sup>5</sup>

### Clinical Features

Age of onset ranges from 12 to 75 years, being more common in the 4th decade for males and in the 5th for females.<sup>6</sup> The onset symptom is usually a focal dystonia, which can then progress to a segmental or generalized form, becoming the most prominent clinical feature. Dystonia often starts in the jaw then spreads to the neck, usually retrocollis. Other forms of craniocervical and upper limb dystonia may develop, but are rarely seen at onset.<sup>7</sup> Parkinsonism is usually characterized by asymmetric bradykinesia, tremor, rigidity, and peculiar gait disturbances.<sup>8-10</sup> Ocular movement abnormalities have also been described.<sup>11</sup> Other movement disorders have been reported, such as chorea, mainly involving the distal upper limbs, and action myoclonus of cortical origin. From the neuropsychological point of view, depression is a common feature,<sup>12</sup> and impulse control disorders (ICD) have been also reported.<sup>13</sup> Frontal executive dysfunction may be seen in some patients, but cognitive deterioration is unusual.<sup>14,15</sup> Females’ phenotype is usually milder, with prominent parkinsonism.<sup>6,16</sup>

### Neuroimaging

Striatal atrophy is the most common finding in neuroimaging studies of XDP patients. Recent studies have shown a strong involvement of regions with striatal connectivity.<sup>17,18</sup> Iron deposition in the putamen has also been reported.<sup>19</sup> On functional neuroimaging, there is evidence for both pre- and post-synaptic nigrostriatal degeneration in the majority of XDP patients.<sup>20</sup> Interestingly, the degree of post-synaptic degeneration correlated with disease duration.<sup>18</sup>

### Treatment

A better prognosis has been reported in those showing more prominent parkinsonian features over dystonia.<sup>9</sup> Parkinsonian features may show a good response to levodopa (L-dopa) and, peculiarly, XDP patients do not develop levodopa-induced dyskinesias (LIDs).<sup>5</sup> Focal dystonia can be successfully treated with botulinum toxin injections. Anticholinergics may be useful in the early stages, along with clonazepam. The predominantly phasic type of generalized dystonic movements may respond

**TABLE 1.** Summary of clinical, genetic, and pathophysiological findings in X-linked parkinsonism

Syndrome	Genetic background	Pathophysiological mechanism	Parkinsonism age of onset	Sex prevalence	MD phenotype	Additional features	Brain imaging	Dopaminergic imaging	Response to L-dopa	Neuropathology
XDP	TAF1 hexanucleotide expansion in SVA retrotransposon	Impaired transcription; LOF	Fourth to fifth decade (range 12–75 y)	M:F ratio 99:1	Progressive dystonia ad parkinsonism	Neuropsychological features (depression, ICD, executive dysfunction)	Striatal atrophy (++) cerebellar, frontal and temporal atrophy, WMNA, putaminal iron deposition	Pre- and postsynaptic dopaminergic deficit	Yes (good response also to GPI DBS)	Striatal synaptic loss and patchy gliosis
FXTAS	FMR1 CGG repeats in premutation range (55–200). Case reports also for grey zone <sup>40-55</sup>	Mitochondrial dysfunction; GOF	Seventh decade (range 30–80 y)	Both sexes, male prevalence	Classic parkinsonism, intention tremor, ataxia	Dysautonomia (erectile dysfunction ++), neuropathy, cognitive deterioration, sensitivity to neurotoxins	Medium cerebellar peduncle hyperintensity (MCP sign); cortical and vermian atrophy	Pre- and postsynaptic dopaminergic deficit in most of the cases	Yes (good response also to Vim DBS for tremor)	Protein and mRNA inclusion bodies; LBs in some parkinsonian cases
BPAN	WDR45 deletions, truncating and non-truncating single nucleotide variants	Disrupted autophagy, ER dysfunction; LOF	Third decade (range 15–37 y)	Female (F:M ratio 6:1)	Akinetic-rigid parkinsonism, rarely tremor	First stage of the disease in childhood with epilepsy, behavioral issues, and developmental delay	Iron deposition in SN and GP (not in infancy or early childhood), halo sign around SN	Pre-synaptic dopaminergic deficit	Yes, but early disabling fluctuations	Iron deposition, neuronal loss, axonal swelling, and gliosis in SN and GP. Mixed 3R and 4R tau pathology
Fabry disease	GLA missense and splicing variants	Lysosomal dysfunction; LOF	Fifth to eighth decade (range 46–72 y)	Both sexes, female prevalence	Akinetic-rigid parkinsonism	Cognitive impairment, proteinuria, acroparesthesia, cardiovascular and cerebrovascular disease, renal disease, and corneal opacity	Diffuse white matter abnormalities, increased susceptibility values in SN and striatum, SN volume loss	Pre-synaptic dopaminergic deficit	Mild-moderate, but early disabling fluctuations in some patients	Typical features of PD (SN neuronal loss, LBs)
Waisman syndrome	RAB39 deletions, truncating, and non-truncating single nucleotide variants	Vesicles trafficking impairment; LOF	Fifth decade, (range 12–62 y)	Strong male prevalence	Classic parkinsonism, preceded by postural tremor	From none to severe encephalopathy with epilepsy and ID	Calcification/iron deposition in SN, GP	Pre- and postsynaptic dopaminergic deficit (only 1 case)	Yes, but some cases with early disabling fluctuations	Typical features of PD (SN neuronal loss, LBs, and iron accumulation in the SN)
MeCP2 spectrum disorder	MECP2 missense variants	Impaired transcription in developing neurons; LOF	Second to third decade (range 11–50 y)	Only males	Classic parkinsonism, PSP-like picture in advanced disease	Psychiatric features (autism, psychotic disorders), ID, ASD, Pyramidal signs	Normal	DaTscan normal	No	—

(Continues)

TABLE 1. Continued

Syndrome	Genetic background	Pathophysiological mechanism	Parkinsonism age of onset	Sex prevalence	MD phenotype	Additional features	Brain imaging	Dopaminergic imaging	Response to L-dopa	Neuropathology
Phosphoglycerate kinase-1 deficiency	PGK1 missense variants	Metabolic insufficiency; LOF (enzyme residual activity 2–7%)	Third decade (range 10–30 s)	Only males	Classic parkinsonism with preceding postural tremor mild upper limbs dystonia	Infantile-onset encephalopathic and stroke-like episodes, hemolytic anemia, and epilepsy.	Normal. Rare features diffuse leukodystrophy and cerebellar atrophy	Postsynaptic dopaminergic deficit	Yes, but early fluctuations, psychosis	–
<b>XPDS</b>	ATP9A2 splicing site variants	Lysosomal dysfunction, LOF	Fourth to fifth decade (range 14–58 y)	Only males	Classic parkinsonism, spasticity	myopathy, ID ID, childhood onset epilepsy	Normal/mild cerebellar atrophy, thin corpus callosum	Postsynaptic dopaminergic deficit	Moderate	4R tauopathy, diffuse A-beta deposits, no LBS

Abbreviations: XDP, X-linked dystonia-parkinsonism; FXTAS, fragile-X associated tremor ataxia syndrome; BPAN, beta-propeller protein associated neurodegeneration; XPDS, X-linked parkinsonism with spasticity; LOF, loss of function; GOF, gain of function; ID, intellectual disability; ICD, impulsive compulsive disorders; LB, Lewy bodies; SN, substantia nigra; GP, globus pallidus; PD, Parkinson's disease.

dramatically to zolpidem or tetrabenazine.<sup>5</sup> Bilateral deep brain stimulation (DBS) of the internal globus pallidus (GPi) has been reported as effective on both dystonic and parkinsonian features in some male patients.<sup>21-24</sup>

### Neuropathology

Striatal synaptic loss and patchy gliosis, involving more the caudate than the putamen, have been described. Both the internal and external globus pallidus (GP) were affected.<sup>5,25</sup> More specifically, Goto et al<sup>26</sup> found a neostriatal defect of the neuropeptide Y system, which is implicated in modulation of neurogenesis and neurotransmitter release.

### Genetic Background and Pathophysiology

The identification of the genetic background of XDP has been truly challenging. Although it was soon established that all symptomatic individuals shared the same haplotype across the DYT3 locus, subsequent sequencing analysis of the only gene contained within the locus (*TAF1*) has long proven unsuccessful, resulting only in a handful of variants of doubtful pathogenicity.<sup>28</sup> Only recently, because of a combined approach of short- and long-read genomic sequencing and transcriptome sequencing in induced pluripotent stem cells (iPSCs)-derived neuronal cells from XDP patients, the molecular culprit was found to be a polymorphic variation of a hexanucleotide repeat (CCCTCT) within a SINE-VNTR-Alu (SVA) retrotransposon inserted within an intron of the *TAF1* gene.<sup>27</sup> The expansion varies from 35 to 52 repeats, whose length was shown to influence the ability of the SVA to regulate transcription and correlated inversely with age at disease onset.<sup>28</sup> This observation has been replicated by Westenberger et al<sup>29</sup> who also speculated that the hexamer length could influence the phenotype, with prominent dystonic versus parkinsonian features, and the severity of the disease. However, the pathogenesis of the disease remains unclear. *TAF1* encodes the TATA-binding protein (TBP)-associated factor-1 (TAF1), a core subunit of the transcription factor II D (TFIID) complex, which is part of the general transcriptional machinery. It seems that the hexanucleotide expansion causes a reduction of TAF1 expression, but there are conflicting data on which of its many tissue-specific transcripts are more affected.<sup>27,30</sup>

## Fragile-X Associated Tremor Ataxia Syndrome: Premutation of a Repeat Expansion Disease with Manifestations in both Sexes

### Epidemiology

Fragile-X-associated tremor ataxia syndrome (FXTAS, OMIM 300623) is a late onset neurodegenerative disorder affecting carriers of the cytosine guanine guanine (CGG)

**TABLE 2.** Diagnostic red flags for each disease

Syndrome	Diagnostic red flags
XDP	<ul style="list-style-type: none"> <li>• Combination with dystonia</li> <li>• Philipino ethnicity</li> <li>• Male sex</li> <li>• Young onset</li> </ul>
FXTAS	<ul style="list-style-type: none"> <li>• Combination with ataxia and/or action tremor</li> <li>• Family or personal history of premature ovarian failure, cognitive impairment, and neuropsychological disorders</li> <li>• MCP sign at brain MRI</li> </ul>
BPAN	<ul style="list-style-type: none"> <li>• Childhood onset of epilepsy and/or behavioral issues</li> <li>• Developmental delay</li> <li>• Female sex</li> <li>• Early adulthood onset</li> </ul>
Fabry disease	<ul style="list-style-type: none"> <li>• Family or personal history of proteinuria, acroparesthesia, cardiovascular and cerebrovascular disease, renal disease, and corneal opacity</li> </ul>
Waisman syndrome	<ul style="list-style-type: none"> <li>• Calcification/iron deposition in SN, GP at brain MRI</li> <li>• Male sex</li> <li>• Combination with ID</li> </ul>
MeCP2 spectrum disorder	<ul style="list-style-type: none"> <li>• Combination with ASD, ID, psychiatric features</li> <li>• Male sex</li> <li>• Juvenile onset</li> </ul>
Phosphoglycerate kinase-1 deficiency	<ul style="list-style-type: none"> <li>• Combination with stroke-like episodes epilepsy, hemolytic anemia, myopathy, and ID</li> <li>• Young onset</li> <li>• Early LIDs and psychosis</li> </ul>
XPDS	<ul style="list-style-type: none"> <li>• Combination with spasticity, ID, and epilepsy</li> <li>• Male sex</li> </ul>

Abbreviations: XDP, X-linked dystonia-parkinsonism; FXTAS, fragile-X associated tremor ataxia syndrome; BPAN, beta-propeller protein associated neurodegeneration; XPDS, X-linked parkinsonism with spasticity; LID, levodopa induced dyskinesias; ID, intellectual disability; ASD, autism spectrum disorders; SN, substantia nigra; GP, globus pallidus.

repeat expansion in the fragile X mental retardation 1 (*FMR1*) gene within the premutation range (55–200 repeats).<sup>31</sup> *FMR1* premutation is also associated with other clinical entities, such as fragile X-associated primary ovarian insufficiency (FXPOI) and fragile X-associated neuropsychiatric disorders (FXAND), including attention deficit hyperactivity disorder (ADHD), autism spectrum disorders (ASD), depression, and anxiety.<sup>32,33</sup> The prevalence of this premutation in the general population has been estimated to be approximately 1:150–300 females and 1:400–850 males, with some geographical differences.<sup>31</sup>

### Clinical Presentation

Onset of FXTAS usually occurs in the 6th to 7th decade, but cases with earlier onset have been

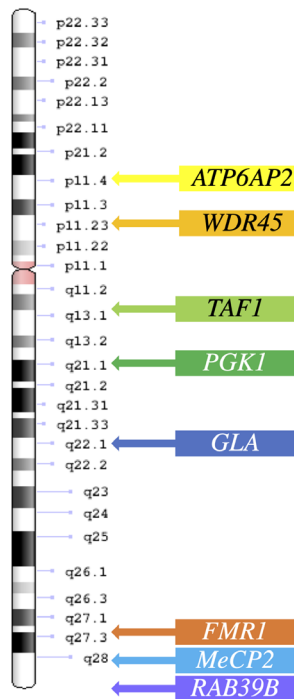
described.<sup>34</sup> Parkinsonian features has been detected in approximately 29% to 60% of FXTAS patients, with bradykinesia reported in almost 50% and rest tremor in 30% to 40%, usually in later stages and in combination with a postural or intentional component.<sup>35</sup> Even if overt parkinsonism is usually diagnosed in the seventh decade, a study on young asymptomatic subjects carrying the CGG expansion premutation demonstrated subclinical but significant motor impairment, with longer manual movement and reaction times.<sup>36</sup> Sometimes the clinical picture resembles that of idiopathic PD, mostly when the repeat expansion is in the lower premutation range on in the so-called “gray zone” (40–55 CGG repeats), and especially in females.<sup>37–43</sup> However, isolated parkinsonism is rare, and the clinical picture is usually more complex, with associated cerebellar features, autonomic dysfunction, peripheral neuropathy, depression, thyroid problems, and cognitive issues.<sup>31,44,45</sup> Ataxia is almost invariably present in males with FXTAS, whereas it is rarer in female subjects. It is progressive with high risk of falling within ~4 years from onset.<sup>46</sup> Intention tremor is seen in 64% to 88% of patients.<sup>44,47</sup> Eye movement abnormalities have been described, including impaired optokinetic nystagmus in the vertical direction, slowing of vertical saccades, saccadic pursuits, and square wave jerks. Cognitive dysfunction is common in later stages. A subcortical frontal executive impairment is the most common pattern along with verbal dysfluency.<sup>44,48</sup> Neuropathy can precede the motor disturbances, and patients usually show diminished distal reflexes and reduced vibratory sensation of which they are rarely aware of.<sup>46</sup> Vestibular dysfunction is also an early feature, with patients complaining of dizziness and vertigo.<sup>31,44</sup> On the other hand, hearing and olfactory deficits have been described in later stages.<sup>31</sup> Erectile dysfunction is by far the most common autonomic symptom, present in more than half patients, but bladder symptoms and orthostatic hypotension are also reported.<sup>31,35</sup> REM sleep behavior disorders and restless leg syndrome are more frequent than in the general population, being found in ~16% of patients.<sup>44</sup>

### Neuroimaging

The hallmark radiological sign of FXTAS is an increased signal on a T<sub>2</sub> flair magnetic resonance imaging (MRI) sequence in cerebral white matter especially on the middle cerebellar peduncles, the so-called “MCP sign”.<sup>49,50</sup> It is highly specific but it is seen in only 50% to 60% of male patients and is rarely seen in women. Moderate to severe cortical atrophy with increased ventricular volumes is seen in both genders, as well as vermian atrophy.<sup>51,52</sup>

Dopaminergic transporter single-photon emission computerized tomography (SPECT) imaging studies

Chromosome X



<p><b>ATP6AP2</b> encodes an accessory unit of vacuolar ATPase (V-ATPase), an essential lysosomal enzyme required for lysosomal degradative functions and autophagy. Splicing site variants described, with altered synthesis of functional protein.</p>
<p><b>WDR45</b> encodes WIPI-4 (WD repeat domain phospho-inositide-interacting protein-4) which is part of the WD40 repeat protein family. They are WD (tryptophan and an aspartic acid) repeat-containing protein which regulate the assembly of multiprotein complexes by presenting a beta-propeller platform for simultaneous and reversible protein-protein interactions. WIPI4 has a 7-bladed propeller structure and contain a conserved motif for interaction with phospholipids, playing a role in autophagy processes. Frameshift, nonsense and missense puntiform variants, splicing variants and deletions lead to reduction or loss of protein expression, leading to neurodegeneration through increased early autophagic products, defective autophagy and consequent endoplasmic reticulum stress.</p>
<p><b>TAF1</b> encodes TATA- binding protein (TBP)-Associated Factor-1, part of transcriptional machinery, role in neuronal development; Hexanucleotide repeat expansion in intronic retrotransposon SVA (35-52 repeats), resulting in splicing abnormality proximal to the SVA insertion site, with production of truncated transcripts.</p>
<p><b>PGK1</b> encodes phosphoglycerate kinase 1, a key enzyme in glycolytic pathway. Missense variants which result in significantly lower catalytic enzyme activity, with consequent metabolic abnormalities in several tissues, including brain.</p>
<p><b>GLA</b> encodes <math>\alpha</math>-galactosidase, a lysosomal hydrolase involved in the catabolism of ceramides. Deletions and missense, nonsense and splicing variants and in this gene are associated to a certain degree of reduction of <math>\alpha</math>-galactosidase enzymatic activity. Therefore, sphingolipids accumulate in cells. The lysosomal dysfunction could predispose to developing a synuclein pathology, although the mechanism is not clear yet.</p>
<p><b>FMR1</b> encodes FMRP, an RNA-binding protein that forms a messenger ribonucleoprotein complex that associates with polyribosomes, suggesting that it is involved in translation. Trinucleotide repeat expansion in coding region (55-200 copies). In the premutation repeat range, gain of function pathogenic mechanism, with up to 6-fold increased RNA production, which: 1. Impairs cellule function because of accumulation and sequestration of proteins in inclusion bodies 2. Damages DNA with R-loop formation 3. Interferes with protein synthesis (RAN translation)</p>
<p><b>MeCP2</b> encodes Methyl CpG-binding Protein 2, a chromatin-associated protein that can both activate and repress transcription. It is required for maturation of neurons and is developmentally regulated. Missense variants associated with some residual function of MECP2</p>
<p><b>RAB39B</b> encodes Ras analogue in Brain 39b, a small GTPase responsible for the control of intracellular vesicular trafficking in neuronal cells. Frameshift, nonsense and missense puntiform variants and deletions bring to complete loss of protein expression. Two silent variants described associated to reduction of protein expression and abnormal localization.</p>

FIG. 1. Genes localization on the X chromosome and insights on gene functions and related disease pathophysiology. [Color figure can be viewed at wileyonlinelibrary.com]

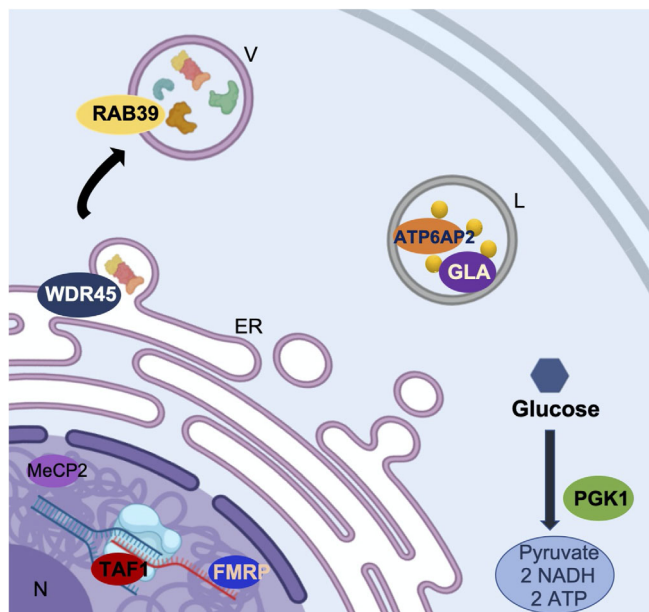


FIG. 2. Schematic representation of X-linked parkinsonism's gene products functions and localizations: MeCP2 (MeCP2 spectrum disorders) encodes a chromatin-associated protein, TAF1 (XDP) is part of the transcriptional machinery, FMRP (FXTAS) is a mRNA binding protein, WDR45 (BPAN) regulates the assembly of multiprotein complexes, RAB39 (Waisman syndrome) is responsible for intracellular vesicular trafficking, PGK1 (PGK1 deficiency syndrome) is a glycolysis enzyme and ATP6AP2 (XPDS) and GLA (Fabry's disease) are lysosomal enzymes. L, lysosome; V, vesicle; ER, endoplasmic reticulum; N, nucleus. (Created with BioRender.com). [Color figure can be viewed at wileyonlinelibrary.com]

usually show evidence of nigrostriatal degeneration in FXTAS cases with parkinsonism.<sup>53</sup> In one case, also a post-synaptic dopaminergic deficit was demonstrated.<sup>54</sup> However, few cases with normal findings at SPECT with (123)I]FP-CIT have also been described.<sup>55</sup>

Treatment

Parkinsonism is usually slowly progressive and has a good response to dopamine-replacement therapy, whereas ataxia and intention tremor have a worse impact on patients' quality of life. Primidone or beta blockers can be used for the tremor and selective serotonin-receptor blockers (SSRIs) for irritability or depression. Vento-intermediate thalamic nucleus (Vim) DBS usually provides mild improvement in the tremor but frequent side effects on gait and postural stability are reported.<sup>44</sup> Interestingly, environmental toxins, such as drugs, general anesthesia, or chemotherapy, can exacerbate the symptoms of FXTAS.<sup>50,56,57</sup>

Neuropathology

Pathological findings from a cohort of 40 subjects with FXTAS showed synuclein and Lewy bodies (LB) pathology in 10% of the cases, of whom two had been diagnosed with PD earlier in life.<sup>37</sup> Furthermore, a presynaptic dopaminergic loss was demonstrated in all cases diagnosed with parkinsonism. Furthermore, high

levels of extracellular or intracellular iron deposits within capillaries and parenchyma of the striatum and, to a lesser extent, the cerebellum have been reported.<sup>58,59</sup> This evidence suggests that the CGG expansion premutation predispose to neurodegeneration through autophagy and protein scavenging impairment.

### Genetic Background and Pathophysiology

FMR1 premutation disorders are associated with a gain-of-function mechanism, resulting in an increase up to eightfold in mRNA production, which is believed to exert deleterious effects in several ways.<sup>60,61</sup> First, the sequestration of proteins and RNAs into inclusion bodies leads to impaired cell function because of loss of these RNA and protein species. Furthermore, excess mRNA leads to DNA damage through R-loop formation, a three-stranded nucleic acid structure, composed of a DNA:RNA hybrid and the associated non-template single-stranded DNA. Finally, regions of mRNA containing the triplet repeat are prone to errors in translation. They interfere with protein synthesis, which can be initiated outside of the traditional AUG start codon, leading to the production of toxic FMR polyG protein. This mechanism is called repeat-associated non-ATG (RAN) translation and is a common feature in triplet repeat expansion disorders.<sup>60</sup> However, whether RAN translation is a central driver of pathogenesis remains unclear. Indeed, Ma et al<sup>62</sup> detected RAN translation products in human FXTAS brain tissue, but in very low abundance and outside FXTAS inclusion bodies.

Another pathophysiological hypothesis sees the mitochondrial dysfunction consequent to elevated mRNA and  $Ca^{+2}$  levels responsible for neurodegeneration in FXTAS.<sup>63</sup> Mitochondrial dysfunction might facilitate the development of conditions such as parkinsonism and extracellular deposition of iron in the striatum.<sup>64-66</sup>

## Beta-Propeller Protein-Associated Neurodegeneration: X-Linked Disorder Prevalent in Females

### Epidemiology

Beta-propeller protein-associated neurodegeneration (BPAN, OMIM 300894), previously called static encephalopathy of childhood with neurodegeneration in adulthood (SENDA) and also known as neurodegeneration with brain iron accumulation 5 (NBIA5), is a rare neurological disorder characterized by early onset seizures, developmental delay, and behavioral issues followed by a later onset progressive dystonia-parkinsonism (mean age 25 years, range 15–37 years). Its prevalence is not known, but it is a rare disorder with <100 cases described. The majority

of patients are female, although few male cases have been reported (F:M ratio  $\cong$  6:1).<sup>67,68</sup>

### Clinical Presentation

BPAN is characterized by a two-stage disease course.<sup>69</sup> Although symptom onset is in childhood, the mean age at diagnosis is in early adulthood.<sup>70</sup> The first phase of the disease, in childhood, is characterized by developmental delay of variable degree, followed by intellectual disability with predominant verbal impairment but also poor coordination, both in fine and gross motor skills.<sup>71</sup> Epilepsy with seizures triggered by fever is also common. It is often initially drug-resistant but tends to become less difficult to treat or even to completely resolve after puberty.<sup>72</sup> Abnormal behaviors similar to those seen in Rett syndrome are also described.<sup>72-74</sup> Other features include abnormal sleep patterns and ophthalmological findings, such as bilateral partial retinal colobomas, myopia, spontaneous retinal detachment, and bilateral optic atrophy.<sup>72</sup> During adolescence or early adulthood, patients experience a neurologic deterioration with movement disorders and cognitive decline.<sup>67,75</sup> Subjects usually show a rigid-akinetic parkinsonism with gait and postural impairment along with upper limb dystonia.<sup>72</sup> The severity of the clinical manifestations can vary. Factors such as a skewed X-inactivation in females, a somatic mosaicism or the variable pathogenic impact of the carried variant are thought to play a major role.<sup>67</sup>

### Neuroimaging

In most of the adult patients (>90%), brain MRI shows iron deposition in the basal ganglia.<sup>70,76</sup> Interestingly, iron deposition seems more prominent in the SN as compared to the GP, which may help in differentiating it from other NBIA5.<sup>77</sup> Another radiological finding, which is considered pathognomonic for BPAN is a hyperintense halo surrounding the SN with a central hypointense band on T<sub>1</sub>-weighted images.<sup>76,77</sup>

Less data is available on the imaging features of pediatric patients, in the earlier stages of the disease. Delayed myelination has been reported, but the most characteristic feature is a transient swelling and T<sub>2</sub>-hyperintensity of GP, SN, and dentate nuclei, usually after febrile seizures.<sup>78,79</sup> Kimura et al<sup>80</sup> also described a persistent hyperintensity in T<sub>2</sub>-weighted images of the deep cerebellar nuclei in three of their patients. Iron deposition is not common but has been also reported in childhood, the youngest patients being a 3-year-old child.<sup>81</sup> In the few cases where a DaTscan is reported, a presynaptic dopaminergic deficit was demonstrated.<sup>82,83</sup>

## Treatment

Parkinsonism in the early stages responds dramatically to dopaminergic treatment. However, disabling motor fluctuations and dyskinesias usually appear shortly after therapy initiation. Dystonia and spasticity may be treated with benzodiazepines, especially clonazepam, botulinum toxin injections, or intrathecal baclofen. Anticholinergics may be considered initially but could worsen cognitive functions at later stages.

## Neuropathology

Neuropathological findings confirmed the major involvement of substantia nigra (SN) and GP, with iron deposition and neuronal loss, axonal swelling, and gliosis.<sup>72,84</sup> Interestingly, a diffuse tau pathology was also demonstrated, with neuropil threads, pre-tangles, and neurofibrillary tangles. An Alzheimer's-like tau pattern with the classical triplet band because of mixed 3R- and 4R-tau isoforms was found at immunoblotting. An increase in LC3-II levels, the end product of LC3-I conversion during autophagy, was detected, supporting the hypothesis of an impaired autophagic process because of the *WDR45* mutation.<sup>84</sup> There is no evidence for synuclein pathology, which distinguish BPAN from other NBIAAs such as PLA2G6 and mitochondrial membrane protein-associated neurodegeneration (MPAN).

## Genetic Background and Pathophysiology

In 2012, variants in the *WDR45* gene were found in BPAN patients.<sup>85,86</sup> The vast majority of cases are because of de novo pathogenic variants, with only two cases reported with maternal inheritance.<sup>87,88</sup> *WDR45* encodes WD repeat domain phosphoinositide-interacting protein-4 (WIPI-4), which is part of the WD40 repeat protein family and plays a role in autophagy.<sup>89,90</sup> Indeed, patients have lower autophagic activity.<sup>85</sup> Recently, endoplasmic reticulum (ER) dysfunction has been proposed as pathophysiological mechanism for BPAN, because a mouse model showed increased ER stress leading to neuronal apoptosis.<sup>91,92</sup>

## Fabry Disease: Missense Variants with Loss-of-Function Mechanism

### Epidemiology

Fabry disease (FD, OMIM 301500) is an X-linked inborn error of glycosphingolipid catabolism resulting from deficient or absent activity of the lysosomal enzyme alpha-galactosidase A, because of variants in the *GLA* gene.<sup>93</sup> Its prevalence is estimated to be 1–5/10,000. Only a small proportion of these patients are diagnosed with parkinsonism, around 1.3% to 2.2% of the total cases, with higher incidence in older

age. Fabry disease manifests in both hemizygous males and heterozygous females, with high clinical variability, milder phenotypes and longer survival in the latter. Therefore, among older FD patients, female sex is more prevalent.

## Clinical Presentation

The age of onset of parkinsonian features ranges from 46 to 72 years. The nine cases reported show a classic akinetic-rigid parkinsonism, alone or with cognitive deterioration, and associated with the classical manifestations of the disease, such as proteinuria, acroparesthesia, cardiovascular and cerebrovascular disease, renal disease, and corneal opacity.<sup>94-98</sup>

## Neuroimaging

Diffuse white matter hyperintensities are the most common feature in MRI scans of FD patients.<sup>94,98,99</sup> A recent study also demonstrated an increase in susceptibility values of the SN and striatum in susceptibility weighted imaging (SWI) sequences, coupled to a reduced volume of the SN only.<sup>99</sup> A presynaptic dopaminergic deficit has been demonstrated in those who underwent a functional dopaminergic imaging, either a DaTscan or a fluorodopa positron emission tomography (PET) scan.<sup>94,97</sup>

## Treatment

Parkinsonian features show a mild to moderate response to treatment with L-dopa. Some patients may experience early and disabling L-dopa induced dyskinesias.<sup>94,95,97</sup>

## Neuropathology

Pathology data is available for only one case of FD with parkinsonism.<sup>96</sup> Authors demonstrated a severe neuronal loss in the SN pars compacta as well as the presence of LBs, which were not found in a FD patient without parkinsonism. Major cerebrovascular lesions and/or additional pathologies were absent. These findings are also supported by the observation of synuclein pathology in a mouse model of FD.<sup>100</sup>

## Genetic Background and Pathophysiology

*GLA* encodes  $\alpha$ -galactosidase, a lysosomal hydrolase involved in the catabolism of ceramides. Deletions and single nucleotide variants (including missense, nonsense, and splicing variants) in this gene are associated with a variable reduction of  $\alpha$ -galactosidase enzymatic activity. Therefore, sphingolipids accumulate in cells causing multi-systemic effects with neuronal, renal, cardiac, and vascular involvement. Interestingly,  $\alpha$ -galactosidase activity was found reduced also in a cohort of PD patients.<sup>101,102</sup> A correlation between  $\alpha$ -galactosidase



residual activity and  $\alpha$ -synuclein deposits was also found.<sup>103</sup> Therefore, the lysosomal dysfunction seen in FD could predispose those patients to develop a synuclein-positive parkinsonism in late adulthood.<sup>104</sup>

## Waisman Syndrome: Single Nucleotide Variants With Phenotypic Variability Mainly in Males

### Epidemiology

Ras analog in brain 39B (*RAB39B*) pathogenic variants are associated with a rare syndrome characterized by X-linked intellectual disability (XLID) and parkinsonism known as Waisman syndrome (OMIM 311510). The first kindred were described in 1985 and only 4 families and 5 sporadic cases have been described to date.<sup>105-111</sup> Of these, only two are females.<sup>109</sup> There are also two cases with only XLID reported in literature.<sup>112,113</sup>

### Clinical Presentation

Patients with Waisman syndrome usually present with variable degrees of intellectual disability (ID) in childhood followed by parkinsonian features later in life. Parkinsonism onset ranges from 12 to 62 years, being more frequent in the 5th decade of life.<sup>106-111</sup> Parkinsonian features are clinically typical, sometimes preceded by a longstanding postural tremor.<sup>106,108</sup> In few cases early gait disturbances have been reported. ID is frequent in male patients and usually shows a fronto-subcortical involvement pattern.<sup>108,110</sup> Few cases have been described with neuropsychiatric manifestations, but only one later developed a parkinsonian condition.<sup>108,112,113</sup> In females, the phenotype seems milder, with later age of onset and no reported ID.<sup>109</sup>

### Neuroimaging

Brain MRI often shows a strong hypointense signal in SN and globus pallidum detectable on gradient-echo (GRE) or SWI sequences. Computed tomography (CT) scans revealed in the majority of the cases high density calcifications in the same regions.<sup>107,108</sup> However, in fewer cases the CT was normal, therefore indicating iron deposits as most likely.<sup>106,108,111</sup> Some author also reported normal neuroimaging findings.<sup>106,110</sup> Functional imaging of the dopaminergic system was performed in only one patient and showed pre- and postsynaptic dopaminergic deficits as shown by DaTscan and IBZM-SPECT.<sup>111</sup>

### Treatment

Overall, a good response to L-dopa has been reported in the majority of the cases. However, some patients developed early treatment-related

complications, including motor fluctuations, dyskinesia, and limb dystonia.<sup>107-111</sup>

### Neuropathology

The neuropathology associated with this genetic form of parkinsonism is characterized by the typical features of PD. SN sections revealed loss of pigmented neurons and LBs in surviving neurons, along with tau-immunoreactive neurofibrillary tangles (NFTs). LBs were also abundant in cortical regions.<sup>106,114</sup>

### Genetic Background and Pathophysiology

*RAB39B*, a member of the RAS oncogene family, consists of 2 exons located on the chromosome Xq28. Rab39B is responsible for the control of intracellular vesicular trafficking in neuronal cells and its downregulation results in dysregulation of  $\alpha$ -synuclein homeostasis.<sup>106</sup> However, in the early stages of brain development, its downregulation seems to alter neuronal differentiation and disturb neurite growth.<sup>112</sup> Clear genotype-phenotype correlates were not reported, however, a residual protein expression seem to be associated with milder phenotypes.<sup>106-111,115</sup>

## Methyl CpG-binding Protein 2 Spectrum Disorders: Milder Variants Associated With Parkinsonism in Males

### Epidemiology

Methyl CpG-binding protein 2 (MeCP2) deficiency is associated with a spectrum of clinical phenotypes. In females it ranges from the classic Rett syndrome (RTT, OMIM 312750), a neurodevelopmental disorder characterized by a phase of normal development followed by the progressive loss of milestones and cognitive abilities, to variant RTT, which can be either milder or more severe, to a phenotype of mild learning disabilities. In males, the spectrum includes severe neonatal encephalopathy, severe syndromic/non-syndromic intellectual disability, as well as a condition associating pyramidal signs, parkinsonism, and macroorchidism (PPM-X syndrome).<sup>116</sup> MeCP2 deficiency accounts for 1.3% to 1.7% of the male cases of ID, but it is a very rare cause of X-linked parkinsonism, as only 11 male cases have been reported to date.<sup>117-122</sup> Age of onset of parkinsonian features ranges from the second to the fifth decade, with a peak in early adulthood.<sup>119</sup>

### Clinical Presentation

Parkinsonism in MeCP2 deficiency is usually a parkinsonism-plus syndrome. Among parkinsonian features, tremor is widely represented, and it is often the

first sign. Bradykinesia, gait disturbances, and stopped posture usually follow. Other features such as distal jerks, dystonic posturing, brisk reflexes, and vertical gaze palsy have been reported.<sup>119</sup> Concomitant PPM-X was described in first reports.<sup>121</sup> Some degree of neurodevelopmental delay or ID has been frequently described.<sup>119-122</sup> Neuropsychiatric features such as bipolar disorders, catatonia, and ASD have also been described.<sup>119,121,122</sup> Obligate female carriers are mildly symptomatic, with either a mild intellectual disability or slight non-progressive resting tremor.<sup>118,120,122</sup>

### Neuroimaging

Normal neuroimaging is reported by different authors.<sup>118,119,122</sup> Pollini et al<sup>119</sup> also described normal findings at DaTscan.

### Treatment

Parkinsonian features are reported to be non-responsive to L-dopa,<sup>119</sup> whereas treatment of the other manifestations is mainly symptomatic.<sup>116,123</sup>

### Genetic Background and Pathophysiology

MeCP2 is a CpGs-binding transcription factor involved in neuronal maturation and is dynamically regulated during neurodevelopment. Variants found in males with parkinsonism are thought to be associated with some residual function of MeCP2. For example, the missense variant c.419C>T (p.Ala140Val) is located in the middle of the  $\alpha$ -helix and appears to shorten the  $\alpha$ -helix length by half, altering the wedge-shaped structure of the methyl-CpG binding domain, with only a subtle effect on MeCP2 function.<sup>120</sup>

## Phosphoglycerate Kinase-1 Deficiency: X-Linked Recessive Metabolic Disease With Phenotypic Variability in Males

### Epidemiology

Phosphoglycerate kinase-1 (PGK1) deficiency (OMIM 300653) was first described in 1968 as a rare cause of non-spherocytic hemolytic anemia.<sup>124</sup> Since that report, nearly 33 families and few sporadic cases have been described.<sup>125</sup> PGK1 deficiency usually presents in males with manifestation involving erythrocytes, skeletal muscles, central nervous system (CNS) or a combination of these.<sup>126</sup> Among CNS manifestations, developmental delay, epilepsy and encephalopathic episodes are most common. To date, eight male cases of parkinsonism associated with PGK1 deficiency have been reported.<sup>127-130</sup>

### Clinical Presentation

The age of onset of neurological signs is the first or second decade of life, most commonly with intention and then rest tremor. An overt parkinsonism develops, with a slowly progressive global bradykinesia, along with rigidity and postural and gait disturbances. Mild dystonic features involving the upper limbs have been described, while no cerebellar or pyramidal signs have been reported.<sup>127,130</sup> A mild developmental delay is common. Frequently, a myopathy precedes or comes along with the extrapyramidal features.<sup>128,129</sup> In other cases, epilepsy and encephalopathic episodes are seen. Hemolytic anemia and myoglobinuria are almost invariably seen in those patients from infancy or childhood.<sup>130</sup>

### Neuroimaging

MRI scan of the brain is reported to be normal in most of the cases. Only Sakaue et al reported a mild cerebellar and pontine atrophy.<sup>129</sup> All subjects who underwent a functional dopaminergic imaging showed a bilateral presynaptic deficit.<sup>129,130</sup>

### Treatment

The response to dopaminergic treatment is usually good from the motor perspective. However, patients may develop psychosis and severe ICD.<sup>128,130</sup> Severe L-dopa-induced dyskinesias were also reported in a patient.<sup>130</sup>

### Genetic Background and Pathophysiology

*PGK1* encodes phosphoglycerate-kinase-1, a key enzyme in the glycolytic pathway, which has a ubiquitous expression. The reported variants are mainly missense variants that result in significantly lower catalytic enzyme activity. Red blood cells PGK1 residual activity in these patients is between 2% and 6%.<sup>130</sup> A clear correlation between the residual enzymatic activity and the clinical has not been demonstrated. However, a recent study supported the hypothesis that the level of impairment of the glycolytic pathway is a major determinant of the phenotype.<sup>131</sup>

## X-linked Parkinsonism and Spasticity: Variants Affecting Splicing

### Epidemiology

Hemizygous mutations of *ATP6AP2* are associated with X-linked syndromic mental retardation of Hedera-type (MRXSH), X-linked spasticity-parkinsonism (XPDS, OMIM 300911) and congenital disorder of glycosylation, type IIr (CDG2R).<sup>132-134</sup> XPDS is a very rare condition, with only seven males from two kindred reported to date.<sup>135,136</sup>

## Clinical Presentation

Age at onset ranges from 14 to 58 years. The two cases with later onset showed a pure parkinsonian syndrome. On the other hand, those with an earlier onset had a complex phenotype with combination of spasticity (scissoring gait, brisk reflexes) and parkinsonian features, namely bradykinesia, tremor, rigidity, shuffling gait, and postural instability. In one case, severe developmental delay and epilepsy were also reported.<sup>135</sup>

## Neuroimaging

Normal findings at neuroimaging studies have been reported in all cases from Poorkaj et al<sup>136</sup> and Gupta et al<sup>135</sup> described mild cerebellar atrophy and thick corpus callosum, the last one being present in only the more severely affected patient. A fluorodopa PET scan was performed in one patient and showed a bilateral asymmetric reduction in tracer uptake in the putamina.<sup>136</sup>

## Treatment

Parkinsonian features show a moderate response to dopaminergic medications.

## Neuropathology

Neuropathology was performed in one mildly affected individual.<sup>136</sup> Overall, findings showed a 4R tauopathy, with tau and glial fibrillary acid protein (GFAP) immunopositive plaques mainly located in the striatum. Diffuse A-beta deposits were observed in the neocortex and limbic system.

## Genetic Background and Pathophysiology

*ATP6AP2* on Xp11.4 encodes an accessory unit of vacuolar ATPase (V-ATPase), an essential lysosomal enzyme expressed in different organs. The V-ATPase is required for lysosomal degradative functions and autophagy. Impairment in these processes is frequently seen in PD and could therefore be implicated in the pathogenesis of the parkinsonian condition seen in XPDS.<sup>133</sup> Interestingly, all known variants causative of XPDS and MRXSH phenotypes were found to alter the correct splicing of the gene, resulting in the variable expression of abnormal isoforms along with some residual wild-type protein. This observation could explain on the one hand the marked differences in age of onset and manifestations seen among patients, on the other hand could suggest that a complete loss of function could be lethal in males, as also confirmed by several *in vivo* models.<sup>137</sup>

## Discussion and Conclusion

X-linked parkinsonian syndromes represent a heterogeneous group of syndromes with age of onset ranging from childhood to older age and huge phenotypic variability. Different pathophysiological pathways are involved, highlighting how different routes can converge to a parkinsonian phenotype. On the other hand, few common characteristics can be outlined. From the clinical-epidemiological point of view, even if female cases are reported, these conditions are prevalent in males. Furthermore, a pure parkinsonian phenotype is rare, and parkinsonian features are usually associated with neuropsychiatric and cognitive manifestations or also in combination with other movement disorders such as ataxia, dystonia, or action tremor. With regards to the pathophysiology underlying these diseases, in most of them there is evidence of abnormal nigrostriatal dopaminergic imaging. Indeed, this finding is in line with the known major role of basal ganglia in the pathophysiology of parkinsonism.

The genetic background is various, ranging from point mutations in coding sequences that disrupt protein expression to triplet expansions that enhance gene transcription, to intronic variants or expansions that impact on splicing or gene expression. Yet, some gene products are involved in the same cellular processes. For example, *GLA* and *ATP6AP2* pathogenic variants are both associated with altered lysosomal activity whereas *TAF1*, *MeCP2*, and *FMRP* have a nuclear localization and are involved in translational and transcriptional processes. Pathophysiological mechanisms revealed by these rare diseases could offer insights and be used as models for those seen in PD, where neurodegenerative pathways such as lysosomal storage and autophagy disruption, mitochondrial dysfunction and abnormal protein accumulation have been advocated.

Furthermore, awareness of these rare conditions and their way of inheritance is essential for a prompt recognition, which bears major implications in terms of familial planning and of patients care. For example, among the parkinsonisms with juvenile or early adulthood onset, some have a good response to dopaminergic treatment, whereas others present high risks of severe side effects. On the other side of the spectrum, it is important to consider X-linked conditions in older patients with parkinsonian manifestations and suggestive MRI findings, comorbidity or family history, to offer proper genetic counselling to the family. Finally, recent advances in genetic therapy may allow patients with a specific genetic diagnosis to become eligible for targeted treatments in the next future.

## Financial Disclosures

### Ethical Compliance Statement

The authors confirm that the approval of an institutional review board was not required for this work. We

confirm that we have read the Journal's position on issues involved in ethical publication and affirm that this work is consistent with those guidelines.

### Funding Sources and Conflicts of Interest

The authors report no sources of funding and no conflicts of interest.

## References

- Lunati A, Lesage S, Brice A. The genetic landscape of Parkinson's disease. *Rev Neurol (Paris)* 2018;174(9):628–643.
- Dobyns WB, Filauo A, Tomson BN, et al. Inheritance of most X-linked traits is not dominant or recessive, just X-linked. *Am J Med Genet* 2004;129A(2):136–143.
- Lee LV, Pascasio FM, Fuentes FD, Viterbo GH. Torsion dystonia in Panay, Philippines. *Adv Neurol* 1976;14:137–151.
- Lee LV, Munoz EL, Tan T, Reyes MT. Reviews sex linked recessive dystonia Parkinsonism of Panay, Philippines (XDP). *J Clin Pathol: Mol Pathol* 2001;54:362–368.
- Evidente VGH. X-linked dystonia-Parkinsonism. In: Adam MP, Ardinger HH, Pagon RA, et al., eds. *GeneReviews®*. Seattle, WA: University of Washington; 2019:1993–2020.
- Evidente VGH, Nolte D, Niemann S, Mayo MC, Natividad FF, Müller U. Phenotypic and molecular analyses of X-linked dystonia-Parkinsonism ("lubag") in women. *Arch Neurol* 2004;61:1956–1959.
- Evidente VGH, Advincula J, Esteban R, et al. Phenomenology of "Lubag" or X-linked dystonia-Parkinsonism. *Mov Disord* 2002;17:1271–1277.
- Lee LV, Rivera C, Teleg RA, et al. The unique phenomenology of sex-linked dystonia Parkinsonism (XDP, DYT3, "Lubag"). *Int J Neurosci* 2011;121(suppl 1):3–11.
- Evidente VGH, Gwinn-Hardy K, Hardy J, Hernandez D, Singleton A. X-linked dystonia ("Lubag") presenting predominantly with Parkinsonism: a more benign phenotype? *Mov Disord* 2002;17(1):200–202.
- Stephen CD, Go CL, Acuna P, Sharma N. Phasic knee bending dystonic and Parkinsonian gait: a characteristic finding in X-linked dystonia Parkinsonism. *Mov Disord Clin Pract* 2020;7(4):448–452.
- Sprenger A, Hanssen H, Hagedorn I, et al. Eye movement deficits in X-linked dystonia-Parkinsonism are related to striatal degeneration. *Parkinsonism Relat Disord* 2019;61:170–178.
- Morigaki R, Nakataki M, Kawarai T, et al. Depression in X-linked dystonia-Parkinsonism: a case-control study. *Parkinsonism Relat Disord* 2013;19(9):844–846.
- Gillian LS. Pathological gambling in X-linked dystonia Parkinsonism. *J Addict Med* 2013;7(4):299–301.
- Domingo AR, Ledesma LK, D. Pasco PM, Jamora RDG, Lee LV. Neuropsychological profile of x-linked dystonia Parkinsonism, (XDP, DYT3). *Mov Disord* 2011;26(suppl 2):S264.
- Jamora RDG, Ledesma LK, Domingo A, Cenina AR A F, Lee LV. Nonmotor features in sex-linked dystonia Parkinsonism. *Neurodegener Dis Manag* 2014;4(3):283–289.
- Waters CH, Takahashi H, Wilhelmsen KC, et al. Phenotypic expression of X-linked dystonia-Parkinsonism (lubag) in two women. *Neurology* 1993;43(8):1555–1558.
- Brüggemann N, Heldmann M, Klein C, et al. Neuroanatomical changes extend beyond striatal atrophy in X-linked dystonia Parkinsonism. *Parkinsonism Relat Disord* 2016;31:91–97.
- Brüggemann N, Rosales RL, Waugh JL, et al. Striatal dysfunction in X-linked dystonia-Parkinsonism is associated with disease progression. *Eur J Neurol* 2017;24(5):680–686.
- Hanssen H, Prasuhn J, Heldmann M, et al. Imaging gradual neurodegeneration in a basal ganglia model disease. *Ann Neurol* 2019;86(4):517–526.
- Tackenberg B, Metz A, Unger M, et al. Nigrostriatal dysfunction in X-linked dystonia-Parkinsonism (DYT3). *Mov Disord* 2007;22(6):900–902.
- Brüggemann N, Domingo A, Rasche D, et al. Association of pallidal neurostimulation and outcome predictors with X-linked dystonia Parkinsonism. *JAMA Neurol* 2019;76(2):211–216.
- Wadia PM, Lim SY, Lozano AM, et al. Bilateral pallidal stimulation for X-linked dystonia Parkinsonism. *Arch Neurol* 2010;67(8):1012–1015.
- Patel AJ, Sarwar AI, Jankovic J, Viswanathan A. Bilateral pallidal deep brain stimulation for X-linked dystonia Parkinsonism. *World Neurosurg* 2014;82(1–2):241.e1–241.e4.
- Evidente VGH, Lyons MK, Wheeler M, et al. First case of X-linked dystonia Parkinsonism ("Lubag") to demonstrate a response to bilateral pallidal stimulation. *Mov Disord* 2007;22(12):1790–1793.
- Waters CH, Faust PL, Powers J, et al. Neuropathology of lubag (x-linked dystonia Parkinsonism). *Mov Disord* 1993;8(3):387–390.
- Goto S, Kawarai T, Morigaki R, et al. Defects in the striatal neuropeptide y system in X-linked dystonia-Parkinsonism. *Brain* 2013;136(Pt 5):1555–1567.
- Aneichyk T, Hendriks WT, Yadav R, et al. Dissecting the causal mechanism of X-linked dystonia-Parkinsonism by integrating genome and transcriptome assembly. *Cell* 2018;172(5):897–909.e21.
- Bragg DC, Mangkalaphiban K, Vaine CA, et al. Disease onset in X-linked dystonia-Parkinsonism correlates with expansion of a hexameric repeat within an SVA retrotransposon in TAF1. *Proc Natl Acad Sci U S A* 2017;114(51):E11020–E11028.
- Westenberger A, Reyes CJ, Saranza G, et al. A Hexanucleotide repeat modifies expressivity of X-linked dystonia Parkinsonism. *Ann Neurol* 2019;85(6):812–822.
- Makino S, Kaji R, Ando S, et al. Reduced neuron-specific expression of the TAF1 gene is associated with X-linked dystonia-Parkinsonism. *Am J Hum Genet* 2007;80(3):393–406.
- Hagerman RJ, Hagerman P. Fragile X-associated tremor/ataxia syndrome-features, mechanisms and management. *Nat Rev Neurol* 2016;12(7):403–412.
- Hagerman RJ, Protic D, Rajaratnam A, Salcedo-Arellano MJ, Aydin EY, Schneider A. Fragile X-associated neuropsychiatric disorders (FXAND). *Front Psych* 2018;9:564.
- Hunter JE, Berry-Kravis E, Hipp H, Todd PK. FMR1 Disorders. In: Adam MP, Ardinger HH, Pagon RA, et al., eds. *GeneReviews®*. Seattle, WA: University of Washington; 2019:1993–2020.
- Martínez-Cerdeño V, Lechpammer M, Lott A, Schneider A, Hagerman R. Fragile X-associated tremor/ataxia syndrome in a man in his 30s. *JAMA Neurol* 2015;72(9):1070–1073.
- Niu YQ, Yang JC, Hall DA, et al. Parkinsonism in fragile X-associated tremor/ataxia syndrome (FXTAS): revisited. *Parkinsonism Relat Disord* 2014;20(4):456–459.
- Shickman R, Famula J, Tassone F, et al. Age- and CGG repeat-related slowing of manual movement in fragile X carriers: a prodrome of fragile X-associated tremor ataxia syndrome? *Mov Disord* 2018;33(4):628–636.
- Salcedo-Arellano MJ, Wolf-Ochoa MW, Hong T, et al. Parkinsonism versus concomitant Parkinson's disease in fragile X-associated tremor/ataxia syndrome. *Mov Disord Clin Pract* 2020;7:413–418.
- Hall DA, Howard K, Hagerman R, Leehey MA. Parkinsonism in FMR1 premutation carriers may be indistinguishable from Parkinson disease. *Parkinsonism Relat Disord* 2009;15(2):156–159.
- Toft M, Aasly J, Bisceglia G, et al. Parkinsonism, FXTAS, and FMR1 premutations. *Mov Disord* 2005;20(2):230–233.
- Loesch DZ, Tassone F, Mellick GD, et al. Evidence for the role of FMR1 gray zone alleles as a risk factor for Parkinsonism in females. *Mov Disord* 2018;33(7):1178–1181.
- Hall DA, Berry-Kravis E. Fragile X syndrome and fragile X-associated tremor ataxia syndrome. *Handbook of Clinical Neurology*. Amsterdam: Elsevier B.V.; 2018:377–391.

42. Hall DA, Hagerman RJ, Hagerman PJ, Jacquemont S, Leehey MA. Prevalence of FMR1 repeat expansions in movement disorders. A systematic review. *Neuroepidemiology* 2006;26(3):151–155.
43. Lenka A, Sundar S, Christopher R, Kumar P. Genetic substrates of psychosis in patients with Parkinson's disease: a critical review. *J Neurol Sci* 2016;364:33–41.
44. Juncos JL, Lazarus JT, Graves-Allen E, et al. New clinical findings in the fragile X-associated tremor ataxia syndrome (FXTAS). *Neurogenetics* 2011;12(2):123–135.
45. Mila M, Alvarez-Mora MI, Madrigal I, Rodriguez-Revenga L. Fragile X syndrome: an overview and update of the FMR1 gene. *Clin Genet* 2018;93(2):197–205.
46. Cabal-herrera AM, Tassanakijpanich N, Salcedo-arellano MJ. Fragile X-associated tremor / ataxia syndrome (FXTAS): pathophysiology and clinical implications. *Int J Mol Sci* 2020;21(12):4391.
47. Fay-Karmon T, Hassin-Baer S. The spectrum of tremor among carriers of the FMR1 premutation with or without the fragile X-associated tremor/ataxia syndrome (FXTAS). *Parkinsonism Relat Disord* 2019;65(May):32–38.
48. Salcedo-Arellano MJ, Dufour B, McLennan Y, Martinez-Cerdeno V, Hagerman R. Fragile X syndrome and associated disorders: Clinical aspects and pathology. *Neurobiology of Disease* 2020;136:104740.
49. Brunberg JA, Jacquemont S, Hagerman RJ, et al. *Fragile X* premutation carriers: characteristic MR imaging findings of adult male patients with progressive cerebellar and cognitive dysfunction. *AJNR Am J Neuroradiol* 2002;23(10):1757–1766.
50. Jacquemont S, Hagerman RJ, Leehey M, et al. *fragile X* premutation tremor/ataxia syndrome: molecular, clinical, and neuroimaging correlates. *Am J Hum Genet* 2003;72(4):869–878.
51. Wang JY, Hessel D, Tassone F, Kim K, Hagerman RJ, Rivera SM. Interaction between ventricular expansion and structural changes in the corpus callosum and putamen in males with FMR1 normal and premutation alleles. *Neurobiol Aging* 2020;86:27–38.
52. Wang JY, Hessel D, Hagerman RJ, Simon TJ, Tassone F, Ferrer E, et al. Abnormal trajectories in cerebellum and brainstem volumes in carriers of the fragile X premutation. *Neurobiol Aging* 2017;55:11–19.
53. Scaglione C, Ginestroni A, Vella A, et al. MRI and SPECT of mid-brain and striatal degeneration in fragile X-associated tremor/ataxia syndrome. *J Neurol* 2008;255(1):144–146.
54. Healy DG, Bressman S, Dickson J, et al. Evidence for pre and post-synaptic nigrostriatal dysfunction in the fragile X tremor-ataxia syndrome. *Mov Disord* 2009;24(8):1245–1247.
55. Ceravolo R, Antonini A, Volterrani D, et al. Dopamine transporter imaging study in Parkinsonism occurring in fragile X premutation carriers. *Neurology* 2005;65(12):1971–1973.
56. O'Dwyer JP, Clabby C, Crown J, Barton DE, Hutchinson M. Fragile X-associated tremor/ataxia syndrome presenting in a woman after chemotherapy. *Neurology* 2005;65(2):331–332.
57. Zuhrofi M, Adams PE, Andrea S, Hagerman RJ, Reymundo L. Addictive substances may induce a rapid neurological deterioration in fragile X-associated tremor ataxia syndrome: a report of two cases. *Intractable Rare Dis Res* 2014;3(4):162–165.
58. Ariza J, Rogers H, Hartvigsen A, Snell M, Dill M, Judd D, et al. Iron accumulation and dysregulation in the putamen in fragile X-associated tremor/ataxia syndrome. *Mov Disord* 2017;32(4):585–591.
59. Rogers H, Ariza J, Monterrubio A, Hagerman P, Martínez-Cerdeño V. Cerebellar mild iron accumulation in a subset of FMR1 premutation carriers with FXTAS. *Cerebellum* 2016;15(5):641–644.
60. Sellier C, Buijsen RAM, He F, et al. Translation of expanded CGG repeats into FMRpolyG is pathogenic and may contribute to fragile X tremor ataxia syndrome. *Neuron* 2017;93(2):331–347.
61. Cleary JD, Ranum LP. New developments in RAN translation: insights from multiple diseases. *Curr Opin Genet Dev* 2017;44:125–134.
62. Ma L, Herren AW, Espinal G, et al. Composition of the intranuclear inclusions of fragile X-associated tremor/ataxia syndrome. *Acta Neuropathol Commun* 2019;7(1):143.
63. Giulivi C, Napoli E, Tassone F, Halmaj J, Hagerman R. Plasma metabolic profile delineates roles for neurodegeneration, pro-inflammatory damage and mitochondrial dysfunction in the FMR1 premutation. *Biochem J* 2016;473(21):3871–3888.
64. Ross-Inta C, Omanska-Klusek A, Wong S, et al. Evidence of mitochondrial dysfunction in fragile X-associated tremor/ataxia syndrome. *Biochem J* 2010;429(3):545–552.
65. Napoli E, Ross-Inta C, Wong S, et al. Altered zinc transport disrupts mitochondrial protein processing/import in fragile X-associated tremor/ataxia syndrome. *Hum Mol Genet* 2011;20(15):3079–3092.
66. Ariza J, Steward C, Rueckert F, et al. Dysregulated iron metabolism in the choroid plexus in fragile X-associated tremor/ataxia syndrome. *Brain Res* 2015;1598:88–96.
67. Gregory A, Kurian MA, Haack T, Hayflick SJ, Hogarth P. Beta-propeller protein-associated neurodegeneration. In: Adam MP, Ardinger HH, Pagon RA, et al., eds. *GeneReviews*. Seattle, WA: University of Washington; 2017:1993–2020.
68. Morikawa M, Takano K, Motobayashi M, Shiba N, Kosho T, Nakazawa Y, et al. Clinical features of a female with WDR45 mutation complicated by infantile spasms: a case report and literature review. *Brain Dev* 2017;39(9):804–807.
69. Gregory A, Polster BJ, Hayflick SJ. Clinical and genetic delineation of neurodegeneration with brain iron accumulation. *J Med Genet* 2008;46:73–80.
70. Stige KE, Gjerde IO, Houge G, Knappskog M, Tzoulis C. Beta-propeller protein-associated neurodegeneration: a case report and review of the literature. *Clin Case Rep* 2018;6(2):353–362.
71. Long M, Abdeen N, Geraghty MT, Hogarth P, Hayflick S, Venkateswaran S. Novel WDR45 mutation and pathognomonic BPAN imaging in a young female with mild cognitive delay. *Pediatrics* 2015;136(3):e714–e717.
72. Hayflick SJ, Kruer MC, Gregory A, et al. Beta-propeller protein-associated neurodegeneration: a new X-linked dominant disorder with brain iron accumulation. *Brain* 2013;136:1708–1717.
73. Ohba C, Nabatame S, Iijima Y, et al. De novo WDR45 mutation in a patient showing clinically Rett syndrome with childhood iron deposition in brain. *J Hum Genet* 2014;59(5):292–295.
74. Khalifa M, Naffaa L. Exome sequencing reveals a novel WDR45 frameshift mutation and inherited POLR3A heterozygous variants in a female with a complex phenotype and mixed brain MRI findings. *Eur J Med Genet* 2015;58(8):381–386.
75. Nishioka K, Oyama G, Yoshino H, et al. High frequency of beta-propeller protein-associated neurodegeneration (BPAN) among patients with intellectual disability and young-onset Parkinsonism. *Neurobiol Aging* 2015;36(5):2004.e9–2004.e15.
76. Kruer MC, Boddaert N, Schneider A, et al. Neuroimaging features of neurodegeneration with brain iron accumulation. *AJNR Am J Neuroradiol* 2012;33(3):407–414.
77. Kimura Y, Sato N, Sugai K, et al. MRI, MR spectroscopy, and diffusion tensor imaging findings in patient with static encephalopathy of childhood with neurodegeneration in adulthood (SENDA). *Brain Dev* 2013;35(5):458–461.
78. Russo C, Ardisson A, Freri E, et al. Substantia nigra swelling and dentate nucleus T2 Hyperintensity may be early magnetic resonance imaging signs of  $\beta$ -propeller protein-associated neurodegeneration. *Mov Disord Clin Pract* 2019;6(1):51–56.
79. Ishiyama A, Kimura Y, Iida A, et al. Transient swelling in the globus pallidus and substantia nigra in childhood suggests SENDA/BPAN. *Neurology* 2018;90(21):974–976.
80. Kimura Y, Sato N, Ishiyama A, et al. Serial MRI alterations of pediatric patients with beta-propeller protein associated neurodegeneration (BPAN). *J Neuroradiol* 2020;23:S0150-9861(20)30157-7.
81. Takano K, Shiba N, Wakui K, et al. Elevation of neuron specific enolase and brain iron deposition on susceptibility-weighted imaging as diagnostic clues for beta-propeller protein-associated neurodegeneration in early childhood: additional case report and

- review of the literature. *Am J Med Genet Part A* 2016;170A(2):322–328.
82. Takeuchi J, Ito K, Takeda A, Saitsu H, Matsumoto N, Itoh Y. A male case with  $\beta$ -propeller protein-associated neurodegeneration (BPAN) with somatic mosaic mutation in WDR45. *Journal of Alzheimer's Disease & Parkinsonism* 2016;6(5):289–291.
  83. Fonderico M, Laudisi M, Andreasi NG, et al. Patient affected by Beta-propeller protein-associated Neurodegeneration: a therapeutic attempt with iron chelation therapy. *Front Neurol* 2017;8:385.
  84. Paudel R, Li A, Wiethoff S, et al. Neuropathology of Beta-propeller protein associated neurodegeneration (BPAN): a new tauopathy. *Acta Neuropathol Commun* 2015;3(30):39.
  85. Saitsu H, Nishimura T, Muramatsu K, et al. De novo mutations in the autophagy gene WDR45 cause static encephalopathy of childhood with neurodegeneration in adulthood. *Nat Genet* 2013;45(4):445–450.
  86. Haack TB, Hogarth P, Kruer MC, et al. Exome sequencing reveals De novo WDR45 mutations causing a phenotypically distinct, X-linked dominant form of NBIA. *Am J Hum Genet* 2012;91:1144–1149.
  87. Zarate YA, Jones JR, Jones MA, et al. Lessons from a pair of siblings with BPAN. *Eur J Hum Genet* 2016;24(7):1080–1083.
  88. Dufke A, Grasshoff U, Dufke C, et al. NGS based whole X-exome analysis reveals a novel WDR45 missense mutation in a family with 3 males with non-syndromic intellectual disability. *Medizinische Genet* 2014;1:133–134.
  89. Ebrahimi-Fakhari D, Saffari A, Wahlster L, et al. Congenital disorders of autophagy: an emerging novel class of inborn errors of neuro-metabolism. *Brain* 2016;139(Pt 2):317–337.
  90. Hor CHH, Tang BL. Beta-propeller protein-associated neurodegeneration (BPAN) as a genetically simple model of multifaceted neuropathology resulting from defects in autophagy. *Rev Neurosci* 2019;30(3):261–277.
  91. Wan H, Wang Q, Chen X, et al. WDR45 contributes to neurodegeneration through regulation of ER homeostasis and neuronal death. *Autophagy* 2020;16(3):531–547.
  92. Mollereau B, Walter L. Is WDR45 the missing link for ER stress-induced autophagy in beta-propeller associated neurodegeneration? *Autophagy* 2019;15(12):2163–2164.
  93. Mehta A, Hughes DA. Fabry disease. In: Adam MP, Ardinger HH, Pagon RA, et al., eds. *GeneReviews*®. Seattle, WA: University of Washington; 2017:1993–2020.
  94. Buechner S, De Cristofaro MTR, Ramat S, Borsini W. Parkinsonism and Anderson Fabry's disease: a case report. *Mov Disord* 2006;21(1):103–107.
  95. Wise AH, Yang A, Naik H, et al. Parkinson's disease prevalence in Fabry disease: a survey study. *Mol Genet Metab Rep* 2017;14:27–30.
  96. Del Tredici K, Ludolph AC, Feldengut S, et al. Fabry disease with concomitant Lewy body disease. *J Neuropathol Exp Neurol* 2020;79(4):378–392.
  97. Gago MF, Azevedo O, Guimarães A, et al. Parkinson's disease and Fabry disease: clinical, biochemical and neuroimaging analysis of three pedigrees. *J Parkinsons Dis* 2020;10(1):141–152.
  98. Orimo S, Iwasaki T, Yoshino H, Arai M, Hiyamuta E. An autopsied case of Fabry's disease presenting with Parkinsonism and cardiomegaly as a cardinal clinical manifestation. *Rinsho Shinkeigaku* 1994;34(10):1003–1007.
  99. Russo C, Pontillo G, Pisani A, et al. Striatonigral involvement in Fabry disease: a quantitative and volumetric magnetic resonance imaging study. *Parkinsonism Relat Disord* 2018;57:27–32.
  100. Nelson MP, Tse TE, O'Quinn DB, et al. Autophagy-lysosome pathway associated neuropathology and axonal degeneration in the brains of alpha-galactosidase A-deficient mice. *Acta Neuropathol Commun* 2014;2:20.
  101. Huebecker M, Moloney EB, Van Der Spoel AC, et al. Reduced sphingolipid hydrolase activities, substrate accumulation and ganglioside decline in Parkinson's disease. *Mol Neurodegener* 2019;14(1):40.
  102. Alcalay R, Wolf P, Levy O, et al. Alpha galactosidase A activity in Parkinson's disease HHS public access. *Neurobiol Dis* 2018;112:85–90.
  103. Nelson MP, Boutin M, Tse TE, et al. The lysosomal enzyme alpha-Galactosidase A is deficient in Parkinson's disease brain in association with the pathologic accumulation of alpha-synuclein. *Neurobiol Dis* 2018;110:68–81.
  104. Paciotti S, Albi E, Parnetti L, Beccari T. Lysosomal ceramide metabolism disorders: implications in Parkinson's disease. *J Clin Med* 2020;9(2):594.
  105. Laxova R, Brown ES, Hogan K, Hecox K, Opitz JM, Reynolds JF. An X-linked recessive basal ganglia disorder with mental retardation. *Am J Med Genet* 1985;21(4):681–689.
  106. Wilson GR, Sim JCH, Mclean C, et al. Mutations in RAB39B cause X-linked intellectual disability and early-onset Parkinson disease with a -Synuclein pathology. *Am J Hum Genet* 2014;95(6):729–735.
  107. Shi CH, Zhang SY, Yang ZH, et al. A novel RAB39B gene mutation in X-linked juvenile Parkinsonism with basal ganglia calcification. *Mov Disord* 2016;31(12):1905–1909.
  108. Ciammola A, Carrera P, Di Fonzo A, et al. X-linked Parkinsonism with intellectual disability caused by novel mutations and somatic mosaicism in RAB39B gene. *Parkinsonism Relat Disord* 2017;44:142–146.
  109. Mata IF, Jang Y, Kim CH, et al. The RAB39B p.G192R mutation causes X-linked dominant Parkinson's disease. *Mol Neurodegener* 2015;10:50.
  110. Lesage S, Bras J, Cormier-Dequaire F, et al. Loss-of-function mutations in RAB39B are associated with typical early onset Parkinson's disease. *Neurol Genet* 2015;1(1):1–3.
  111. Güldner M, Schulte C, Hauser AK, Gasser T, Brockmann K. Broad clinical phenotype in Parkinsonism associated with a base pair deletion in RAB39B and additional POLG variant. *Parkinsonism Relat Disord* 2016;31:148–150.
  112. Giannandrea M, Bianchi V, Mignogna ML, et al. Mutations in the small GTPase gene RAB39B are responsible for X-linked mental retardation associated with autism, epilepsy, and macrocephaly. *Am J Hum Genet* 2010;86(2):185–195.
  113. Vanmarsenille L, Giannandrea M, Fieremans N, et al. Increased dosage of RAB39B affects neuronal development and could explain the cognitive impairment in male patients with distal Xq28 copy number gains. *Hum Mutat* 2014;35(3):377–383.
  114. Gao Y, Martínez-Cerdeño V, Hogan KJ, McLean CA, Lockhart PJ. Clinical and neuropathological features associated with loss of RAB39B. *Mov Disord* 2020;35(4):687–693.
  115. Gregg RG, Metzberg AB, Hogan K, Sekhon G, Laxova R. Waisman syndrome, a human X-linked recessive basal ganglia disorder with mental retardation: localization to Xq27.3-qter. *Genomics* 1991;9(4):701–706.
  116. Kaur S, Christodoulou J, Adam MP, Ardinger HH, Pagon RA. MECP2 disorders. In: Adam MP, Ardinger HH, Pagon RA, et al., eds. *GeneReviews*®. Seattle, WA: University of Washington; 2019:1993–2020.
  117. Villard L. MECP2 mutations in males. *J Med Genet* 2007;44:417–423.
  118. Couvert Bienvenu T, Aquaviva C, Poirier K, et al. MECP2 gene is highly mutated in X-linked mental retardation. *Hum Mol Genet* 2001;10(9):941–946.
  119. Pollini L, Galosi S, Nardecchia F, et al. Parkinsonism, intellectual disability, and catatonia in a young male with MECP2 variant. *Mov Disord Clin Pract* 2020;7(1):118–119.
  120. Orrico A, Lam CW, Galli L, et al. MECP2 mutation in male patients with non-specific X-linked mental retardation. *FEBS Lett* 2000;481(3):285–288.
  121. Lindsay S, Splitt M, Edney S, et al. PPM-X: a new X-linked mental retardation syndrome with psychosis, pyramidal signs, and macroorchidism maps to Xq28. *Am J Hum Genet* 1996;58(6):1120–1126.
  122. Chahil G, Yelam A, Bollu PC. Rett syndrome in males: a case report and review of literature. *Cureus* 2018;10(10):e3414.

123. Swanberg SE, Nagarajan RP, Peddada S, Yasui DH, Lasalle JM. Reciprocal co-regulation of EGR2 and MECP2 is disrupted in Rett syndrome and autism. *Hum Mol Genet* 2009;18(3):525–534.
124. Kraus AP, Langston MF, Lynch BL. Red cell phosphoglycerate kinase deficiency. A new cause of non-spherocytic hemolytic anemia. *Biochem Biophys Res Commun* 1968;30(2):173–177.
125. Garcia-Solaesa V, Serrano-Lorenzo P, Ramos-Arroyo MA, et al. A novel missense variant associated with a splicing defect in a myopathic form of pgk1 deficiency in the spanish population. *Genes (Basel)* 2019;10(10):785.
126. Beutler E. PGK deficiency. *Br J Haematol* 2007;113(3):3–11.
127. Konrad PN, McCarthy DJ, Mauer AM, Valentine WN, Paglia DE. Erythrocyte and leukocyte phosphoglycerate kinase deficiency with neurologic disease. *J Pediatr* 1973;82(3):456–460.
128. Virmani T, Rotstein M, Spiegel R, Akman HO, Dimauro S, Greene PE. Levodopa responsive Parkinsonism in two patients with phosphoglycerate kinase deficiency. *Mov Disord Clin Pract* 2014;1(3):240–242.
129. Sakaue S, Kasai T, Mizuta I, et al. Early-onset Parkinsonism in a pedigree with phosphoglycerate kinase deficiency and a heterozygous carrier: do PGK-1 mutations contribute to vulnerability to Parkinsonism? *NPJ Parkinsons Dis* 2017;3:13.
130. Morales-Briceño H, Ha AD, London K, Farlow D, Chang FCF, Fung VSC. Parkinsonism in PGK1 deficiency implicates the glycolytic pathway in nigrostriatal dysfunction. *Parkinsonism Relat Disord* 2019;64:319–323.
131. Vissing J, Akman HO, Aasly J, Kahler SG, Bacino CA, DiMauro S, et al. Level of residual enzyme activity modulates the phenotype in phosphoglycerate kinase deficiency. *Neurology* 2018;91(11):e1077–e1082.
132. Ramser J, Abidi FE, Burckle CA, et al. A unique exonic splice enhancer mutation in a family with X-linked mental retardation and epilepsy points to a novel role of the renin receptor. *Hum Mol Genet* 2005;14(8):1019–1027.
133. Korvatska O, Strand NS, Berndt JD, et al. Altered splicing of ATP6AP2 causes X-linked Parkinsonism with spasticity (XPDS). *Hum Mol Genet* 2013;22(16):3259–3268.
134. Rujano MA, Serio MC, Panasyuk G, et al. Mutations in the X-linked ATP6AP2 cause a glycosylation disorder with autophagic defects. *J Exp Med* 2017;214(12):3707–3729.
135. Gupta HV, Vengoechea J, Sahaya K, Virmani T. A splice site mutation in ATP6AP2 causes X-linked intellectual disability, epilepsy, and Parkinsonism. *Parkinsonism Relat Disord* 2015;21(12):1473–1475.
136. Poorkaj P, Raskind WH, Leverenz JB, et al. A novel X-linked four-repeat tauopathy with Parkinsonism and spasticity. *Mov Disord* 2010;25(10):1409–1417.
137. Dubos A, Castells-Nobau A, Meziane H, et al. Conditional depletion of intellectual disability and Parkinsonism candidate gene ATP6AP2 in fly and mouse induces cognitive impairment and neurodegeneration. *Hum Mol Genet* 2015;24(23):6736–6755.