

Received: 21 January 2021

Revised: 21 March 2021

Accepted: 29 March 2021

DOI: 10.1111/aogs.14157



## ORIGINAL RESEARCH ARTICLE

# Contralateral lymph node metastases in patients with vulvar cancer and unilateral sentinel lymph node metastases

Tanja Ignatov<sup>1,2</sup> | Johannes Gaßner<sup>1</sup> | Mihaela Bozukova<sup>3</sup> | Stylianos Ivros<sup>2,4</sup> |  
József Mészáros<sup>1</sup> | Olaf Ortman<sup>1</sup> | Holm Eggemann<sup>5</sup> | Atanas Ignatov<sup>1,2</sup> 

<sup>1</sup>Department of Gynecology and Obstetrics, University Medical Center Regensburg, Regensburg, Germany

<sup>2</sup>Department of Gynecology and Obstetrics, Otto-von-Guericke University, Magdeburg, Germany

<sup>3</sup>Max Planck Institute for Biology of Ageing, Cologne, Germany

<sup>4</sup>Gynecologic Oncology Unit, Metropolitan Hospital, Athens, Greece

<sup>5</sup>Department of Gynecology and Obstetrics, Klinikum Magdeburg, Magdeburg, Germany

## Correspondence

Atanas Ignatov, Department of Obstetrics and Gynecology, Otto-von-Guericke University, G.-Hauptmann Strasse 35, 39108 Magdeburg, Germany.  
Email: [atanas.ignatov@gmail.com](mailto:atanas.ignatov@gmail.com)

## Abstract

**Introduction:** The risk of contralateral lymph node metastases following unilateral sentinel lymph node (SLN) metastases in patients with vulvar cancer(s) remains to be systematically assessed.

**Material and methods:** We performed a multicenter, retrospective registry-based study of 476 patients with vulvar cancer. The primary outcome measure was the rate of contralateral non-SLN metastases in the case of positive unilateral SLN.

**Results:** Out of 476 patients with primary vulvar cancer, 202 received SLN biopsy: 58 unilateral and 144 bilateral. Out of 66 patients with unilateral metastatic SLN, 62 (93.9%) received contralateral lymphadenectomy—18 after unilateral and 44 after bilateral SLN biopsy. In the study group, 132 SLN were assessed with a median number of 2 (range 1–4) per patient and 76 of these were positive. Lymph node-positivity was associated with advanced tumor stage, as well as lymph and vascular space invasion. In the group of patients with bilateral inguino-femoral lymphadenectomy, 1004 lymph nodes were resected with a median number of 15 (range 10–29) per patient. After full dissection of the inguino-femoral lymph nodes, no contralateral non-SLN metastases were found.

**Conclusions:** The risk of contralateral non-SLN metastases in patients with unilateral SLN metastases was low. Therefore, the impact of contralateral lymphadenectomy on patient survival should be investigated in further studies.

## KEYWORDS

cancer, lymphadenectomy, metastases, sentinel node, vulvar, vulvar cancer

**Abbreviations:** LN, lymph node; SLN, sentinel lymph node.

Tanja Ignatov and Johannes Gaßner contributed equally.

This is an open access article under the terms of the Creative Commons Attribution-NonCommercial License, which permits use, distribution and reproduction in any medium, provided the original work is properly cited and is not used for commercial purposes.

© 2021 The Authors. *Acta Obstetrica et Gynecologica Scandinavica* published by John Wiley & Sons Ltd on behalf of Nordic Federation of Societies of Obstetrics and Gynecology (NFOG)

## 1 | INTRODUCTION

Metastases in inguinofemoral lymph nodes (LN) remains the most important prognostic factor for survival of patients with vulvar cancer,<sup>1</sup> highlighting the essential role of LN staging. The data of the GROINSS-V trial demonstrated the diagnostic relevance of the sentinel lymph node (SLN) procedure for patients with clinically node-negative disease.<sup>2</sup> The significant reduction of treatment-related morbidity and the excellent long-term outcome,<sup>3</sup> resulted in the wide adoption of this procedure as the standard of care. Nevertheless, some controversies regarding LN staging remain unresolved. One of the most important questions is whether contralateral groin lymphadenectomy should be performed in the case of unilateral SLN metastases. Some older studies suggested an increased risk of contralateral groin metastases upon unilateral metastasis.<sup>4,5</sup> Notably, SLN biopsy has not been performed in these studies. After the introduction of SLN biopsy,<sup>2</sup> no increased numbers of contralateral LN metastases were observed in studies with limited numbers of patients.<sup>6,7</sup> Current German and European guidelines recommend a contralateral lymphadenectomy in the case of ipsilateral LN metastases.<sup>1,8</sup>

The aim of this study was to evaluate the rate of contralateral non-SLN metastases in vulvar cancer patients with unilateral SLN metastases.

## 2 | MATERIAL AND METHODS

### 2.1 | Patients

We investigated cases of squamous and adenosquamous vulvar cancer included in the prospectively maintained regional cancer registry of Saxony-Anhalt, a federal state of Germany. These population-based data originate from medical reports, pathology and follow-up records. Documented parameters comprise diagnosis, therapies, course of disease and long-term follow up, including locoregional or distant recurrence and death.<sup>9</sup> The date and cause of death are documented in the registry by the main health department shortly after death. In this cohort study, we analyzed women who were diagnosed with vulvar cancer between January 2000 and September 2017. Overall, 476 patients were assessed for inclusion in the present study (Figure 1). Patients who did not receive an SLN biopsy ( $n = 263$ ) and patients with missing information regarding lymphadenectomy ( $n = 7$ ) or with basaloid carcinoma ( $n = 4$ ) were excluded, as were patients who had negative SLN ( $n = 131$ ), bilateral SLN metastases ( $n = 5$ ), or who did not receive contralateral lymphadenectomy despite having unilateral SLN metastases ( $n = 4$ ). The remaining 62 patients who had unilateral SLN metastases and underwent contralateral lymphadenectomy were further investigated. For these patients, tumor localization was investigated by classifying the tumors as lateral lesions ( $>1$  cm from the midline) or midline lesions ( $\leq 1$  cm from the midline). The surgical approach and the SLN procedure were performed in accordance with the institutional procedure. Biopsy of SLN was performed for patients with clinically negative nodes and tumors  $<4$  cm. The SLN were labeled by  $^{99m}\text{Tc}$ -nanocolloid and detected by gamma counter. The identified SLN were sent for

### Key message

The role of contralateral lymphadenectomy in patients with vulvar cancer and a unilateral metastatic sentinel lymph node is debatable. In our population-based study the risk of contralateral metastases in such patients was low. Additional studies are needed.

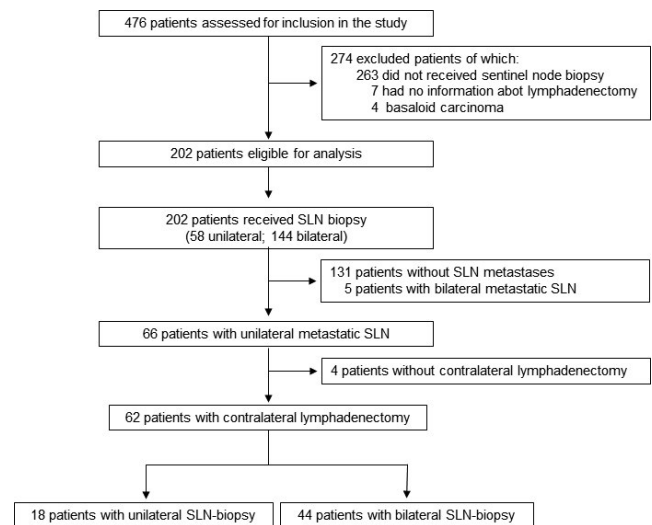


FIGURE 1 Schematic representation of the study design. SLN, sentinel lymph node

frozen-section analysis. Bilateral lymphadenectomy was performed in cases of positive SLN(s). In the case of negative frozen sections, hematoxylin and eosin staining of the LN was performed. In a case of positivity, a secondary lymphadenectomy was performed. Ultrastaging of all negative LN was performed after 2009. The manuscript was prepared in accordance with the STROBE statement criteria.<sup>10</sup>

### 2.2 | Statistical analysis

Statistical analyses were performed using SPSS version 26.0 (IBM). Correlation of variables was assessed using chi-squared test and two-sided Student's *t* test for continuous variables. Values of *p* below the significance level ( $\alpha$ ) of 0.05 were considered statistically significant. Continuous variables are presented as means and ranges and categorical variables are presented as numbers.

### 2.3 | Ethical approval

The Ethics Committee of the Otto-von-Guericke University, Magdeburg, Germany concluded that no informed consent was

required for this retrospective, observational study (ID: 143/15; October 28, 2015). Before analysis, patient data were subjected to pseudonymization.

### 3 | RESULTS

Between January 2000 and September 2017, 472 women with vulvar cancer were identified. The flow diagram shows the study design and the number of patients at each stage of the study (Figure 1). From the 202 patients included in the initial analysis, 71 (35.1%) exhibited SLN metastases (Table 1). SLN metastases were associated with advanced tumor stage ( $p = 0.0001$ ) and lymph space invasion ( $p = 0.0001$ ). Patient's age, histological grade and vascular space invasion did not show any association with SLN metastases. SLN metastases were observed unilaterally and bilaterally in 66 (93.0%) and 5 (7.0%) patients, respectively. Of special interest were the patients in the former category, so we focused on these 62 patients with unilateral SLN metastases, of which 18 (29.0%) underwent a unilateral and the remaining 44 (71%) a bilateral SLN biopsy (Figure 1). Of these patients, 54 had no additional LN metastases, whereas in eight women a non-SLN metastasis was observed (Table 1). The presence of additional LN was associated with lymph space invasion ( $p = 0.039$ ). Patient's age, tumor size, tumor localization, tumor grading, and vascular space invasion were not associated with any additional non-SLN metastases (Table 2). The performance of unilateral or bilateral SLN biopsy was associated with the tumor localization. Only two (5.7%) of 35 patients with median tumor localization and 15 (65.2%) of 23 patients with lateral localized tumors underwent a

unilateral SLN biopsy ( $p = 0.0001$ ). Moreover, the tumor localization correlated with the localization of the LN metastases. In 5 (12.5%) of 40 patients with median tumors and in 0 (0%) of 23 patients with lateral tumors bilateral metastases were observed. Nevertheless, this correlation was not significant ( $p = 0.077$ ). During the follow-up period of 35 months (range 1–114 months), a recurrence was observed in 12 (22.6%) patients, more specifically 7 (11.3%) vulvar, 5 (8.1%) groin and 2 (3.2%) distant recurrences. Interestingly, four of the groin metastases were on the contralateral side to the primary SLN biopsy. Notably, only three of the patients with groin recurrence received an adjuvant therapy. The other two patients refused the therapy.

In this group of patients, overall 132 SLN were removed (Table 3) in the group of patients with a bilateral SLN procedure and 42 in the group with unilateral SLN biopsy. The median number of removed SLN was 2 (range 1–4) per patient. Metastases to LN were observed in 76 SLN: one SLN metastasis in 48 (21.6%) women and two SLN metastases in 14 (18.4%) women. After bilateral lymphadenectomy, 1004 LN were removed with a median number of 15 (range 10–29) per patient. Among these, 89 LN metastases were observed. However, in the case of unilateral SLN metastases, no contralateral non-SLN metastases were found.

### 4 | DISCUSSION

In the present study, we found no positive association between unilateral SLN metastases and contralateral non-SLN metastases in patients with primary vulvar cancer. These findings put into question

TABLE 1 Clinical and pathological characteristics of the study cohort

Variable	Total	Lymph nodes				p value
		Negative		Positive		
		N	%	N	%	
Total	202	131	64.9	71	35.1	
Age (years), mean (range)	202	75 (33–95)		72 (34–91)		0.085
Tumor stage						
pT1	108	83	63.4	25	35.2	0.0001
pT2	86	46	35.1	40	56.3	
pT3	8	2	1.5	6	8.5	
Histological grade						
1	27	22	16.8	5	7.0	0.148
2	123	76	58.0	47	66.2	
3	52	33	25.2	19	26.8	
Lymph space invasion						
Negative	108	89	74.8	19	27.9	0.0001
Positive	79	30	25.2	49	72.1	
Vascular space invasion						
Negative	159	109	94.8	50	86.2	0.074
Positive	14	6	5.2	8	13.8	

Variable	Non-sentinel lymph nodes				p value
	Negativ		Positiv		
	N	%	N	%	
Total	54	87.1	8	12.9	
Age (years), mean ( $\pm$ SD)	72 ( $\pm$ 13)		74 ( $\pm$ 12)		0.954
Tumor stage					
pT1	21	38.9	4	50.0	0.560
pT2	30	55.6	3	37.5	
pT3	3	5.6	1	12.5	
Tumor localization					
$\leq$ 1 cm from the midline	30	60.0	5	32.5	0.893
$>$ 1 cm from the midline	20	40.0	3	37.5	
Histological grade					
1	5	9.3	0	0	0.409
2	35	64.8	7	87.5	
3	14	25.9	1	12.5	
Lymph space invasion					
Negative	19	36.5	0	0	0.039
Positive	33	63.5	8	100	
Vascular space invasion					
Negative	39	88.6	4	66.7	0.146
Positive	5	11.4	2	33.3	

TABLE 2 Clinical and pathological characteristics of the patients with non-sentinel lymph node metastases

the current standard of practice of contralateral lymphadenectomy for women with unilateral SLN metastases.<sup>1,8</sup>

The above-mentioned recommendations are based on older studies that suggested an increased risk of contralateral LN metastases in patients with vulvar cancer and confirmed unilateral LN metastasis. In a study with 195 patients with vulvar cancer, systematic bilateral inguinal and pelvic lymphadenectomy was performed.<sup>5</sup> The rate of LN metastases was 21% with an ipsilateral spread of 84.6%. In the case of a lateral tumor, contralateral LN metastases occurred in 15.3% and 30.7% of patients without and with ipsilateral positive LN, respectively. In general, bilateral involvement of the groin LN was observed in 60.0% of bilateral labial lesions, 29.6% of unilateral labial lesions and 37.5% of clitoral lesions.<sup>5</sup> These results demonstrate the strong association between tumor localization and LN metastases. In a further study, the relationship between the contralateral involvement of the groin LN and tumor localization was investigated.<sup>4</sup> The risks of contralateral LN involvement were 1.8% and 9.5% for unilateral and mediolateral tumors, respectively. No contralateral LN metastases were observed in patients in whom the tumor size was  $\leq$ 2 cm with an invasion depth of  $\leq$ 5 mm. The reduced risk of contralateral LN metastases in patients with lateral lesions was further documented in another study with tumors localized  $>$ 1 cm from the midline.<sup>11</sup> Importantly, these studies were conducted before the era of SLN biopsy, so lack the accuracy and precision of results obtained by the SLN procedure.

A recent study investigated the rate of contralateral non-SLN metastases in 28 patients with vulvar cancer.<sup>7</sup> In agreement with our results, the authors did not find any contralateral non-SLN metastasis after bilateral lymphadenectomy in the case of unilateral metastatic SLN. Moreover, the clinical and pathological characteristics of the patients in this study were comparable with our cohort. Importantly, in this study the patients underwent bilateral SLN biopsy and demonstrated a negative contralateral SLN in patient with metastatic ipsilateral SLN. In our cohort, 44 patients had similar conditions. In another recent study, Nica and co-workers analyzed 19 patients, who had unilateral positive SLN and underwent bilateral lymphadenectomy.<sup>6</sup> Thirteen of these patients (68.4%) had midline and six (31.6%) had lateral tumors, which mirrors the tumor localization in our cohort; the midline tumors in our study population were 60.3%. Notably, the authors observed in one patient (5.3%) a contralateral non-SLN metastasis with a lesion sized 6 cm. Importantly, direct comparison with our results is difficult because Nica et al. included also tumors with a diameter of  $>$ 4 cm in their analysis.<sup>6</sup> Therefore, these data should be interpreted with caution. In our cohort, only patients with lesions  $<$ 4 cm were included, for whom the effectiveness and safety has been documented.<sup>3</sup> In contrast, Winarno et al. have recently demonstrated that 4 of 18 (22.2%) women with unilateral SLN metastasis had contralateral inguino-femoral groin metastases.<sup>12</sup> Notably, the rate of contralateral LN metastases in this cohort correlated significantly with the depth of

**TABLE 3** Sentinel lymph node and lymphadenectomy characteristics

Variable	N
SLN	
Total	132
Median ( $\pm$ SD)	2 ( $\pm$ 2)
Unilateral	42
Bilateral	90
SLN+	76
1 SLN+	48
2 SLN+	14
Lymphadenectomy after SLN+	
Total LN	1004
LN median ( $\pm$ SD)	15 ( $\pm$ 6)
LN+	89
Contralateral LN+	0

Abbreviation: LN, lymph node; SLN, sentinel lymph node.

infiltration. In our cohort, this factor was not evaluated. Therefore, the comparison of the data should be interpreted with caution.

In conclusion, our data demonstrate that lymphadenectomy of the contralateral groin in cases of unilateral SLN groin metastasis in patients with vulvar cancer <4 cm was not associated with additional LN metastases and this has been confirmed by others.<sup>6,7</sup> The study design and the number of patients included do not allow any conclusion on safety of lymphadenectomy to be drawn.

The preoperative evaluation of the LN in patients with vulvar cancer is important and should be used to select appropriate patients for sentinel approach.<sup>13,14</sup> As suggested by the current German and European Society of Gynaecological Oncology guidelines in patients with small-volume lateral tumors and no clinically suspicious LN, the contralateral lymphadenectomy could be omitted.<sup>1,8</sup> However, contralateral lymphadenectomy may be performed when ipsilateral LN are metastatic.

In our cohort, bilateral sentinel LN metastases were observed only in patients with median tumors. No contralateral metastases were found in patients with laterally localized tumors. As suggested by the guidelines, the tumor localization should be considered during performance of the SLN biopsy.<sup>1,8</sup> We have found that most unilateral SLN biopsies were performed in patients with lateral tumors. In the case of median tumors, unilateral SLN biopsy was performed in 5.6%.

Limitations of our study are its retrospective character, the relatively short median follow up and missing information regarding depth of tumor infiltration and micrometastases in the LN. Based on the small number of patients our data need further investigation in larger cohorts. Furthermore, the use of dual labeling with <sup>99m</sup>Tc-nanocolloid and blue dye as well as the reason for omitting adjuvant therapy in a case of LN metastases was not evaluated, which is an important limitation of the study. The strengths of the present study, on the other hand, are the relatively large sample size of patients with this rare constellation of unilateral SLN metastasis and

contralateral lymphadenectomy and the high level of external validity (multicentric population-based study). Further studies should be performed to confirm our findings in larger cohorts of patients.

## 5 | CONCLUSION

The risk of contralateral LN metastases in patients with unilateral SLN metastases is low. However, the limitations do not allow us to draw general conclusions, whether contralateral lymphadenectomy should be performed or not. Further studies are needed.

## CONFLICTS OF INTEREST

None.

## AUTHOR CONTRIBUTIONS

TI, SI, HE, AI designed the study. TI, JG, JM collected clinical data. TI, JG, MB, HE, AI performed statistical analyses. SI, JM, OO, contributed methodological know-how. TI, JG, MB, HE, AI drafted the manuscript.

## ORCID

Atanas Ignatov  <https://orcid.org/0000-0002-9006-4029>

## REFERENCES

- National German Guideline S2k. Diagnosis, therapy, and follow-up care of vulvar cancer and its precursors, AWMF Registry No. 015/059. 2015
- Van der Zee AG, Oonk MH, De Hullu JA, et al. Sentinel node dissection is safe in the treatment of early-stage vulvar cancer. *J Clin Oncol.* 2008;26:884-889.
- Te Grootenhuis NC, van der Zee AG, van Doorn HC, et al. Sentinel nodes in vulvar cancer: Long-term follow-up of the GROningen International Study on Sentinel nodes in Vulvar cancer (GROINSS-V) I. *Gynecol Oncol.* 2016;140:8-14.
- Gonzalez Bosquet J, Magrina JF, Magtibay PM, et al. Patterns of inguinal groin metastases in squamous cell carcinoma of the vulva. *Gynecol Oncol.* 2007;105:742-746.
- Krupp PJ, Bohm JW. Lymph gland metastases in invasive squamous cell cancer of the vulva. *Am J Obstet Gynecol.* 1978;130:943-952.
- Nica A, Covens A, Vicus D, et al. Sentinel lymph nodes in vulvar cancer: Management dilemmas in patients with positive nodes and larger tumors. *Gynecol Oncol.* 2019;152:94-100.
- Woelber L, Eulenburg C, Grimm D, et al. The Risk of Contralateral Non-sentinel Metastasis in Patients with Primary Vulvar Cancer and Unilaterally Positive Sentinel Node. *Ann Surg Oncol.* 2016;23:2508-2514.
- ESGO guidelines: <https://guidelines.esgo.org/media/2016/08/ESGO-Vulvar-cancer-Complete-report-fox2.pdf>
- Ignatov T, Eggemann H, Burger E, Costa SD, Ignatov A. Adjuvant radiotherapy for vulvar cancer with close or positive surgical margins. *J Cancer Res Clin Oncol.* 2016;142:489-495.
- von Elm E, Altman DG, Egger M, et al. The Strengthening the Reporting of Observational Studies in Epidemiology (STROBE) statement: guidelines for reporting observational studies. *Lancet.* 2007;370:1453-1457.
- Andrews SJ, Williams BT, DePriest PD, et al. Therapeutic implications of lymph nodal spread in lateral T1 and T2 squamous cell carcinoma of the vulva. *Gynecol Oncol.* 1994;55:41-46.

12. Winarno AS, Mondal A, Martignoni FC, Fehm TN, Hampl M. The potential risk of contralateral non-sentinel groin node metastasis in women with early primary vulvar cancer following unilateral sentinel node metastasis: a single center evaluation in University Hospital of Dusseldorf. *BMC Womens Health*. 2021;21:23.
13. Garganese G, Collarino A, Fragomeni SM, et al. Groin sentinel node biopsy and <sup>18</sup>F-FDG PET/CT-supported preoperative lymph node assessment in cNO patients with vulvar cancer currently unfit for minimally invasive inguinal surgery: The GroSNaPET study. *Eur J Surg Oncol*. 2017;43:1776-1783.
14. Garganese G, Fragomeni SM, Pasciuto T, et al. Ultrasound morphometric and cytologic preoperative assessment of inguinal

lymph-node status in women with vulvar cancer: MorphoNode study. *Ultrasound Obstet Gynecol*. 2020;55:401-410.

**How to cite this article:** Ignatov T, Gaßner J, Bozukova M, et al. Contralateral lymph node metastases in patients with vulvar cancer and unilateral sentinel lymph node metastases. *Acta Obstet Gynecol Scand*. 2021;00:1–6. <https://doi.org/10.1111/aogs.14157>