



3-2021

## Electrosurgical bipolar vessel sealing for a standing flank ovariectomy in beef heifers

Joseph Smith  
jsmit604@utk.edu

Guillermo Salazar  
*ISU*

Ciara Peace  
*ISU*

Jeff D. Olivarez  
*ISU*

Katie Vermeulen  
*ISU*

*See next page for additional authors*

Follow this and additional works at: [https://trace.tennessee.edu/utk\\_largpubs](https://trace.tennessee.edu/utk_largpubs)



Part of the [Large or Food Animal and Equine Medicine Commons](#), [Surgery Commons](#), and the [Veterinary Anatomy Commons](#)

---

### Recommended Citation

Joe Smith, Guillermo Salazar, Ciara Peace, Jeff Olivarez, Katie Vermeulen, Kelley Black, Camille Guss, Dane Tatarniuk, Tyler Dohlman, Caitlin Wiley. Use of an electrosurgical vessel-sealing device for standing flank ovariectomy in heifers: Technical description and a case report. *Clinical Theriogenology*, 13(1); March 2021, p 60-67.

This Article is brought to you for free and open access by the Veterinary Medicine -- Faculty Publications and Other Works at TRACE: Tennessee Research and Creative Exchange. It has been accepted for inclusion in Faculty Publications and Other Works -- Large Animal Clinical Sciences by an authorized administrator of TRACE: Tennessee Research and Creative Exchange. For more information, please contact [trace@utk.edu](mailto:trace@utk.edu).

---

**Authors**

Joseph Smith, Guillermo Salazar, Ciara Peace, Jeff D. Olivarez, Katie Vermeulen, Kelley Black, Camille Guss, Dane Tatarniuk, Tyler Dohlman, and Caitlin Wiley

## Electrosurgical bipolar vessel sealing for a standing flank ovariectomy in beef heifers

Joe Smith,<sup>a,b,c,e</sup> Guillermo Salazar,<sup>c,\*</sup> Ciara Peace,<sup>c,\*</sup> Jeff Olivarez,<sup>a,b,c</sup> Katie Vermeulen,<sup>a,b</sup> Kelley Black,<sup>a,b</sup>  
Camille Guss,<sup>a,b</sup> Dane Tatarskiuk,<sup>d</sup> Tyler Dohleman,<sup>a,c</sup> Caitlin Wiley<sup>a,c</sup>

<sup>a</sup>Veterinary Diagnostic and Production Animal Medicine, <sup>b</sup>Biomedical Sciences

<sup>c</sup>Food Animal and Camelid Hospital

<sup>d</sup>Veterinary Clinical Sciences

Iowa State University, Ames, IA

<sup>e</sup>Large Animal Clinical Sciences, University of Tennessee, Knoxville, TN

\*Co-second Authors

### Abstract

Traditional ovariectomy techniques for heifers (e.g. colpotomy) have adverse effects ranging from hemorrhage to mortality. Electrosurgical bipolar vessel sealing devices offer a superior ligation of ovarian pedicle and associated structures. In ruminants, standing flank laparotomy has been used for abdominal visibility. We performed ovariectomy in 2 companion beef heifers via a unilateral flank approach, combined with electrosurgical ligation. Surgeries were performed in standing animals, under local anesthesia, with no observed short- or long-term adverse effects. This technique is worth considering for cases where the security of electrosurgical ligation combined with the accessibility of a flank laparotomy are desired. Additional research is needed to determine the viability of the technique for cattle of various ages and breeds.

**Keywords:** Cattle, laparotomy, ligasure, ovariectomy, spay

### Introduction

Various techniques are described for ovariectomy in bovine practice. Ovariectomy is performed to suppress estrus in feedlot heifers, for brucellosis control, for research purposes, and for diseased ovary removal.<sup>1</sup> While routine, surgical removal of bovine ovary is not without risks, as intraoperative and/or postoperative hemorrhage is a potential life threatening complication.<sup>2</sup> Vaginal approaches to ovariectomy, common in feedlot heifers, offer convenient access. However, care must be taken to avoid damaging viscera or uterine vessels by the ovariectomy instrument, as these approaches dictate that the technique is performed blind, albeit with guidance via transrectal palpation.<sup>1</sup> Flank approaches offer better visualization of the ovarian and uterine structures, but can still present challenges with hemostasis and suture security. Mortality from the current described techniques ranged from 0.26 - 6%, with certain animal welfare concerns.<sup>3,4</sup> In ovariectomy via colpotomy, as currently practiced, failure to confirm hemostasis after ovary removal increased risks of bleeding from the ovarian pedicle.<sup>5-7</sup>

Electrosurgical bipolar vessel sealing devices are utilized in multiple areas of veterinary medicine for hemostasis, ranging from small intestinal resection and anastomoses in horses<sup>8</sup> to enucleation in rabbits.<sup>9</sup> LigaSure<sup>TM</sup> (LS) is an electrosurgical bipolar vessel sealing device (Covidien LS1020 LigaSure Atlas, Medtronic, Minneapolis, MN) used in many areas of veterinary medicine to minimize hemorrhage and to reduce surgery time. The LS device was successfully used to seal vessels of  $\leq 7$  mm in diameter in equine models.<sup>8</sup> Use of this device had profoundly decreased hemorrhage in pet pig ovariohysterectomy procedures, wherein hemorrhage has been a complication associated with standard ligation technique.<sup>10,11</sup>

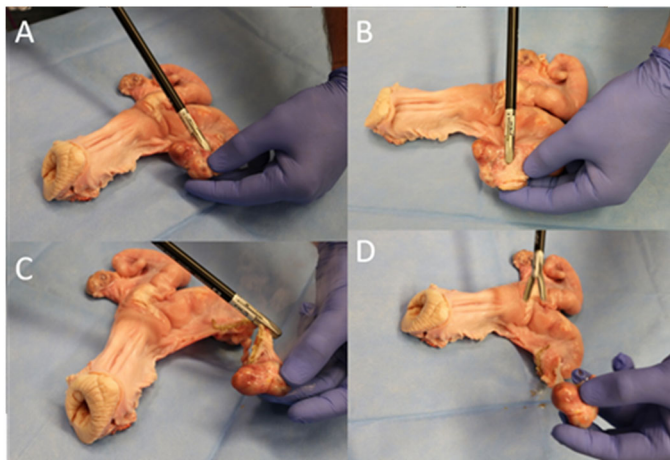
Recently laparoscopic ovariectomy with a LS device has been described for cattle.<sup>7</sup> Although this technique has multiple benefits, including a minimally invasive incision and direct observation of vessel sealing, it requires many people to manage equipment and 1 more person to provide guidance via transrectal palpation.<sup>7</sup> Another recent unilateral ovariectomy technique via flank incision used an endoscopic articulating linear cutter instrument for ligation.<sup>12</sup> Although this technique provided excellent visualization of structures and hemostasis, drawbacks exist in staples cost and possibility of foreign body (stainless steel staple) occurrence within the abdomen of a food animal, poses a safety risk in the 'food chain'. Therefore, the goal was to demonstrate the feasibility of adopting LS for hemostasis in a standing bilateral laparoscopic ovariectomy via a unilateral standard flank incision. This amalgamation of existing

techniques could allow for excellent hemostasis with the ease of a standard procedure performed through a conventional abdominal laparotomy approach.

## Method

### Ex vivo

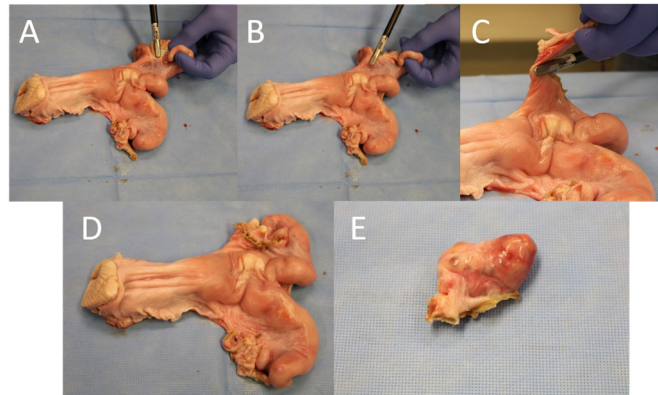
Procedure was refined on a cadaver bovine uterus (Figures 1 & 2). Initially, the right ovary was identified and held in the left hand of the operator. Ligation with the LS device started with the mesovarium and mesosalphinx, continuing with multiple bites until the right ovary was free from the broad ligament. Distal aspect of the right uterine horn was then evaluated for cauterization and released. Procedure was repeated for the left ovary.



**Figure 1.** Ex vivo description of right ovariectomy with Ligasure device. A. Right ovary held by operator's left hand, Ligasure jaws encompassing mesovarium, mesosalphinx, and uterine tube. B. Positioning of Ligasure jaws. C & D. After first cauterization, demonstrating advancement of Ligasure jaws through remaining mesovarium and broad ligament.

**Figure 2.** Ex vivo description of left ovariectomy.

A. Left ovary held by operator's left hand and Ligasure jaws encompassing mesovarium, mesosalphinx, and uterine tube.  
B. Placement of jaws after initial ligation, to further advance through mesovarium and broad ligament.  
C. Positioning for final advancement to ligate through remaining broad ligament  
D. Uterus after bilateral ovariectomy  
E. Ligated ovary, demonstrating ligation through pedicle and complete detachment of mesovarium and mesosalphinx.



## In vivo

Two 1-year old mixed breed intact beef heifers, owned by a local farm animal sanctuary, were presented for bilateral ovariectomy. Client elected this procedure due to the desire to eliminate mounting behavior exhibited by the heifers during estrus, as 1 of them was blind and presented a safety risk. Both heifers were on a grass hay diet and raised together in an ~ 2-acre paddock. They spent most of the day outside and went into an indoor stall at night.

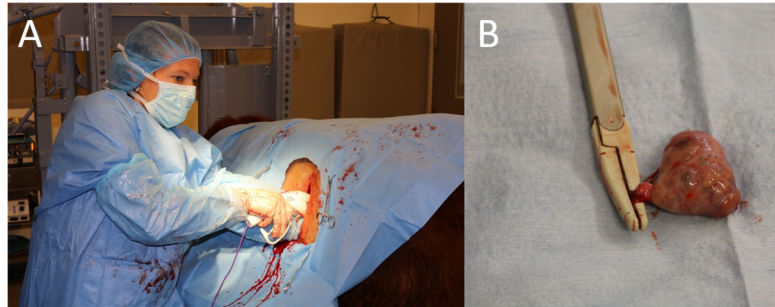
Heifer 1 was bright, alert and responsive, weighting 365 kg with a body condition score of 5/9. Physical examination findings were within normal limits. Packed cell volume (PCV) and total protein (TP) were within reference range at 31% and 6.8 g/dl respectively.

Heifer 2 was also bright, alert and responsive, weighing 319 kg with a body condition score of 4/9. She had bilateral absence of menace, dazzle and presence of pupillary light response reflexes and palpebral reflex. Both eyes also exhibited ventral strabismus, rotatory nystagmus, hypermature cataracts, uveitis, posterior synechiae, anterior synechiae, and retinal detachment. Despite being nonvisual, the second heifer was able to ambulate, eat and drink well on her own. No blepharospasm was observed. Through extensive previous workup and consultation with veterinary ophthalmology specialists, the heifer was determined to be in pain from her eye pathology and previous inflammation had been managed with oral meloxicam (Meloxicam Tablets USP, Zydus Pharmaceuticals, Pennington, NJ) and topical ketorolac (Ketorolac Ophthalmic Solution, Sandoz, Princeton, NJ). Heifer 2 had a grade V/VI, right basilar systolic heart murmur that was associated with a small, previously diagnosed, congenital ventricular septal defect. PCV and TP were within reference range at 36% and 6.6 g/dl respectively.

Both animals were deemed acceptable candidates for the surgical procedure and fasted for 24 hours prior to surgery. Prophylactic antibiotic coverage was provided subcutaneously with 2.5 mg/kg of tulathromycin (Draxxin, Zoetis, Parasippany-Hills, NJ). Preoperatively, 1.1 mg/kg of flunixin meglumine (Banamine, Merck, Kenilworth, NJ) was given intravenously and vaccinated with a booster vaccination for *Clostridium perfringens* (types C and D) and tetanus toxoid (BarVac CD/T, Boehringer Ingelheim, Ingelheim am Rhein, Germany).

Heifer 1 was premedicated intravenously with 0.05 mg/kg of butorphanol (Butorphanol, Akorn Inc., Lake Forest, IL) and intramuscularly with 5 mg of xylazine (Anased, Lloyd Labs, Shenandoah, IA). Heifer was placed in a mobile cattle restraint chute for the procedure. Left flank was clipped and aseptically prepared, first with a preliminary scrub and then in an aseptic fashion using chlorhexidine and alcohol. A distal paravertebral block was performed with 2% lidocaine (Lidocaine Injectable, Aspen Pharmaceuticals, Irvine, CA) on the spinous processes of the 1<sup>st</sup> lumbar, 2<sup>nd</sup> lumbar, and 4<sup>th</sup> lumbar vertebra, and a line block on the caudal flank area was performed, all with 2% lidocaine. The surgery site was finally aseptically prepared with alternating scrubs of chlorhexidine and alcohol. A 14 cm vertical incision was made using a #10 blade cranioventral to the tuber coxae. Skin, subcutaneous tissue, and external abdominal oblique were incised and the remaining muscle layers and peritoneum were bluntly dissected by hand in a grid technique. While incising through the body wall, bleeding was controlled by applying pressure to soft tissues with 4 x 4 gauze. Left and right ovaries were manually palpated and visually identified. Although ovaries were visualized, we were not able to completely exteriorize them to the level of the incision. A 37 mm LS (Covidien LS1020 LigaSure Atlas, Medtronic) was introduced into the abdomen (Figure 3a) with 1 hand over the jaws, protecting surrounding soft tissues. With 1 hand in the abdomen, the right ovary was isolated and the LS was placed caudal to the ovary, over the uterine tube, ensuring no other tissue was incorporated. Right ovarian pedicle was clamped, cauterized, severed, and the ovary was removed with the pedicle assessed with 4 x 4 gauze for bleeding prior to proceeding to the left ovary. Left ovary was then palpated, identified, and LS was used in the same manner to remove the ovary. Left pedicle was visually evaluated for any signs of hemorrhage and after examination was released back into the abdominal cavity. Peritoneum and transversus abdominus were closed with 1 polydioxanone suture (PDS II, Ethicon, US) in a simple continuous pattern. Remaining muscle layers and subcutaneous tissues were closed with 1 PDS in a simple continuous pattern. Skin was closed with 2-0 polyamide suture having 'S curved' needle (Braunamid, Braun, Tuttlingen, Germany) using a Ford

interlocking pattern. A single simple interrupted suture was placed at the ventral aspect of the incision. The area was cleaned, and an aluminum spray (Aluspray, Neogen, France) bandage was applied.



**Figure 3.** A: Position of the operator advancing the Ligasure device through a flank incision for ovarian ligation. B: Closeup view of the ovary after removal (note complete ligation through pedicle).

Heifer 2 was premedicated with butorphanol (Butorphanol, Akorn Inc.). Heifer was restrained, prepped and had a distal paravertebral nerve block as described for the first heifer. An additional inverted L block over the incision was performed with 2% lidocaine (Lidocaine Injectable, Aspen Pharmaceuticals). Surgery site was finally aseptically prepped with alternating scrubs of alcohol and chlorhexidine. A 15 cm vertical incision was made using a #10 blade cranial and ventral to the tuber coxae. Skin, subcutaneous tissue, and muscle layers were then dissected as described for the first heifer. LS was introduced, ovarian pedicles ligated, and incisions closed as described for the first heifer.

### Outcome

Duration of surgeries were 80 and 77 minutes respectively and heifers tolerated surgeries well. Ovaries appeared normal and had clear margins (Figure 3b). Day after surgery, heifer 1 had a PCV of 34% and TP of 6.8 g/dl and heifer 2 had 33% and 6.6 g/dl respectively. Transabdominal ultrasonography on day 2 postsurgery revealed no evidence of free fluid and peristalsis was noted in both heifers. Skin sutures were removed on day 10 postsurgery by the referring veterinarians and no complications were evident. Client reported at 8 months postovariectomy that there was no estrous behaviour in heifers.

### Discussion

In equine practice, ovariectomies are commonly performed for disease, performance, and behavioural reasons. We explored the feasibility of combining electrosurgical vessel sealing as described for laparoscopic ovariectomy in cattle and adopted a flank approach as described for unilateral ovariectomy.<sup>7,12</sup> Combination of these aspects formed a hybrid technique that was well tolerated by 2 heifers and allowed for a relatively quick ovariectomy with good vessel ligation. As anticipated, estrous behavior was absent and furthermore there were no postoperative complications.

Currently, specific effects of LS ovariectomy within the bovine abdomen or with respect to changes to the peritoneal environment are not known. Stallions that underwent standing laparoscopic cryptorchidectomy with a LS device had higher total nucleated cells in peritoneal fluid at 24 hours postprocedure compared to stallions that had standard ligatures.<sup>13</sup> However, at 72 hours, no differences were observed between groups for peritoneal nucleated cell count, red blood cell count, or total protein.<sup>13</sup> Although abdominocentesis was not performed in our cases, there was no clinical evidence of peritonitis as both heifers postsurgically had normal physical examination parameters and adequate appetite.

A unilateral ovariectomy technique utilizing a linear stapler that could potentially be modified for bilateral ovariectomy procedures in cattle was described.<sup>12</sup> However, a relative paucity of information exists regarding the migration of staples in cattle. In humans the migration and use of linear staples has led to multiple uncommon adverse effects, including volvulus, serosal laceration, and leakage.<sup>14-16</sup> Although beef heifers that had surgeries were companion animals, in the United States, companion food

animal species are still considered food animals from a regulatory perspective.<sup>17-19</sup> With this categorization leaving a metallic object in a food animal would be a food safety risk due to carcass contamination. Our technique would alleviate this carcass risk as no foreign material was used for ovarian ligation.

Tulathromycin was utilized as a prophylactic antimicrobial due to broad spectrum action and ability to penetrate into tissues.<sup>20,21</sup> Often anecdotally discussed for abdominal surgeries in the bovine, intraabdominal treatment of penicillin was not considered, due to no empirical data suggesting the superiority of this route of treatment.<sup>22</sup> In hindsight, antimicrobial prophylaxis may not have been necessary, as ovariectomies are generally clean procedures and both heifer surgeries were completed in < 90 minutes. Prevention of nociceptive pain wind-up was provided with premedication with a nonsteroidal antiinflammatory drug (NSAID) flunixin meglumine. Although not labelled for prevention or treatment of surgical pain, flunixin has been demonstrated to decrease cortisol concentrations in calves undergoing surgery.<sup>23</sup> Transitioning from 1 NSAID to another can potentially lead to complications, however there are several cases of ruminants being initially treated with a single dose of flunixin and then being transitioned to meloxicam without adverse effects.<sup>24,25</sup> Heifers in our case study did not demonstrate any evidence of abomasal ulceration and postoperatively were maintained on oral meloxicam (1 mg/kg) once daily for 5 days. Treatment with NSAIDs (ketoprofen or meloxicam) in dairy cows after flank laparotomy (rumen fistula placement) improved outcomes of pain with no difference between them.<sup>26</sup>

A higher fasting time of at least 36 hours was recommended<sup>27</sup> as a means to reduce rumen volume and increase visualization of the abdomen, although 24 hours may be sufficient.<sup>7</sup> We fasted the animals for 24 hours prior to surgery. Four authors of this report who performed surgeries were able to easily identify and manipulate both ovarian pedicles in each animal. Transrectal guidance by an assistant, as described for manipulation of the ovaries for laparoscopic ovariectomy in cattle,<sup>7</sup> was not necessary for our cases. However, this technique will be useful in cases difficult to identify and ligate an ovarian pedicle. If a unilateral approach is not sufficient for identification of the opposite ovary, a bilateral flank approach is warranted.<sup>27</sup>

Clinicians should exercise caution when using a LS or other electrosurgical device, since electric sparks are possible with electrosurgical instruments.<sup>28</sup> Additionally, authors took care to identify ovarian pedicle with their hand to avoid thermal injury to adjacent tissues. Thermal injury after LS procedures has been reported in people, with specific examples being anal stenosis after LS hemorrhoidectomy,<sup>29</sup> and ureteral lesions after perirenal fat dissection.<sup>30</sup> According to the manufacturer, the tissue sealed and cauterized with a LS can reach 100°C that can spread laterally to up to 2 mm.<sup>30</sup> Additionally, care should be taken to not include too much tissue in the instrument jaws, as this could lead to unnecessarily repeated cycles, and increased lateral thermal damage. Caution should be used to clearly ligate only the ovarian pedicle and no surrounding tissues.

Standing sedation was achieved with butorphanol in heifer 2 with additional xylazine (5 mg, total dose) in heifer 1. While both surgeries were completed in a timely fashion, future applications of this technique could evaluate other sedation techniques such as the butorphanol-ketamine-xylazine for standing sedation.<sup>31</sup> While generally regarded as safe, clinicians should be aware that this combination has been associated with regurgitation in other large ruminant species, so care should be taken when assessing patients for this sedation technique.<sup>32</sup>

Pain scores are not known for LS procedures compared to standard technique in cattle. In cats undergoing, LS versus open ovariectomy, no difference in pain scores were noted.<sup>33</sup> Similarly, in women undergoing hysterectomy via LS or RoBi bipolar forceps, no difference was noted between groups and postoperative pain scoring.<sup>34</sup> In mares undergoing laparoscopic ovariectomy, pain was reduced by the mesovarian injection of lidocaine, when compared to intraovarian injection.<sup>35</sup> Epidural anaesthesia has also been of benefit for cattle undergoing laparotomy.<sup>36,37</sup> Future investigation of our technique could involve mesovarian lidocaine injection and epidural anaesthesia.

In other species, primarily dogs and cats, there are reports of remnants of ovarian tissue revascularizing and contributing to signs of estrus and cyclicity. In previously mentioned techniques for ovariectomy in cattle, ovaries are generally dropped into abdomen after excision (as with the Willis spay

tool). There are little to no reported data that proves this is a potential complication in cattle. This was attributed to ovariectomies being primarily done in heifers that enter a feedlot where their lifespan is too short to observe any potential effects of revascularization. For large animals, options include colpotomy, laparoscopic, ventral, and flank incisions. In mares, standing laparoscopic ovariectomy may be performed for elective or pathologic conditions.<sup>38-41</sup> Standing laparoscopic ovariectomy in mares provided good access with low morbidity regardless of the method of hemostasis used (linear stapler, bipolar sealing device, modified Roeder's knot, vessel sealing system or laser).<sup>42</sup> However, 11% of mares that developed some form of a postoperative complication, ranging from incisional seromas and infection to fever and abdominal discomfort.<sup>42</sup> Additionally, mares that underwent standing laparoscopic ovariectomy had similar cortisol concentrations, regardless of the method of mepivacaine application (topical or injection into ovarian pedicle).<sup>43</sup> Similar studies are needed in cattle.

'Dropped ovaries' revascularizing in omentum is possible in mares, however, not confirmed when a mare was examined several months after a procedure.<sup>44</sup> Generally, mares live much longer than several months and the question of whether revascularization can occur may still remain. Ovarian remnant revascularization and hormone production occurred in 8 of 9 cats.<sup>45</sup> Since these heifers reside at a farm sanctuary where they are likely to live for multiple years beyond the lifespan of a normal production animal, removal of ovaries as described reduces any risk of potential revascularization of the ovaries.

We recognize the limitations (small number of animals and the controlled conditions in which the procedures were performed) of our report. While the heifers were clinically observed for 4 days postoperatively, they were not evaluated via abdominocentesis for inflammatory changes. Future studies need to evaluate the effect of LS ovariectomy on inflammation in the abdominal environment, as well as pain from the technique. Further exploration of the feasibility of the technique in cattle of various breeds and ages, as the heifers in our study were young and both of beef breeds. The LS is not the only electronic vessel sealing device in practice, additional investigations on the use of other devices (e.g. ENSEAL<sup>®</sup> [SurgRx, Redwood City, CA] used for equine ovariectomy<sup>46</sup>) are warranted.

## Conclusion

Ovariectomy using a LS device through flank laparotomy incision was well-tolerated in heifers with no adverse effects or complications. Electrosurgical vessel-sealing (via a LS device) for standing flank ovariectomy was feasible. Although not necessarily practical in a field setting (on farm), a left flank approach for bilateral LS ovariectomy is worth considering to minimize complications (reduced haemorrhage, no foreign material left in abdomen, and complete removal of ovaries).

## Conflict of interest

None to declare.

## References

1. Prado TM, Schumacher J, Dawson LJ: Surgical procedures of the genital organs of cows. *Vet Clin North Am Food Anim* 2016;32:727-752.
2. Marchionatti E, Nichols S, Babkine M, et al: Outcome following partial unilateral hysterectomy by standing flank approach in dairy cattle. *Vet Surg* 2016;45:943-948.
3. McCosker K, Letchford P, Petherick JC, et al: Morbidity, mortality and body weight gain of surgically spayed, yearling Brahman heifers. *Aust Vet J* 2010;88:497-503.
4. Jubb TF, Fordyce G, Bolam MJ, et al: Trial introduction of the Willis dropped ovary technique for spaying cattle in northern Australia. *Aust Vet J* 2003;81:66-70.
5. Habermehl NL: Heifer ovariectomy using the Willis spay instrument: Technique, morbidity and mortality. *Can Vet J* 1993;34:664-667.
6. Rupp GP, Kimberling CV: A new approach for spaying heifers. *Vet Med Sm Anim Clin* 1982;77:561-565.
7. Sato R, Kanai E, Kitahara G, et al: Transrectal guidance of the ovaries reduces operative time during bovine laparoscopic ovariectomy. *J Vet Med Sci* 2017;79:2019-2022.
8. Rumbaugh ML, Burba DJ, Natalini C, et al: Evaluation of a vessel-sealing device for small intestinal resection and anastomosis in normal horses. *Vet Surg* 2003;32:574-579.
9. Moore BA, Robertson J, Tarbert DK, et al: A novel surgical technique for enucleation in rabbits to reduce the risk of intra- and post-operative orbital hemorrhage. *Vet Ophthalmol* 2020;23:409-413.
10. Biedrzycki A, Brounts SH: A less invasive technique for spaying pet pigs. *Vet Surg* 2013;42:346-352.



11. Cypher E, Videla R, Pierce R, et al: Clinical prevalence and associated intraoperative surgical complications of reproductive tract lesions in pot-bellied pigs undergoing ovariectomy: 298 cases (2006-2016). *Vet Rec* 2017;181:685.
12. Rizzo A, Piccinno M, Lacitignola L, et al: Application of an innovative technique for unilateral ovariectomy in dairy cows. *Vet Rec* 2016;179:463.
13. Seabaugh KA, Goodrich LR, Morley PS, et al: A comparison of peritoneal fluid values after laparoscopic cryptorchidectomy using a vessel-sealing device versus a ligating loop and removal of the descended testis. *Vet Surg* 2013;42:600-606.
14. Kim R, Moore R, Schmidt L, et al: Volvulus caused by a free intraperitoneal staple after laparoscopic appendectomy: a case report. *Int J Surg Case Rep* 2019;65:259-261.
15. Matsuzawa F, Homma S, Yoshida T, et al: Serosal laceration during firing of powered linear stapler is a predictor of staple malformation. *Surg Innov* 2017;24:590-597.
16. Lee S, Ahn B. The relationship between the number of intersections of staple lines and anastomotic leakage after the use of a double stapling technique in laparoscopic colorectal surgery. *Surg Laparosc Endosc Percutan Tech* 2017;27:273-281.
17. Lord LK, Wittum TE: Survey of humane organizations and slaughter plants regarding experiences with Vietnamese potbellied pigs. *J Am Vet Med Assoc* 1997;211:562-565.
18. Smith J, Cuneo M, Walton R, et al: Spontaneous pneumothorax in a companion Kunekune pig due to pulmonary bullae rupture. *Journal of Exotic Pet Medicine* 2020;34:6-9.
19. Schleining JA, Bergh MS: Surgical correction of angular and torsional metatarsal deformity with cylindrical osteotomy and locking compression plates in a calf. *Vet Surg* 2014;43:563-568.
20. Lin Z, He C, Magstadt DR, et al: Tissue residue depletion and estimation of extralabel meat withdrawal intervals for tulathromycin in calves after pneumatic dart administration. *J Anim Sci* 2019;97:3714-3726.
21. Smith JS, Mochel JP, Borts DJ, et al: Effects of experimentally induced respiratory disease on the pharmacokinetics and tissue residues of tulathromycin in meat goats. *J Vet Pharmacol Ther* 2019;42:420-429.
22. O'Connor AM, Gould SA, Coetzee JF, et al: What Is the Evidence? *J Vet Clin North Am Food Anim* 2011;239:314-316.
23. Kleinhenz M, Van Engen N, Smith J, et al: The impact of transdermal flunixin meglumine on biomarkers of pain in calves when administered at the time of surgical castration without local anesthesia. *Livest Sci* 2018;212:1-6.
24. Breuer R, Merkatoris P, Tepley S, et al: Treatment of cerebrospinal nematodiasis in a Boer buck. *Vet Rec Case Rep* 2019;7:e000706.
25. Smith J, Klostermann C, Harm T, et al: Abomasal hamartoma in a La Mancha wether. *Vet Rec Case Rep* 2017;5:e000515.
26. Newby NC, Tucker CB, Pearl DL, et al: Short communication: a comparison of 2 nonsteroidal antiinflammatory drugs following the first stage of a 2-stage fistulation surgery in dry dairy cows. *J Dairy Sci* 2013;96:6514-6519.
27. Bleul U, Hollenstein K, Kahn W: Laparoscopic ovariectomy in standing cows. *Anim Reprod Sci* 2005;90:193-200.
28. Stormont G, Deibert CM: Surgical Fire Safety. StatPearls. Treasure Island; StatPearls Publishing LLC: 2020.
29. Gravante G, Venditti D: Postoperative anal stenoses with ligasure hemorrhoidectomy. *World J Surg* 2007;31:245-245.
30. Selli C, Turri FM, Gabellieri C, et al: Delayed-onset ureteral lesions due to thermal energy: an emerging condition. *Arch Ital Urol Androl* 2014;86:152-153.
31. Abrahamsen EJ: Chemical Restraint and Injectable Anesthesia of Ruminants. *Vet Clin North Am Food Anim* 2013;29:209-227.
32. Smith JS, Sheley M, Chigerwe M: Aspiration pneumonia in two Tibetan yak bulls (*Bos grunniens*) as a complication of ketamine-xylazine-butorphanol anesthesia for recumbent castration. *J Zoo Wildl Med* 2018;49:242-246.
33. Coisman JG, Case JB, Shih A, et al: Comparison of surgical variables in cats undergoing single-incision laparoscopic ovariectomy using a LigaSure or extracorporeal suture versus open ovariectomy. *Vet Surg* 2014;43:38-44.
34. Taskin S, Sukur YE, Altin D, et al: Bipolar energy instruments in laparoscopic uterine cancer surgery: a randomized study. *J Laparoendosc Adv Surg Tech A* 2018;28:645-649.
35. Farstvedt EG, Hendrickson DA: Intraoperative pain responses following intraovarian versus mesovarian injection of lidocaine in mares undergoing laparoscopic ovariectomy. *J Am Vet Med Assoc* 2005;227:593-596.
36. Baniadam A, Afshar FS, Ahmadian F: Analgesic effects of tramadol hydrochloride administered via caudal epidural injection in healthy adult cattle. *Am J Vet Res* 2010;71:720-725.
37. Fierheller EE, Caulkett NA, Bailey JV: A romifidine and morphine combination for epidural analgesia of the flank in cattle. *Can Vet J* 2004;45:917-923.
38. Hubert JD, Burba DJ, Moore RM: Evaluation of a vessel-sealing device for laparoscopic granulosa cell tumor removal in standing mares. *Vet Surg* 2006;35:324-329.
39. Petrizzi L, Guerri G, Straticò P, et al: Laparoscopic ovariectomy in standing mule mares. *J Equine Vet Sci* 2020;44:102857.
40. Smith SE, Devine DV: Hand-assisted laparoscopic ovariectomy and colpotomy in standing mares. *Vet Surg* 2013;42:586-590.
41. Seabaugh KA, Schumacher J: Urogenital surgery performed with the mare standing. *Vet Clin North Am Equine* 2014;30:191-209.

42. Röcken M, Mosel G, Seyrek-Intas K, et al: Unilateral and bilateral laparoscopic ovariectomy in 157 mares: a retrospective multicenter study. *Vet Surg* 2011;40:1009-1014.
43. Koch DW, Easley JT, Hatzel JN, et al: Prospective randomized investigation of topical anesthesia during unilateral laparoscopic ovariectomy in horses. *Vet Surg* 2020;49 Suppl 1:O54-o59.
44. Shoemaker RW, Read EK, Duke T, et al: In situ coagulation and transection of the ovarian pedicle: an alternative to laparoscopic ovariectomy in juvenile horses. *Can J Vet Res* 2004;68:27-32.
45. DeNardo GA, Becker K, Brown NO, et al: Ovarian remnant syndrome: revascularization of free-floating ovarian tissue in the feline abdominal cavity. *J Am Anim Hosp Assoc* 2001;37:290-296.
46. Dunay MP, Németh T, Makra Z, et al: Laparoscopic cryptorchidectomy and ovariectomy in standing horses using the EnSeal<sup>®</sup> tissue-sealing device. *Acta Vet Hung* 2012;60:41-53.