

Henry Ford Health

Henry Ford Health Scholarly Commons

Orthopedics Articles

Orthopedics / Bone and Joint Center

5-1-2021

Ultrasound shear wave elastography and its association with rotator cuff tear characteristics

Rebekah L. Lawrence

Henry Ford Health, RLawren2@hfhs.org

Matthew C. Ruder

Henry Ford Health, mruder1@hfhs.org

Vasilios Moutzouros

Henry Ford Health, VMOUTZO1@hfhs.org

Eric C. Makhni

Henry Ford Health, emakhni1@hfhs.org

Stephanie J. Muh

Henry Ford Health, Smuh1@hfhs.org

See next page for additional authors

Follow this and additional works at: https://scholarlycommons.henryford.com/orthopaedics_articles

Recommended Citation

Lawrence RL, Ruder MC, Moutzouros V, Makhni EC, Muh SJ, Siegal D, Soliman SB, van Holsbeeck M, Bey MJ. Ultrasound shear wave elastography and its association with rotator cuff tear characteristics. JSES Int 2021; 5(3):500-506.

This Article is brought to you for free and open access by the Orthopedics / Bone and Joint Center at Henry Ford Health Scholarly Commons. It has been accepted for inclusion in Orthopedics Articles by an authorized administrator of Henry Ford Health Scholarly Commons.

Authors

Rebekah L. Lawrence, Matthew C. Ruder, Vasilios Moutzouros, Eric C. Makhni, Stephanie J. Muh, Daniel Siegal, Steven B. Soliman, Marnix van Holsbeeck, and Michael J. Bey



Ultrasound shear wave elastography and its association with rotator cuff tear characteristics

Rebekah L. Lawrence, PT, PhD^{a,*}, Matthew C. Ruder, MS^a, Vasilios Moutzouros, MD^b, Eric C. Makhni, MD, MBA^b, Stephanie J. Muh, MD^b, Daniel Siegal, MD^c, Steven B. Soliman, DO, RMSK^c, Marnix van Holsbeeck, MD^c, Michael J. Bey, PhD^a

^a Bone and Joint Center, Henry Ford Health System, Detroit, MI, USA

^b Department of Orthopaedic Surgery, Henry Ford Health System, Detroit, MI, USA

^c Department of Radiology, Henry Ford Health System, Detroit, MI, USA

ARTICLE INFO

Keywords:

Ultrasound shear wave elastography
Rotator cuff
Tear size
Fatty degeneration
Atrophy
Mechanical properties

Level of Evidence: Level III; Diagnostic study

Background: Approximately 20-60% of rotator cuff repairs fail with higher failure rates in patients with larger or more chronic tears. Although MRI provides an objective estimate of tear size, it can only provide qualitative descriptions of tear chronicity. By contrast, ultrasound shear wave elastography (SWE) may assess tear chronicity by estimating tissue mechanical properties (ie, shear modulus). Furthermore, SWE imaging does not share many of the challenges associated with MRI (eg, high cost, risk of claustrophobia). Therefore, the objective of this study was to determine the extent to which estimated supraspinatus shear modulus is associated with conventional MRI-based measures of rotator cuff tear size and chronicity.

Methods: Shear modulus was estimated using ultrasound SWE in two regions of the supraspinatus (intramuscular tendon, muscle belly) under two contractile conditions (passive, active) in 22 participants with full-thickness rotator cuff tears. The extent to which estimated supraspinatus shear modulus is associated with conventional MRI measures of tear size and chronicity was assessed using correlation coefficients and Kruskal-Wallis tests, as appropriate.

Results: Estimated shear modulus was not significantly associated with anterior/posterior tear size ($P > .09$), tear retraction ($P > .20$), occupation ratio ($P > .11$), or fatty infiltration ($P > .30$) under any testing condition.

Discussion: Although ultrasound SWE measurements have been shown to be altered in the presence of various tendinopathies, the findings of this study suggest the utility of ultrasound SWE in this population (ie, patients with a small to medium supraspinatus rotator cuff tear) before surgical rotator cuff repair remains unclear.

© 2021 The Author(s). Published by Elsevier Inc. on behalf of American Shoulder and Elbow Surgeons. This is an open access article under the CC BY-NC-ND license (<http://creativecommons.org/licenses/by-nc-nd/4.0/>).

Rotator cuff tears are common, affecting about 40% of the population over the age of 60 years^{30,39,55} and are often associated with significant pain and dysfunction.⁴⁴ If conservative treatment does not improve the patient's symptoms or quality of life, rotator cuff repair is often considered and accounts for approximately 250,000 surgical procedures in the United States each year.⁴ Unfortunately, an estimated 20-60% of rotator cuff repairs fail.⁴⁵ Previous studies have suggested that the risk for repair failure is higher in patients with larger tears^{2,8,34,54} or with more muscle atrophy²¹ or fatty

degeneration.^{8,10,23,42} Consequently, assessing these characteristics has emerged as an important step during the crucial presurgical phase to inform patient counseling and surgical planning.

Magnetic resonance imaging (MRI) is currently the predominant method for assessing rotator cuff tear characteristics (ie, size) and chronicity (ie, atrophy, fatty degeneration) for preoperative planning. Although MRI provides an objective estimate of tear size, it is limited to providing only qualitative descriptions of tear chronicity. For example, the degree of fatty degeneration present within the muscle is typically described using the Goutallier classification.^{15,22} This classification, which uses an ordinal scale (grades 0-IV), has been shown to have low to moderate reliability^{28,36,50,51} and only assesses a single MRI image slice, which may not be predictive of 3D measurements.⁵³ Therefore, the ability to objectively and reliably assess tear chronicity remains a challenge.

This study was approved by the Henry Ford Health System's Institutional Review Board (study number 12162).

* Corresponding author: Rebekah L. Lawrence, PT, PhD, Bone and Joint Center, Henry Ford Health System, 6135 Woodward Avenue Detroit, MI 48202, USA.

E-mail address: rlawren2@hfhs.org (R.L. Lawrence).

<https://doi.org/10.1016/j.jseint.2020.11.008>

2666-6383/© 2021 The Author(s). Published by Elsevier Inc. on behalf of American Shoulder and Elbow Surgeons. This is an open access article under the CC BY-NC-ND license (<http://creativecommons.org/licenses/by-nc-nd/4.0/>).

Shear wave elastography (SWE) is an emerging ultrasound-based technology that may provide a quantitative assessment of tear chronicity by estimating tissue mechanical properties (ie, shear modulus). Specifically, SWE provides an indirect measure of a tissue's mechanical properties by quantifying the speed at which sound waves propagate through soft tissue (ie, shear wave speed).^{13,17} As such, SWE may provide important and currently lacking information on rotator cuff tear chronicity that is needed to optimize presurgical planning. Furthermore, SWE has potential added clinical benefit compared with MRI because of its lower cost and ability to image patients for whom MRI is not an option due to issues such as claustrophobia or the presence of metal implants. However, the relationship between estimated supraspinatus shear modulus and conventional MRI-based measures of tear chronicity remain unclear. Therefore, the objective of this study is to determine the extent to which estimated supraspinatus shear modulus is associated with conventional MRI-based measures of rotator cuff tear size (anterior/posterior tear size, degree of tendon retraction) and chronicity (fatty degeneration, atrophy). We hypothesized that estimated supraspinatus shear modulus would be significantly associated with measures of rotator cuff tear size and chronicity.

Materials and methods

Participants

After institutional review board approval and obtaining written informed consent, 22 participants were enrolled in this study. Eligible participants were aged 50–80 years, scheduled to undergo surgical repair of a small- or medium-sized full-thickness supraspinatus tear (<3 cm), and had a preoperative MRI within their medical record. Participants were excluded if they had symptoms that started after trauma, received more than one steroid injection, had a BMI >30 kg/m², an outstanding worker's compensation claim, previous shoulder surgery, or currently smoked. Participant demographic data are presented in Table I. Preoperative patient-reported shoulder pain and function was assessed using the visual analog scale and Western Ontario Rotator Cuff (WORC) Index,³³ respectively.

Experimental assessment of tear size and chronicity: ultrasound shear wave elastography

Ultrasound SWE images were acquired using a Siemens ACUSON S3000 and a 9L4 (4–9 MHz) linear transducer (Siemens; Erlangen, German). Supraspinatus shear wave speed was assessed on each participant's involved shoulder in two regions (intramuscular tendon, muscle belly) under two contractile conditions

Table I

Demographic and patient-reported outcome measures for all participants (n = 31).

Variable	Mean ± SD or %
Demographics	
Age	61 ± 7 years
Sex (% female)	18.2
BMI*	26.3 ± 3.1 kg/m ²
Involved side (% dominant)	63.6
Patient-reported measures	
Symptom duration	9 ± 8 months
VAS [†] (best in last week)	2 ± 2
VAS (worst in last week)	8 ± 2
WORC [‡] (% function)	37 ± 16

* Body mass index.

[†] Visual analog scale.

[‡] Western Ontario Rotator Cuff Index.

(passive, active). The same researcher acquired all ultrasound images, which were collected in the same order for all participants (passive intramuscular tendon, active intramuscular tendon, passive muscle, active muscle). Preliminary work established the reliability of the protocol (ICCs: intra-rater >0.87, inter-rater >0.72).⁵

Ultrasound SWE image acquisition was performed with the participant seated with his/her shoulder in 30° of scapular plane abduction and forearm supported on a pillow. Shoulder position was verified before image acquisition using a standard clinical goniometer. For imaging the intramuscular tendon, the transducer was placed 1–2 cm anterior to the scapular spine and medial to the acromioclavicular joint and aligned with the intramuscular tendon. For imaging the muscle, the transducer was placed 1–2 cm medial to the intramuscular tendon and aligned with the muscle fibers. During the active conditions, the participants were asked to gently lift (ie, abduct) and hold his/her forearm so that it was no longer supported by the pillow. Minor adjustments were made to the ultrasound transducer's orientation, as necessary, to accommodate any changes in the tissue's location within the ultrasound image caused by muscle contraction. Typically, the process of reorienting the transducer took less than 3 seconds and the participant remained in the isometric hold position until the trial image was acquired. Participants rested for approximately 10 seconds between trials. Five trials were collected for each combination of region (intramuscular tendon, muscle belly) and condition (passive, active). Each trial resulted in the acquisition of a brightness mode (B-mode) image and a corresponding SWE image.

Estimated shear modulus was limited to the region of interest (ie, muscle, intramuscular tendon) by first isolating the region from surrounding tissue on the B-mode images using ImageJ⁴⁶ integrated into a custom MATLAB program (The MathWorks, Inc.; Natick, MA, USA). The program subsequently verified the shear waveforms for each pixel within the region of interest on the corresponding SWE image using Siemens' proprietary quality metric. A quality threshold of 0.87 was used according to manufacturer recommendations. Each pixel's shear wave speed was subsequently converted to an estimated shear modulus using the following equation:

$$\mu = c_s^2 \rho$$

where μ is the estimated shear modulus, c_s is the pixel's shear wave speed, and ρ is the tissue density, which was assumed to be 1000 kg/m³ for soft tissues.¹³ Next, for each trial image, the estimated shear modulus within the region of interest was calculated as the median value across all quality-verified pixels because the distribution of estimated moduli was typically skewed. Finally, the mean shear modulus was calculated across trials for each combination of region and condition resulting in four shear moduli estimates for each participant.

Clinical assessment of tear size and chronicity: conventional MRI imaging

A board-certified musculoskeletal radiologist with 15 years of experience read the preoperative MRI for all study participants. Clinical scans were typically performed on a 1.5T scanner and included axial and oblique sagittal proton density images with fat suppression, oblique coronal and oblique sagittal T1-weighted images without fat suppression, and oblique coronal T2-weighted images with fat suppression. The radiologist was blinded to the ultrasound SWE results. Outcome measures included anterior/posterior tear size, degree of tendon retraction, supraspinatus atrophy using the tangent sign,⁵⁶ and supraspinatus fatty

Table II
Descriptive statistics for conventional MRI-based measures of tear chronicity.

MRI measure	Mean \pm SD or %
Supraspinatus tear size	
Anterior/posterior (cm)	1.6 \pm 0.6
Retraction (cm)	1.7 \pm 0.6
Involved tendons (%)	
Isolated supraspinatus	54.5
Supraspinatus and infraspinatus	27.3
Supraspinatus and subscapularis	18.2
Fatty degeneration (Goutallier)	
Grade 0 (%)	72.7
Grade 1 (%)	27.3
Grade 2 (%)	0
Grade 3 (%)	0
Grade 4 (%)	0
Muscle atrophy	
Occupation ratio (%)	65 \pm 13
Tangent sign (% positive)	9.1

Calculation for involved tendons includes partial- or full-thickness tears of the infraspinatus and subscapularis.

degeneration using the Goutallier classification^{15,22} (Table II). In addition, supraspinatus occupation ratio was calculated using a method described previously.⁵² To ensure a reliable assessment of fatty degeneration, a second board-certified musculoskeletal radiologist with 11 years of experience also scored each MRI in accordance with the Goutallier classification (agreement: 77.3%). The Goutallier scores from the more experienced radiologist were used for the statistical analysis.

Statistical analysis

The extent to which SWE-estimated supraspinatus shear modulus is associated with conventional MRI measures of supraspinatus tear size and atrophy was assessed using correlation coefficients and 95% confidence intervals. Comparison of estimated shear modulus between Goutallier grades was assessed using Kruskal-Wallis tests due to non-normal data. Separate analyses were performed for each combination of region (intramuscular tendon, muscle) and condition (passive, active). All statistical analyses were performed using R (R Core Team, 2018). Statistical significance was defined as $P < .05$.

Results

On average (\pm standard deviation), participants were 61 ± 7 years of age with a medium-sized supraspinatus tear (1.6 ± 0.6 cm) with retraction (1.7 ± 0.6 cm), mild atrophy (9.1% positive tangent sign), and mild to no fatty degeneration (100% Goutallier grades 0 or 1). Participants reported moderate shoulder disability (WORC: $37 \pm 16\%$). Full participant demographic and patient-reported outcome measures are presented in Table I, and conventional MRI-based measures of tear size and chronicity are presented in Table II.

Estimated shear modulus was not correlated to anterior/posterior tear size ($P > .09$) (Fig. 1, A), tear retraction ($P > .20$) (Fig. 1, B), or occupation ratio ($P > .11$) (Fig. 2) under any testing condition. Furthermore, estimated shear modulus was not significantly different between Goutallier grades under any testing condition ($P > .30$) (Fig. 3).

Discussion

The objective of this study was to determine the extent to which ultrasound SWE-estimated supraspinatus shear modulus is

associated with conventional MRI-based measures of rotator cuff tear size (anterior/posterior tear size, degree of tendon retraction) and chronicity (fatty degeneration, atrophy). Contrary to our hypothesis, estimated supraspinatus shear modulus was not significantly associated with any measure of preoperative tear size or chronicity. Although ultrasound SWE measurements (ie, estimated shear modulus and/or shear wave speed) have been shown to be altered in the presence of various tendinopathies,^{9,11,35} the findings of this study suggest the utility of ultrasound SWE in patients before surgical rotator cuff repair remains unclear. However, the lack of significant findings in the present study may highlight fundamental differences between how conventional MRI-imaging and ultrasound SWE assess rotator cuff tears, and the challenges associated with using ultrasound SWE to assess full-thickness tendon tears. Understanding these factors will help inform further technology development and research protocol refinement and interpret ultrasound SWE findings when used in clinical practice.

An important fundamental difference between conventional MRI and ultrasound SWE imaging is the nature of the tissue characteristics being assessed. Specifically, conventional MRI imaging assesses structural and compositional changes within the muscle-tendon unit (eg, tear size, presence of fat), whereas ultrasound SWE is capable of assessing aspects of tissue quality (ie, modulus).^{13,17} Therefore, it may not be surprising that SWE measurements were not found to be associated with conventional MRI-based measures of rotator cuff integrity because the technologies assess two different constructs (ie, tissue structure and composition vs. quality). Clinically, it may be beneficial to utilize both technologies to provide information on both aspects of rotator cuff health for preoperative planning. This premise is supported by a recent cadaveric study that showed that the ability to predict supraspinatus extensibility was significantly improved by combining ultrasound SWE with MRI imaging to estimate tissue stiffness and fatty degeneration, respectively.¹⁷ However, more research is needed to determine the extent to which the combination of these modalities improves the prediction of tissue extensibility in living humans and, subsequently, the efficacy and cost-effectiveness of using multiple imaging modalities during presurgical planning.

The potential for ultrasound SWE to assess tissue quality is based on its ability to estimate material properties (ie, modulus). However, it is important to recognize that SWE measurements are influenced not only by the tissue's material properties but also tissue tension,³⁷ and this factor likely influenced the results of the study. Under highly controlled *in vitro* experiments where tissue tension can be prescribed, variability in SWE estimates of shear modulus have been shown to account for 33%–98% of the variability in mechanical properties depending on the experimental approach.^{13,17} However, under *in vivo* testing conditions, ultrasound SWE measures are likely to be influenced by additional sources of tension including the tissue's contractile state^{6,31,37} and length.^{25,40} Consequently, when two SWE-estimated shear modulus measurements collected under *in vivo* conditions are compared, a higher shear wave speed may indicate the tissue has a higher modulus, is under more tension, or both. Unfortunately, differentiating between these factors so that the underlying tissue material properties can be assessed remains challenging, which necessitates highly controlled testing conditions. Even so, SWE measurement reliability under *in vivo* conditions is typically low to moderate,^{5,24,43} underscoring the sensitivity of SWE measurements to these factors and others (eg, anisotropy).

Given the challenges associated with acquiring and interpreting SWE data under *in vivo* conditions, it may not be surprising that SWE-estimated shear modulus was not associated with any

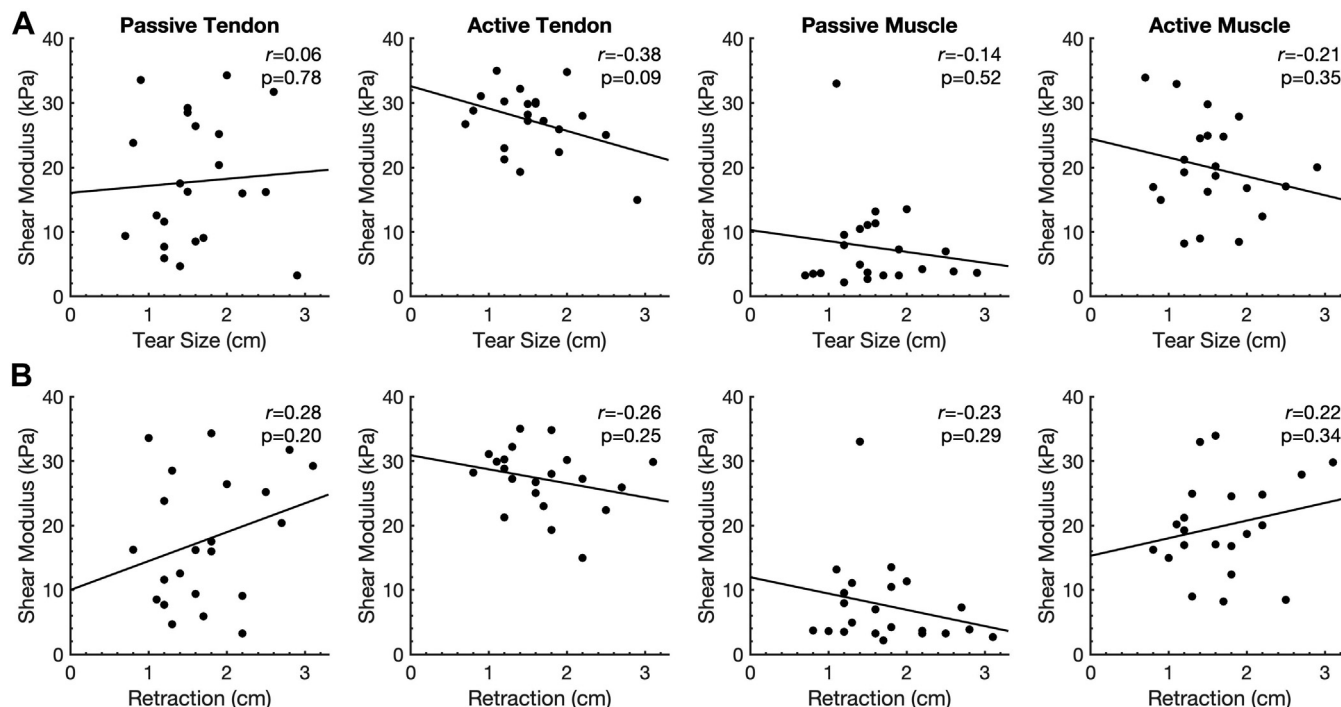


Figure 1 Correlations between tear dimensions and estimated supraspinatus shear modulus for each combination of region (intramuscular tendon, muscle) and condition (passive, active): (A) anterior/posterior tear size, (B) tear retraction.

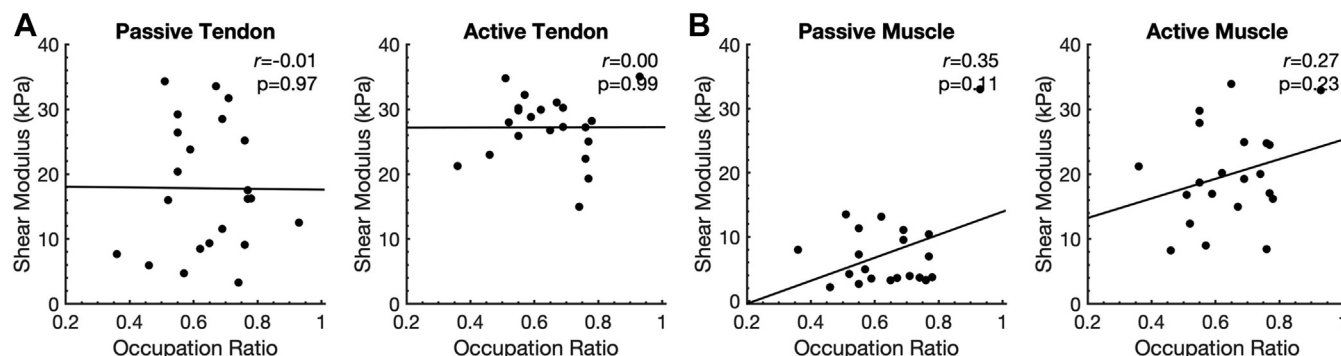


Figure 2 Correlations between occupation ratio and estimated supraspinatus shear modulus for each combination of region (intramuscular tendon, muscle) and condition (passive, active): (A) anterior/posterior tear size, (B) tear retraction.

individual variable of supraspinatus tear size (anterior/posterior tear size, degree of tendon retraction) or chronicity (Goutallier grade, occupation ratio). Although variables were assessed individually, clinically they occur in combination. Consequently, the relationship between the estimated shear modulus and any individual tear characteristic or chronicity variable is likely confounded if coexisting variables have opposing influences on SWE measurements. For example, a supraspinatus muscle with a high degree of fatty degeneration (which often occurs in larger and more chronic rotator cuff tears^{18,30}) would be expected to have a lower estimated shear modulus than a healthy rotator cuff because fat presumably has a lower SWE measurement than muscle. However, a chronic rotator cuff tear may be stiffer due to tendon retraction and fibrosis,^{16,20,26,47,48} thus resulting in a higher SWE measurement. Consequently, these two mechanisms—ie, fatty degeneration and retraction/fibrosis—may be confounding factors in the interpretation of SWE-estimated shear modulus.

Another example of how the relationship between the SWE-estimated shear modulus and individual variables of tear size or chronicity may have been confounded in the present study relates to the potential impact anterior/posterior tear size has on the passive tension within the musculotendinous unit. Specifically, it has been hypothesized that the passive tension within the supraspinatus may decrease as the anterior/posterior tear size increases because the tendon is no longer fully anchored to the bone.¹⁴ Conversely, previous research has found that the supraspinatus muscle elastic modulus increases as tear sizes increases.⁴⁹ Therefore, it is possible that opposing influences confounded the SWE-estimated shear modulus, and subsequently its relationship with supraspinatus anterior/posterior tear size. Ultimately, these two examples illustrate that in this study, the relationship between SWE measurements and any individual variable describing tear size or chronicity may have been confounded by complex interactions between multiple factors with opposing influences on estimated

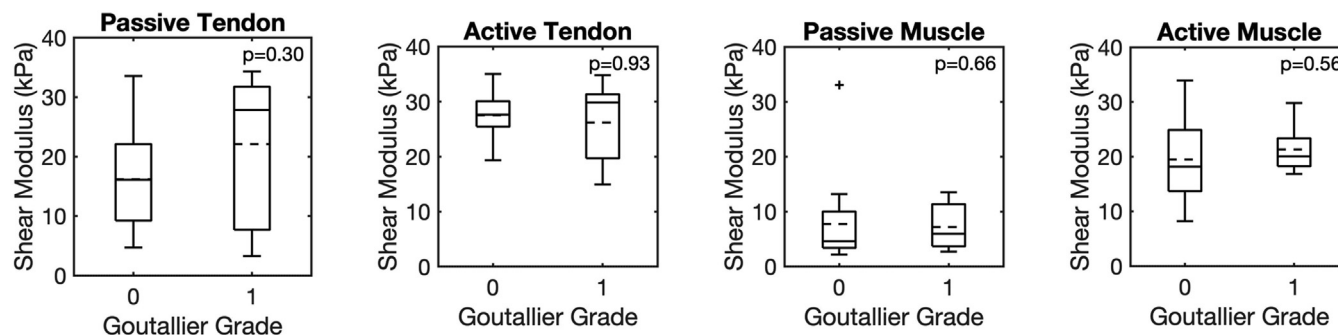


Figure 3 Comparison of estimated supraspinatus shear modulus across Goutallier grades for each combination of region (intramuscular tendon, muscle) and condition (passive, active). On each box, the *solid line* indicates the median, the *dashed line* represents the mean, the *bottom and top edges* indicate the 25th and 75th percentiles, respectively. The *whiskers* extend to the most extreme data points not considered outliers, and the outliers are plotted individually using the '+' symbol.

shear modulus. A larger and more diverse sample (ie, more variability in tear characteristics and chronicity) is necessary to understand the extent to which a combination of tear characteristics and chronicity impacts SWE measurements in an effort to maximize the clinical utility of this technology.

It is possible that other factors not assessed in this study may have influenced SWE measurements. For example, the location of the tear within the supraspinatus tendon—and specifically whether the tear involved the rotator cuff cable—may have influenced the tension within the musculotendinous unit and thus SWE measurements. For example, previous research has shown that supraspinatus tears involving the rotator cuff cable reduce the stiffness of the musculotendinous unit more than tears involving the rotator cuff crescent.³⁸ This data suggests that the rotator cuff cable's theorized stress-shielding role may help preserve the passive tension within the supraspinatus as long as the cable remains intact. Therefore, it is possible that involvement of the rotator cuff cable influences SWE measurements. However, this remains speculative as the present study was unable to assess whether participants' rotator cuff tears involved the cable. Furthermore, the results of the study suggest that the variability between subjects in SWE measurements cannot be fully explained by tear characteristics. Subject-specific factors (eg, genetics) whose influence is not yet fully understood may have contributed to this intersubject variability. Normalizing SWE measures to a contralateral side may help reduce intersubject variability. However, the utility of this approach is unclear given it may only reduce intersubject variability when the contralateral rotator cuff is free of pathology. Consequently, future research is needed to better understand the influence of various tear characteristics and subject-specific factors on SWE measurements.

Although this study found that SWE-estimated shear modulus was not significantly associated with any individual tear characteristic or chronicity variable, its potential clinical utility may fulfill an entirely different clinical need. Specifically, chronic tendon rupture is associated with a stiffening of the musculotendinous unit^{16,19,26,47,48} which will presumably cause the repaired tendon to be under higher tension once anchored to the bone during surgical repair. Importantly, intraoperative repair tension is associated with higher rates of repair failure.^{2,32} Unfortunately, there is currently no method to predict surgical repair tension in advance, which hinders its utility as a predictive biomarker during presurgical planning or to guide the selection, intensity, and pace of postoperative rehabilitation. However, the sensitivity of SWE measurements to tissue tension may make it a candidate technology for noninvasively predicting repair tension. This premise is supported by a previous study that reported a strong association between SWE-estimated

shear modulus in the deep posterior region of the supraspinatus and intraoperative estimates of supraspinatus stiffness.²⁷ Future research will investigate the extent to which preoperative SWE measurements predict repair failure to investigate the technology's potential to guide preoperative surgical and postoperative rehabilitation decision-making.

This study has limitations that should be considered when interpreting the results. First, recruitment was targeted to individuals scheduled to undergo arthroscopic rotator cuff repair, which limited the inclusion of individuals with small- or medium-sized tears. Consequently, the variability between participants in measures of tear characteristics and chronicity was limited, which may have impacted our ability to detect potentially meaningful relationships. Future studies may benefit from including individuals with large or massive tears by including patients preparing to undergo reverse total shoulder arthroplasty to ensure a broad distribution of rotator cuff tear characteristics and chronicity. Second, female participants were under-represented in the study sample because of lower than expected enrollment within this demographic. Although there is evidence females may have a higher estimated shear modulus than males,¹² this study was not designed to investigate gender-based differences. Future research may benefit from larger samples that allow stratification based on gender. Third, the use of the ordinal Goutallier classification likely impacts the precision with which fatty degeneration can be assessed. This factor, combined with the low variability in Goutallier grades, likely hindered our ability to fully assess the relationship between SWE measurements and fatty degeneration. Future studies may benefit from assessing fatty degeneration using more objective measures such as the MRI-based Dixon technique.^{1,29,41} Finally, although previous work established the reliability of the data collection protocol used in this study,⁵ SWE measurements are often challenging to standardize as they are sensitive to many factors including joint position,^{7,25} muscle contraction,^{6,7} and transducer pressure.³ Consequently, the methodology of this study was specifically designed to minimize these effects by standardizing patient position, ensuring the same SWE operator for all subjects, and using custom software run by a single operator to quantitatively calculate measures of shear wave speed.

Conclusions

SWE-estimated shear modulus was not associated with any individual variable of supraspinatus tear characteristics (anterior/posterior tear size, retraction) or chronicity (Goutallier grade, occupation ratio). Although ultrasound SWE measurements have been shown to be altered in the presence of various tendinopathies,

the findings of this study suggest the utility of ultrasound SWE in this population (ie, patients with a small supraspinatus rotator cuff tear) before surgical rotator cuff repair remains unclear.

Disclaimers:

Funding: This work was supported by the National Institutes of Health (grant number R21AR072785). The NIH did not play a role in the design, conduct, or reporting of this study.

Conflicts of Interest: The authors, their immediate families, and any research foundations with which they are affiliated have not received any financial payments or other benefits from any commercial entity related to the subject of this article.

References

- Agten CA, Roskopf AB, Gerber C, Pfirrmann CW. Quantification of early fatty infiltration of the rotator cuff muscles: comparison of multi-echo Dixon with single-voxel MR spectroscopy. *Eur Radiol* 2016;26:3719-27. <https://doi.org/10.1007/s00330-015-4144-y>.
- Ahmad S, Haber M, Bokor DJ. The influence of intraoperative factors and postoperative rehabilitation compliance on the integrity of the rotator cuff after arthroscopic repair. *J Shoulder Elbow Surg* 2015;24:229-35. <https://doi.org/10.1016/j.jse.2014.06.050>.
- Alfuraih AM, O'Connor P, Hensor E, Tan AL, Emery P, Wakefield RJ. The effect of unit, depth, and probe load on the reliability of muscle shear wave elastography: variables affecting reliability of SWE. *J Clin Ultrasound* 2018;46:108-15. <https://doi.org/10.1002/jcu.22534>.
- American Academy of Orthopaedic Surgeons. *Management of Rotator Cuff Injuries Clinical Practice Guidelines*. Rosemont, IL, USA: American Academy of Orthopaedic Surgery; 2019.
- Baumer TG, Davis L, Dischler J, Siegal DS, van Holsbeeck M, Moutzouros V, et al. Shear wave elastography of the supraspinatus muscle and tendon: repeat-ability and preliminary findings. *J Biomech* 2017;53:201-4. <https://doi.org/10.1016/j.jbiomech.2017.01.008>.
- Baumer TG, Dischler J, Davis L, Labyed Y, Siegal DS, van Holsbeeck M, et al. Effects of age and pathology on shear wave speed of the human rotator cuff. *J Orthop Res* 2018;36:282-8. <https://doi.org/10.1002/jor.23641>.
- Chernak LA, DeWall RJ, Lee KS, Thelen DG. Length and activation dependent variations in muscle shear wave speed. *Physiol Meas* 2013;34:713-21. <https://doi.org/10.1088/0967-3334/34/6/713>.
- Choi S, Kim MK, Kim GM, Roh YH, Hwang IK, Kang H. Factors associated with clinical and structural outcomes after arthroscopic rotator cuff repair with a suture bridge technique in medium, large, and massive tears. *J Shoulder Elbow Surg* 2014;23:1675-81. <https://doi.org/10.1016/j.jse.2014.02.021>.
- Coombes BK, Tucker K, Vicenzino B, Vuvan V, Mellor R, Heales L, et al. Achilles and patellar tendinopathy display opposite changes in elastic properties: a shear wave elastography study. *Scand J Med Sci Sports* 2018;28:1201-8. <https://doi.org/10.1111/sms.12986>.
- Deniz G, Kose O, Tugay A, Guler F, Turan A. Fatty degeneration and atrophy of the rotator cuff muscles after arthroscopic repair: does it improve, halt or deteriorate? *Arch Orthop Trauma Surg* 2014;134:985-90. <https://doi.org/10.1007/s00402-014-2009-5>.
- Dirrichs T, Quack V, Gatz M, Tingart M, Kuhl CK, Schrading S. Shear wave elastography (SWE) for the evaluation of patients with tendinopathies. *Acad Radiol* 2016;23:1204-13. <https://doi.org/10.1016/j.acra.2016.05.012>.
- Eby SF, Cloud BA, Brandenburg JE, Giambini H, Song P, Chen S, et al. Shear wave elastography of passive skeletal muscle stiffness: influences of sex and age throughout adulthood. *Clin Biomech* 2015;30:22-7. <https://doi.org/10.1016/j.clinbiomech.2014.11.011>.
- Eby SF, Song P, Chen S, Chen Q, Greenleaf JF, An KN. Validation of shear wave elastography in skeletal muscle. *J Biomech* 2013;46:2381-7. <https://doi.org/10.1016/j.jbiomech.2013.07.033>.
- Frisch KE, Marcu D, Baer GS, Thelen DG, Vanderby R. Influence of tendon tears on ultrasound echo intensity in response to loading. *J Biomech* 2014;47:3813-9. <https://doi.org/10.1016/j.jbiomech.2014.10.026>.
- Fuchs B, Weishaupt D, Zanetti M, Hodler J, Gerber C. Fatty degeneration of the muscles of the rotator cuff: assessment by computed tomography versus magnetic resonance imaging. *J Shoulder Elbow Surg* 1999;8:599-605.
- Gerber C, Meyer DC, Schneeberger AG, Hoppeler H, von Rechenberg B. Effect of tendon release and delayed repair on the structure of the muscles of the rotator cuff: an experimental study in sheep. *J Bone Joint Surg Am* 2004;86:1973-82. <https://doi.org/10.2106/00004623-200409000-00016>.
- Giambini H, Hatta T, Rezaei A, An KN. Extensibility of the supraspinatus muscle can be predicted by combining shear wave elastography and magnetic resonance imaging-measured quantitative metrics of stiffness and volumetric fat infiltration: a cadaveric study. *Clin Biomech* 2018;57:144-9. <https://doi.org/10.1016/j.clinbiomech.2018.07.001>.
- Gilbert F, Meffert RH, Schmalz J, Weng AM, Kostler H, Eden L. Grade of retraction and tendon thickness correlates with MR-spectroscopically measured amount of fatty degeneration in full thickness supraspinatus tears. *BMC Musculoskelet Disord* 2018;19:197. <https://doi.org/10.1186/s12891-018-2096-5>.
- Gimbel JA, Mehta S, Van Kleunen JP, Williams GR, Soslowky LJ. The tension required at repair to reappose the supraspinatus tendon to bone rapidly increases after injury. *Clin Orthop Relat Res* 2004;258-65. <https://doi.org/10.1097/01.blo.0000136831.17696.80>.
- Gimbel JA, Van Kleunen JP, Mehta S, Perry SM, Williams GR, Soslowky LJ. Supraspinatus tendon organizational and mechanical properties in a chronic rotator cuff tear animal model. *J Biomech* 2004;37:739-49. <https://doi.org/10.1016/j.jbiomech.2003.09.019>.
- Gladstone JN, Bishop JY, Lo IK, Flatow EL. Fatty infiltration and atrophy of the rotator cuff do not improve after rotator cuff repair and correlate with poor functional outcome. *Am J Sports Med* 2007;35:719-28. <https://doi.org/10.1177/0363546506297539>.
- Goutallier D, Postel JM, Bernageau J, Lavau L, Voisin MC. Fatty muscle degeneration in cuff ruptures. Pre- and postoperative evaluation by CT scan. *Clin Orthop Relat Res* 1994;78-83.
- Goutallier D, Postel JM, Gleyze P, Leguilloux P, Van Driessche S. Influence of cuff muscle fatty degeneration on anatomic and functional outcomes after simple suture of full-thickness tears. *J Shoulder Elbow Surg* 2003;12:550-4. <https://doi.org/10.1016/S1058274603002118>.
- Hackett L, Aveludo R, Lam PH, Murrell GA. Reliability of shear wave elastography ultrasound to assess the supraspinatus tendon: an intra and inter-rater in vivo study. *Shoulder Elbow* 2020;12:18-23. <https://doi.org/10.1177/1758573218819828>.
- Hatta T, Giambini H, Uehara K, Okamoto S, Chen S, Sperling JW, et al. Quantitative assessment of rotator cuff muscle elasticity: reliability and feasibility of shear wave elastography. *J Biomech* 2015;48:3853-8. <https://doi.org/10.1016/j.jbiomech.2015.09.038>.
- Hersche O, Gerber C. Passive tension in the supraspinatus musculotendinous unit after long-standing rupture of its tendon: a preliminary report. *J Shoulder Elbow Surg* 1998;7:393-6.
- Itoigawa Y, Maruyama Y, Kawasaki T, Wada T, Yoshida K, An KN, et al. Shear wave elastography can predict passive stiffness of supraspinatus musculotendinous unit during arthroscopic rotator cuff repair for presurgical planning. *Arthroscopy* 2018;34:2276-84. <https://doi.org/10.1016/j.arthro.2018.01.059>.
- Jo CH, Shin JS. Changes in appearance of fatty infiltration and muscle atrophy of rotator cuff muscles on magnetic resonance imaging after rotator cuff repair: establishing new time-zero traits. *Arthroscopy* 2013;29:449-58. <https://doi.org/10.1016/j.arthro.2012.10.006>.
- Khanna R, Saltzman MD, Elliott JM, Hoggarth MA, Marra GM, Omar I, et al. Development of 3D method to assess intramuscular spatial distribution of fat infiltration in patients with rotator cuff tear: reliability and concurrent validity. *BMC Musculoskelet Disord* 2019;20:295. <https://doi.org/10.1186/s12891-019-2631-z>.
- Kim HM, Dahiya N, Teefey SA, Middleton WD, Stobbs G, Steger-May K, et al. Location and initiation of degenerative rotator cuff tears: an analysis of three hundred and sixty shoulders. *J Bone Joint Surg Am* 2010;92:1088-96. <https://doi.org/10.2106/JBJS.I.00686>.
- Kim K, Hwang HJ, Kim SG, Lee JH, Jeong WK. Can shoulder muscle activity be evaluated with ultrasound shear wave elastography? *Clin Orthop Relat Res* 2018;476:1276-83. <https://doi.org/10.1097/01.blo.0000533628.06091.0a>.
- Kim DH, Jang YH, Choi YE, Lee HR, Kim SH. Evaluation of repair tension in arthroscopic rotator cuff repair: does it really matter to the integrity of the rotator cuff? *Am J Sports Med* 2016;44:2807-12. <https://doi.org/10.1177/0363546516651831>.
- Kirkley A, Alvarez C, Griffin S. The development and evaluation of a disease-specific quality-of-life questionnaire for disorders of the rotator cuff: the Western Ontario Rotator Cuff Index. *Clin J Sport Med* 2003;13:84-92. <https://doi.org/10.1097/00042752-200303000-00004>.
- Le BT, Wu XL, Lam PH, Murrell GA. Factors predicting rotator cuff retears: an analysis of 1000 consecutive rotator cuff repairs. *Am J Sports Med* 2014;42:1134-42. <https://doi.org/10.1177/0363546514525336>.
- Lee SU, Joo SY, Kim SK, Lee SH, Park SR, Jeong C. Real-time sonoelastography in the diagnosis of rotator cuff tendinopathy. *J Shoulder Elbow Surg* 2016;25:723-9. <https://doi.org/10.1016/j.jse.2015.10.019>.
- Lippe J, Spang JT, Leger RR, Arciero RA, Mazzocca AD, Shea KP. Inter-rater agreement of the Goutallier, Patte, and Warner classification scores using preoperative magnetic resonance imaging in patients with rotator cuff tears. *Arthroscopy* 2012;28:154-9. <https://doi.org/10.1016/j.arthro.2011.07.016>.
- Martin JA, Brandon SCE, Keuler EM, Hermus JR, Ehlers AC, Segalman DJ, et al. Gauging force by tapping tendons. *Nat Commun* 2018;9:1592. <https://doi.org/10.1038/s41467-018-03797-6>.
- Mesiha MM, Derwin KA, Sibole SC, Erdemir A, McCarron JA. The biomechanical relevance of anterior rotator cuff cable tears in a cadaveric shoulder model. *J Bone Joint Surg Am* 2013;95:1817-24. <https://doi.org/10.2106/JBJS.L.00784>.
- Milgrom C, Schaffler M, Gilbert S, van Holsbeeck M. Rotator-cuff changes in asymptomatic adults. The effect of age, hand dominance and gender. *J Bone Joint Surg Br* 1995;77:296-8.

40. Nishishita S, Hasegawa S, Nakamura M, Umegaki H, Kobayashi T, Ichihashi N. Effective stretching position for the supraspinatus muscle evaluated by shear wave elastography in vivo. *J Shoulder Elbow Surg* 2018;27:2242-8. <https://doi.org/10.1016/j.jse.2018.06.003>.
41. Nozaki T, Tasaki A, Horiuchi S, Osakabe C, Ohde S, Saida Y, et al. Quantification of fatty degeneration within the supraspinatus muscle by using a 2-point dixon method on 3-T MRI. *AJR Am J Roentgenol* 2015;205:116-22. <https://doi.org/10.2214/AJR.14.13518>.
42. Ohzono H, Gotoh M, Nakamura H, Honda H, Mitsui Y, Kakuma T, et al. Effect of preoperative fatty degeneration of the rotator cuff muscles on the clinical outcome of patients with intact tendons after arthroscopic rotator cuff repair of large/massive cuff tears. *Am J Sports Med* 2017;45:2975-81. <https://doi.org/10.1177/0363546517724432>.
43. Peltz CD, Haladik JA, Divine G, Siegal D, van Holsbeeck M, Bey MJ. ShearWave elastography: repeatability for measurement of tendon stiffness. *Skeletal Radiol* 2013;42:1151-6. <https://doi.org/10.1007/s00256-013-1629-0>.
44. Roe Y, Bautz-Holter E, Juel NG, Soberg HL. Identification of relevant International Classification of Functioning, Disability and Health categories in patients with shoulder pain: a cross-sectional study. *J Rehabil Med* 2013;45:662-9. <https://doi.org/10.2340/16501977-1159>.
45. Rossi LA, Chahla J, Verma NN, Millett PJ, Ranalletta M. Rotator cuff retears. *JBJS Rev* 2020;8:e0039. <https://doi.org/10.2106/JBJS.RVW.19.00039>.
46. Rueden CT, Schindelin J, Hiner MC, DeZonia BE, Walter AE, Arena ET, et al. ImageJ2: ImageJ for the next generation of scientific image data. *BMC Bioinformatics* 2017;18:529. <https://doi.org/10.1186/s12859-017-1934-z>.
47. Safiran O, Derwin KA, Powell K, Iannotti JP. Changes in rotator cuff muscle volume, fat content, and passive mechanics after chronic detachment in a canine model. *J Bone Joint Surg Am* 2005;87:2662-70. <https://doi.org/10.2106/JBJS.D.02421>.
48. Sato EJ, Killian ML, Choi AJ, Lin E, Esparza MC, Galatz LM, et al. Skeletal muscle fibrosis and stiffness increase after rotator cuff tendon injury and neuromuscular compromise in a rat model. *J Orthop Res* 2014;32:1111-6. <https://doi.org/10.1002/jor.22646>.
49. Silldorff MD, Choo AD, Choi AJ, Lin E, Carr JA, Lieber RL, et al. Effect of supraspinatus tendon injury on supraspinatus and infraspinatus muscle passive tension and associated biochemistry. *J Bone Joint Surg Am* 2014;96:e175. <https://doi.org/10.2106/JBJS.M.01315>.
50. Slabaugh MA, Friel NA, Karas V, Romeo AA, Verma NN, Cole BJ. Interobserver and intraobserver reliability of the Goutallier classification system using magnetic resonance imaging: proposal of a simplified classification system to increase reliability. *Am J Sports Med* 2012;40:1728-34. <https://doi.org/10.1177/0363546512452714>.
51. Spencer EE Jr, Dunn WR, Wright RW, Wolf BR, Spindler KP, McCarty E, et al. Interobserver agreement in the classification of rotator cuff tears using magnetic resonance imaging. *Am J Sports Med* 2008;36:99-103. <https://doi.org/10.1177/0363546507307504>.
52. Thomazeau H, Rolland Y, Lucas C, Duval JM, Langlais F. Atrophy of the supraspinatus belly. Assessment by MRI in 55 patients with rotator cuff pathology. *Acta Orthop Scand* 1996;67:264-8.
53. Vidt ME, Santago AC 2nd, Tuohy CJ, Poehling GG, Freehill MT, Kraft RA, et al. Assessments of fatty infiltration and muscle atrophy from a single magnetic resonance image slice are not predictive of 3-dimensional measurements. *Arthroscopy* 2016;32:128-39. <https://doi.org/10.1016/j.arthro.2015.06.035>.
54. Wu XL, Briggs L, Murrell GA. Intraoperative determinants of rotator cuff repair integrity: an analysis of 500 consecutive repairs. *Am J Sports Med* 2012;40:2771-6. <https://doi.org/10.1177/0363546512462677>.
55. Yamamoto A, Takagishi K, Osawa T, Yanagawa T, Nakajima D, Shitara H, et al. Prevalence and risk factors of a rotator cuff tear in the general population. *J Shoulder Elbow Surg* 2010;19:116-20. <https://doi.org/10.1016/j.jse.2009.04.006>.
56. Zanetti M, Gerber C, Hodler J. Quantitative assessment of the muscles of the rotator cuff with magnetic resonance imaging. *Invest Radiol* 1998;33:163-70.