

Henry Ford Health

Henry Ford Health Scholarly Commons

Rheumatology Articles

Rheumatology

6-27-2021

Prevalence of avascular necrosis in idiopathic inflammatory myositis: a single center experience.

Khalil I. Bourji

Henry Ford Health, kbourji1@hfhs.org

Christopher A. Mecoli

Julie J. Paik

Jemima Albayda

Eleni Tiniakou

See next page for additional authors

Follow this and additional works at: https://scholarlycommons.henryford.com/rheumatology_articles

Recommended Citation

Bourji KI, Mecoli CA, Paik JJ, Albayda J, Tiniakou E, Kelly W, Lloyd TE, Mammen A, Ahlawat S, and Christopher-Stine L. Prevalence of avascular necrosis in idiopathic inflammatory myositis: a single center experience. *Rheumatology (Oxford)* 2021.




This Article is brought to you for free and open access by the Rheumatology at Henry Ford Health Scholarly Commons. It has been accepted for inclusion in Rheumatology Articles by an authorized administrator of Henry Ford Health Scholarly Commons.

Authors

Khalil I. Bourji, Christopher A. Mecoli, Julie J. Paik, Jemima Albayda, Eleni Tiniakou, William Kelly, Thomas E. Lloyd, Andrew Mammen, Shivani Ahlawat, and Lisa Christopher-Stine

Original article

Prevalence of avascular necrosis in idiopathic inflammatory myopathies: a single-centre experience

Khalil I. Bourji ^{1,*}, Christopher A. Mecoli ^{2,*}, Julie J. Paik ², Jemima Albayda², Eleni Tiniakou², William Kelly², Thomas E. Lloyd³, Andrew Mammen^{3,4}, Shivani Ahlawat⁵ and Lisa Christopher-Stine²

Abstract

Objectives. To assess the prevalence of avascular necrosis (AVN) in a large cohort of patients with idiopathic inflammatory myopathies (IIM) and define the major associated risk factors.

Methods. We retrospectively reviewed the electronic medical records of all patients with a definitive diagnosis of IIM enrolled in our registry between 2003 and 2017, and followed until 2020. Pertinent demographic, clinical, serologic and imaging data were collected. A matched group of patients without AVN was then selected for comparison.

Results. A total of 1680 patients were diagnosed with IIM. Fifty-one patients developed AVN, with an overall prevalence of 3%. Musculoskeletal MRI was available for 1085 patients and AVN was present in 46 patients (43 lower extremities and 3 upper extremities MRI studies), with a relative prevalence of 4.2%. Most patients with AVN were Caucasian females (57%) with a mean (s.d.) age at diagnosis of 44.5 (12.4) years. Sixty-one percent had DM and 29% had PM. The median time from onset of IIM to diagnosis of AVN was 46 months. The hip joint was most commonly involved in 76% of cases, followed by the knee joint in 15% and shoulder joint in 9%. Some 81% of patients were asymptomatic. Established risk factors for AVN were not found to be associated with the development of AVN in IIM patients.

Conclusion. Although mostly asymptomatic and incidental, the overall prevalence of AVN in IIM was 3% and the prevalence by MRI was 4.2%. None of the established risk factors was found to be associated with AVN development.

Key words: avascular necrosis, osteonecrosis, AVN, myositis

Rheumatology key messages

- Prevalence of avascular necrosis in a large single-centre cohort of idiopathic inflammatory myopathies was ~3%.
- Most cases were asymptomatic, revealed on musculoskeletal MRI done for evaluation of idiopathic inflammatory myopathies.
- Established risk factors were not associated with avascular necrosis development in idiopathic inflammatory myopathies.

¹Division of Rheumatology, Wayne State University/Henry Ford Health System, Detroit, MI, ²Division of Rheumatology, ³Department of Neurology, Johns Hopkins University School of Medicine, Baltimore, ⁴Muscle Disease Unit, National Institute of Arthritis and Musculoskeletal and Skin Diseases, National Institutes of Health, Bethesda and ⁵Department of Radiology and Radiological Science, Johns Hopkins University School of Medicine, Baltimore, MD, USA
Submitted 2 March 2021; accepted 7 June 2021

Correspondence to: Lisa Christopher-Stine, Division of Rheumatology, Johns Hopkins University School of Medicine, 5200 Eastern Avenue, Mason F. Lord Center Tower, Suite 4500, Baltimore, MD 21224, USA.
E-mail: lchrist4@jhmi.edu

*Khalil I. Bourji, Christopher A. Mecoli contributed equally to this study.

Introduction

Avascular necrosis (AVN), also known as osteonecrosis when diaphyseal in location, is the death of bone due to interruption of vascular supply. Although AVN is often related to a direct trauma, it is not unusual to observe this complication in a variety of systemic diseases, particularly when other well-recognized risk factors (e.g. CS, alcohol or tobacco use, or hyperlipidaemia) are associated [1]. AVN is a frequently reported complication of systemic inflammatory illnesses, such as SLE and IBD [2–4], with strong attribution to CS exposure

[5]. Idiopathic inflammatory myopathies (IIM), a heterogeneous group of autoimmune disorders that predominantly affect skeletal muscles, share with SLE many clinical, pathogenic and therapeutic features (musculo-skeletal presentation, autoimmunity and CS use, respectively). However, unlike in SLE, few studies describing AVN in IIM exist. Hence, we sought to assess the prevalence of AVN in our IIM cohort and define associated risk factors.

Methods

Patient population

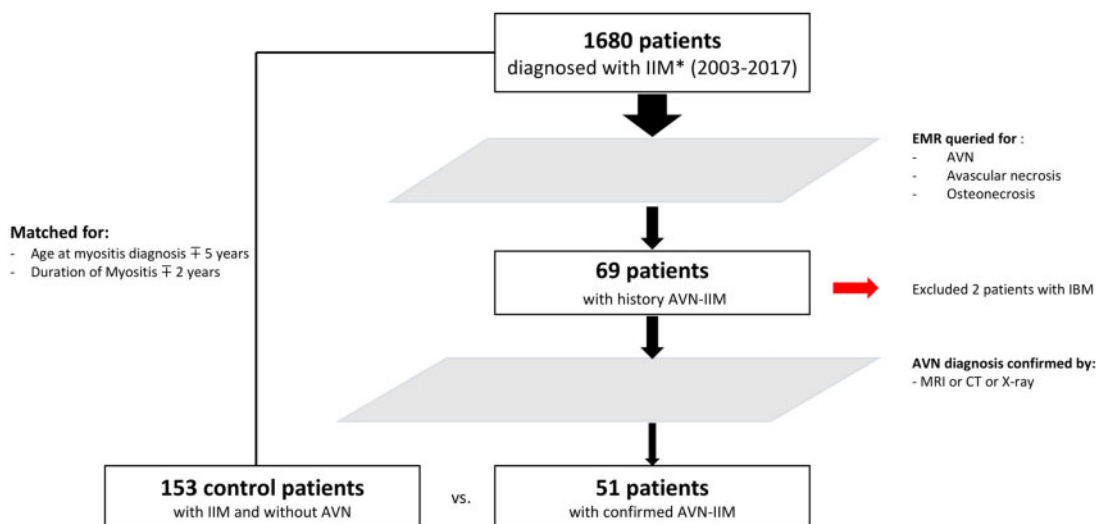
This is a retrospective observational study that included all patients enrolled in the Johns Hopkins Myositis Registry between January 2003 and December 2017, and followed until December 2020. Written informed consents were obtained from all patients included in the registry. This study was covered by the Johns Hopkins Institutional Review Board approval number NA0007454. In order to identify patients who developed AVN, the electronic medical record (The Johns Hopkins EPIC Electronic Medical Record) was queried for keywords including 'avascular necrosis', 'AVN' and 'osteonecrosis' (Fig. 1). Patients' electronic medical records were then reviewed and pertinent demographic, clinical and imaging data collected including: age at myositis diagnosis, sex, race, AVN diagnosis date, presence of symptoms at AVN diagnosis, presence of major risk factors for AVN [HIV infection, hyperlipidaemia, alcohol consumption (recorded as drinkers vs non-drinkers), tobacco use (recorded as active/former smoker vs never smoked), CS use (recorded as never/ever as well as highest dose prescribed in the 6 months prior to diagnosis of AVN)]. Subsequently, the highest prednisone dose prescribed

was grouped into intervals (i.e. 1–10, 11–20, 21–30 and >30 mg/day) to assess for dose-related effect. All patients in our cohort underwent auto-antibody profile phenotyping by Euroimmun EUROLINE (Lubeck, Germany). Positive values were based on manufacturer's guidelines of $\geq 15/+$. The diagnosis of AVN was based on imaging findings (MRI, CT or X-ray). MRI or radiograph reports with description and site of AVN were reviewed. The duration of IIM was calculated from the date of onset of first IIM symptom (i.e. weakness, myalgia, RP, dyspnoea, dysphagia or rash attributable to IIM) until the date of death, last follow-up or administrative censor date of 25 December 2020, whichever came first. All patients included in this study had a diagnosis of IIM and they were classified in one of five mutually exclusive clinical subgroups. Thus, patients were classified as having immune-mediated necrotizing myositis if they met the 2003 European Neuromuscular Centre criteria, IBM if they fulfilled European Neuromuscular Centre criteria or clinically amyopathic DM if they met Sontheimer's criteria [6–9]. If none of these three criteria was met, patients were evaluated for Bohan and Peter criteria and classified accordingly as possible, probable or definite DM or PM [10, 11]. Patients with IBM were then excluded from analysis.

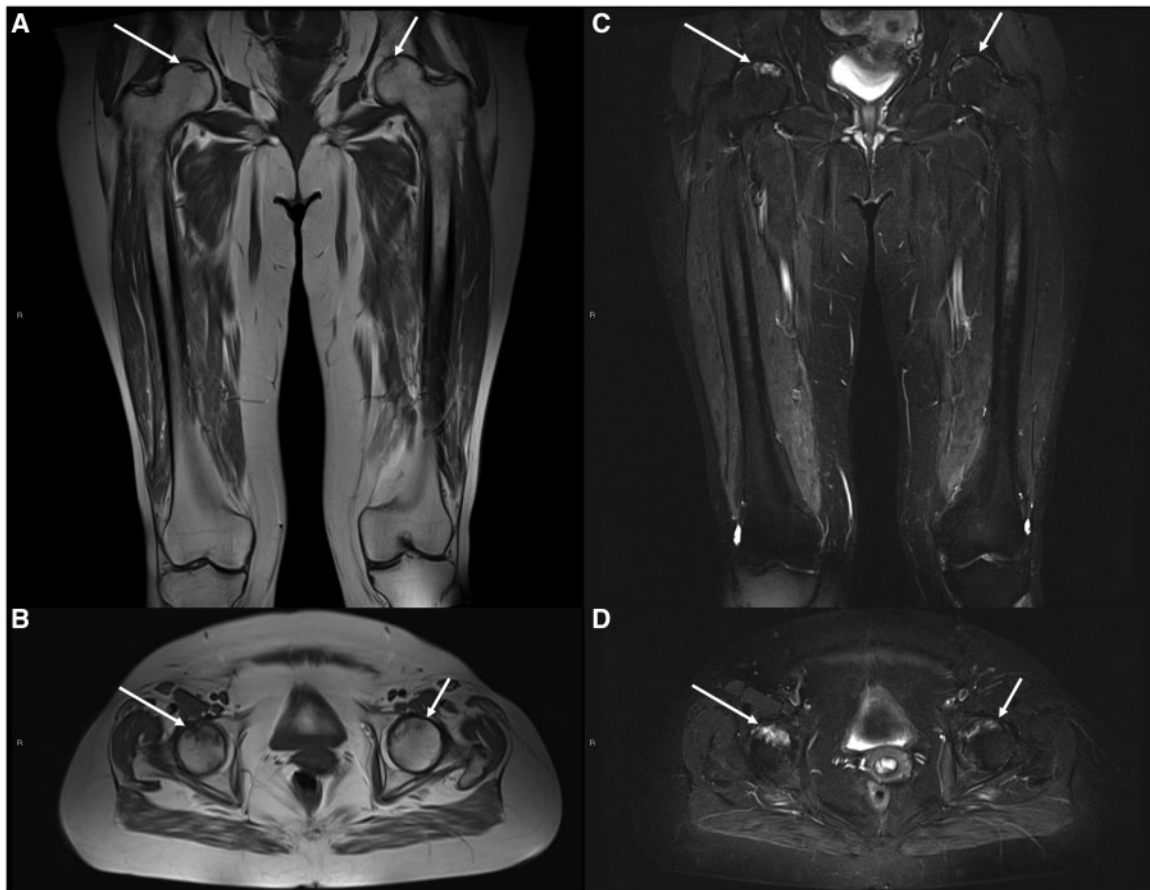Image acquisition

Imaging was comprised of radiography, CT and MRI. Radiography was comprised of anteroposterior and lateral projects of the hip. CT was performed according to institutional protocol (120 kV), 147 mAS, acquisition time 5–7 s, collimation 128×0.6 mm, pitch 0.6 and cranio-caudal scan direction. CT studies were prompted by symptoms and the body regions scanned included the shoulders and abdomen/pelvis. MRI of bilateral thighs was performed using institutional myositis protocol

Fig. 1 Selection flowchart



IIM: idiopathic inflammatory myopathies; EMR: electronic medical records; AVN: avascular necrosis.

Fig. 2 Example image of AVN on MRI

A 41-year-old woman with history of DM and AVN detected on thigh MRI. Coronal and axial T1-weighted (**A** and **B**) and STIR (**C** and **D**) sequences performed through bilateral thighs as per myositis protocol show bilateral right (long arrow) greater than left (short arrow) femoral head AVN characterized by serpentine elevated STIR and dark T1 signal abnormality in the bilateral femoral heads with preservation of fat signal in the subarticular bone. AVN: avascular necrosis; STIR: short tau inversion recovery.

comprised of fluid sensitive short tau inversion recovery, or STIR [repetition time (TR), 3500–6800 ms, echo time (TE), 42–58 ms, slice thickness (ST) 6–7 mm, inter-slice gap 1 mm] and T1-weighted (TR 680–790 ms, TE 8–12 ms, slice ST 5–6 mm, inter-slice gap 1 mm) sequence in the axial and coronal plane with field of view spanning from iliac crests to knees. (Fig. 2) While the majority of MRI studies were performed to assess for myositis of the proximal lower extremities, in three instances symptoms prompted MRI of the shoulders.

Image interpretation (diagnostic criteria for AVN/osteonecrosis)

Musculoskeletal fellowship-trained radiologists interpreted all imaging. On radiography and CT, presence of peripheral undulating or serpentine sclerosis with intermixed regions of central lucency with or without subarticular collapse (when involving the epiphysis), articular surface fragmentation or secondary OA was interpreted as AVN (when epiphyseal) or osteonecrosis (when

diaphyseal in location). Similarly, on MRI, presence of fatty marrow with peripheral undulating or serpentine sclerosis or hypointense signal on all sequences or a 'double-line' sign indicative of outer low-signal intensity rim of sclerosis and inner high-signal intensity rim of granulation tissue/reactive interface visible on fluid sensitive sequences was interpreted as AVN or osteonecrosis. When AVN or osteonecrosis was present, the anatomic location was documented in the radiology report. Due to the lack of available radiography in all patients and large field of view for MRIs optimized for the evaluation of skeletal thigh muscles rather than subarticular bone, staging of AVN was not performed [12, 13].

Statistical analysis

Data are reported as number of cases (percentage) and continuous variables are shown as mean \pm s.d. or median (range), as appropriate. A 3:1 matching group of patients without history/diagnosis of AVN was randomly

selected and matched on the following criteria: age at IIM diagnosis ± 5 years, duration of IIM ± 2 years. As in the AVN group, IBM patients were excluded from the matching pool. Group comparisons were made using Student's *t*-test for continuous variables and χ^2 statistics for categorical variables. A *P*-value < 0.05 was considered significant. To examine the relationship between multiple major known risk factors for AVN and the development of AVN in a large myositis cohort, univariable logistic regression was performed. Statistical analyses were performed using SPSS Statistics 27.0.1.0 (IBM Corp., Armonk, NY, USA).

Results

Prevalence of AVN

Among 1680 patients who were evaluated and diagnosed with IIM between 2003 and 2020, 51 had developed AVN on documented imaging with a median (min, max) time from IIM diagnosis of 46 months (–338, 384). The overall prevalence of AVN was 3% (51/1680). Musculoskeletal MRI (MSK MRI) was available for 1085 patients, and 46 of 51 patients with AVN were diagnosed with MSK MRI, therefore the relative prevalence (on MRI) was calculated to be 4.2% (46/1085).

Patients with IIM and AVN

The demographic and clinical characteristics of these patients are reported in Table 1. In the AVN group, the majority of patients were White, middle-aged women [71% women, 57% White, and mean age at myositis diagnosis 44.5 (12.4) years]. Sixty-one percent of these patients were diagnosed with DM, and 29% with PM. Nine of 51 patients (17%) were diagnosed with AVN before being diagnosed with IIM, and 6 of them were exposed to CS (prednisone equivalent dose in mg: 40, 100, 80, 10, 10, 10). Only 10 patients (19%) had symptoms upon their AVN diagnosis (reported symptoms included joint pain and ambulation difficulty). The hip joint was most frequently involved, in 76% of cases (femoral head/neck 60%, acetabula 16%), followed by the knee joint in 15% and shoulder joint in 9%. AVN diagnosis was confirmed by MRI in 46 patients (90%). Of the 46 cases of AVN on MRI, 43 cases were diagnosed by lower extremities MRI studies that anatomically include the hip through the distal femur and 3 cases by upper extremities MRI that included mainly the shoulders. AVN was diagnosed by CT scan in three patients (6%), CT scan of the shoulders in two patients and abdomen/pelvis in one patient. Two patients (4%) had their AVN diagnosed by hip X-ray. Ten patients required surgical repair for their AVN (seven patients had core decompression and three patients had total replacement of the joint), and only three (30%) were symptomatic.

TABLE 1 Demographic and clinical characteristics of patients with AVN and myositis

	Myositis with AVN, n (%)
Number of patients	51
Gender	
Men	15 (29)
Women	36 (71)
Race	
White	29 (57)
Black	15 (29)
Asian	1 (2)
Hispanic	2 (4)
Other	4 (8)
Age at myositis onset, years	43.9 (12.1)
Duration of IIM, years	10.2 (4.5)
Diagnosis	31 (61)
DM	15 (29)
PM	2 (4)
AD	3 (6)
IMNM	
Site of AVN	42 (76)
Hip joint	8 (15)
Knee joint	5 (9)
Shoulder joint	
Symptomatic AVN	10 (19)
Recurrent AVN	5 (10)
Surgical correction	10 (19)
Age at AVN diagnosis, years	44.5 (12.4)
Time from myositis to AVN, months (range)	46 (–338, 384)

Data are expressed in number of cases (%), mean (s.d.) or median (min, max). AD: amyopathic dermatomyositis; AVN: avascular necrosis; IIM: idiopathic inflammatory myopathies; IMNM: immune-mediated necrotizing myositis.

IIM with AVN vs IIM without AVN

One hundred and fifty-three patients were selected as matches for the in-study group of IIM-AVN. Baseline demographics were similar between the two groups including sex, race and age at myositis onset. In the IIM AVN group, there were fewer patients with DM (61 vs 72%, $P < 0.01$) as compared with the matched group. None of the major recognized risk factors for AVN (history of cancer, tobacco use, alcohol use or CS use) was found to be significantly associated with AVN. Similarly, no myositis-specific or myositis-associated autoantibodies were significantly associated with AVN (Table 2).

Predictors of AVN development

Univariable regression analyses were performed for all the major risk factors for AVN previously described. None of the examined factors was shown to have significant associations (Table 3). Of note, neither prednisone use as single variable (ever/never) nor any of the dose interval categories assessed separately were found to be associated with AVN development.

TABLE 2 Risk factors and serology in myositis with AVN vs myositis without AVN

	Myositis with AVN	Myositis without AVN	P-value
IIM type			0.001
DM	31 (61)	110 (72)	
PM	15 (29)	43 (28)	
AD	2 (4)	0	
IMNM	3 (6)	0	
AVN risk factors			
History of cancer, yes	4 (8)	15 (10)	NS
History of tobacco use, yes	13 (24)	48 (31)	NS
History of hyperlipidemia, yes	10 (20)	–	
History of HIV, yes	2 (4)	–	
History of alcohol use, yes	18 (35)	41 (27)	NS
History of steroid use, yes	45 (89)	138 (90)	NS
Prednisone equivalent dose used, mg/day	20 (5, 100)	10 (2, 40)	NS
Serology			NS
Anti-PL12, positive	5 (10)	10 (7)	NS
Anti-Jo1, positive	5 (10)	25 (16)	NS
Anti-PL7, positive	5 (10)	6 (4)	NS
Anti-EJ, positive	0 (0)	2 (1)	NS
Anti-OJ, positive	1 (2)	0 (0)	NS
Anti-T1F1g, positive	10 (20)	20 (13)	NS
Anti-MDA5, positive	5 (10)	15 (10)	NS
Anti-NXP2, positive	4 (8)	10 (7)	NS
Anti-Ku, positive	2 (4)	5 (3)	NS
Anti-SRP, positive	4 (8)	13 (9)	NS
Anti-PM75, positive	5 (10)	17 (11)	NS
Anti-PM100, positive	2 (4)	9 (6)	NS
Anti-Mi2b, positive	6 (12)	8 (5)	NS
Anti-Mi2a, positive	3 (6)	9 (6)	NS
Anti-SAE1, positive	0 0	2 (1)	NS

Data are expressed in number of cases (%) or median (min, max). AD: amyopathic dermatomyositis; AVN: avascular necrosis; IIM: idiopathic inflammatory myopathies; IMNM: immune-mediated necrotizing myositis; NS: not significant.

TABLE 3 Univariate logistic regression analysis, predictors of developing AVN in myositis population

Variable	OR	95% CI (min, max)	P-value
Sex, female	0.90	0.45, 1.82	0.78
Race, white	0.69	0.36, 1.33	0.27
History of cancer, yes	0.78	0.24, 2.47	0.67
History of alcohol use, yes	1.49	0.75, 2.93	0.24
History of tobacco use, yes	0.67	0.32, 1.39	0.28
History of steroid use, yes	0.81	0.29, 2.22	0.69
Daily PED range, mg (1–10)	2.33	1.68, 4.28	0.92
11–20	1.55	1.81, 3.12	0.56
21–30	1.56	0.33, 7.31	0.71
>30 mg	1.11	0.08, 15.03	0.93

AVN: avascular necrosis; OR: odds ratio; PED: prednisone equivalent dose.

Discussion

Our study demonstrated an overall AVN prevalence of 3% and a relative prevalence of 4.7% considering only cases with available MRI among patients with diagnosis of IIM. The major recognized risk factors for atraumatic AVN were assessed in this population and none was found to be significantly associated.

Although AVN is known to be a disabling complication of multiple rheumatic/systemic diseases, it has been studied most in SLE. High AVN incidence and prevalence rates in SLE populations have been attributed to common risk factors in this population (e.g. CS use, inflammation and thrombophlebitis) [14–16]. The prevalence of AVN in SLE has ranged in different studies between 4 and 15% [17–19]. In a Canadian study of

1729 SLE patients followed prospectively since 1970, 13.5% developed symptomatic AVN, with strong association with steroid use [20]. Unlike in SLE, the literature on AVN in IIM has been limited to case series/reports [21]. Huang *et al.* reported an AVN incidence of 11.6% (15/129) in patients with PM/DM (PM 3/27, DM 12/87) who underwent whole-body MRI to diagnose muscular and extra-muscular lesions [22]. All patients were exposed to CS and most of them were asymptomatic (87%). In comparison, our study was similar in that the majority of patients were asymptomatic and the hip joint was most commonly affected. In contrast, we report a lower prevalence of AVN in IIM, perhaps due to only having MRI data on limited extremities rather than whole body. Although the routine use of MRI to assess potential IIM is more likely to reveal subclinical/asymptomatic AVN in our practice, the prevalence of AVN in SLE is substantially higher. This could be, in part, attributed to the higher doses of CS usually prescribed and possibly to the pro-coagulant state that exists in SLE. In SLE, CS use was associated with increased AVN at a maximum daily prednisone dose of at least twice the dose used in our patients [23].

While CS were not significantly associated with AVN in our study, those who developed AVN had twice the median dose of steroid (20 vs 10 mg/day) prior to AVN diagnosis. Despite the difference in median dose of steroid between AVN group and controls, the dose interval categories did not reveal a specific dose-dependent relationship with AVN. The pathogenesis of steroid-induced osteonecrosis is unclear; however, several theories have been proposed. Steroid use may lead to fat mobilization and increased blood lipid levels with higher risk of fat microvascular embolization, medullary fat accumulation and increased volume of adipocytes, which can cause insufficient blood supply. Additionally, steroids can possibly decrease osteogenesis of bone marrow mesenchymal stem cells, cause local bone inflammation and increase apoptosis [24].

Alcohol consumption was not associated with AVN development in our IIM patients. The pathogenesis of alcohol-induced AVN is not well known, but several mechanisms including increased adipogenesis and diminished haematopoiesis in the bone have been suggested [25]. In a meta-analysis, Yoon *et al.* analysed five studies that reported an association between alcohol intake (both current consumption and cumulative amount) and AVN development [26]. In our study, we assessed the history of alcohol consumption during or before AVN diagnosis in a dichotomous manner (regular drinkers vs non-drinkers), without being able to quantify the amount consumed given the nature of the study. None of the myositis-specific or myositis-associated autoantibodies was significantly associated with AVN. This observation might be due to small sample size and a very low frequency of certain antibodies (e.g. anti-OJ positivity in only one case of IIM with AVN).

To our knowledge, this is the largest study examining the prevalence of AVN in IIM. The standardized nature

of our MSK MRI protocol of the bilateral proximal lower extremities performed on all patients at the time of IIM evaluation allows for a comprehensive capture of both symptomatic and asymptomatic cases in that anatomic distribution. While many incidental and asymptomatic cases of AVN were discovered, the diagnosis of AVN at early stages is crucial to allow time for interventions to preserve the joint and prevent collapse. Such interventions include pharmacologic agents (e.g. lipid-lowering agents, anticoagulation and bisphosphonates), biophysical treatment and joint-preserving surgeries (e.g. core decompression) [27]. Of the 10 patients who had surgical repair in our study, 7 (70%) had only core decompression in the pre-collapse phase and did not require joint replacement.

While the size of our study and standardized MRI assessment are strengths of our study, we acknowledge several limitations exist. First, we might have missed patients who had AVN in our cohort of IIM, either if their clinical notes did not include the queried keywords (avascular necrosis, AVN and osteonecrosis), if the imaging study was done in an outside hospital or if they developed asymptomatic AVN after the initial MRI assessment. Of note, we attempted to contact the primary physician of all patients who had uncertain history of AVN in their records. Second, the majority of incidental AVN were revealed on lower-extremity MRI studies performed for IIM diagnosis, which can potentially underestimate asymptomatic upper-extremity AVN cases. Additionally, limited information was available regarding the quantity of alcohol and tobacco used in the study patients, prompting dichotomous reporting of users vs non-users, which might have affected the accuracy of the risk relationship between these two factors and AVN development. Finally, we only considered the highest dose of CS used in our patients, since we were unable to obtain an accurate measure of a cumulative dose. However, in the absence of a standardized method to assess the dose of CS used, we believe that considering the highest dose used in the last 6 months prior to AVN diagnoses is reasonable [28].

Conclusions

In this retrospective study, the prevalence of AVN in a large cohort of patient with IIM was found to be 3%, and slightly higher (4.2%) if we considered AVN diagnosed only on MRI. AVN was diagnosed by MSK MRI of the proximal lower extremities that was mainly part of the IIM diagnostic protocol in 90% of the cases, and the majority (81%) were asymptomatic. None of the major recognized risk factors for AVN was found to be significantly associated with AVN. Similarly, no myositis-specific or myositis-associated autoantibodies were significantly associated with AVN.

Acknowledgements

Conception/design of the study was carried out by K.I.B., C.A.M. and L.C.-S. Data collection was done by

K.I.B. and W.K. Data analysis and interpretation was performed by K.I.B., C.A.M. and L.C.-S. K.I.B. and C.A.M. drafted the article, and C.A.M., J.J.P., J.A., E.T., T.E.L., A.M., S.A. and L.C.-S. carried out critical revision of the article.

Funding: No specific funding was received from any bodies in the public, commercial or not-for-profit sectors to carry out the work described in this article.

Disclosure statement: The authors have declared no conflicts of interest.

Data availability statement

Data used in this study are available electronically in the Hopkins Myositis Registry, Johns Hopkins Myositis Center, Baltimore, MD, USA.

References

- Assouline-Dayana Y, Chang C, Greenspan A, Shoenfeld Y, Gershwin ME. Pathogenesis and natural history of osteonecrosis. *Semin Arthritis Rheum* 2002;32:94–124.
- Dima A, Pedersen AB, Pedersen L, Baicus C, Thomsen RW. Risk of osteonecrosis in patients with systemic lupus erythematosus: a nationwide population-based study. *Eur J Intern Med* 2016;35:e23–4.
- Petri M. Musculoskeletal complications of systemic lupus erythematosus in the Hopkins Lupus Cohort: an update. *Arthritis Rheum* 1995;8:137–45.
- Rolston VS, Patel AV, Leach TJ *et al.* Prevalence and associations of avascular necrosis of the hip in a large well-characterized cohort of patients with inflammatory bowel disease. *J Clin Rheumatol* 2019;25:45–9.
- Mont MA, Glueck CJ, Pacheco IH *et al.* Risk factors for osteonecrosis in systemic lupus erythematosus. *J Rheumatol* 1997;24:654–62.
- Griggs RC, Askanas V, DiMauro S *et al.* Inclusion body myositis and myopathies. *Ann Neurol* 1995;38:705–13.
- Hoogendijk JE, Amato AA, Lecky BR *et al.* 119th ENMC international workshop: trial design in adult idiopathic inflammatory myopathies, with the exception of inclusion body myositis, 10–12 October 2003, Naarden, The Netherlands. *Neuromuscular Disorders* 2004;14:337–45.
- Sontheimer RD. Would a new name hasten the acceptance of amyopathic dermatomyositis (dermatomyositis *siné* myositis) as a distinctive subset within the idiopathic inflammatory dermatomyopathies spectrum of clinical illness? *J Am Acad Dermatol* 2002;46:626–36.
- Rose MR. 188th ENMC International Workshop: inclusion body myositis, 2–4 December 2011, Naarden, The Netherlands. *Neuromuscul Disord* 2013;23:1044–55.
- Bohan A, Peter JB. Polymyositis and dermatomyositis (first of two parts). *N Engl J Med* 1975;292:344–7.
- Bohan A, Peter JB. Polymyositis and dermatomyositis (second of two parts). *N Engl J Med* 1975;292:403–7.
- Murphey MD, Foreman KL, Klassen-Fischer MK *et al.* From the radiologic pathology archives: imaging of osteonecrosis: radiologic-pathologic correlation. *Radiographics* 2014;34:1003–28.
- Mitchell DG, Kressel HY, Arger PH *et al.* Avascular necrosis of the femoral head: morphologic assessment by MR imaging with CT correlation. *Radiology* 1986;161:739–42.
- Chen HL, Shen LJ, Hsu PN *et al.* Cumulative burden of glucocorticoid-related adverse events in patients with systemic lupus erythematosus: findings from a 12-year longitudinal study. *J Rheumatol* 2018;45:83–9.
- Oinuma K, Harada Y, Nawata Y *et al.* Osteonecrosis in patients with systemic lupus erythematosus develops very early after starting high dose corticosteroid treatment. *Ann Rheum Dis* 2001;60:1145–8.
- Petri M, Bechtel B, Dennis G *et al.* Burden of corticosteroid use in patients with systemic lupus erythematosus: results from a Delphi panel. *Lupus* 2014;23:1006–13.
- Al Saleh J, El Sayed M, Salah N *et al.* Predictors of avascular necrosis of the hip in Emiratis patients with systemic lupus erythematosus. *Egypt J Immunol* 2010;17:29–40.
- Lee J, Kwok SK, Jung SM *et al.* Osteonecrosis of the hip in Korean patients with systemic lupus erythematosus: risk factors and clinical outcome. *Lupus* 2014;23:39–45.
- Sayarlioglu M, Yuzbasioglu N, Inanc M *et al.* Risk factors for avascular bone necrosis in patients with systemic lupus erythematosus. *Rheumatol Int* 2012;32:177–82.
- Gladman DD, Dhillon N, Su J, Urowitz MB. Osteonecrosis in SLE: prevalence, patterns, outcomes and predictors. *Lupus* 2018;27:76–81.
- Robinson AB, Rabinovich CE. Avascular necrosis of the metacarpals in juvenile dermatomyositis. *J Clin Rheumatol* 2010;16:233–6.
- Huang Z-G, Gao B-X, Chen H *et al.* An efficacy analysis of whole-body magnetic resonance imaging in the diagnosis and follow-up of polymyositis and dermatomyositis. *PLoS One* 2017;12:e0181069.
- Tse SM, Mok CC. Time trend and risk factors of avascular bone necrosis in patients with systemic lupus erythematosus. *Lupus* 2017;26:715–22.
- Wang A, Ren M, Wang J. The pathogenesis of steroid-induced osteonecrosis of the femoral head: a systematic review of the literature. *Gene* 2018;671:103–9.
- Wang Y, Li Y, Mao K *et al.* Alcohol-induced adipogenesis in bone and marrow: a possible mechanism for osteonecrosis. *Clin Orthop Relat Res* 2003;410:213–24.
- Yoon BH, Young KT, Shin IS *et al.* Alcohol intake and the risk of osteonecrosis of the femoral head in Japanese populations: a dose-response meta-analysis of case-control studies. *Clin Rheumatol* 2017;36:2517–24.
- Moya-Angeler J, Gianakos AL, Villa JC, Ni A, Lane JM. Current concepts on osteonecrosis of the femoral head. *World J Orthopaed* 2015;6:590–601.
- Powell C, Chang C, Naguwa SM, Cheema G, Gershwin ME. Steroid induced osteonecrosis: an analysis of steroid dosing risk. *Autoimmun Rev* 2010;9:721–43.