

Henry Ford Health

Henry Ford Health Scholarly Commons

Neurosurgery Articles

Neurosurgery

6-15-2021

Expandable Cage Technology-Transforaminal, Anterior, and Lateral Lumbar Interbody Fusion

Mohamed Macki

Henry Ford Health, mmacki2@hfhs.org

Travis Hamilton

Henry Ford Health, THAMILT8@hfhs.org

Yazeed W. Haddad

Henry Ford Health, yhaddad1@hfhs.org

Victor Chang

Henry Ford Health, vchang1@hfhs.org

Follow this and additional works at: https://scholarlycommons.henryford.com/neurosurgery_articles

Recommended Citation

Macki M, Hamilton T, Haddad YW, and Chang V. Expandable Cage Technology-Transforaminal, Anterior, and Lateral Lumbar Interbody Fusion. *Oper Neurosurg (Hagerstown)* 2021; 21(Supplement_1):S69-s80.

This Article is brought to you for free and open access by the Neurosurgery at Henry Ford Health Scholarly Commons. It has been accepted for inclusion in Neurosurgery Articles by an authorized administrator of Henry Ford Health Scholarly Commons.

Expandable Cage Technology—Transforaminal, Anterior, and Lateral Lumbar Interbody Fusion

Mohamed Macki, MD, MPH*

Travis Hamilton, MD*

Yazeed W. Haddad, BS

Victor Chang, MD 

Department of Neurosurgery, Henry Ford Hospital, Detroit, Michigan, USA

*Mohamed Macki and Travis Hamilton contributed equally to this work.

Correspondence:

Victor Chang, MD,
Department of Neurosurgery,
Henry Ford Hospital,
2799 West Grand Boulevard,
Detroit, MI 48202, USA.
Email: VCHANG1@hfhs.org

Received, May 1, 2020.

Accepted, August 19, 2020.

Published Online, June 15, 2021.

© Congress of Neurological Surgeons
2021. All rights reserved.
For permissions, please e-mail:
journals.permissions@oup.com

This review of the literature will focus on the indications, surgical techniques, and outcomes for expandable transforaminal lumbar interbody fusion (TLIF), anterior lumbar interbody fusion (ALIF), and lateral lumbar interbody fusion (LLIF) operations. The expandable TLIF cage has become a workhorse for common degenerative pathology, whereas expandable ALIF cages carry the promise of greater lordotic correction while evading the diseased posterior elements. Expandable LLIF cages call upon minimally invasive techniques for a retroperitoneal, transpoas approach to the disc space, obviating the need for an access surgeon and decreasing risk of injury to the critical neurovascular structures. Nuances between expandable and static cages for all 3 TLIF, ALIF, and LLIF operations are discussed in this review.

KEY WORDS: Anterior lumbar interbody fusion (ALIF), Expandable cage, Lateral lumbar interbody fusion (LLIF), Spine, Transforaminal lumbar interbody fusion (TLIF)

Operative Neurosurgery 21:S69–S80, 2021

DOI: 10.1093/ons/opaa342

As spinal techniques advance, much of degenerative thoracolumbar surgery has evolved into surgery of the intervertebral disc space. Expandable cages, in particular, have offered a favorable alternative to traditional ostomies because of the greater disc height expansion and lordotic restoration as compared to static cages. Expandable cages allow surgeons to reach the desired interbody height without the need for trialing or other maneuvers to expand the disc space. Expandable cages also partially eliminate the need to trial prior to implant placement. Theoretically, this minimizes the trauma to the endplate, which could potentially decrease implant subsidence. This review will discuss 3 expandable cage options: transforaminal lumbar interbody fusion (TLIF), anterior lumbar interbody fusion (ALIF), and lateral lumbar interbody fusion (LLIF).

ABBREVIATIONS: **ALIF**, anterior lumbar interbody fusion; **EMG**, electromyography; **LLIF**, lateral lumbar interbody fusion; **MCID**, minimally clinically important difference; **MIS-TLIF**, minimally invasive TLIF; **ODI**, Oswestry Disability Index; **PRO**, patient-reported outcome; **TLIF**, transforaminal lumbar interbody fusion; **VAS**, visual analog score

METHODS

PubMed and Embase identified peer-reviewed articles in English. Keywords included “expandable” PLUS “transforaminal” or “TLIF” for TLIFs, “anterior” or “ALIF” for ALIFs, and “lateral” or “transpoas” or “LLIF” for LLIFs. Corpectomy operations were removed. All relevant papers were included in this review. Neither Institutional Review Board nor patient consent is required for literature reviews.

TRANSFORAMINAL LUMBAR INTERBODY FUSION

The TLIF has become one of the original workhorses in disc height restoration during lumbar fusion surgeries (Table 1).^{1–13} Refined techniques include minimally invasive TLIF (MIS-TLIF)⁵ as well as expandable cages.^{14–26}

Indications

The TLIF approach is indicated for mechanical/low back pain with radiculopathy secondary to spondylolisthesis. This encompasses a range of degenerative lumbar spine pathologies such as degenerative disc disease, disc prolapses or herniations, pseudarthrosis, and symptomatic spondylosis.²⁷ Other possible surgical indications include postlaminectomy instability without significant scarring that would, otherwise, hinder the transforaminal

TABLE 1. Literature Review of Expandable Cages for TLIF

Author	N	Surgical indication	Clinical outcome	Radiographic outcome	Follow-up
Hawasli et al ¹	44 (28 expandable)	Degenerative disc disease and lumbar spondylosis with radiculopathy with or without grade I to II spondylolisthesis with absence of previous surgical instrumentation	The mean postoperative minimally invasive TLIF ODI scores were lower compared to static device ($P < .001$)	Patients with an expandable cage had a greater increase in disc height compared to static interbody device both at postoperation and upon follow-up ($P < .01$) MIS-TLIF with an expandable interbody device increases index-level segmental lordosis but has no effect on overall lumbar lordosis ($P < .01$) The use of minimally invasive TLIF did not change pelvic parameters or pelvic incidence-lumbar lordosis mismatch Both expandable and static devices in MIS-TLIF have similar pseudarthrosis rates of 6.90% and 5.30%, respectively	14.6 ± 7.1 mo (range 3.0–26.0 mo) postoperatively, and the last follow-up for expandable interbody device patients occurred 7.1 ± 4.2 mo (range 0.9–19.8 mo)
Kim et al ²	50	Degenerative disc disease with up to grade 1 spondylolisthesis at 1 or 2 contiguous levels at L2-S1, in the absence of previous surgical intervention at the index level(s)	Mean VAS and ODI scores decreased significantly from preoperative to all postoperative assessment times (6, 12, and 24 mo) ($P < .05$) No significant intraoperative or perioperative complications were reported for the 50 patients in this study	Intervertebral disc height was increased significantly at 24 mo and maintained after operation ($P < .05$) No significant change in neural foraminal height and operative level Cobb angle ($P > .05$) No evidence of cage migration, subsidence or collapse at 12 and 24 mo	6, 12, 24 mo
Stein et al ³	1	Single patient with many lumbar operations with continuing radicular pain and weakness	Patient reported improved radicular pain yet reported right perineal numbness and bladder and bowel dysfunction that later improved Upon follow-up pain persisted yet patient did report improvement overall compared to preoperation	Postoperative MRI did not show residual stenosis	9 mo
Massie et al ⁴	39	Spondylolisthesis	Back pain, leg pain, and ODI were significantly improved at the 1-yr mark ($P < .001$)	On average spondylolisthesis was corrected by 4.3 mm ($P < .001$), segmental angle 4.94° ($P < .001$), segmental height increased by 3.1 mm ($P < .001$)	3, 12, 24 mo
Yee et al ⁵	89 patients (42 expandable)	Degenerative disc disease with both recurrent herniation of nucleus pulposus and stenosis Degenerative scoliosis Spondylolisthesis	Not reported	There was no significant change in lumbar lordosis and segmental lordosis between expandable and nonexpandable groups	Follow-up at 1 and 12 mo
Boktor et al ⁶	54	Stenotic leg pain ≥ 6 mo with failed conservative treatment Radiological evidence of foraminal stenosis and/or spondylolisthesis with presence of spinal canal stenosis	Mean ODI, VAS for back and leg pain improved significantly ($P < .001$)	Disc height, foraminal height, focal Cobb angle, and global Cobb angle were significantly increased and maintained at all time points for 24 mo ($P < .001$)	6 wk, 6 mo, 1 and 2 yr

TABLE 1. Continued

Author	N	Surgical indication	Clinical outcome	Radiographic outcome	Follow-up
Morrison et al ⁷	10	N/A	VAS and Oswestry scores improved significantly ($P < .05$)	Frontal and sagittal plane correction obtained on all 10 patients	Immediately postoperative and at 12-mo mark
Vaishnav et al ⁸	171 patients (60 expandable)	Patients were stratified based on preoperative segmental lordosis into 3 groups: low lordosis ($<15^\circ$), moderate lordosis (15° - 25°), and high lordosis ($>25^\circ$)	Not reported	Patients with low lordosis preoperatively ($>15^\circ$) have the highest likelihood of achieving statistically significant improvement in segmental lordosis Patients with moderate (15° - 25°) or high ($>25^\circ$) lordosis preoperatively may experience no change or even a loss of lordosis postoperatively	Immediately postoperative only
Khechen et al ⁹	60 patients (30 expandable)	Patients with degenerative lumbar pathology	Both expandable and nonexpandable cage cohorts demonstrated a significant improvement in ODI, VAS back and leg pain at 6 mo postoperatively ($P < .001$)	Both static and expandable device cohorts had a significant improvement in disc and foraminal height The same trend was evident for lumbar lordosis and not segmental lordosis at the 6-mo mark ($P < .001$ for all), with segmental lordosis improvement in the static cohort ($P = .054$)	6 and 12 wk 6 mo
Tassemeier et al ¹⁰	61	Patients with degenerative lumbar pathology	Not reported	Sixty-one patients were studied (33 banana-shaped and 28 straight cages). Disc height changed in the banana group from 4.8 mm (standard deviation [SD] 2.5) to 10.4 (SD 2.4) and in the straight cage group from 6.2 mm (SD 2.5) to 9.6 mm (SD 1.7). The difference was statistically significant ($P = .03$)	Postoperative only
Kremer et al ¹¹	99 patients (51 expandable)	Not mentioned	At 3-mo and final follow-up, expandable implant patients had significantly lower ODI scores than static implant patients ($P < .05$)	Disc/neuroforaminal height increased significantly ($P < .05$) from baseline at 3-mo follow-up for both interbody spacers, although the expandable group had significantly greater neuroforaminal static height (22.3 vs 20.1 mm)	3, 24 mo
Wang et al ¹²	10	All patients had severe disc height collapse, and 60% had a grade I spondylolisthesis	ODI improves significantly ($P < .0001$), improved short-form 36 scores and EQ-5D score improved from 10.7 ± 9.5 to 14.2 ± 1.6 ($P < .0001$)	All patients had successful fusion	3, 6, and 12 mo
Alimi et al ¹³	49	Patients with degenerative disc disease	Statistically significant improvement in VAS for back ($P < .001$), VAS for buttock ($P = .002$), VAS for leg ($P < .001$), and ODI ($P < .001$)	Statistically significant increase in the average disk height ($P = .037$) and foraminal height ($P = .0001$), and a significant reduction in the listhesis ($P = .005$)	19.3 ± 6.37 mo

corridor.²⁸ TLIF may also be indicated in spinal trauma with significant kyphosis and/or injury limited to the endplate (eg, A1 compression fracture or an A3 burst fracture in the AO classification).²⁹ Contraindications to TLIF surgery include extensive epidural scarring, arachnoiditis, active infection and osteoporotic patients, and conjoined nerve roots.²⁷ Patients with high-grade spondylolisthesis and high pelvic incidence may not be amenable to MIS-TLIF surgery.³⁰

Technique

A variety of approaches have been used to describe the MIS-TLIF. Our preference is to utilize an operative microscope using a bladed retractor (Mars 3VL, Globus Medical, Audubon, Pennsylvania) through a 25-mm incision 4.0-4.5 cm off midline. Facetectomy and laminectomy are performed using a combination of a high-speed burr and rongeurs. Access to the disc space is through Kambin's triangle where in the majority of cases retraction of the traversing or exiting nerve roots is unnecessary. Annulotomy is performed sharply, followed by disc shavers and rongeurs to prepare the endplate. Extreme care is taken to preserve the bony endplate. Grafting materials and biologics are at the discretion of the surgeon and are all equally adaptable to expandable cages. Trialing is generally unnecessary, and our preference is to use the nearest minimally degenerated disc space to gauge the correct implant height. Prior to cage insertion, our preference is to preload the interbody space with graft, followed by the implant. In cases where an articulating, expandable cage is used, the cage is first turned into a horizontal orientation prior to expansion. In addition, these interbody designs allow for additional graft to be placed posterior to the cage. Once the cage is fully expanded, backfilling with the cage is recommended and most manufacturers will have some tools to facilitate this step. Pedicle screws can be placed either before or after cage insertion, and our preference is to do so after the cage is implanted.

Outcomes

Kim et al² were the first to report the outcomes of 50 consecutive patients undergoing 1- and 2-level MIS-TLIFs using straight expandable cages, which improved disc height and increased segmental Cobb angle. Tassemeier et al¹⁰ also reported an improvement in disc height and segmental lordosis with a similar patient cohort using straight expandable cages. However, in their comparative study, Yee et al⁵ failed to demonstrate any significant differences in segmental or overall lumbar lordosis, presumably because of the limitations in performing a unilateral facetectomy. In contrast, Jagannathan et al³¹ achieved an increased disc height and ultimately lumbar lordosis when an expandable cage is placed anteriorly in combination with bilateral facetectomies.⁵ Because of the larger footprint, straight expandable cages achieve an immediate long-standing increase in disc height relative to straight static cages, while also immediately increasing the neuroforaminal height and preserving segmental lordosis.^{2,5,32-34}

In a retrospective comparison of expandable curved versus straight cages, Tassemeier et al¹⁰ reported improved disc height in the curved cohort. Curved expandable cages, like straight cages, improve disc height and neuroforaminal height but provide the additional benefit of improving segmental lordosis, which correlated with improved clinical outcomes (Figures 1 and 2).^{1,4} As straight cages are typically placed in an oblique direction based on the angle of approach, curved cages are able to be positioned more anteriorly, which translates into greater lordosis.¹⁰ Kwon et al³⁵ demonstrated that the improvement of sagittal alignment, disc height, and lumbar lordosis is proportional to the anterior placement of static interbody grafts. McMordie et al³⁶ found anteriorly placed straight expandable cages showed similar improvements in segmental lordosis, disc height, and foraminal height, further demonstrating that preoperative lordosis is inversely correlated with postoperative lordosis in patients with pelvic mismatch.

The use of expandable cages in TLIF surgery demonstrates significant improvement in patient outcomes measured by the Oswestry Disability Index (ODI) and visual analog scores (VAS) for back pain up to 1 yr postoperatively.^{2,4,6,36-42} However, when comparing postoperative patient-reported outcomes (PROs) between the static and expandable cage cohorts after MIS-TLIF, Khechen et al⁹ found no significant difference in ODI, VAS back pain, VAS leg pain, and minimally clinically important differences (MCIDs) at all time points. These authors presume that both cage types provide sufficient nerve root decompression and preservation of segmental lordosis.

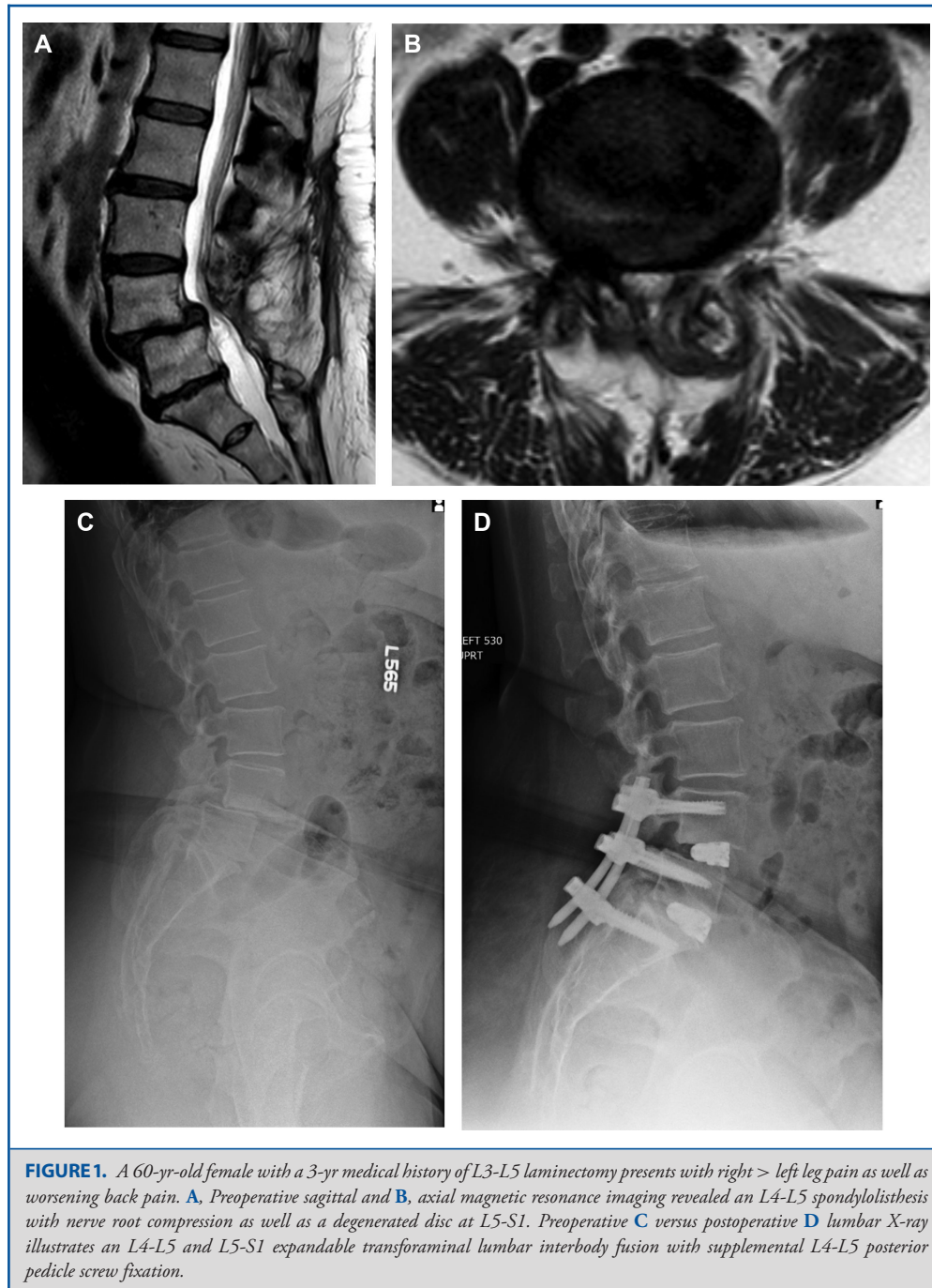
Alvi et al³³ published a similar rate of fusion in expandable versus nonexpandable cages in a meta-analysis on patients undergoing MIS-TLIF, and the former group did not exhibit a statistically significant difference in the reoperations or subsidence. A number of factors contribute to the development of subsidence. Expandable cages have a larger anatomic footprint relative to static cages, which improves the contact area and reduces posterior displacement of the inferior endplate of the superior vertebral body during pedicle compression.³² Other related patient variables affecting subsidence and bony fusion include bone mineral density, segmental spinal level, and the underlying diagnosis.^{13,43-45}

ANTERIOR LUMBAR INTERBODY FUSION

ALIF represents a retroperitoneal approach to the anterior face of the lumbar intervertebral disc space.⁴⁶⁻⁴⁸ Of all static cages, ALIF is touted as the greatest success in lordotic correction, owing to the anterior cage position.^{49,50} However, the advent of expandable ALIF cages promises even more dramatic lordotic correction.^{51,52}

Indications

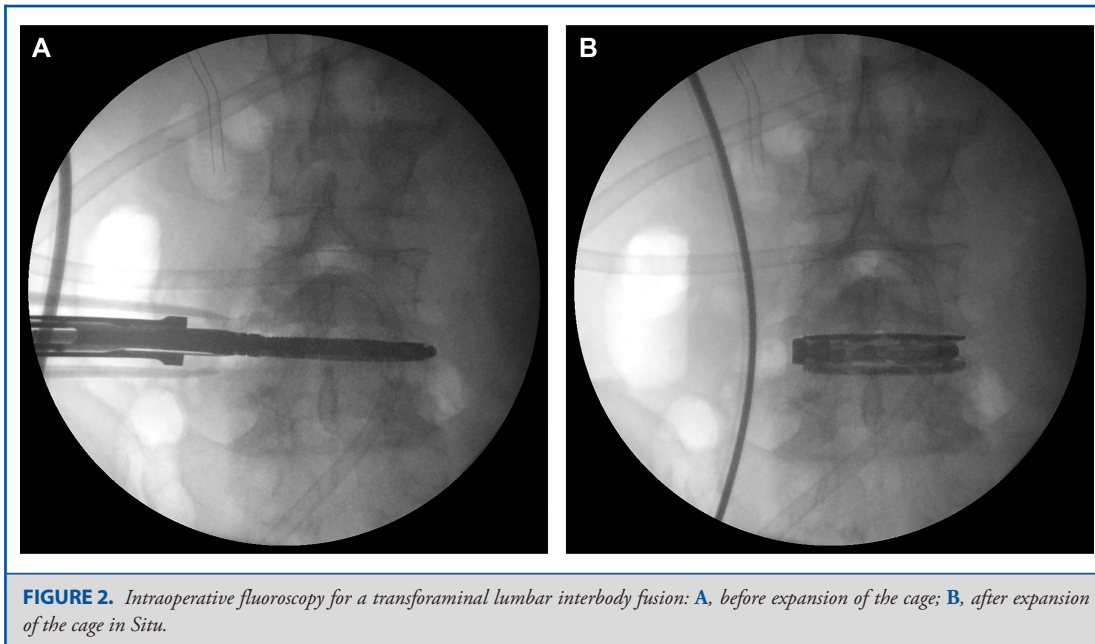
With the assistance of an access surgeon, this approach allows for correction in up to 3 levels of the lumbar spine (from L3 to S1). Indications include patients with spondylolisthesis



(isthmic, degenerative, dysplastic, or traumatic), degenerative disc disease, degenerative lumbar scoliosis, pseudarthrosis, and adjacent segment disease.⁵³ This surgery is considered after failed medical management of mechanical back pain and radicular leg pain. ALIF can also be considered for revision surgery to provide a more robust correction to reestablish adequate sagittal or coronal alignment.⁵⁴

Technique

The ALIF approach is done with a general/vascular surgeon to allow for a retroperitoneal approach to the anterior lumbar spine, albeit some experienced spine surgeons may independently obtain access to the lumbar region with general/vascular surgery on back-up availability. Once the significant vasculature in the working area has been protected with retractors, the anterior



disc space is opened sharply. A Cobb elevator incises the intervertebral disc from the superior and inferior endplates. The remaining disc material is then removed using a combination of curettes and rongeurs. Trialing for implant height is generally unnecessary although in cases where the disc space is collapsed it can be helpful to use a trial to distract the segment up the minimum implant height prior to placing the cage. As with other expandable cage designs, a wide range of grafting and biologics options can be used. Once the cage is expanded to the desired height, it is recommended to postfill the cage as in most ALIF cages there can be additional space within the graft chamber after expansion. Depending on design, the cage can be either fixated with an anterior plate or integrated screws through the anterior surface of the cage. Supplemental posterior fixation with pedicle screws may be necessary depending on the pathology being treated.

Outcomes

An anterior approach to the spine offers several advantages including direct and efficient access for spinal reconstruction. Compared to open posterior approaches, the ALIF avoids paraspinal muscle trauma with minimal blood loss and shorter operative times.^{49,50} Unfortunately, the literature on expandable cages for ALIF procedures is sparse, and comparative statistics on expandable versus static ALIF cages are almost nonexistent. In one of the largest published experiences, Jackson et al⁵¹ reported a study of 43 patients who underwent placement of modular ALIF cages. Bony fusion reached 95%.⁵² One case revealed progressive subsidence and nonunion on plain films, and the other case experienced arthrodesis at 1 of the 3 ALIF levels fused. According

to a series of 17 patients with expandable ALIF cages by Lee,⁵² all 7 patients in whom postoperative computed tomography scan was obtained showed evidence of fusion. In a cohort of 142 patients receiving ALIF for L4-L5 degenerative spinal disease, Hironaka et al⁵⁵ cited a solid fusion rate of 90.1%, although only 112 out of 142 patients had expandable cages placed. Subsidence >2 mm was observed in 4.9% of patients. Fusion and subsidence rates were initially thought to be affected by posterior transpedicular supplementation in selected cases. Biomechanical studies suggest that stand-alone cages tolerate flexion and lateral bending, but rotation and extension has suboptimal stability, and cage type did not affect stability.⁵⁶ However, this has not materialized in clinical studies, which have failed to demonstrate a statistically significant difference in radiographic or PROs between stand-alone ALIF and ALIF + posterior augmentation.⁵⁷ In a direct comparative study, Strube et al⁵⁸ argued that the addition of pedicle screws should be reserved for decompression of posterior neural structures, anteroposterior repositioning, bilateral spondylolysis, or other high-grade posterior instability. The configuration of static ALIF cages, in particular, allows for maximum endplate coverage that provides enhanced resistance to subsidence.⁵¹

Favorable PROs have also been reported for expandable ALIF. Postoperative compared to preoperative back pain and leg pain scores as well as quality-of-life measures reached statistically significant differences.^{51,52} These clinical results may be attributable to the significant increase in neuroforamen height, disc height, and intervertebral lordotic angle after in Situ expansion of the ALIF implant. In addition, the wide exposure to the disc space also allows for a more accurate discectomy, widening of the disc space,

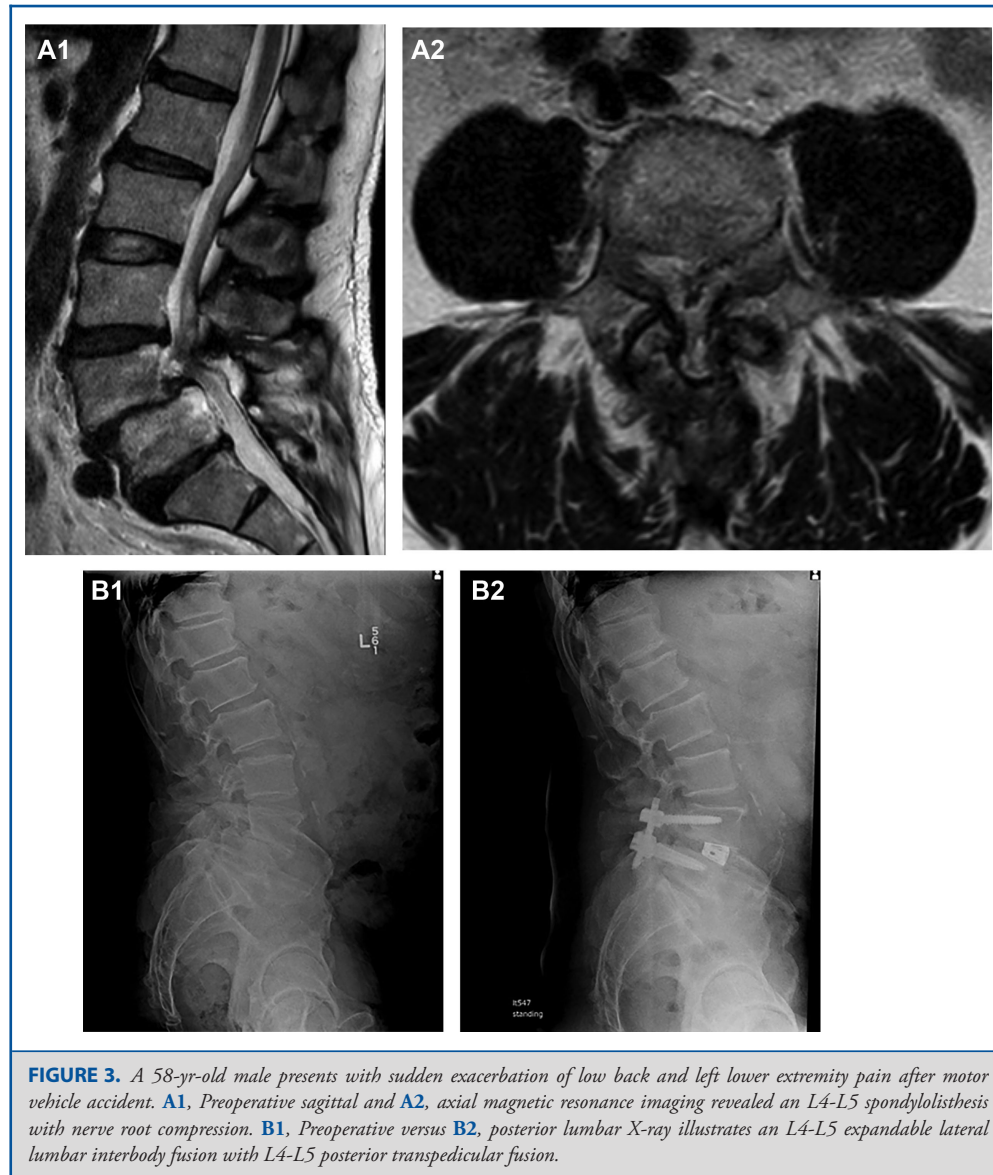


FIGURE 3. A 58-yr-old male presents with sudden exacerbation of low back and left lower extremity pain after motor vehicle accident. **A1**, Preoperative sagittal and **A2**, axial magnetic resonance imaging revealed an L4-L5 spondylolisthesis with nerve root compression. **B1**, Preoperative versus **B2**, posterior lumbar X-ray illustrates an L4-L5 expandable lateral lumbar interbody fusion with L4-L5 posterior transpedicular fusion.

and indirect neural decompression.^{59,60} Optimal outcomes in patients with failed back syndrome, particularly, are attributable to an anterior approach through virgin tissue, thereby circumventing dissection of perineural scar tissue and retraction of scarred nerve roots.⁶¹

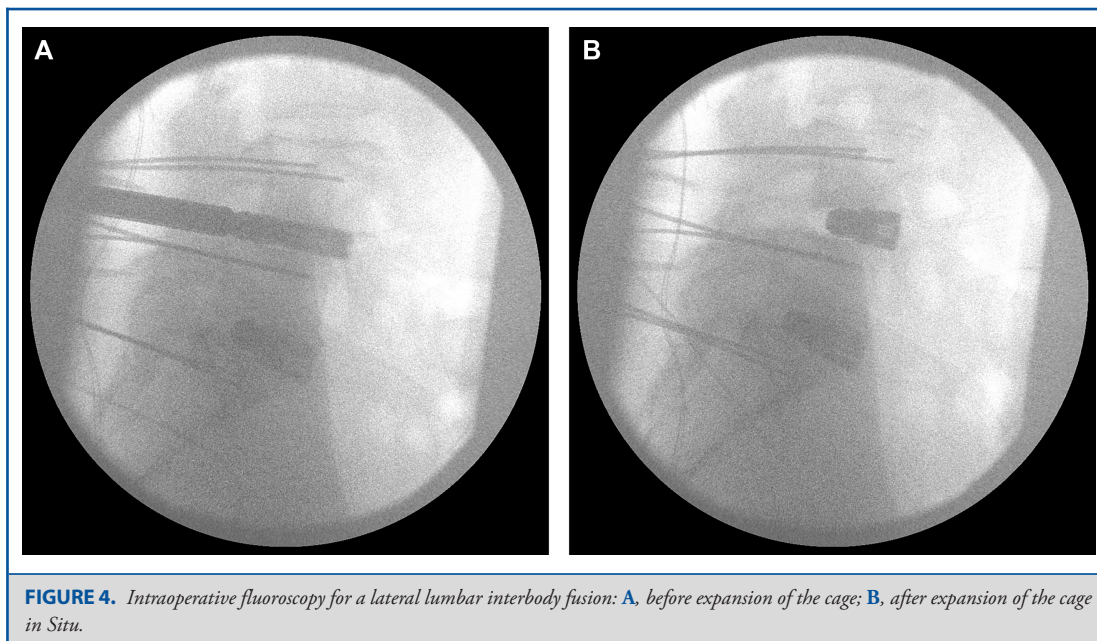
ALIFs do confer several disadvantages, not unique to expandable versus static cages. The approach does require an access surgeon who must be comfortable with mobilization of the great vessels and avoidance of bowel perforation. Iatrogenic injury to the superior hypogastric sympathetic plexus/sacral splanchnic nerves leads to retrograde ejaculation and sterility in male patients.⁶² More common complications include warm-leg sensation, thrombophlebitis, and urinary retention.⁶³

LATERAL LUMBAR INTERBODY FUSION

The LLIF represents a minimally invasive operation that utilizes a flank incision for direct access to the lateral intervertebral disk via the retroperitoneal space (Figures 3 and 4).⁶⁴

Indications

LLIF is indicated for degenerative disc disease with up to grade I spondylolisthesis or retrolisthesis at the involved levels. The interbody(ies) may be placed at 1 or 2 continuous levels from L2 to L5. Expandable cages, in particular, offer the advantage of continuous in Situ height expansion for up to 17 mm, depending on the manufacturer. In addition to fixed lordotic angles, some



cage designs allow for adjustable lordosis up to 30 degrees of segmental correction.

The lumbar spine must be skeletally mature. All patients must have failed several months of conservative management (Table 2).⁶⁵⁻⁷³

Technique

Expandable lateral cages can be applied in any lateral technique (ie, transpoas, ante-psoas) and the exact approach can be tailored according to surgeon preference. Image guidance can also be used. Our typical practice is with a transpoas approach, utilizing intraoperative electromyography (EMG) with stimulation probes as well as soft tissue dilators with the capacity for directional stimulation. The docking area for the retractor is dorsally located within the disc space with safe thresholds in EMG stimulation. This allows for maximizing the anterior-posterior footprint of the LLIF cage. Disc prep is done with a combination of Cobb elevators, curettes, and rongeurs with special care to not violate the bony endplate. Trialing with a sizer can be used primarily for the antero-posterior and coronal planes, as with the expandable technology there is flexibility with intervertebral height. It is our practice to use the nearest adjacent intervertebral levels with minimal degeneration to estimate the anticipated final height. At the surgeons' discretion, biologics are loaded into the graft chamber, and the cage is inserted followed by expansion to the desired height, and in the application of an adjustable lordotic cage the desired degree of segmental lordosis. Due to the extra space created from cage expansion, further backfilling of the graft window is recommended to maximize the surface area of graft contact to the bone as well as loading to promote arthrodesis. Most expandable cage designs incorporate a device to allow for backfilling postcage

expansion. Regarding supplemental fixation posteriorly, it is our practice to place percutaneous pedicle screws with posterior arthrodesis to add additional rigidity to the construct.

Outcomes

Because the TLIF and PLIF approaches are limited by manipulation of the nerve roots, thecal sac, and spinal canal, the size of the interbody is restricted by the operative corridor. The LLIF, on the other hand, obviates these narrow passages and allows for placement of wide, yet slender, interbodies. According to Wolff's law, the cage's larger surface area in contact with the bony endplate will not only decrease subsidence into the vertebral body but also provide a greater footprint for fusion.⁷⁴ This was best demonstrated in a study by Smith et al,⁷⁰ who found that all cases of subsidence occurred in the earlier-designed expandable cylindrical cages versus the more current expandable wide footprint cage among 52 patients undergoing lateral interbody fusion. Moreover, studies comparing static and expandable LLIF reported higher subsidence rates in the former group.^{69,75} The impaction force necessary when placing a static spacer may have contributed to the higher rates of subsidence.

The expandable cages combine the advantage of the wide endplate contact with a dynamic heightening in Situ. In comparison studies, Li et al⁶⁹ reported that preoperative and postoperative segmental lordosis statistically significantly increased at all time points in the expandable LLIF cohort, whereas an improvement was only elicited at 24 mo in the static LLIF cohort. No difference was appreciated between the expandable and static groups. Frisch et al⁶⁶ reported equivalent changes in segmental lordosis with respect to both preoperative versus postoperative measures and expandable versus static cages.

TABLE 2. Literature Review of Expandable Cages for LLIF

Author	N	Surgical indication	Clinical outcome	Radiographic outcome	Follow-up
Frisch et al ⁶⁶	56 (27 expandable vs 29 static)	All patients with objective evidence of degenerative disc disease (DDD) at 1 or 2 contiguous levels at L2–S1	Although postoperative VAS and ODI scores improved compared to preoperative scales, these patient-reported outcomes did not differ between the static cohort and expandable cohort at any time interval	Postoperative intervertebral disc height and neuroforaminal height significantly improved compared to preoperative radiographic measures Postoperative intervertebral disc height in the static group was statistically significantly greater compared to the expandable groups at all time points. Postoperative neuroforaminal height did not differ between the 2 groups at any time point Subsidence (>2 mm of cage settling) was significantly greater in the static group versus expandable group Radiographic fusion (Brantigan and Steffee scale) was achieved in all patients.	At 6 wk, and 3, 6, 12, and 24 mo
Huang et al ⁶⁸	37	DDD patients, degenerative spondylolisthesis and spinal stenosis with neurogenic claudication	Postintervention decreased VAS and ODI ($P < .001$) No radiculopathy at 12-mo follow-up	Segmental lordosis and mean neuroforaminal height improved ($P < .001$) Fusion measured with the Brantigan, Steffee, and Fraser (BSF) radiographic classification with an outcome of 100% fusion with no revision of surgery Disc height increase in anterior, middle, and posterior at 12 mo mark postoperative ($P < .001$) Bone mineral density revealing mild osteopenia	At 6 wk, 3, 6, 12 mo
Li et al ⁶⁹	62 (35 expandable)	Diagnosis of DDD at 1 or 2 contiguous levels from L1 to L5 with or without grade 1 spondylolisthesis	Mean VAS and leg pain improved significantly in expandable spacer compared to static at 6 and 24 mo ($P < .05$) with the same trend present with the ODI ($P < .05$) Compared to baseline VAS and leg pain improved significantly at 6 wk, 3, 6, 12, and 24 mo ($P < .001$) both in static and expandable groups respectively with same trend present in ODI with both groups respectively ($P < .001$)	In both expandable and static groups, mean disc height increased significantly from baseline ($P < .001$) and ($P < .05$) respectively this was evident at 6 wk, 3, 6, 12, and 24 mo Postoperative neural foraminal heights did not differ between the expandable and static groups. Yet both groups improved compared to preop ($P < .05$) While lordosis significantly increased at all time points in the expandable cohort, the static cohort only saw a statistically significant increase from baseline at only 24 mo All operative levels achieved fusion based on Classification of interbody fusion success: BSF with this respective study achieving a BSF-3 at 24 mo mark Implant subsidence was significantly greater in static group compared to expandable ($P < .05$) with no revision surgery needed in either groups	At 3, 6, 12, 24 mo mark
Smith et al ⁷¹	52	Traumatic thoracic and lumbar fractures	American Spinal Injury Association improved significantly ($P < .001$) Eight patients only experienced complications	Radiographic subsidence was noted between the cylindrical 13.5% vs wide footprint cage 0% respectively	At 12, 24 mo mark

Changes in lordosis with expandable cages have not translated to a significant restoration of disc height. Both Frisch et al⁶⁶ and Li et al⁶⁹ reported greater disc space measurements postoperatively versus preoperatively, but the change was statistically larger in the static versus expandable cohort. This may be due to the overdistraction required when inserting the static cage. While postoperative versus preoperative neuroforamen significantly improved, no difference was appreciated between the expandable and static groups.

Clinical outcomes have been shown to improve after surgery with expandable LLIF.^{66,69} Li et al⁶⁹ demonstrated that improvements in the VAS for back and leg pain as well as ODI were statistically significantly greater in the expandable versus static group. One possible explanation is that improved lordosis, which may serve as a surrogate marker of spinopelvic balance, equates to more favorable PROs. Moreover, the greater impaction necessary with static cages may cause axial pain improvement.

LLIF eliminates retraction of the nerve roots as well as direct entry into the spinal canal or neuroforamen.⁶⁴ These advantages decrease the likelihood of iatrogenic nerve root injury and postoperative epidural adhesions/fibrosis.^{76,77} However, owing to the transpoas approach mandated by the LLIF, risks of postoperative weakness and/or pain on hip flexion secondary to Bovie cautery of the muscle must be addressed in preoperative surgical consent discussions.⁷⁸⁻⁸⁰ Injury to the lumbosacral plexus within the psoas muscle carries the highest danger with access to the L4-L5 level. Other more serious, yet less likely, complications include damage to the great vessel, bowel perforations, and ureteral injury.^{80,81}

Perhaps the most cited disadvantage of the LLIF is the steep learning curve in a minimally invasive procedure with seemingly disorienting anatomy—the patient in a lateral position.

CONCLUSION

Spinal operations have evolved to focus on the intervertebral disc space because of the advent of the expandable cage, and this evolution promises disc restoration, neuroforaminal opening, increased lordosis, and scoliosis correction. From a technical perspective, placement of a collapsed interbody that enlarges in situ decreases the incidence of subsidence or other trauma to the endplates. Expandable cages may be applied to the TLIF, ALIF, and LLIF. TLIF historically represents the most familiar corridor to spine surgeons; however, its utility is limited by extensive scarring and high-grade spondylolisthesis. Of all the static cages, ALIF cages confer the greatest lordotic restoration, so the addition of a dynamic component has potentially the most dramatic alignment correction, although results are still preliminary. Regarding the greatest disadvantage, manipulation anterior to the lumbar spine carries the risk of retroperitoneal damage and hollow viscus injury. Expandable LLIF permits access through virgin tissue without manipulation of the posterior neural elements or prior surgical scars, but the procedure is associated with a learning curve.

Funding

Publication of this supplement was funded by Globus and Medtronic.

Disclosures

Dr Chang has consulting agreements with Depuy Synthes and Globus, and receives some research support from Medtronic. Outside of publication in this supplement, the other authors have no personal, financial, or institutional interest in any of the drugs, materials, or devices described in this article.

REFERENCES

- Hawasli AH, Khalifeh JM, Chatrath A, Yarbrough CK, Ray WZ. Minimally invasive transforaminal lumbar interbody fusion with expandable versus static interbody devices: radiographic assessment of sagittal segmental and pelvic parameters. *Neurosurg Focus*. 2017;43(2):E10.
- Kim CW, Doerr TM, Luna IY, et al. Minimally invasive transforaminal lumbar interbody fusion using expandable technology: a clinical and radiographic analysis of 50 patients. *World Neurosurg*. 2016;90:228-235.
- Stein IC, Than KD, Chen KS, Wang AC, Park P. Failure of a polyether-etherketone expandable interbody cage following transforaminal lumbar interbody fusion. *Eur Spine J*. 2015;24(Suppl 4):S555-S559.
- Massie LW, Zakaria HM, Schultz LR, Basheer A, Buraimoh MA, Chang V. Assessment of radiographic and clinical outcomes of an articulating expandable interbody cage in minimally invasive transforaminal lumbar interbody fusion for spondylolisthesis. *Neurosurg Focus*. 2018;44(1):E8.
- Yee TJ, Joseph JR, Terman SW, Park P. Expandable vs static cages in transforaminal lumbar interbody fusion: radiographic comparison of segmental and lumbar sagittal angles. *Neurosurgery*. 2017;81(1):69-74.
- Boktor JG, Pockett RD, Verghese N. The expandable transforaminal lumbar interbody fusion—two years follow-up. *J Craniovertebr Junction Spine*. 2018;9(1):50-55.
- Morrison R, Rigal J, Le Huec JC, Schnake KJ. Report of one year follow up of patients after TLIF using a 3-dimensional expandable cage for lumbar fusion with lordotic correction. *Global Spine J*. 2016;6(1_Suppl):s-0036-1583147-s-1580036-1583147.
- Vaishnav AS, Saville P, McAnany S, et al. Retrospective review of immediate restoration of lordosis in single-level minimally invasive transforaminal lumbar interbody fusion: a comparison of static and expandable interbody cages. *Oper Neurosurg*. 2020;18(5):518-523.
- Khechen B, Haws BE, Patel DV, et al. Static versus expandable devices provide similar clinical outcomes following minimally invasive transforaminal lumbar interbody fusion. *HSS J*. 2020;16(1):46-53.
- Tassemeier T, Haversath M, Jager M. Transforaminal lumbar interbody fusion with expandable cages: radiological and clinical results of banana-shaped and straight implants. *J Craniovertebr Junction Spine*. 2018;9(3):196-201.
- Kremer MA, Alferink J, Wynsma SM, Shirk T, Ledonio CGT. P16. A retrospective review of transforaminal lumbar interbody fusion patients treated with expandable and static spacers. *Spine J*. 2019;19(9):S165.
- Wang MY, Grossman J. Endoscopic minimally invasive transforaminal interbody fusion without general anesthesia: initial clinical experience with 1-year follow-up. *Neurosurg Focus*. 2016;40(2):E13.
- Alimi M, Shin B, Macielak M, et al. Expandable polyaryl-ether-etherketone spacers for interbody distraction in the lumbar spine. *Global Spine J*. 2015;5(3):169-178.
- Harms J, Rolinger H. A one-stager procedure in operative treatment of spondylolistheses: dorsal traction-reposition and anterior fusion (author's transl). *Z Orthop Ihre Grenzgeb*. 1982;120(3):343-347.
- Garg B, Mehta N. Minimally invasive transforaminal lumbar interbody fusion (MI-TLIF): a review of indications, technique, results and complications. *J Clin Orthop Trauma*. 2019;10(Suppl 1):S156-S162.
- Lan T, Hu SY, Zhang YT, et al. Comparison between posterior lumbar interbody fusion and transforaminal lumbar interbody fusion for the treatment of lumbar degenerative diseases: a systematic review and meta-analysis. *World Neurosurg*. 2018;112:86-93.
- de Kunder SL, van Kuijk SMJ, Rijkers K, et al. Transforaminal lumbar interbody fusion (TLIF) versus posterior lumbar interbody fusion (PLIF) in lumbar spondylolisthesis: a systematic review and meta-analysis. *Spine J*. 2017;17(11):1712-1721.

18. Choi WS, Kim JS, Ryu KS, Hur JW, Seong JH. Minimally invasive transforaminal lumbar interbody fusion at L5-S1 through a unilateral approach: technical feasibility and outcomes. *Biomed Res Int*. 2016;2016:2518394.
19. Abdu WA, Sacks OA, Tosteson ANA, et al. Long-term results of surgery compared with nonoperative treatment for lumbar degenerative spondylolisthesis in the Spine Patient Outcomes Research Trial (SPORT). *Spine (Phila Pa 1976)*. 2018;43(23):1619-1630.
20. Xie Q, Zhang J, Lu F, Wu H, Chen Z, Jian F. Minimally invasive versus open transforaminal lumbar interbody fusion in obese patients: a meta-analysis. *BMC Musculoskelet Disord*. 2018;19(1):15.
21. Narain AS, Hijji FY, Markowitz JS, Kudravalli KT, Yom KH, Singh K. Minimally invasive techniques for lumbar decompressions and fusions. *Curr Rev Musculoskelet Med*. 2017;10(4):559-566.
22. Lee HJ, Kim JS, Ryu KS. Minimally invasive TLIF using unilateral approach and single cage at single level in patients over 65. *Biomed Res Int*. 2016;2016:4679865.
23. Kulkarni AG, Bohra H, Dhruv A, Sarraf A, Bassi A, Patil VM. Minimal invasive transforaminal lumbar interbody fusion versus open transforaminal lumbar interbody fusion. *Indian J Orthop*. 2016;50(5):464-472.
24. Djurasovic M, Rouben DP, Glassman SD, Casnellie MT, Carreon LY. Clinical outcomes of minimally invasive versus open TLIF: a propensity-matched cohort study. *Am J Orthop*. 2016;45(3):E77-E82.
25. Terman SW, Yee TJ, Lau D, Khan AA, La Marca F, Park P. Minimally invasive versus open transforaminal lumbar interbody fusion: comparison of clinical outcomes among obese patients. *J Neurosurg Spine*. 2014;20(6):644-652.
26. Sulaiman WA, Singh M. Minimally invasive versus open transforaminal lumbar interbody fusion for degenerative spondylolisthesis grades 1-2: patient-reported clinical outcomes and cost-utility analysis. *Ochsner J*. 2014;14(1):32-37.
27. Mobbs RJ, Phan K, Malham G, Seex K, Rao PJ. Lumbar interbody fusion: techniques, indications and comparison of interbody fusion options including PLIF, TLIF, MI-TLIF, OLIF/ATP, LLIF and ALIF. *J Spine Surg*. 2015;1(1):2-18.
28. Holly LT, Schwender JD, Rouben DP, Foley KT. Minimally invasive transforaminal lumbar interbody fusion: indications, technique, and complications. *Neurosurg Focus*. 2006;20(3):E6.
29. Schmid R, Krappinger D, Blauth M, Kathrein A. Mid-term results of PLIF/TLIF in trauma. *Eur Spine J*. 2011;20(3):395-402.
30. Adams MA, Dolan P. Lumbar intervertebral disk injury, herniation and degeneration. In: Pinheiro-Franco JL, Vaccaro AR, Benzel EC, Mayer HM, eds. *Advanced Concepts in Lumbar Degenerative Disk Disease*. Berlin, Heidelberg: Springer; 2016:23-39.
31. Jagannathan J, Sansur CA, Oskouian RJ Jr, Fu KM, Shaffrey CI. Radiographic restoration of lumbar alignment after transforaminal lumbar interbody fusion. *Neurosurgery*. 2009;64(5):955-963; discussion 963-954.
32. Godzik J, Lehrman JN, Newcomb A, et al. Tailoring selection of transforaminal interbody spacers based on biomechanical characteristics and surgical goals: evaluation of an expandable spacer. published online: April 12, 2019. *J Neurosurg Spine*. (doi:10.3171/2019.1.SPINE181008).
33. Alvi MA, Kurian SJ, Wahood W, Goyal A, Elder BD, Bydon M. Assessing the difference in clinical and radiologic outcomes between expandable cage and nonexpandable cage among patients undergoing minimally invasive transforaminal interbody fusion: a systematic review and meta-analysis. *World Neurosurg*. 2019;127:596-606.e1.
34. Cannestra AF, Peterson MD, Parker SR, Roush TF, Bundy JV, Turner AW. MIS expandable interbody spacers: a literature review and biomechanical comparison of an expandable MIS TLIF with conventional TLIF and ALIF. *Spine*. 2016;41(Suppl 8):S44-S49.
35. Kwon BK, Berta S, Daffner SD, et al. Radiographic analysis of transforaminal lumbar interbody fusion for the treatment of adult isthmic spondylolisthesis. *J Spinal Disord Tech*. 2003;16(5):469-476.
36. McMordie JH, Schmidt KP, Gard AP, Gillis CC. Clinical and short-term radiographic outcomes of minimally invasive transforaminal lumbar interbody fusion with expandable lordotic devices. *Neurosurgery*. 2020;86(2):E147-E155.
37. Kremer MA, Alferink J, Wynsma S, Shirk T, Ledonio C. Expandable spacers provide better functional outcomes than static spacers in minimally invasive transforaminal lumbar interbody fusion. *J Spine Surg*. 2019;5(3):315-319.
38. Djurasovic MO, Carreon LY, Glassman SD, Dimar JR, 2nd, Puno RM, Johnson JR. Sagittal alignment as a risk factor for adjacent level degeneration: a case-control study. *Orthopedics*. 2008;31(6):546.
39. Kumar MN, Baklanov A, Chopin D. Correlation between sagittal plane changes and adjacent segment degeneration following lumbar spine fusion. *Eur Spine J*. 2001;10(4):314-319.
40. Nakai S, Yoshizawa H, Kobayashi S. Long-term follow-up study of posterior lumbar interbody fusion. *J Spinal Disord*. 1999;12(4):293-299.
41. Schwab FJ, Blondel B, Bess S, et al. Radiographical spinopelvic parameters and disability in the setting of adult spinal deformity: a prospective multicenter analysis. *Spine*. 2013;38(13):E803-E812.
42. Tempel ZJ, Gandhoke GS, Bolinger BD, et al. The influence of pelvic incidence and lumbar lordosis mismatch on development of symptomatic adjacent level disease following single-level transforaminal lumbar interbody fusion. *Neurosurgery*. 2017;80(6):880-886.
43. Lau D, Song Y, Guan Z, La Marca F, Park P. Radiological outcomes of static vs expandable titanium cages after corpectomy: a retrospective cohort analysis of subsidence. *Neurosurgery*. 2013;72(4):529-539; discussion 528-529.
44. Bhatia NN, Lee KH, Bui CN, Luna M, Wahba GM, Lee TQ. Biomechanical evaluation of an expandable cage in single-segment posterior lumbar interbody fusion. *Spine*. 2012;37(2):E79-E85.
45. Karikari IO, Grossi PM, Nimjee SM, et al. Minimally invasive lumbar interbody fusion in patients older than 70 years of age: analysis of peri- and postoperative complications. *Neurosurgery*. 2011;68(4):897-902; discussion 902.
46. Saraph V, Lerch C, Walochnik N, Bach CM, Krismer M, Wimmer C. Comparison of conventional versus minimally invasive extraperitoneal approach for anterior lumbar interbody fusion. *Eur Spine J*. 2004;13(5):425-431.
47. Mayer HM. A new microsurgical technique for minimally invasive anterior lumbar interbody fusion. *Spine*. 1997;22(6):691-699; discussion 700.
48. Zucherman JF, Zdeblick TA, Bailey SA, Mahvi D, Hsu KY, Kohrs D. Instrumented laparoscopic spinal fusion. Preliminary results. *Spine*. 1995;20(18):2029-2034; discussion 2034-2025.
49. Mummaneni PV, Haid RW, Rodts GE. Lumbar interbody fusion: state-of-the-art technical advances. Invited submission from the joint section meeting on disorders of the spine and peripheral nerves, March 2004. *J Neurosurg Spine*. 2004;1(1):24-30.
50. Shen FH, Samartzis D, Khanna AJ, Anderson DG. Minimally invasive techniques for lumbar interbody fusions. *Orthop Clin North Am*. 2007;38(3):373-386; abstract vi.
51. Jackson KL, Yeoman C, Chung WM, Chappuis JL, Freedman B. Anterior lumbar interbody fusion: two-year results with a modular interbody device. *Asian Spine J*. 2014;8(5):591-598.
52. Lee R. Expandable anterior lumbar interbody fusion cages – early clinical and radiographic results and the ability to fine tune adjacent segmental lordosis. *The International Society for the Advancement of Spine Surgery*. Toronto, Ontario, Canada; 2018.
53. Mobbs RJ, Loganathan A, Yeung V, Rao PJ. Indications for anterior lumbar interbody fusion. *Orthop Surg*. 2013;5(3):153-163.
54. Vaccaro AR, Fisher CG, Prasad SK, et al. Evidence-based recommendations for spine surgery. *Spine*. 2016;41(3):E165-E173.
55. Hironaka Y, Morimoto T, Motoyama Y, Park YS, Nakase H. Surgical management of minimally invasive anterior lumbar interbody fusion with stand-alone interbody cage for L4-5 degenerative disorders: clinical and radiographic findings. *Neurol Med Chir*. 2013;53(12):861-869.
56. Oxland TR, Lund T. Biomechanics of stand-alone cages and cages in combination with posterior fixation: a literature review. *Eur Spine J*. 2000;9(Suppl 1):S95-S101.
57. Zhang JD, Poffyn B, Sys G, Uyttendaele D. Are stand-alone cages sufficient for anterior lumbar interbody fusion? *Orthop Surg*. 2012;4(1):11-14.
58. Strube P, Hoff E, Hartwig T, Perka CF, Gross C, Putzier M. Stand-alone anterior versus anteroposterior lumbar interbody single-level fusion after a mean follow-up of 41 months. *J Spinal Disord Tech*. 2012;25(7):362-369.
59. Chen D, Fay LA, Lok J, Yuan P, Edwards WT, Yuan HA. Increasing neuroforaminal volume by anterior interbody distraction in degenerative lumbar spine. *Spine*. 1995;20(1):74-79.
60. Dennis S, Watkins R, Landaker S, Dillin W, Springer D. Comparison of disc space heights after anterior lumbar interbody fusion. *Spine*. 1989;14(8):876-878.
61. Duggal N, Mendiondo I, Pares HR, et al. Anterior lumbar interbody fusion for treatment of failed back surgery syndrome: an outcome analysis. *Neurosurgery*. 2004;54(3):636-643; discussion 643-634.
62. Flynn JC, Price CT. Sexual complications of anterior fusion of the lumbar spine. *Spine*. 1984;9(5):489-492.

63. Regan JJ, Yuan H, McAfee PC. Laparoscopic fusion of the lumbar spine: minimally invasive spine surgery. A prospective multicenter study evaluating open and laparoscopic lumbar fusion. *Spine*. 1999;24(4):402-411.
64. Kwon B, Kim DH. Lateral lumbar interbody fusion: Indications, outcomes, and complications. *J Am Acad Orthop Surg*. 2016;24(2):96-105.
65. Srikantha U, Lokanath YK, Hari A, Nirmala S, Varma RG. Minimally invasive lateral transpoas approach for lumbar corpectomy and stabilization. *Surg Neurol Int*. 2019;10:153.
66. Frisch RF, Luna IY, Brooks DM, Joshua G, O'Brien JR. Clinical and radiographic analysis of expandable versus static lateral lumbar interbody fusion devices with two-year follow-up. *J Spine Surg*. 2018;4(1):62-71.
67. Mattei TA, Hanovnikian J, Dinh HD. Progressive kyphotic deformity in comminuted burst fractures treated non-operatively: the Achilles tendon of the Thoracolumbar Injury Classification and Severity Score (TLICS). *Eur Spine J*. 2014;23(11):2255-2262.
68. Huang Z, Li YM, Towner J, Li YI, Edsall A, Ledonio C. Laterally placed expandable interbody spacers improve radiographic and clinical outcomes: a 1-year follow-up study. *Interdiscip Neurosurg*. 2020;20:100639.
69. Li YM, Frisch RF, Huang Z, et al. Comparative effectiveness of expandable versus static interbody spacers via MIS LLIF: a 2-year radiographic and clinical outcomes study. published online: October 29, 2019. *Global Spine J*. (doi:10.1177/2192568219886278).
70. Smith WD, Dakwar E, Le TV, Christian G, Serrano S, Uribe JS. Minimally invasive surgery for traumatic spinal pathologies: a mini-open, lateral approach in the thoracic and lumbar spine. *Spine*. 2010;35(26 Suppl):S338-S346.
71. Smith WD, Ghazarian N, Christian G. Acute and hyper-acute thoracolumbar corpectomy for traumatic burst fractures using a mini-open lateral approach. *Spine*. 2018;43(2):E118-E124.
72. Krafft PR, Noureldine MHA, Greenberg MS, Alikhani P. Minimally invasive lateral retropleural approach to the thoracic spine for salvage of a subsided expandable interbody cage. *World Neurosurg*. 2020;135:58-62.
73. Amaral R, Marchi L, Oliveira L, Coutinho T, Pimenta L. Acute lumbar burst fracture treated by minimally invasive lateral corpectomy. *Case Rep Orthop*. 2013;2013:953897.
74. Basheer A, Macki M, La Marca F. Options for interbody grafting. In: Kaiser M, Haid R, Shaffrey C, Fehlings MG, eds. *Degenerative Cervical Myelopathy and Radiculopathy*. Springer; 2019:309-318.
75. Foley KT, Holly LT, Schwender JD. Minimally invasive lumbar fusion. *Spine*. 2003;28(15 Suppl):S26-S35.
76. Rihn JA, Patel R, Makda J, et al. Complications associated with single-level transforaminal lumbar interbody fusion. *Spine J*. 2009;9(8):623-629.
77. Potter BK, Freedman BA, Verwiebe EG, Hall JM, Polly DW Jr, Kuklo TR. Transforaminal lumbar interbody fusion: clinical and radiographic results and complications in 100 consecutive patients. *J Spinal Disord Tech*. 2005;18(4):337-346.
78. Knight RQ, Schwaegler P, Hanscom D, Roh J. Direct lateral lumbar interbody fusion for degenerative conditions: early complication profile. *J Spinal Disord Tech*. 2009;22(1):34-37.
79. Lee YP, Regev GJ, Chan J, et al. Evaluation of hip flexion strength following lateral lumbar interbody fusion. *Spine J*. 2013;13(10):1259-1262.
80. Aichmair A, Fantini GA, Garvin S, Beckman J, Girardi FP. Aortic perforation during lateral lumbar interbody fusion. *J Spinal Disord Tech*. 2015;28(2):71-75.
81. Malham GM, Ellis NJ, Parker RM, Seex KA. Clinical outcome and fusion rates after the first 30 extreme lateral interbody fusions. *ScientificWorldJournal*. 2012;2012:246989.