

Henry Ford Health

Henry Ford Health Scholarly Commons

Otolaryngology Articles

Otolaryngology - Head and Neck Surgery

5-18-2021

Critical Review and Consensus Statement for Neural Monitoring in Otolaryngologic Head, Neck, and Endocrine Surgery

Joseph Scharpf

Jeffrey C. Liu

Catherine Sinclair

Michael C. Singer

Henry Ford Health, MSINGER1@hfhs.org

Whitney Liddy

See next page for additional authors

Follow this and additional works at: https://scholarlycommons.henryford.com/otolaryngology_articles

Recommended Citation

Scharpf J, Liu JC, Sinclair C, Singer M, Liddy W, Orloff L, Steward D, Bonilla Velez J, and Randolph GW. Critical Review and Consensus Statement for Neural Monitoring in Otolaryngologic Head, Neck, and Endocrine Surgery. Otolaryngol Head Neck Surg 2021.

This Article is brought to you for free and open access by the Otolaryngology - Head and Neck Surgery at Henry Ford Health Scholarly Commons. It has been accepted for inclusion in Otolaryngology Articles by an authorized administrator of Henry Ford Health Scholarly Commons.

Authors

Joseph Scharpf, Jeffrey C. Liu, Catherine Sinclair, Michael C. Singer, Whitney Liddy, Lisa Orloff, David Steward, Juliana Bonilla Velez, and Gregory W. Randolph

Critical Review and Consensus Statement for Neural Monitoring in Otolaryngologic Head, Neck, and Endocrine Surgery

Joseph Scharpf, MD¹, Jeffrey C. Liu, MD², Catherine Sinclair, MD³, Michael Singer, MD⁴, Whitney Liddy, MD⁵, Lisa Orloff, MD⁶, David Steward, MD⁷, Juliana Bonilla Velez, MD⁸, and Gregory W. Randolph, MD⁹

Otolaryngology–
Head and Neck Surgery
1–16

© American Academy of
Otolaryngology–Head and Neck
Surgery Foundation 2021
Reprints and permission:
sagepub.com/journalsPermissions.nav
DOI: 10.1177/01945998211011062
http://otojournal.org



Abstract

Background. Enhancing patient outcomes in an array of surgical procedures in the head and neck requires the maintenance of complex regional functions through the protection of cranial nerve integrity. This review and consensus statement cover the scope of cranial nerve monitoring of all cranial nerves that are of practical importance in head, neck, and endocrine surgery except for cranial nerves VII and VIII within the temporal bone. Complete and applied understanding of neurophysiologic principles facilitates the surgeon's ability to monitor the at-risk nerve.

Methods. The American Academy of Otolaryngology–Head and Neck Surgery (AAO-HNS) identified the need for a consensus statement on cranial nerve monitoring. An AAO-HNS task force was created through soliciting experts on the subject. Relevant domains were identified, including residency education, neurophysiology, application, and various techniques for monitoring pertinent cranial nerves. A document was generated to incorporate and consolidate these domains. The panel used a modified Delphi method for consensus generation.

Results. Consensus was achieved in the domains of education needs and anesthesia considerations, as well as setup, troubleshooting, and documentation. Specific cranial nerve monitoring was evaluated and reached consensus for all cranial nerves in statement 4 with the exception of the spinal accessory nerve. Although the spinal accessory nerve's value can never be marginalized, the task force did not feel that the existing literature was as robust to support a recommendation of routine monitoring of this nerve. In contrast, there is robust supporting literature cited and consensus for routine monitoring in certain procedures, such as thyroid surgery, to optimize patient outcomes.

Conclusions. The AAO-HNS Cranial Nerve Monitoring Task Force has provided a state-of-the-art review in neural monitoring in otolaryngologic head, neck, and endocrine surgery. The evidence-based review was complemented by consensus statements utilizing a modified Delphi method to prioritize key statements to enhance patient outcomes in an array of surgical procedures in the head and neck. A precise

definition of what actually constitutes intraoperative nerve monitoring and its benefits have been provided.

Keywords

nerve monitoring, intraoperative nerve monitoring, endocrine surgery, head and neck nerve monitoring

Received December 16, 2020; accepted March 30, 2021.

Introduction

Enhancing patient outcomes in a wide array of surgical procedures in the head and neck requires the maintenance of complex regional functions through the protection of cranial nerve integrity. In many circumstances, functional nerve information is valuable for optimizing nerve management and, ultimately, in the realization of one of the overarching goals in the standard of care in head and neck surgery, which is to maintain cranial nerve function when possible. Although the exact format may vary, nerve monitoring and stimulation testing are potentially valuable to cranial nerve surgical management and represent a separate additional endeavor concerning equipment, setup, and data interpretation. Electrophysiologic assessment of the pertinent nerves is within the scope of an

¹Cleveland Clinic Foundation Head and Neck Institute, Cleveland, Ohio, USA

²Lewis Katz School of Medicine, Temple University, Philadelphia, Pennsylvania, USA

³New York Eye and Ear Infirmary of Mount Sinai, New York, New York, USA

⁴Henry Ford Health System, Detroit, Michigan, USA

⁵Northwestern University, Chicago, Illinois, USA

⁶Stanford University, Palo Alto, California, USA

⁷University of Cincinnati, Cincinnati, Ohio, USA

⁸Seattle Children's Hospital, Seattle, Washington, USA

⁹Massachusetts Eye and Ear, Boston, Massachusetts, USA

Corresponding Author:

Joseph Scharpf, MD, Cleveland Clinic Foundation Head and Neck Institute, 9500 Euclid Avenue/A71, Cleveland, OH 44195, USA.

Email: scharpj@ccf.org

Table 1. Cranial Nerve Monitoring in Head and Neck Surgery: Neural Stimulation With Muscle and EMG Response Opportunity Profile.

Cranial nerve	Muscle innervation	Muscle response?		EMG		
		Visible	Palpable	Evoked?	Passive monitoring?	Continuous monitoring?
VII: Facial	Facial muscles/platysma	Yes	Yes	Yes	Yes	
IX: Glossopharyngeal	Stylopharyngeus	No	No	Yes	Yes	
X: Vagus						
RLN	Vocalis/thyroarytenoid, posterior cricoarytenoid	No	Yes	Yes	Yes	Yes
SLN	Cricothyroid	Yes	Yes	Yes	Yes	Yes
XI: Spinal accessory	Trapezius, sternocleidomastoid	Yes	Yes	Yes	Yes	
XII: Hypoglossal	Genioglossus	Yes	Yes	Yes	Yes	
	Styloglossus/hyoglossus	No	No	Yes	Yes	

Abbreviations: EMG, electromyographic; RLN, recurrent laryngeal nerve; SLN, superior laryngeal nerve.

otolaryngology–head and neck surgical practice, and intraoperative nerve monitoring (IONM) is required in the training of residents and fellows by the American Board of Otolaryngology–Head and Neck Surgery. Position statements proposed by the American Academy of Otolaryngology–Head and Neck Surgery (AAO-HNS) Cranial Nerve Monitoring Task Force¹ have been endorsed by the AAO-HNS concerning intraoperative cranial nerve monitoring as well as IONM in otologic surgery.² Otolaryngologists are trained to perform, interpret, and strategically utilize intraoperative cranial nerve monitoring and nerve stimulation testing. The benefits of IONM have been accepted and supported through evidence-based guidelines on intraoperative cranial nerve monitoring in vestibular schwannoma surgery, which have been endorsed by the Joint Guidelines Committee of the American Association of Neurological Surgeons and the Congress of Neurological Surgeons.³ Recommendation for monitoring in all adult patients regardless of tumor size was supported.

This review and consensus statement will cover the scope of cranial nerve monitoring of all cranial nerves that are of practical importance in head, neck, and endocrine surgery except for cranial nerves VII and VIII within the temporal bone, which have been covered by a prior task force on otologic surgery.² Neural stimulation and monitoring encompass a range of techniques that may use a range of muscle or electromyographic (EMG) endpoints (**Table 1**). For this review and consensus statement, IONM will be inclusive of the range of techniques employed by practitioners to test cranial nerve functional status. These techniques include gross motor observation, intermittent nerve stimulation with muscle twitch observation and EMG response, and continuous stimulation with continuous response monitoring. IONM provides an additive functional status component as compared with full anesthetic paralysis with only visual identification of the nerve for anatomic preservation.

Complete and applied understanding of neurophysiologic principles facilitates the surgeon's ability to monitor the at-risk nerve. Intraoperative neural stimulation and nerve monitoring provide optimal neural detection in specific procedures

such as thyroid surgery, where the level of evidence for monitoring is strongest. It has been shown to accelerate the learning curve for inexperienced thyroid surgeons, allowing them to approach outcome levels comparable to more experienced surgeons.⁴ Furthermore, current evidence supports the cost-effectiveness and benefits of nerve monitoring for patients undergoing thyroidectomy,⁵ and benefits with varying levels of evidence quality in the literature have been put forth for parotidectomy⁶ and neck dissection⁷ as well as hypoglossal nerve stimulator implantation.⁸ Although the level for facial nerve monitoring is not as robust as it is for recurrent laryngeal nerve (RLN) monitoring, it does have a more compelling level of supportive evidence than for monitoring of the spinal accessory nerve.

Methods

The AAO-HNS identified the need for a consensus statement on cranial nerve monitoring. An AAO-HNS task force on this subject was created through soliciting experts on the subject. Relevant domains on the subject were identified, including residency education, neurophysiology, application, and various techniques for monitoring specific pertinent cranial nerves. A document was generated to incorporate these domains and consolidate them. The panel then used a modified Delphi method for consensus generation.

Delphi Survey Method Process and Administration

A modified Delphi survey method was utilized to assess consensus for the proposed statements, with multiple anonymous surveys to minimize bias within the expert panel and facilitate consensus. This process was similar to the processes used in other AAO-HNS clinical consensus statements.⁹ In our method, a 9-point Likert scale was used to measure agreement, with 7 being the threshold for agreement and consensus. The criteria for consensus were established a priori:

- **Consensus:** Statements achieving a mean score of 7.00 or higher and having no more than 1 outlier,

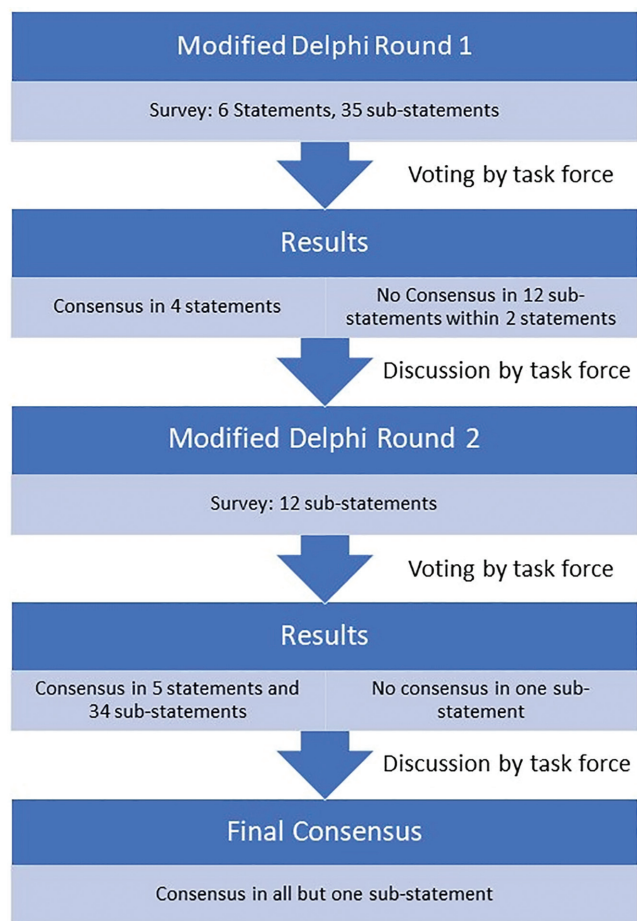


Figure 1. Modified Delphi method schematic.

defined as any rating 2 or more Likert points less than 7.

- **No consensus:** Statements that did not meet the criteria of consensus.

Web-based software (www.surveymonkey.com) was used to administer confidential surveys to panel members. All answers were deidentified and remained confidential; however, names were collected to ensure proper complete response by the 9-person task force.

Overall, 2 Delphi rounds were necessary (**Figure 1**). The initial survey comprised 6 major statements with 35 substatements, for a total of 41 questions. The surveys were distributed, and responses were aggregated. The results showed no consensus, as defined here, within 2 statement headings across 12 substatement questions. A conference call convened that reviewed these 12 items of no consensus. The statements were discussed with regard to rationale and proposed changes. Following revisions of the statements, a second round of voting with these now modified 12 substatements was performed. All substatements achieved consensus except 1. Further discussion ensued on the remaining statement, with no additional feedback, and a conclusion of no consensus was affirmed.

Conflict of Interest

The authors were required to have no conflicts of interest, with declarations at the project's inception and at the conclusion of the review. When any conflict of interest was present, that author was recused from participation in all writing, discussion, and editing of the applicable topic.

Grading of Consensus Statements

The statements put forth utilized the 2019 American College of Physicians' grading system. This system employs a validated scale to critically interpret and evaluate the strength and quality of the evidence. Quality of evidence is evaluated by using the guideline grading system of the American College of Physicians, which is adopted from the GRADE system (Grading of Recommendations, Assessment, Development, and Evaluation).¹⁰

Education

Statement 1:

Formal didactic programming on the rationale, benefits, and techniques of IONM of the cranial nerves should be incorporated into the otolaryngology resident training curriculum and offered for all otolaryngology surgeons regardless of the level of training. (Moderate-quality evidence)

Consensus was achieved on the first Delphi round of the survey (mean, 8.56) with all substatements achieving consensus (**Table 2**).

In recent decades, different forms of IONM have been widely adopted for a range of head and neck applications. All of these techniques, whether relying on observable, palpable, or measurable responses (**Table 1**), are intended to aid in the reduction of injury to cranial nerves at risk during surgery. The use of IONM in thyroid surgery has been most robustly studied. When it was introduced in the mid-1990s, the utility of monitoring the RLN was questioned. However, a series of studies have demonstrated that the adoption of IONM in thyroid surgery has been extensive among general surgeons and otolaryngologists¹¹⁻¹³ Importantly, high-volume surgeons are among those most likely to utilize IONM on a routine basis. This wide use of IONM likely reflects its multidimensional functionality in thyroid surgery, as it can facilitate nerve identification, potentially reduce the risk of neuropraxia and transection injuries, and aid in prognostication of postoperative function. Recent data from academic surgeons in the United States suggest that IONM is used by approximately 80% of otolaryngologists and nearly 50% of general surgeons performing thyroid surgery.¹⁴ Neural monitoring has proven value as an educational adjunct. One European study showed younger, less experienced surgeons had improved surgical outcomes equivalent to experienced surgeons with the addition of IONM.⁴

In surgeons trained in otolaryngology or general surgery-based thyroid fellowships, IONM use is nearly universal.¹⁵

Table 2. Initial Survey and First-Round Results. ^a

Statement	Mean Score
1. Formal didactic programming on the rationale, benefits and techniques of IONM of the cranial nerves should be incorporated into the otolaryngology resident training curriculum and offered for all otolaryngology surgeons regardless of level of training.	8.55
1A. Education in IONM should solidify an understanding of its rationale, benefits, and techniques.	8.55
1B. IONM is a worthy topic for inclusion in formal educational programs.	8.44
1C. Education in IONM is an essential component of thyroid/parathyroid fellowship training programs.	8.77
1D. Education in IONM is an essential component of head and neck surgery fellowship training programs.	8.55
1E. Education in IONM is an essential component of residency training programs.	8.33
1F. The option to pursue education in IONM should be available for surgeons at any level of training.	8.55
2. IONM should be closely coordinated with anesthesia, for the selection of anesthetic agents and endotracheal tube positioning for vagal and RLN monitoring. Anesthesia concerns during surgery should remain a priority.	8.66
2A. Coordination with colleagues in anesthesia supports optimal endotracheal tube positioning and selection of anesthetic agents in cases where IONM is utilized.	8.55
2B. Partnership with colleagues in anesthesia is critical for successful and optimal IONM outcomes.	8.55
2C. Concerns raised by anesthesiologists during surgery are important considerations.	8.88
2D. Intraoperative circumstances throughout the case may warrant additional communication and coordination between surgeons and anesthesiologists	8.66
3. Given the surgical importance of loss of signal, surgeons utilizing neural monitoring must be thoroughly fluent with all facets of waveform analysis and equipment troubleshooting to determine nonneural sources in the setting of loss of signal.	7.88
3A. Fluency with electromyography waveform analysis is essential for surgeons who utilize IONM.	7.77
3B. Fluency in determining whether loss of signal arises from a neural or nonneural cause is essential for surgeons who use IONM.	8.55
3C. The ability to perform a structured assessment and determination of nonneural causes of loss of signal is an essential skill for surgeons who use IONM.	8.44
3D. Understanding how surgical decision making relates to loss of signal during IONM is beneficial.	8.66
4. Neural stimulation and monitoring of muscular activity and/or EMG elicited activity should be considered in all patients undergoing surgery that places the following specific nerves at risk. Particular emphasis for monitoring should be placed on those circumstances when IONM may change the extent of surgery and reduce potential significant operative morbidity. (1) The facial nerve (CN 7) in its extra temporal bone segment. (2) The recurrent laryngeal nerve and vagus nerve (CN 10) during thyroid and parathyroid surgery. IONM may change the extent of surgery and reduce potential significant operative morbidity (3) The spinal accessory (CN 11) nerve and hypoglossal (CN 12) during surgeries placing them at risk.	7.44
4A-1. IONM of the extratemporal segment of the facial nerve is beneficial in cases where the nerve and its branches are at risk.	7.55
4A-2. IONM of the extratemporal segment of the facial nerve has utility in cases where the nerve and its branches are at risk.	7.00
4A-3. IONM of the extratemporal segment of the facial nerve is a consideration in cases where the nerve and its branches are at risk.	7.66
4B-1. IONM of the recurrent laryngeal nerve is beneficial in thyroid and parathyroid surgery.	8.11
4B-2. IONM of the recurrent laryngeal nerve has utility in thyroid and parathyroid surgery.	7.77
4B-3. IONM of the recurrent laryngeal nerve is a consideration in thyroid and parathyroid surgery.	8.11
4C-1. IONM of the vagus nerve is beneficial in thyroid and parathyroid surgery.	7.88
4C-2. IONM of the vagus nerve has utility in thyroid and parathyroid surgery.	7.44
4C-3. IONM of the vagus nerve is a consideration in thyroid and parathyroid surgery.	7.66
4D-1. IONM of the spinal accessory nerve is beneficial in cases where it is at risk.	7.22

Abbreviations: EMG, electromyographic; IONM, intraoperative nerve monitoring; RLN, recurrent laryngeal nerve.

^aA score of 7 indicates consensus. Bold indicates ≥ 2 outliers.

The introduction of monitoring has had an impact in changing practice, as seen in the experience of evolving surgical strategy in the groups studied subsequent to its introduction.¹⁶

Utilization of IONM in other head and neck surgical procedures has been less well documented. In parotid surgery, a single study from 2005 found that approximately 60% of

surgeons were using facial nerve monitoring.¹⁷ As with thyroid surgery, utilization during training and higher procedural volume was associated with a higher likelihood of IONM adoption.

Currently, there is little formalized IONM education for head and neck surgery at the resident level. The otolaryngology guidelines of the Accreditation Council for Graduate Medical Education do not mention IONM. While discussion of IONM may be referenced in a module on otologic or thyroid surgery, no discrete module exists on application of, or decision making with, IONM in AcademyU.

In contrast, the American Board of Otolaryngology–Head and Neck Surgery curriculum specifically includes training in the use of IONM for otologic surgery. In the otology learning objectives, there is also a brief mention of techniques for lower cranial nerve monitoring (IX, X, XI, XII). However, no reference is made to IONM as it relates to head and neck training. In addition, several national courses on IONM in thyroid surgery are available, as offered through institutional continuing medical education programs. A recent survey of the American Otological Society, American Neurotology Society, and American Society of Pediatric Otolaryngology evaluated the opinions of IONM for the facial nerve (S Malekzadeh, MD, unpublished data, 2016). In this 10-question survey, IONM of the facial nerve was widely used by otologists/neurotologists.

Despite the absence of IONM from formal training standards and its generally wide adoption, informal instruction is likely occurring during resident training as residents participate in cases that utilize IONM. However, its frequency of use during training is not captured routinely, and the teaching, demonstration, and application of IONM in surgery are not formally specified or captured. With regard to continuing medical education, while select IONM courses are available, there is a paucity of formal courses for physicians on IONM. However, there are multiple detailed published sources in standard recommended high-quality monitoring practices.^{18–20}

Basic Electrophysiology, Anesthesia Considerations, and Setup

Statement 2:

IONM should be closely coordinated with anesthesia, for the selection of anesthetic agents and endotracheal tube positioning for vagal and RLN monitoring. Anesthesia concerns during surgery should remain a priority. (Moderate-quality evidence)

Consensus was achieved on the first Delphi round of survey (mean, 8.67) with all substatements achieving consensus (Table 2).

Surgeon comfort with the fundamental principles behind IONM is critical to the successful implementation of this technology. This includes an understanding of the electrophysiology, the standards for equipment setup and coordination with anesthesia, and the application of troubleshooting algorithms.

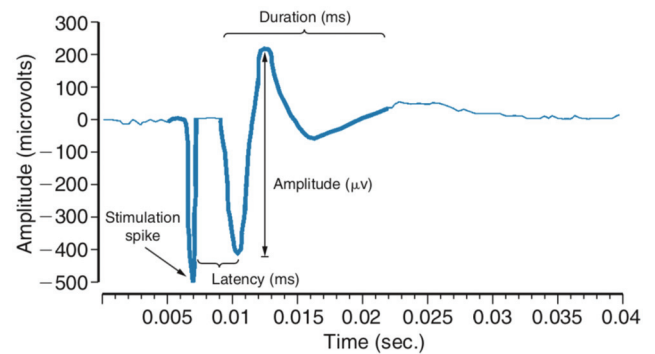


Figure 2. Adapted from: Randolph G. Surgical anatomy and monitoring of the recurrent laryngeal nerve. In: Randolph G, ed. *Surgery of the Thyroid and Parathyroid Glands*. Saunders; 2013:306–340.

Electrophysiology: Basic Concepts and Terminology for Peripheral Nerves

An understanding of the waveform morphology is critical to the surgeon's accurate interpretation of data during intraoperative neural monitoring. The waveform is illustrated in **Figure 2**.

Key terminology:

- **Waveform morphology:** The basic evoked EMG waveform with neural stimulation is usually biphasic or triphasic, representing the summated action potential of the ipsilateral target muscle.
- **Amplitude:** Corresponds to the height of the apex of the positive waveform deflection to the lowest point in the next opposite polarity phase of the waveform.²⁰ This reflects the number of muscle fibers participating in depolarization.²¹ Amplitude can vary within and among patients due to variation in probe-nerve contact, contact with fluid/blood, coverage with tissue, irrigation temperature, recording electrode position, or nerve integrity.
- **Threshold:** Is the current required to first elicit EMG activity. EMG amplitude at threshold stimulation will be lower than the amplitude at maximum stimulation (when all nerve fibers are depolarized). Increasing current above the maximum stimulation suprathreshold level will not lead to increases in EMG amplitude but can expand the sphere of depolarization around the tip of the probe, which can be helpful when initially searching for the nerve.
- **Latency:** While not uniformly defined in the surgical monitoring literature, EMG latency is generally measured as the time from stimulation spike to the first evoked waveform peak. Latency represents the speed of stimulation-induced depolarization and is dependent on the distance between the stimulation point and the target muscle. For example, given the relative lengths of the RLN to the right and left vagal nerves, mean latency is shorter for the RLN (3.97 ms) than the vagus and shorter for the right

Table 3. Seddon and Sunderland Grades of Neural Injury.

Sunderland degree of injury	Seddon classification	Physiology	Prognosis
I	Neurapraxia	Focal myelin sheath injury resulting in a reversible temporary conduction block. Axonal continuity is preserved.	Generally complete recovery within days to months. No synkinesis.
II	Axonotmesis	Disruption of the axon, while the continuity of the endoneurium, perineurium, and epineurium remain intact. Wallerian degeneration occurs distal to the injury site, but regeneration within the endoneurial tube ensures preservation of the original innervation pattern.	Generally good functional outcome within months, with little synkinesis.
III	Axonotmesis	Disruption of the axon and endoneurium, leading to disruption of the internal structure of fasciculi. Wallerian degeneration occurs. Intrafascicular fibrosis can lead to disorganized axonal growth and change the in innervation pattern.	Functional outcomes can vary. Can have synkinesis.
IV	Axonotmesis	Disruption of the axon, endoneurium, and perineurium, leading to alteration of the fascicular structure. Wallerian degeneration occurs. Due to the degree of fibrosis, axonal regrowth can be arrested, limiting spontaneous neural regeneration.	Functional outcomes can vary. Greater risk of synkinesis. A traumatic neuroma may develop. May require surgical exploration, neurolysis, and reconstruction.
V	Neurotmesis	Complete nerve transection. Disruption of the axon, endoneurium, perineurium, and epineurium. Undergoes Wallerian degeneration. Spontaneous neural regeneration is unlikely.	Functional recovery is usually poor and incomplete. Will develop synkinesis. May require surgical exploration, neurolysis, and reconstruction.

Adapted from:

Dionigi G, Snyder SK, Chiang FY, Liddy W, Kamani D, Kyriazidis N. Mechanism of injury. In: Randolph G, ed. *The Recurrent and Superior Laryngeal Nerves*. Springer; 2016:223-237.

Randolph G. Surgical anatomy and monitoring of the recurrent laryngeal nerve. In: Randolph G, ed. *Surgery of the Thyroid and Parathyroid Glands*. Saunders; 2013:306-340.

Seddon H. A classification of nerve injuries. *Br Med J*. 1942;2(4260):237-239.

Sunderland S. The anatomy and physiology of nerve injury. *Muscle Nerve*. 1990;13(9):771-784.

versus left vagus (5.4 vs 8.1 ms) during stimulation in thyroid surgery.²⁰

Waveforms should be interpreted in the context of the nerve being stimulated and confirmed with visual or palpable target muscle contraction to enhance appropriate interpretation of EMG data and avoid potential confusion from far-field artifact waveforms.²²

Neural Injury

The mechanism of intraoperative neural injury is variable and commonly results from surgical errors, including ligation, traction, clamping, suction, compression, contusion, electrical or thermal injury, and rarely complete transection of the nerve.²³ In the absence of complete transection, functional recovery of the nerve varies and is based on the severity of injury. Some injuries, such as stretch or traction injury (the most common mechanisms of RLN injury during thyroid surgery), are not sudden-onset, all-or-nothing injuries but

gradually graded injuries with the potential for reversal/recovery if identified and corrected early. The most frequently used classifications for quantifying the degree of neural injury are those proposed by Seddon and Sunderland,^{24,25} and a summary of these is presented in **Table 3**.

Anesthesia Considerations and Equipment Setup

Partnership with anesthesia is critical for successful and optimal IONM outcomes. Long-acting neuromuscular blockade (NMB) should be avoided after induction of anesthesia, given the potential for reduction in EMG-evoked response and amplitude with the risk of decreased sensitivity for impending neural injury. NMB will also prevent accurate quantitative analysis of EMG data. If short-acting NMB such as succinylcholine is used for induction, the return of full muscular activity should be confirmed as soon as possible after intubation. Aside from avoiding NMB, the anesthesiologist should be able to choose the most appropriate anesthetic for the patient, as very little effect on peripheral nerves and muscles has been

Table 4. Modified Delphi Results: Round 2.^a

Statement	Mean
4A-1. IONM of the extratemporal segment of the facial nerve is beneficial in cases where the nerve and its branches are at risk.	8.67
4A-2. IONM of the extratemporal segment of the facial nerve has utility in cases where the nerve and its branches are at risk.	8.67
4C-2. IONM of the vagus nerve has utility in thyroid and parathyroid surgery.	8.67
4C-3. IONM of the vagus nerve is a consideration in thyroid and parathyroid surgery.	8.78
4D-1. IONM of the spinal accessory nerve is beneficial in cases where it is at risk.	7.56
4D-2. IONM of the spinal accessory nerve has utility in cases where it is at risk.	7.89
4D-3. IONM of the spinal accessory nerve is a consideration in cases where it is at risk.	8.44
4E-1. IONM of the hypoglossal nerve is beneficial in cases where it is both at risk and also integral to the outcome of specific cases such as sleep apnea implant surgery or facial reanimation surgery utilizing the nerve in contrast to routine neck dissection or submandibular gland removal.	8.78
4E-2. IONM of the hypoglossal nerve has utility in cases where it is both at risk and also integral to the outcome of specific cases such as sleep apnea implant surgery or facial reanimation surgery utilizing the nerve in contrast to routine neck dissection or submandibular gland removal.	8.78
4E-3. IONM of the hypoglossal nerve is a consideration in cases where it is both at risk and also integral to the outcome of specific cases such as sleep apnea implant surgery or facial reanimation surgery utilizing the nerve in contrast to routine neck dissection or submandibular gland removal.	8.89
5. The final functional status of the nerve after all aspects of the procedure including achievement of hemostasis have been completed is recommended to be ascertained and documented if the surgeon feels it would affect patient management or counseling. This will provide prognostic information for potential further rehabilitation efforts if needed and prevent unnecessary postoperative nerve testing and even nerve reexploration procedures that would be considered if the nerve functional status was unknown at the end of the procedure.	8.22
5A. Prior to closure, after all other aspects of the procedure have been completed, it may be beneficial to assess the response to neural stimulus in the nerve at risk if the surgeon feels it would affect patient management or counseling.	8.67

Abbreviation: IONM, intraoperative nerve monitoring.

^aA score of 7 indicates consensus. Bold indicates ≥ 2 outliers.

identified with inhalational agents, nitrous oxide, opioids, and propofol.²⁰

While many IONM formats have been utilized and reviewed, standardization of equipment setup and use has been supported to optimize the quality and accuracy of IONM.²⁰ The most widely used monitoring systems typically include EMG with or without a stimulator probe and incorporate either an audio-only system or a system with audio as well as graphic waveform information allowing EMG data analysis. For vagal and RLN monitoring, combined audio and visual systems are preferred by the International Neural Monitoring Study Group given the opportunity for EMG quantification and improved documentation of response.²⁰

IONM employs recording side data and stimulation side data. Recording electrodes are positioned to maximally record the EMG target muscle response for the cranial nerve being monitored—such as needle recording electrodes in the ipsilateral facial muscles (extratemporal CN VII),²⁶ intramuscular needle or adhesive surface electrodes in the trapezius muscle (CN XI),²⁷ or needle electrodes in the tongue (targeting hyoglossus, styloglossus) and floor of mouth (genioglossus) (CN XII).²⁸ Based on simplicity and ease of use, the most common recording electrodes employed for vagal/RLN monitoring are paired endotracheal tube (ET)-based surface

electrodes placed between the vocalis muscles (either prefashioned with integrated electrodes or created with adhesive electrodes placed on a regular ET). Recording electrodes must be paired with a corresponding ground electrode (often placed on the shoulder or sternal area) and the associated connections to the monitor and interface-connector box (**Figure 3**). As the majority of equipment-related problems during RLN/vagal monitoring are due to movement and malpositioning of the ET,²⁹⁻³² it is critical that confirmation of appropriate placement of the ET recording electrodes be performed *after* final surgical positioning with neck extension (either through direct glottic visualization or adequate respiratory variation of the EMG baseline) and partnership with anesthesia continue to the end of surgery to ensure continued optimal ET positioning.^{20,21}

The stimulation component of neural monitoring systems typically includes a neural stimulation probe (typically monopolar but may be bipolar or integrated into a dissecting instrument), its corresponding ground electrode (often placed on the shoulder or substernal area), and associated connections to the monitor and interface-connector box (**Figure 3**). Once setup is complete, monitoring system settings should be checked and verified (eg, impedance values, event threshold settings, stimulator probe current).

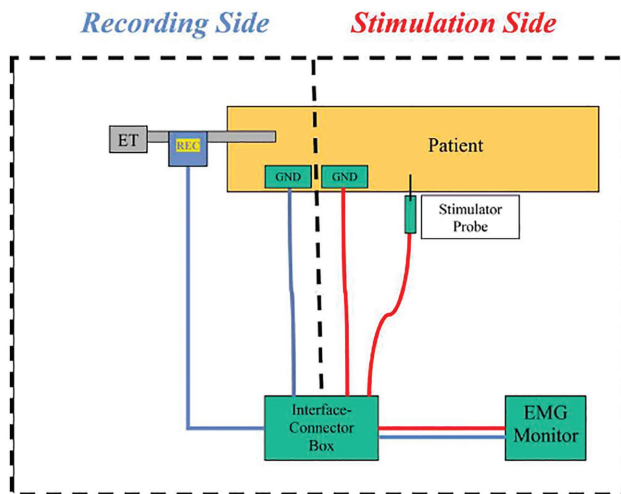


Figure 3. Basic vagal/recurrent laryngeal nerve monitoring equipment setup. EMG, electromyography; ET, endotracheal tube; GND, ground electrodes; REC, recording electrodes.

Statement 3:

Given the surgical importance of loss of signal, surgeons utilizing neural monitoring must be thoroughly fluent with all facets of waveform analysis and equipment troubleshooting to determine nonneural sources in the setting of loss of signal. (Moderate-quality evidence)

Consensus was achieved on the first Delphi round of survey (mean, 7.78) with all substatements achieving consensus (Table 2).

Troubleshooting

During surgery, if a loss of EMG signal is encountered, algorithms for troubleshooting have been developed to determine if an equipment-related problem or true neural injury has occurred.³³ The basic algorithm for troubleshooting involves separating potential equipment-related failures into recording- and stimulation-side problems.²⁰ For vagal and RLN monitoring, a critical maneuver to aid in decision making involves palpation of a laryngeal twitch (with the index finger on the back of the larynx at the level of the posterior cricoarytenoid muscle) with ipsilateral neural stimulation.³⁴ If present, then the nerve is functional, and the problem must be on the recording side (check recording side equipment/connections, most commonly ET malposition). If absent, then either a stimulation side problem has occurred (check equipment and connections, stimulator current, NMB), or there is a true neural injury.

Specific Cranial Nerve Monitoring

Statement 4:

Neural stimulation and monitoring of muscular activity and/or EMG-elicited activity may be considered

in all patients undergoing surgery that places the following specific nerves at risk.

1. *The facial nerve (CN VII) in its extratemporal bone segment. (Low-quality evidence)*
2. *The recurrent laryngeal nerve and/or vagus nerve (CN X) during thyroid and parathyroid surgery. IONM may change the extent of surgery and reduce potential significant operative morbidity. (Moderate-quality evidence)*
3. *The spinal accessory (CN XI) nerve during surgeries that place it at risk. (Low-quality evidence)*
4. *The hypoglossal nerve (CN XII) during surgeries that place it at risk. (Low-quality evidence)*

Particular emphasis for monitoring should be placed on those circumstances when IONM may change the extent of surgery and reduce potential significant operative morbidity.

Consensus was achieved for monitoring of the facial nerve in its temporal bone segment and for monitoring the recurrent laryngeal or vagus nerve during thyroid and parathyroid surgery (Tables 2 and 4).

There was a lack of consensus for monitoring of the spinal accessory nerve (Tables 2 and 4).

Monitoring of the hypoglossal nerve was deemed beneficial and reached consensus for its use in cases where it was integral to the outcome of specific cases, such as hypoglossal nerve stimulator implant surgery or facial reanimation surgery utilizing the nerve in contrast to routine neck dissection or submandibular gland removal (Tables 2 and 4).

Extratemporal Bone Facial Nerve Monitoring (CN VII)

Injury to the extratemporal facial nerve is the most significant and dreaded complication of surgery on the parotid gland. The muscles of facial expression are innervated by the facial nerve, via its dominant frontal, zygomatic, buccal, and marginal mandibular branches. Ocular complications from eye exposure and oral incompetence are the most significant impairments.^{35,36} Up to 40% of patients undergoing parotidectomy experience some temporary facial nerve dysfunction, while permanent dysfunction occurs in 0% to 7% of patients.³⁷⁻⁴⁵ Mechanisms of facial nerve injury are similar to other iatrogenic cranial nerve injuries and include nerve division, stretch, compression, ligature entrapment, thermal and electrical injury, and ischemia.

Recent studies indicate that the majority of otolaryngologists and head and neck surgeons in the United States and United Kingdom utilize nerve monitoring during parotid surgery.^{17,46,47} Facial nerve monitoring is accomplished by either visual monitoring of facial movements or electrophysiologic monitoring of facial muscle EMG activity. The latter, which is the more sensitive, specific, and quantifiable of the 2 methods, is achieved by placing transcutaneous needle electrodes into the facial muscles innervated by the 4 dominant branches, along with ground and stimulator anode electrodes. Neuromuscular blockade is avoided.⁴⁸ Passive, mechanically

evoked responses during surgical dissection can provide immediate feedback to the surgeon regarding the proximity and manipulation of the nerve. Active stimulation of the nerve trunk or its branches is achieved via a sterile pulsed-current stimulation probe, initially set to a stimulus intensity of 0.5 mA, duration of 100 microseconds, rate of 4 bursts/second, and event threshold of 100 microvolts.

As with the monitoring of other cranial nerves, the absence of an electrically evoked response does not exclude the possibility that the stimulated tissue is the facial nerve. Anatomic information and clinical judgment should complement and synergize with electrophysiologic data. The goals of facial nerve monitoring during parotidectomy are the same as the general goals of cranial nerve monitoring: early nerve identification, warning of unexpected nerve stimulation, mapping of the course of the nerve, reduction of mechanical trauma to the nerve, and evaluation and prognosis of nerve function at the conclusion of the procedure.⁴⁹ A growing body of literature on surgeon-performed facial nerve monitoring exists to support its routine use during parotidectomy.⁵⁰⁻⁷⁰ However, most studies are retrospective nonrandomized single-institution studies with relatively small sample sizes, and patient and monitoring parameters are heterogeneous. The limited prospective study results available suggest a reduction in duration of surgery when monitoring is employed, without a significant difference in long-term facial nerve outcomes.^{57,58,59} A meta-analysis of 7 studies involving 546 parotidectomies noted a reduction in temporary postoperative facial nerve paralysis and a trend but not a significant reduction in permanent facial nerve paralysis in monitored surgery.⁴⁵

Conflicting results exist on outcomes in primary versus reoperative surgery and in partial versus total parotidectomy. A multi-institutional prospective randomized study of sufficient size and statistical power to potentially demonstrate the benefit of facial nerve monitoring in reducing the frequency of facial nerve paralysis has yet to be performed. Still, independent of statistics on surgery duration and facial nerve outcomes, most studies cite several advantages of monitoring: (1) improved ability to determine the topographical identity of the facial nerve and its distal branches, (2) improved ability to differentiate the facial nerve from other tissue, (3) improved dynamic actionable awareness of potentially injurious manipulation of the facial nerve, and (4) acquisition of prognostic information about facial nerve function during surgery.

Glossopharyngeal Nerve (CN IX)

The glossopharyngeal nerve has primarily sensory function but does innervate the stylopharyngeus muscle, which is involved with elevating the larynx and dilating the pharynx during swallowing. Of the lower cranial nerves with motor function, the glossopharyngeal is less commonly at risk during head and neck surgery but may be monitored during selective skull base procedures. The nerve can be monitored intraorally with electrodes in the soft palate or posterior pharyngeal wall and requires comonitoring of the vagus (CN X) to identify selective glossopharyngeal stimulation.⁷¹⁻⁷⁴

Reduction in the ratio of glossopharyngeal to vagal amplitude is associated with soft palate dysfunction, dysphagia, and loss of gag reflex.^{71,72}

Recurrent Laryngeal Nerve/Vagus (CN X)

In thyroid and parathyroid surgery, the immediate proximity of the RLN and external branch of the superior laryngeal nerve (EBSLN) to the operative field places them at potential risk of injury. Traditionally, rates of nerve injury during thyroid and parathyroid procedures have been reportedly low (3%-5%); however, this is likely a significant underestimation of the true incidence, with many recent series quoting rates closer to 10%.^{75,76} Similarly, although the actual incidence of EBSLN injury remains unknown, it has been reported as high as 58%.⁷⁷ These inconsistencies in injury rates may result from a lack of standardization of pre- and postoperative laryngeal examination practices, the often subtle and variable nature of nerve palsy symptoms, and reporting biases from large thyroid centers where complication rates are low. Several large national databases in the United Kingdom and Europe have shown that the rate of RLN paralysis is significantly underreported in part due to the variable rates of postoperative laryngeal examination.⁷⁸⁻⁸⁰ Vocal cord paralysis rates from a large meta-analysis of >25,000 patients and large Medicare population found an immediate vocal cord paralysis rate after surgery of approximately 9%.⁷⁵ Factors increasing the risk include age, comorbidity, advanced stage of the disease, extensive dissection, and lesser surgical experience.⁸¹

Clinical implications of unilateral RLN injury revolve around breathing, phonation, and swallowing with a range of severity from mild to severe impairment.⁸² Vocal cord paralysis can engender dysphonia, aspiration, dysphagia, ineffective cough, and difficulty in maneuvers requiring glottic closure such as lifting. It is independently predictive of hospital readmission, length of stay, respiratory tract infection, and increased risk for gastrostomy and tracheotomy.⁸³ Furthermore, bilateral RLN injury can lead to significant respiratory distress and necessitate the placement of a tracheostomy. Similarly, clinical symptoms of EBSLN injury can be significant and are often out of proportion to examination findings. Such changes include vocal fatigue and alterations in vocal range and pitch, all of which can significantly impair quality of life and livelihood. Vagal and/or RLN nerve monitoring during neck endocrine surgery aims to minimize the risk of iatrogenic nerve injuries by various means, including neural mapping/early nerve detection, differentiation between neural and nonneural tissue, and dynamic awareness of neural presence and function during surgery. Furthermore, it enhances the identification of atypical nerve branching patterns and neural function prognostication with the recognition and potential prevention of impending neuropraxia and loss of signal.^{20,84}

Techniques for monitoring of the RLN during thyroid and parathyroid surgery range from direct assessment of posterior cricoarytenoid muscle contraction with palpation to near-continuous EMG assessment of the course of the complete

RLN. While some surgeons utilize hook wire electrodes for EMG RLN monitoring, surface electrodes placed on an ET are the most widely adopted methodology. These ET electrodes are positioned to contact the true vocal cords, assessing the evoked response of the thyroarytenoid and lateral cricoarytenoid muscles from stimulation of the RLN. RLN stimulation can be achieved either directly or, alternatively, by stimulation of the vagus nerve. Vagus nerve stimulation allows the complete neural course of the RLN to be tested and may provide improved real-time intraoperative predictive information, which preliminarily seems to be extrapolated to lower rates of nerve injury. Safety analysis of the world literature of 4000 patients receiving repetitive vagal stimulation during surgery showed no cardiopulmonary or adverse neural events.^{85,86}

Currently, intermittent stimulation of the RLN is the most widely adopted method of IONM.^{12,13} The International Neural Monitoring Study Group has published guidelines for a standardized method for this type of IONM that results in consistently reliable data.²⁰ Continuous IONM, in which stimulation of the nerve occurs more frequently, has also been recently described.^{84,87} Continuous IONM, as performed with a lead placed on the vagus nerve, provides near real-time feedback on the functional status of the RLN with the potential advantage of identifying impending neuropraxia before it results in a loss of signal. In addition to the RLN, IONM can aid in the preservation of the EBSLN, which is critical for pitch modulation and voice projection.¹⁹ IONM with intermittent RLN stimulation can facilitate nerve dissection. Circumstances where this strategy may be particularly useful include patients exhibiting aberrant RLN branching patterns and revision surgery. Most important, in contrast to visual evaluation only, intermittent IONM assesses the dynamic awareness of the structural presence and functional status of the RLN and provides potentially critical prognostic information to inform intraoperative decisions and postoperative counseling. The loss of signal correlates highly with postoperative vocal cord paralysis.⁸⁸ In planned bilateral surgery, intraoperative recognition of loss of signal on the first side of surgery can alert surgeons to the possibility of bilateral vocal cord paralysis if they were to proceed onto the contralateral side. Crucially, in many cases, this can lead to the consideration of ending the surgery, avoiding any possibility of bilateral RLN injury and consequent airway compromise.^{20,89} This permits further discussion with the patient, reassessment of the need for completion surgery, and, if absolutely indicated, staging to allow the initial RLN to recover function potentially. Furthermore, if IONM is used and loss of signal occurs, postoperative counseling can be facilitated and early intervention initiated, including voice therapy and early vocal cord augmentation procedures for symptomatic hoarseness.

When continuous IONM is performed with a vagus nerve electrode, EMG amplitude and latency variations can suggest an impending loss of EMG signal and RLN injury. By changing or stopping the surgical maneuver that led to the amplitude/latency variations, loss of signal and vocal cord paralysis may be avoided. Early investigations of continuous IONM

have demonstrated remarkably low rates of temporary and permanent RLN injury.^{19,90} In addition, these studies have shown that changes in RLN EMG waveforms during surgical maneuvers commonly performed in thyroid surgery occur more frequently than previously recognized with intermittent nerve monitoring alone.

Numerous guidelines and consensus statements have been published discussing the application and appropriate use of vagus nerve/RLN IONM in thyroid surgery. Highlights from these various statements are summarized in turn.

The International Neural Monitoring Study Group is an international multidisciplinary collaboration established to develop the best practices for the preservation of the laryngeal nerves during surgery. A consensus guideline in 2 parts was designed to guide best practices in the management of laryngeal nerve preservation.^{91,92} Recapitulation of this nearly 75-page 2-part document would be redundant here, but certain major themes are worthy of mention. The data are robust that RLN injury remains a persistent problem in parathyroid/thyroid surgery, with significant impact. IONM provides key functional information on the status of the RLN and allows for intraoperative decision making when changes to RLN functional status evolve during surgery. Signal loss during IONM can vary from signal changes indicating impending neuropraxia to evolving neuropraxia and significant injury. Intraoperative decision making depending on the degree of RLN signal change is discussed, including the context of the injury and whether the patient has fully functional bilateral vocal cord function preoperatively or preoperative paresis or paralysis. The use of surgical staging, either planned or unplanned, in the case of intraoperative loss of signal is discussed as are the pros and cons of stimulatory versus continuous vagus nerve monitoring.

The International Neural Monitoring Study Group document is extensive and comprehensive as well as technically rich. Two important recommendations from part 1 of the document include recommendation 1: neural monitoring information should be obtained and utilized in the strategy of a planned bilateral procedure by staging the surgery in the setting of ipsilateral loss of signal. This algorithm should be shared and discussed with the patient during the preoperative informed consent process. Moreover, recommendation 2 is that the surgeon should prioritize concern for the obvious significant medical and psychological morbidity of bilateral vocal cord paralysis and possible tracheotomy, even temporary, over perceived surgical convenience. It is discouraged to routinely perform the entirety of the planned operation; rather, there should be an open acknowledgment of the surgical complication of ipsilateral loss of signal. The full benefit of neural monitoring information in this surgical setting is appreciated through optimization of the patient's quality of life as well as surgical cost.

Multiple consensus guidelines have been published by the American Head and Neck Society—Endocrine Section, including the management of well-differentiated thyroid cancer,⁹³ recurrent thyroid cancer,⁹⁴ and the central compartment in well-differentiated thyroid cancer.⁹⁵ All reflect similar

themes on the application of IONM in thyroid surgery for cancer. Preoperative evaluation of vocal cord function and voice function is strongly recommended in this evaluation prior to surgery, with flexible transnasal laryngoscopy being the optimal examination modality.⁹⁶ Most guideline statements agree that preoperative laryngoscopy is essential in patients with vocal hoarseness, prior neck surgery on the ipsilateral side, or prior neck malignancy. Intraoperative decision making with IONM is discussed in the context of preoperative vocal cord mobility status—in general, preservation of the RLN is favored in patients with preoperatively normal vocal cord function, and avoidance of tracheostomy is encouraged. When oncologic priorities conflict with functional priorities, selection of a surgical strategy that avoids tracheostomy but optimizes oncologic outcomes is preferred.

The 2015 American Thyroid Association guidelines⁹⁷ state that all patients undergoing thyroid surgery should have preoperative voice assessment as part of their preoperative physical examination and that the preoperative laryngeal examination should be performed in all patients with voice abnormalities, history of cervical or upper chest surgery, and known thyroid carcinoma with posterior extrathyroidal extension or extensive central nodal metastases. With regard to IONM, these guidelines provide minimal guidance to its benefits but do state that IONM may be a useful technique for intraoperative decision making and management of the RLN. Finally, the AAO-HNS has published a clinical practice guideline on improving voice outcomes following thyroid surgery.⁷⁸ These guidelines recommend preoperative laryngoscopy for similar indications as the American Thyroid Association guidelines. In addition, clinical practice guideline statement 7 recommends IONM application as an option in thyroid/parathyroid surgery with special utility in revision surgery and surgery on an only functioning nerve.

Overall, multiple guidelines reference the valuable information provided by IONM in intraoperative decision making during thyroid surgery. Particular circumstances that may benefit from IONM include the presence of preoperative vocal cord paresis/paralysis with or without malignancy, management of thyroid malignancy with extrathyroidal extension, and revision/recurrent thyroid surgery with or without malignancy. A common consensus theme is a focus on preservation of laryngeal function and avoidance of tracheostomy. With neural monitoring, ipsilateral nerve function can be established definitively prior to operating on the second side. With this information, the application of neural monitoring is recommended for all bilateral thyroid surgery.⁵

Spinal Accessory Nerve (CN XI)

The spinal accessory nerve (CN XI) innervates the sternocleidomastoid and trapezius muscles, which are critical for maintenance of shoulder function.⁹⁸⁻¹⁰⁰ Intraoperative nerve stimulation can discriminate between the sternocleidomastoid and trapezius branches and determine which cervical branches contribute motor function.^{98,99} The spinal accessory nerve is at risk during any surgery involving the lateral neck, particularly during lymph node biopsy or cervical

lymphadenectomy, and intraoperative nerve stimulation and monitoring have been shown to be safe and effective.¹⁰¹⁻¹⁰⁴ IONM during neck dissection was associated with better trapezius EMG values 6 months postoperatively for nerves monitored versus not monitored in a prospective controlled study.¹⁰³ Shoulder dysfunction was significantly greater for patients with reduced neuromuscular stimulation response at the end of dissection as compared with the time of nerve identification.¹⁰² Postoperative recovery of shoulder dysfunction was greater for those with better postdissection stimulation response¹⁰² and better postoperative trapezius EMG values.¹⁰⁰ Despite these data, the overall data are limited and of variable quality, as noted in a recent systematic review.¹⁰⁵

Hypoglossal Nerve (CN XII)

The hypoglossal nerve (CN XII) provides primary innervation to the tongue, and its function is critical for speaking, swallowing, and maintenance of the oropharyngeal airway.¹⁰⁶ The hypoglossal nerve is vulnerable to injury involving surgery of the tongue and upper neck. Recently, hypoglossal nerve stimulation and monitoring have become critical to the correct placement of the cuff electrode for hypoglossal nerve stimulator implantation for obstructive sleep apnea.¹⁰⁷⁻¹¹² Perhaps in no other surgery involving the lower cranial motor nerves is direct surgeon stimulation and EMG monitoring of the various branches of the hypoglossal nerve more critical to a successful outcome of surgery.^{8,107,109,112} Failure to include the branch to the genioglossus muscle (which protrudes the tongue) or failure to exclude the styloglossus and hyoglossus muscles (which retract the tongue) within the cuff electrode will result in failure to correct tongue collapse and obstructive apnea with implantation.^{8,109,111}

Statement 5:

When a cranial nerve is monitored, the final functional status of the nerve is best determined after all aspects of the procedure have been completed, including achievement of hemostasis, and it is recommended to be documented and incorporated into patient management and counseling. (Moderate-quality evidence)

Consensus was achieved for the ascertainment of the final functional status of the nerve (**Tables 2 and 4**) if it would affect patient management and counseling.

A risk of a false-negative test can exist, as represented by an intraoperative EMG or other aforementioned nerve evaluation test (**Table 1**) suggesting that nerve function is intact. Postoperatively, a nerve weakness can be observed if there is injury after the last stimulation. The surgeon would feel confident that the nerve's functional status was intact, but he or she may cause subsequent injury after that last evaluation through traction during examination of the wound or injury through maneuvers to achieve hemostasis, such as cautery, suture tying, or vessel ligation. If no further evaluation was done of the nerve, the surgeon could be unaware of the injury. There would be an unpleasant surprise to observe nerve weakness in the postoperative period.

Documentation and Reimbursement

Statement 6:

The operating surgeon or designee maintains a unique position in nerve monitoring and should document the monitoring methodology and nerve outcome status from head and neck surgical procedures. Optimization of intraoperative cranial nerve monitoring requires that the operating surgeon take control of its simultaneous active use and ongoing interpretation during the course of surgery. While intraoperative cranial nerve monitoring is integral to certain head and neck surgeries where cranial nerves are at risk, it remains a separate service requiring distinct expertise, equipment setup, interpretation of data, and documentation. (Moderate-quality evidence)

Consensus was achieved regarding the role and unique position of the operating surgeon in nerve monitoring (**Table 2**).

Guidelines published for the standardization and optimization of IONM have emphasized the importance of active surgeon or designee participation with the required knowledge of anesthesia concerns, standardized equipment setup, real-time interpretation of electrophysiologic data, and intraoperative troubleshooting algorithms.²⁰ This fundamental role of the operating surgeon in IONM allows for instantaneous interpretation of EMG signal by the person who (1) has the most in-depth knowledge of the anatomy and pathology of the surgical procedure and cranial nerves involved and (2) is performing the intraoperative maneuvers directly responsible for potential changes in IONM signal.¹¹³ Consequently, surgeon control of IONM removes the potential for delayed/failed communication of a potential detrimental change in IONM signal by a middle party sitting across the operating room or even outside of the hospital.¹¹⁴

Surgeon documentation of IONM should align with its recognition as a separate service during the course of surgery requiring separate expertise, setup, and interpretation. An option to achieve this goal could be the provision of a short additional procedure note separate from the operative note, with basic information including clinical data such as pre- and postoperative diagnosis, basic equipment setup, baseline electrophysiologic data, and a short description of the IONM procedure. Equipment costs for nerve monitoring are variable and hard to quantify. Fixed costs such as a nerve-monitoring ETs with surface electrodes exist and are around \$400 currently per ET per case. The cost of paralytic agents is variable and dependent on the strategy being used for any particular case as determined between the surgeon and anesthesiologist.

While criteria for commercial payers vary, Medicare rules currently allow billing for IONM from the following providers: (1) a physician who is not performing the surgery; (2) an audiologist trained and certified in electrophysiologic monitoring; (3) a physical therapist trained and certified in electrophysiologic monitoring; and (4) a neurophysiologist, neurologist, or physiatrist.¹¹⁵ This has historically omitted the operating surgeon from billing for IONM.

Conclusion

The AAO-HNS Cranial Nerve Monitoring Task Force has provided a state-of-the-art review in neural monitoring in otolaryngologic head, neck, and endocrine surgery. The evidence-based review was complemented by consensus statements utilizing a modified Delphi method to prioritize key statements to enhance patient outcomes in an array of surgical procedures in the head and neck. A precise definition of what actually constitutes IONM and its benefits have been provided.

Consensus was achieved in the domains of education needs and anesthesia considerations, as well as setup, troubleshooting, and documentation. Specific cranial nerve monitoring was evaluated and reached consensus level for all cranial nerves in statement 4 with the exception of the spinal accessory nerve. Although the spinal accessory nerve's value can never be marginalized, the task force did not feel that the existing literature was as robust to support a recommendation of routine monitoring of this nerve. In contrast, there is robust supporting literature cited and consensus for routine monitoring in certain procedures such as thyroid surgery to optimize patient outcomes. Future advancements and outcome reporting will undoubtedly be additive to the existing literature and consensus statements reflected in this report.

Acknowledgment

We acknowledge and thank Dr Jennifer Shin of the Harvard Medical School. Dr Shin is thanked for substantial contributions to the design, analysis, and interpretation of the work; revising the work critically for important intellectual content; approval of the version to be published; and agreeing to be accountable for the work.

We also thank Adrienne Deneal and Nui Dhepyasuwan of the AAO-HNS who greatly assisted us with the survey administration.

Author Contributions

Joseph Scharpf; contributed to conception and design, acquisition of data, and analysis of data; drafting and critical revision of article; final approval of the version to be published; agreement to be accountable for all aspects of the work; **Jeffrey C. Liu**; contributed to conception and design, acquisition of data, and analysis of data; drafting and critical revision of article; final approval of the version to be published; agreement to be accountable for all aspects of the work; **Catherine Sinclair**; contributed to conception and design, acquisition of data, and analysis of data; drafting and critical revision of article; final approval of the version to be published; agreement to be accountable for all aspects of the work; **Michael Singer**; contributed to conception and design, acquisition of data, and analysis of data; drafting and critical revision of article; final approval of the version to be published; agreement to be accountable for all aspects of the work; **Whitney Liddy**; contributed to conception and design, acquisition of data, and analysis of data; drafting and critical revision of article; final approval of the version to be published; agreement to be accountable for all aspects of the work; **Lisa Orloff**; contributed to conception and design, acquisition of data, and analysis of data; drafting and critical revision of article; final approval of the version to be published; agreement to be accountable for all aspects of the work; **David Steward**; contributed to conception and design, acquisition

of data, and analysis of data; drafting and critical revision of article; final approval of the version to be published; agreement to be accountable for all aspects of the work; **Juliana Bonilla Velez**; contributed to conception and design, acquisition of data, and analysis of data; drafting and critical revision of article; final approval of the version to be published; agreement to be accountable for all aspects of the work; **Gregory W. Randolph**; contributed to conception and design, acquisition of data, and analysis of data; drafting and critical revision of article; final approval of the version to be published; agreement to be accountable for all aspects of the work.

Disclosures

Competing interests: None.

Sponsorships: None.

Funding source: None.

References

- American Academy of Otolaryngology–Head and Neck Surgery. Position statement: intraoperative cranial nerve monitoring in otolaryngology–head and neck surgery. Published April 2018. <https://www.entnet.org/content/intraoperative-cranial-nerve-monitoring>
- American Academy of Otolaryngology–Head and Neck Surgery. Position statement: intraoperative nerve monitoring in otologic surgery. Published March 2017. <http://www.entnet.org/intraoperative-nerve-monitoring>
- Vivas EX, Carlson ML, Neff BA, et al. Congress of Neurological Surgeons systematic review and evidence-based guideline on intraoperative cranial nerve monitoring in vestibular schwannoma surgery. *Neurosurgery*. 2018;82(2):E44-E46.
- Alesina PF, Hinrichs J, Meier B, Cho EY, Bolli M, Walz MK. Intraoperative neuromonitoring for surgical training in thyroid surgery: its routine use allows a safe operation instead of lack of experienced mentoring. *World J Surg*. 2014;38:592-598.
- Al-Qurayshi Z, Kandil E, Randolph GW. Cost-effectiveness of intraoperative nerve monitoring in avoidance of bilateral recurrent laryngeal nerve injury in patients undergoing total thyroidectomy. *Br J Surg*. 2017;104(11):1523-1531. doi:10.1002/bjs.10582
- Savvas E, Hillmann S, Weiss D, Koopmann M, Rudack C, Alberty J. Association between facial nerve monitoring with postoperative facial paralysis in parotidectomy. *JAMA Otolaryngol Head Neck Surg*. 2016;142(9):828-833. doi:10.1001/jamaoto.2016.1192
- Lanišnik B, Žitnik L, Levart P, Žargi M, Rodi Z. The impact on postoperative shoulder function of intraoperative nerve monitoring of cranial nerve XI during modified radical neck dissection. *Eur Arch Otorhinolaryngol*. 2016;273(12):4445-4451. doi:10.1007/s00405-016-4096-0
- Heiser C, Hofauer B, Lozier L, Woodson BT, Stark T. Nerve monitoring-guided selective hypoglossal nerve stimulation in obstructive sleep apnea patients. *Laryngoscope*. 2016;126(12):2852-2858. doi:10.1002/lary.26026
- McKenna HP. The Delphi technique: a worthwhile approach for nursing? *J Adv Nurs*. 1994;19(6):1221-1225.
- Qaseem A, Kansagara D, Lin JS, Mustafa RA, Wilt TJ. The development of clinical guidelines and guidance statements by the Clinical Guidelines Committee of the American College of Physicians: update of methods. *Ann Intern Med*. 2019;170(12):863-870.
- Horne SK, Gal TJ, Brennan JA. Prevalence and patterns of intraoperative nerve monitoring for thyroidectomy. *Otolaryngol Head Neck Surg*. 2007;136(6):952-956.
- Sturgeon C, Sturgeon T, Angelos P. Neuromonitoring in thyroid surgery: attitudes, usage patterns, and predictors of use among endocrine surgeons. *World J Surg*. 2009;33(3):417-425.
- Singer MC, Rosenfeld RM, Sundaram K. Laryngeal nerve monitoring: current utilization among head and neck surgeons. *Otolaryngol Head Neck Surg*. 2012;146:895-899.
- Ho Y, Carr MM, Goldenberg D. Trends in intraoperative neural monitoring for thyroid and parathyroid surgery amongst otolaryngologists and general surgeons. *Eur Arch Otorhinolaryngol*. 2013;270:2525-2530
- Marti JL, Holm T, Randolph G. Universal use of intraoperative nerve monitoring by recently fellowship-trained thyroid surgeons is common, associated with higher surgical volume, and impacts intraoperative decision-making. *World J Surg*. 2016;40(2):337-343.
- Duclos A, Lifante JC, Ducarroz S, Soardo P, Colin C, Peix JL. Influence of intraoperative neuromonitoring on surgeons' technique during thyroidectomy. *World J Surg*. 2011;35(4):773-778.
- Lowry TR, Gal TJ, Brennan JA. Patterns of use of facial nerve monitoring during parotid gland surgery. *Otolaryngol Head Neck Surg*. 2005;133(3):313-318.
- Macias AA, Eappen S, Malikin I, et al. Successful intraoperative electrophysiologic monitoring of the recurrent laryngeal nerve, a multidisciplinary approach: the Massachusetts Eye and Ear Infirmary monitoring collaborative protocol with experience in over 3000 cases. *Head Neck*. 2016;38(10):1487-1494.
- Barczyński M, Randolph GW, Cernea CR, et al; International Neural Monitoring Study Group. External branch of the superior laryngeal nerve monitoring during thyroid and parathyroid surgery: International Neural Monitoring Study Group standards guideline statement. *Laryngoscope*. 2013;123(suppl 4):S1-S14.
- Randolph GW, Dralle H; International Neural Monitoring Study Group. Electrophysiologic recurrent laryngeal and nerve monitoring during thyroid and parathyroid surgery: International standards guidelines statement. *Laryngoscope*. 2011;121:S1-S16.
- Blitzer A, Crumley RL, Dailey SH, et al. Recommendations of the Neurolaryngology Study Group on laryngeal electromyography. *Otolaryngol Head Neck Surg*. 2009;140(6):782-793.
- Liddy W, Barber SR, Cinquepalmi M, et al. The electrophysiology of thyroid surgery: electrophysiologic and muscular responses with stimulation of the vagus nerve, recurrent laryngeal nerve, and external branch of the superior laryngeal nerve. *Laryngoscope*. 2017;127(3):764-771.
- Dionigi G, Snyder SK, Chiang FY, Liddy W, Kamani D, Kyriazidis N. Mechanism of injury. In: Randolph G, ed. *The Recurrent and Superior Laryngeal Nerves*. Springer International Publishing; 2016:223-237.
- Sunderland S. The anatomy and physiology of nerve injury. *Muscle Nerve*. 1990;13(9):771-784.
- Seddon HJ. A classification of nerve injuries. *Br Med J*. 1942;2(4260):237-239.

26. Savvas E, Hillmann S, Weiss D, Koopmann M, Rudack C, Alberty J. Association between facial nerve monitoring with postoperative facial paralysis in parotidectomy. *JAMA Otolaryngol Head Neck Surg.* 2016;142(9):828-833.
27. Lanisnik B, Zitnik L, Levart P, Zargi M, Rodi Z. The impact on postoperative shoulder function of intraoperative nerve monitoring of cranial nerve XI during modified radical neck dissection. *Eur Arch Otorhinolaryngol.* 2016;273(12):4445-4451.
28. Heiser C, Hofauer B, Lozier L, Woodson BT, Stark T. Nerve monitoring-guided selective hypoglossal nerve stimulation in obstructive sleep apnea patients. *Laryngoscope.* 2016;126(12):2852-2858.
29. Snyder SK, Hendricks JC. Intraoperative neurophysiology testing of the recurrent laryngeal nerve: plaudits and pitfalls. *Surgery.* 2005;138(6):1183-1191.
30. Beldi G, Kinsbergen T, Schlumpf R. Evaluation of intraoperative recurrent nerve monitoring in thyroid surgery. *World J Surg.* 2004;28(6):589-591.
31. Lu IC, Chu KS, Tsai CJ, et al. Optimal depth of NIM EMG endotracheal tube for intraoperative neuromonitoring of the recurrent laryngeal nerve during thyroidectomy. *World J Surg.* 2008;32(9):1935-1939.
32. Barber SR, Liddy W, Kyriazidis N, et al. Changes in electromyographic amplitudes but not latencies occur with endotracheal tube malpositioning during intraoperative monitoring for thyroid surgery: implications for guidelines. *Laryngoscope.* 2017;127(9):2182-2188.
33. Lorenz K, Schneider R, Machens A, Sekulla C, Randolph G, Dralle H. Loss of signal in IONM and staged thyroid surgery. In: Randolph G, ed. *The Recurrent and Superior Laryngeal Nerves.* Springer International Publishing; 2016:211-221.
34. Randolph GW, Kobler JB, Wilkins J. Recurrent laryngeal nerve identification and assessment during thyroid surgery: laryngeal palpation. *World J Surg.* 2004;28(8):755-760.
35. Ryzenman JM, Pensak ML, Tew JM Jr. Facial paralysis and surgical rehabilitation: a quality of life analysis in a cohort of 1,595 patients after acoustic neuroma surgery. *Otol Neurotol.* 2005;26:516-521.
36. Lydiatt DD. Medical malpractice and facial nerve paralysis. *Arch Otolaryngol Head Neck Surg.* 2003;129:50-53.
37. Nouraei SA, Ismail Y, Ferguson MS, et al. Analysis of complications following surgical treatment of benign parotid disease. *ANZ J Surg.* 2008;73:134-138.
38. Upton DC, McNamar JP, Connor NP, et al. Parotidectomy: ten-year review of 237 cases at a single institution. *Otolaryngol Head Neck Surg.* 2007;136:788-792.
39. Gaillard C, Perie S, Susini B, St Guily JL. Facial nerve dysfunction after parotidectomy: the role of local factors. *Laryngoscope.* 2005;115:287-291.
40. Guntinas-Lichius O, Klussmann JP, Wittekindt C, Stennert E. Parotidectomy for benign disease at a university teaching hospital: outcome of 963 operations. *Laryngoscope.* 2006;116:534-540.
41. Witt RL. Facial nerve function after partial superficial parotidectomy: an 11-year review (1987-1997). *Otolaryngol Head Neck Surg.* 1999;121:210-213.
42. Bron LP, O'Brien CJ. Facial nerve function after parotidectomy. *Arch Otolaryngol Head Neck Surg.* 1997;123:1091-1096.
43. Leverstein H, van der Wal JE, Tiwari RM, et al. Surgical management of 246 previously untreated pleomorphic adenomas of the parotid gland. *Br J Surg.* 1997;84:399-403.
44. Laccourreye H, Laccourreye O, Cauchois R, et al. Total conservative parotidectomy for primary benign pleomorphic adenoma of the parotid gland: a 25-year experience with 229 patients. *Laryngoscope.* 1994;104:1487-1494.
45. Sood AJ, Houlton JJ, Nguyen SA, Gillespie MB. Facial nerve monitoring during parotidectomy: a systematic review and meta-analysis. *Otolaryngol Head Neck Surg.* 2015;152(4):631-637.
46. Hopkins C, Khemani S, Terry RM, Golding-Wood D. How we do it; nerve monitoring in ENT surgery: current UK practice. *Clin Otolaryngol.* 2005;30:195-198.
47. O'Regan B, Bharadwaj G, Elders A. Techniques for dissection of the facial nerve in benign parotid surgery: a cross specialty survey of oral and maxillofacial and ear nose throat surgeons in the UK. *Br J Oral Maxillofac Surg.* 2008;46:564-566.
48. Theide O, Klusener T, Sielenkamper A, et al. Interference between muscle relaxation and facial nerve monitoring during parotidectomy. *Acta Otolaryngol.* 2006;126:422-428.
49. Silverstein H, Rosenberg S. Intraoperative facial nerve monitoring. *Otolaryngol Clin North Am.* 1991;24:709-725.
50. Anon JP, Lipman SP, Guelcher RT, et al. Monitoring the facial nerve during parotidectomy. *Arch Otolaryngol Head Neck Surg.* 1991;117:1420.
51. Anon JP, Lipman SP, Thumfart W, Sibly DA. Parotidectomy with the nerve integrity monitor II. *Eur Arch Otolaryngol.* 1994 Dec;S385-S386.
52. Olsen KD, Daube JR. Intraoperative monitoring of the facial nerve: an aid in the management of parotid gland recurrent pleomorphic adenoma. *Laryngoscope.* 1994;104:229-232.
53. Cillero Ruiz G, Espinosa Sanchez JM, Ruis de Erenchun Lasa I, et al. Intraoperative facial nerve monitoring: results. *Acta Otorrinolaringol Esp.* 1994;45:425-431.
54. Wolf SR, Schneider W, Suchy B, Eichhorn B. Intraoperative facial nerve monitoring in parotid surgery. *HNO.* 1995;43:294-298.
55. Terrell JE, Kileny PR, Yian C, et al. Clinical outcome of continuous facial nerve monitoring during primary parotidectomy. *Arch Otolaryngol Head Neck Surg.* 1997;157:1081-1087.
56. Witt RL. Facial nerve monitoring in parotid surgery: the standard of care? *Otolaryngol Head Neck Surg.* 1998;119:468-470.
57. Dulguerov P, Marchal F, Lehmann W. Postparotidectomy facial nerve paralysis: possible etiologic factors and results with routine facial monitoring. *Laryngoscope.* 1999;109:754-762.
58. Brennan J, Moore EJ, Shuler KJ. Prospective analysis of the efficacy of continuous intraoperative nerve monitoring during thyroidectomy, parathyroidectomy, and parotidectomy. *Otolaryngol Head Neck Surg.* 2001;124:537-543.
59. Lopez M, Quer M, Leon X, et al. Usefulness of facial nerve monitoring during parotidectomy. *Acta Otorrinolaringol Esp.* 2001;52:418-421.
60. Doikov IY, Konsulov SS, Dimov RS. Stimulation electromyography as a method of intraoperative localization and

- identification of the facial nerve during parotidectomy: review of 15 consecutive parotid surgeries. *Folia Med (Plovdiv)*. 2001; 43:23-26.
61. Makeieff M, Venail F, Cartier C, et al. Continuous facial nerve monitoring during pleomorphic adenoma recurrence surgery. *Laryngoscope*. 2005;115:1310-1314.
 62. Meier JD, Wenig BL, Manders EC, Nenonene EK. Continuous intraoperative facial nerve monitoring in predicting postoperative injury during parotidectomy. *Laryngoscope*. 2006;116: 1569-1572.
 63. Wang Z, Wu H, Huang Q, et al. Facial nerve monitoring in parotid gland surgery. *Lin Chuang Er Bi Yan Hou Ke Za Zhi*. 2006; 20:436-437.
 64. Eisele DW, Wang SJ, Orloff LA. Electrophysiologic facial nerve monitoring during parotidectomy. *Head Neck*. 2010; 32(3):399-405.
 65. Regloix SB, Grinholtz-Haddad J, Maurin O, Genestier L, Lisan Q, Pons Y. Facial nerve monitoring during parotidectomy: a two-center retrospective study. *Iran J Otorhinolaryngol*. 2016; 28(87):255-260.
 66. Savvas E, Hillmann S, Weiss D, Koopmann M, Rudack C, Alberty J. Association between facial nerve monitoring with postoperative facial paralysis in parotidectomy. *JAMA Otolaryngol Head Neck Surg*. 2016;142(9):828-833.
 67. Guntinas-Lichius O, Eisele DW. Facial nerve monitoring. *Adv Otorhinolaryngol*. 2016;78:46-52.
 68. Liu H, Wen W, Huang H, et al. Recurrent pleomorphic adenoma of the parotid gland: intraoperative facial nerve monitoring during parotidectomy. *Otolaryngol Head Neck Surg*. 2014; 151(1):87-91.
 69. Mamelie E, Bernat I, Pichon S, et al. Supramaximal stimulation during intraoperative facial nerve monitoring as a simple parameter to predict early functional outcome after parotidectomy. *Acta Otolaryngol*. 2013;133(7):779-784.
 70. Grosheva M, Klussmann JP, Grimminger C, et al. Electromyographic facial nerve monitoring during parotidectomy for benign lesions does not improve the outcome of postoperative facial nerve function: a prospective two-center trial. *Laryngoscope*. 2009;119(12):2299-2305.
 71. Kullmann M, Tatagiba M, Liebsch M, Feigl GC. Evaluation of the predictive value of intraoperative changes in motor-evoked potentials of caudal cranial nerves for the postoperative functional outcome. *World Neurosurg*. 2016;95:329-334.
 72. Fukuda M, Takao T, Hiraishi T, Yajima N, Saito A, Fujii Y. Novel devices for intraoperative monitoring of glossopharyngeal and vagus nerves during skull base surgery. *Surg Neurol Int*. 2013;4:97.
 73. Singh R, Husain AM. Neurophysiologic intraoperative monitoring of the glossopharyngeal and vagus nerves. *J Clin Neurophysiol*. 2011;28:582-586.
 74. Zhang W, Chen M, Zhang W, Chai Y. Use of electrophysiological monitoring in selective rhizotomy treating glossopharyngeal neuralgia. *J Craniomaxillofac Surg*. 2014;42:e182-e185.
 75. Jeannon JP, Orabi AA, Bruch GA, et al. Diagnosis of recurrent laryngeal nerve palsy after thyroidectomy: a systematic review. *Int J Clin Pract*. 2009;63:624-629.
 76. Francis DO, Pearce EC, Ni S, et al. Epidemiology of vocal fold paralyses after total thyroidectomy for well-differentiated thyroid cancer in a Medicare population. *Otolaryngol Head Neck Surg*. 2014;150:548-557.
 77. Jansson S, Tisell LE, Hagne I, et al. Partial superior laryngeal nerve (SLN) lesions before and after thyroid surgery. *World J Surg*. 1988;12:522-527.
 78. Chandrasekhar SS, Randolph GW, Seidman MD, et al. Clinical practice guideline: improving voice outcomes after thyroid surgery. *Otolaryngol Head Neck Surg*. 2013;148(6):S1-S37.
 79. Dixon H, Amin M, Roplekar R, et al. Assessment of voice in thyroidectomy patients—an audit cycle. *Otorhinolaryngologist*. 2013;6(2):122-124.
 80. Bergenfelz A, Jansson S, Kristoffersson A, et al. Complications to thyroid surgery: results as reported in a database from a multicenter audit comprising 3,660 patients. *Langenbecks Arch Surg*. 2008;393:667-673.
 81. Papaleontiou M, Hughes DT, Guo C, et al. Population-based assessment of complications following surgery for thyroid cancer. *JCEM*. 2017;102(7):2543-2551.
 82. Nouraei SAR, Allen J, Kaddour H, et al. Vocal palsy increases the risk of lower respiratory tract infection in low-risk, low-morbidity patients undergoing thyroidectomy for benign disease: a big data analysis. *Clin Otolaryngol*. 2017;42(6):1259-1266.
 83. Nouraei SAR, Virk JS, Middleton SE. A national analysis of trends, outcomes and volume-outcome relationships in thyroid surgery. *Clin Otolaryngol*. 2017;42(2):354-365.
 84. Ulmer C, Koch KP, Seimer A, et al. Real-time monitoring of the recurrent laryngeal nerve: an observational clinical trial. *Surgery*. 2008;143:359-365.
 85. Dionigi G, Chiang FU, Dralle H, et al. Safety of neural monitoring in thyroid surgery. *Internat J Surg*. 2013;11(S1):S120-S126.
 86. Bacuzzi A, Dralle H, Randolph GW. Safety of continuous intraoperative neuromonitoring (C-IONM) in thyroid surgery. *World J Surg*. 2016;40(3):768-769.
 87. Schneider R, Przybyl J, Pliquett U, et al. A new vagal anchor electrode for real-time monitoring of the recurrent laryngeal nerve. *Am J Surg*. 2010;199:507-514.
 88. Randolph GW, Kamani D. Intraoperative electrophysiologic monitoring of the recurrent laryngeal nerve during thyroid and parathyroid surgery: experience with 1,381 nerves at risk. *Laryngoscope*. 2017;127:280-286.
 89. Fundakowski CE, Hales NW, Agrawal N, et al. Surgical management of the recurrent laryngeal nerve in thyroidectomy: American Head and Neck Society consensus statement. *Head Neck*. 2018;40(4):663-675.
 90. Phelan E, Schneider R, Lorenz K, et al. Continuous vagal IONM prevents recurrent laryngeal nerve paralysis by revealing initial EMG changes of impending neuropraxic injury: a prospective, multicenter study. *Laryngoscope*. 2014;124:1498-1505.
 91. Schneider R, Randolph GW, Dionigi G, et al. International neural monitoring study group guideline 2018 part I: staging bilateral thyroid surgery with monitoring loss of signal. *Laryngoscope*. 2018;128(suppl 3):S1-S17.
 92. Wu CW, Dionigi G, Barczynski M, et al. International neural monitoring study group guideline 2018: part II. Optimal

- recurrent laryngeal nerve management for invasive thyroid cancer-incorporation of surgical, laryngeal, and neural electrophysiologic data. *Laryngoscope*. 2018;128(suppl 3):S18-S27.
93. Shindo ML, Caruana SM, Kandil E, et al. Management of invasive well-differentiated thyroid cancer: an American Head and Neck Society consensus statement. AHNS consensus statement. *Head Neck*. 2014;36(10):1379-1390.
 94. Scharpf J, Tuttle M, Wong R, et al. Comprehensive management of recurrent thyroid cancer: an American Head and Neck Society consensus statement. AHNS consensus statement. *Head Neck*. 2016;38(12):1862-1869.
 95. Agrawal N, Evasovich MR, Kandil E, et al. Indications and extent of central neck dissection for papillary thyroid cancer: an American Head and Neck Society consensus statement. *Head Neck*. 2017;39(7):1269-1279.
 96. Sinclair CF, Bumpous JM, Haugen B, et al. Laryngeal examination in thyroid and parathyroid surgery: an American Head and Neck Society consensus statement. AHNS consensus statement. *Head Neck*. 2016;38(6):811-819.
 97. Haugen BR, Alexander EK, Bible KC, et al. 2015 American Thyroid Association management guidelines for adult patients with thyroid nodules and differentiated thyroid cancer: the American Thyroid Association Guidelines Task Force on Thyroid Nodules and Differentiated Thyroid Cancer. *Thyroid*. 2016; 26(10):1-133.
 98. Gavid M, Mayaud A, Timochenko A, Asanau A, Prades JM. Topographical and functional anatomy of trapezius muscle innervation by spinal accessory nerve and C2 to C4 nerves of cervical plexus. *Surg Radiol Anat*. 2016;38:917-922.
 99. Lanisnik B, Zitnik L, Levart P, Zargi M, Rodi Z. The impact on postoperative shoulder function of intraoperative nerve monitoring of cranial nerve XI during modified radical neck dissection. *Eur Arch Otorhinolaryngol*. 2016;273:4445-4451.
 100. Brinzeu A, Sindou M. Functional anatomy of the accessory nerve studied through intraoperative electrophysiological mapping. *J Neurosurg*. 2017;126:913-921.
 101. Lee CH, Huang NC, Chen HC, Chen MK. Minimizing shoulder syndrome with intra-operative spinal accessory nerve monitoring for neck dissection. *Acta Otorhinolaryngol Ital*. 2013;33: 93-96.
 102. Midwinter K, Willatt D. Accessory nerve monitoring and stimulation during neck surgery. *J Laryngol Otol*. 2002;116:272-274.
 103. Witt RL, Rejto L. Spinal accessory nerve monitoring in selective and modified neck dissection. *Laryngoscope*. 2007;117: 776-780.
 104. Birinci Y, Genc A, Ecevit MC, et al. Spinal accessory nerve monitoring and clinical outcome results of nerve-sparing neck dissections. *Otolaryngol Head Neck Surg*. 2014;151:253-259.
 105. McGarvey AC, Hoffman GR, Osmotherly PG, Chiarelli PE. Intra-operative monitoring of the spinal accessory nerve: a systematic review. *J Laryngol Otol*. 2014;128:746-751.
 106. Heiser C, Knopf A, Hofauer B. Surgical anatomy of the hypoglossal nerve: a new classification system for selective upper airway stimulation. *Head Neck*. 2017;39:2371-2380.
 107. Steffen A, Kilic A, Konig IR, Suurna MV, Hofauer B, Heiser C. Tongue motion variability with changes of upper airway stimulation electrode configuration and effects on treatment outcomes. *Laryngoscope*. 2018;128:1970-1976.
 108. Woodson BT, Strohl KP, Soose RJ, et al. Upper airway stimulation for obstructive sleep apnea: 5-year outcomes. *Otolaryngol Head Neck Surg*. 2018;159:194-202.
 109. Wainwright SD, Wainwright LK. On the uptake and incorporation of thymidine by cultured chick pineal glands. *J Pineal Res*. 1989;6:169-178.
 110. Woodson BT, Gillespie MB, Soose RJ, et al. Randomized controlled withdrawal study of upper airway stimulation on OSA: short- and long-term effect. *Otolaryngol Head Neck Surg*. 2014;151:880-887.
 111. Strollo PJ Jr, Soose RJ, Maurer JT, et al. Upper-airway stimulation for obstructive sleep apnea. *N Engl J Med*. 2014;370: 139-149.
 112. Heiser C, Thaler E, Boon M, Soose RJ, Woodson BT. Updates of operative techniques for upper airway stimulation. *Laryngoscope*. 2016;126(suppl 7):S12-S16.
 113. Gidley P, Maw J, Gantz B, et al. Contemporary opinions on intraoperative facial nerve monitoring. *OTO Open*. 2018;2(3): 2473974X18791803.
 114. Maw J, Gidley PW. Brief commentary on Gidley et al: "Contemporary opinions on intraoperative facial nerve monitoring." *Otolaryngol Head Neck Surg*. 2018;159(4):601-602.
 115. Medtronic. Intraoperative nerve monitoring reimbursement coding guide. Published 2016. http://www.medtronic.com/content/dam/medtronic-com/products/ear-nose-throat/coding-and-reimbursement/UC201404769bEN_IOMN_CodingGuide.pdf