

Henry Ford Health

Henry Ford Health Scholarly Commons

Cardiology Articles

Cardiology/Cardiovascular Research

5-19-2021

Laser for balloon uncrossable and undilatable chronic total occlusion interventions

Judit Karacsonyi

Khaldoon Alaswad

Henry Ford Health, kalaswa1@hfhs.org

James W. Choi

Evangelia Vemmou

Ilias Nikolakopoulos

See next page for additional authors

Follow this and additional works at: https://scholarlycommons.henryford.com/cardiology_articles

Recommended Citation

Karacsonyi J, Alaswad K, Choi JW, Vemmou E, Nikolakopoulos I, Poommipanit P, Rafeh NA, ElGuindy A, Ungi I, Egred M, and Brilakis ES. Laser for balloon uncrossable and undilatable chronic total occlusion interventions. *Int J Cardiol* 2021.

This Article is brought to you for free and open access by the Cardiology/Cardiovascular Research at Henry Ford Health Scholarly Commons. It has been accepted for inclusion in Cardiology Articles by an authorized administrator of Henry Ford Health Scholarly Commons.


Authors

Judit Karacsonyi, Khaldoon Alaswad, James W. Choi, Evangelia Vemmou, Ilias Nikolakopoulos, Paul Poommipanit, Nidal Abi Rafeh, Ahmed ElGuindy, Imre Ungi, Mohaned Egred, and Emmanouil S. Brilakis



Contents lists available at ScienceDirect

International Journal of Cardiology

journal homepage: www.elsevier.com/locate/ijcard

Laser for balloon uncrossable and undilatable chronic total occlusion interventions

Judit Karacsonyi^{a,1}, Khaldoun Alaswad^{b,1}, James W. Choi^{c,1}, Evangelia Vemou^{a,1}, Ilias Nikolakopoulos^{a,1}, Paul Poommipanit^{d,1}, Nidal Abi Rafah^{e,1}, Ahmed ElGuindy^{f,1}, Imre Ungi^{g,1}, Mohaned Egreg^{h,1}, Emmanouil S. Brilakis^{a,*,1}

^a Minneapolis Heart Institute and Minneapolis Heart Institute Foundation, Abbott Northwestern Hospital, Minneapolis, MN, USA

^b Henry Ford Hospital, Detroit, MI, USA

^c Baylor Heart and Vascular Hospital, Dallas, TX, USA

^d University Hospitals, Case Western Reserve University, Cleveland, OH, USA

^e North Oaks Health System, Hammond, LA, USA

^f Department of Cardiology, Aswan Heart Centre, Magdi Yacoub Foundation, Aswan, Egypt

^g Division of Invasive Cardiology, Second Department of Internal Medicine and Cardiology Center, University of Szeged, Szeged, Hungary

^h The Newcastle upon Tyne Hospitals NHS Foundation Trust, Newcastle upon Tyne, UK

ARTICLE INFO

Article history:

Received 11 March 2021

Received in revised form 27 April 2021

Accepted 10 May 2021

Available online xxxxx

Keywords:

Percutaneous coronary intervention

Chronic total occlusion

Laser

ABSTRACT

Background: There is limited information on use of laser in complex percutaneous coronary interventions (PCI). We examined the impact of laser on the outcomes of balloon uncrossable and balloon undilatable chronic total occlusion (CTO) PCI.

Methods: We reviewed baseline clinical and angiographic characteristics and procedural outcomes of 4845 CTO PCIs performed between 2012 and 2020 at 32 centers.

Results: Of the 4845 CTO lesions, 752 (15.5%) were balloon uncrossable (523 cases) or balloon undilatable (356 cases) and were included in this analysis. Mean patient age was 66.9 ± 10 years and 83% were men. Laser was used in 20.3% of the lesions. Compared with cases in which laser was not used, laser was more commonly used in longer length occlusions (33 [21, 50] vs. 25 [15, 40] mm, $p = 0.0004$) and in-stent restenotic lesions (41% vs. 20%, $p < 0.0001$). Laser use was associated with higher technical (91.5% vs. 83.1%, $p = 0.010$) and procedural (88.9% vs. 81.6%, $p = 0.033$) success rates and similar incidence of major adverse cardiac events (3.92% vs. 3.51%, $p = 0.805$). Laser use was associated with longer procedural (169 [109, 231] vs. 130 [87, 199], $p < 0.0001$) and fluoroscopy time (64 [40, 94] vs. 50 [31, 81], $p = 0.003$).

Conclusions: In a contemporary, multicenter registry balloon uncrossable and balloon undilatable lesions represented 15.5% of all CTO PCIs. Laser was used in approximately one-fifth of these cases and was associated with high technical and procedural success and similar major complication rates.

© 2021 Elsevier B.V. All rights reserved.

1. Introduction

Laser is an important tool in complex percutaneous coronary intervention (PCI), even though there is limited information on real-world use and outcomes. [1–3] We examined the impact of laser on the outcomes of PCI of balloon uncrossable and balloon undilatable chronic total occlusions (CTO) (Supplementary Fig. 1). Balloon uncrossable

lesions are defined as lesions that cannot be crossed with a balloon after successful guidewire crossing. Balloon uncrossable lesions are relatively common, representing 6.4% of the CTO lesions in a single center study (laser was used in 18% of the lesions) [4] and 9% in a multicenter CTO registry (laser was used in 8.7% of the lesions). [5] Balloon undilatable lesions are lesions that do not expand despite high-pressure balloon inflations; approximately 12% of the CTO lesions were balloon undilatable in the same multicenter CTO registry. [6] Laser can provide effective treatment for both lesion types. No guidewire exchange is necessary when using laser for balloon uncrossable lesions. Laser can either cross such lesions or modify them enough to facilitate subsequent balloon advancement. [7] Laser can also help expand balloon undilatable lesions, sometimes with simultaneous contrast administration when treating in-stent undilatable lesions. [1,8–10]

* Corresponding author at: Minneapolis Heart Institute, 920 E 28th Street #300, Minneapolis, MN 55407, USA.

E-mail address: esbrilakis@gmail.com (E.S. Brilakis).

¹ This author takes responsibility for all aspects of the reliability and freedom from bias of the data presented and their discussed interpretation.

2. Materials and methods

We analyzed the baseline clinical and angiographic characteristics and procedural outcomes of 4845 CTO PCIs performed between 2012 and 2020 enrolled at 32 centers. Data collection was performed both prospectively and retrospectively and was recorded in a dedicated on-line database (PROGRESS CTO: Prospective Global Registry for the Study of Chronic Total Occlusion Intervention; [Clinicaltrials.gov](https://clinicaltrials.gov/ct2/show/study/NCT02061436) identifier: NCT02061436). Study data were collected and managed using REDCap (Research Electronic Data Capture) electronic data capture tools hosted at Minneapolis Heart Institute Foundation. [11,12] The study was approved by the institutional review board of each site.

Coronary CTOs were defined as coronary lesions with Thrombolysis in Myocardial Infarction (TIMI) grade 0 flow of at least 3-month duration. Estimation of the duration of occlusion was clinical, based on the first onset of angina, prior history of myocardial infarction (MI) in the target vessel territory, or comparison with a prior angiogram. Calcification was assessed by angiography as mild (spots), moderate (involving $\leq 50\%$ of the reference lesion diameter), or severe (involving $> 50\%$ of the reference lesion diameter). Moderate proximal vessel tortuosity was defined as the presence of at least 2 bends $> 70^\circ$ or 1 bend $> 90^\circ$ and severe tortuosity as 2 bends $> 90^\circ$ or 1 bend $> 120^\circ$ in the CTO vessel. A retrograde procedure was an attempt to cross the lesion through a collateral vessel or bypass graft supplying the target vessel distal to the lesion; otherwise, the intervention was classified as an antegrade-only procedure. Antegrade dissection/re-entry was defined as antegrade PCI during which a guidewire was intentionally introduced into the subintimal space proximal to the lesion, or re-entry into the distal true lumen was attempted after intentional or inadvertent subintimal guidewire crossing. Technical success was defined as successful CTO revascularization with achievement of $< 30\%$ residual diameter stenosis within the treated segment and restoration of TIMI grade 3 antegrade flow. Procedural success was defined as the achievement of technical success without any in-hospital complications. In-hospital major adverse cardiac event (MACE) included any of the following adverse events prior to hospital discharge: death, MI, recurrent symptoms requiring urgent repeat target-vessel revascularization (TVR) with PCI or coronary artery bypass graft (CABG) surgery, tamponade requiring either pericardiocentesis or surgery, and stroke. MI was defined using the Third Universal Definition of Myocardial Infarction (type 4a MI). [13] The Japanese CTO (J-CTO) score was calculated as described by Morino et al., [14] the PROGRESS-CTO score as described by Christopoulos et al. [15] The decision to use laser atherectomy and the associated techniques was at the operators' discretion.

Categorical variables were expressed as percentages and were compared using Pearson's Chi-square test or Fisher's exact test. Continuous variables were presented as mean \pm standard deviation or median (interquartile range [IQR]) unless otherwise specified and were compared using the student's *t*-test and one-way analysis of variance (ANOVA) for normally distributed variables and the Wilcoxon rank-sum test, or the Kruskal-Wallis test for non-parametric continuous variables, as appropriate. Logistic regression analysis was performed to identify clinical and angiographic parameters associated with technical success. Variables with $p < 0.10$ on univariate analysis (presence of proximal cap ambiguity, in-stent restenosis, prior failed CTO PCI, presence of interventional collaterals, use of laser) were included in a multivariate model. All statistical analyses were performed using JMP, version 13.0 (SAS Institute). A *P*-value of < 0.05 was considered statistically significant.

3. Results

Of the 4845 CTOs, 752 (15.5%) were balloon uncrossable (523 cases) or balloon undilatable (356 cases) and were included in the present analysis (127 cases were both balloon uncrossable and undilatable). A gradual increase in laser use was observed from 2012 to 2019 ($p < 0.0001$, Fig. 1; a decrease in 2020 was likely related to the COVID-19 outbreak).

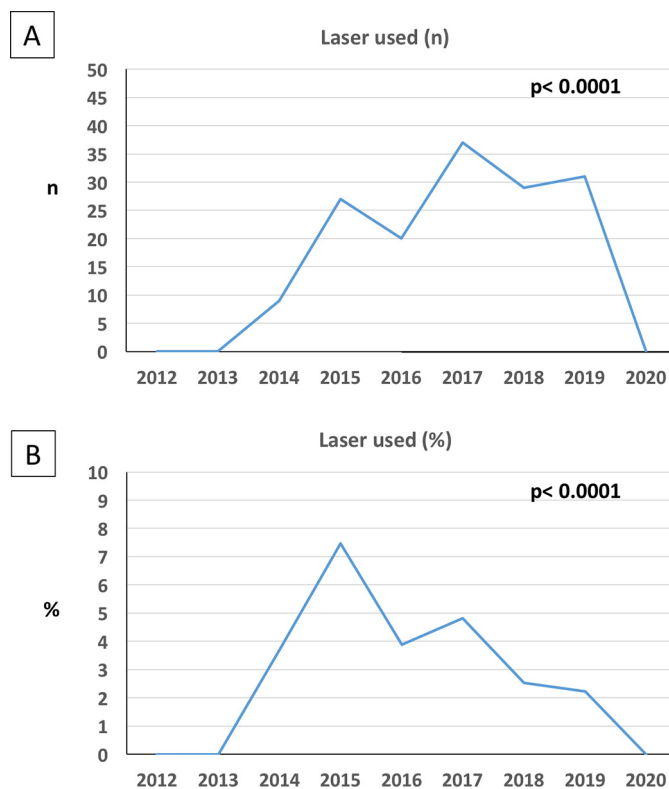


Fig. 1. A. Temporal trends in number of laser cases in balloon uncrossable and undilatable chronic total occlusions (CTOs). B. Temporal trends in proportion of laser cases in balloon uncrossable and undilatable chronic total occlusions (CTOs).

Laser was used in 153 CTO lesions (20.3%). The baseline clinical characteristics of the study patients are summarized in Table 1. Mean patient age was 66.9 ± 10 years, 83% were men, 51% had diabetes mellitus and 42% had prior coronary artery bypass graft surgery. Patients in whom laser was used were more likely to have diabetes than the patients who did not undergo laser treatment (61% vs. 48%, $p = 0.005$). There was no other difference in baseline clinical characteristics between the two groups.

The angiographic characteristics and procedural strategies are summarized in Table 1. The most common target vessel was the right coronary artery (55%) followed by the left anterior descending (22%) and left circumflex coronary artery (21%). The study lesions were complex: moderate or severe calcification was present in 73%, mean Japan CTO score was 2.79 ± 1.19 , and mean PROGRESS CTO score was 1.36 ± 1.02 . Compared with cases in which laser was not used, laser was more commonly used in lesions with longer occlusion length (33 [21, 50] vs. 25 [15, 40] mm, $p = 0.0004$) and in-stent occlusions (41% vs. 20%, $p < 0.0001$).

Procedural characteristics and outcomes are listed in Table 2. The overall technical and procedural success were 84.8% and 83.1%, respectively. The incidence of in-hospital MACE was 3.59%. Laser use was associated with higher technical (91.5% vs. 83.1%, $p = 0.010$) and procedural (88.9% vs. 81.6%, $p = 0.033$) success rates (Fig. 2A) and similar incidence of MACE (3.92% vs. 3.51%, $p = 0.805$, Fig. 2B). On multivariable analysis laser was no longer associated with technical success (Supplementary Fig. 2).

There was no difference in the components of MACE and other complications between the two groups (Table 2). Laser use was associated with longer procedural (169 [109, 231] vs. 130 [87, 199] min, $p < 0.0001$) and fluoroscopy (64 [40, 94] vs. 50 [31, 81] min, $p = 0.003$) time but similar contrast volume (200 [141, 295] vs. 201 [150, 280] ml, $p = 0.567$). Other techniques used in balloon uncrossable and undilatable

Table 1
Baseline clinical, angiographic and technical characteristics of study patients and procedures.

Variable	Laser used	Laser not used	P value
	(n = 153)	(n = 599)	
Age (years) ^a	65.7 ± 9	67.2 ± 10	0.077
Men	84%	82%	0.524
BMI (kg/m ²) ^a	30.6 ± 7	29.8 ± 6	0.167
Diabetes Mellitus	61%	48%	0.005
Hypertension	92%	93%	0.569
Dyslipidemia	96%	93%	0.223
Smoking (current)	19%	22%	0.457
LVEF (%) ^a	49 ± 14	49 ± 13	0.692
Family History of CAD	36%	38%	0.722
Congestive Heart Failure	31%	33%	0.618
Prior Myocardial Infarction	54%	46%	0.130
Prior CABG	44%	41%	0.616
Prior CVD	12%	11%	0.861
Prior PVD	18%	16%	0.457
Baseline creatinine (mg/dL) ^b	1.0 (0.9, 1.3)	1.0 (0.9, 1.2)	0.349
Angiographic and technical characteristics			
CTO Target Vessel			
▪ RCA	56%	54%	0.968
▪ LAD	21%	22%	
▪ LCX	21%	21%	
▪ LM	1%	0.5%	
▪ Other	1.4%	2.1%	
Successful Crossing Strategy			
▪ Antegrade wiring	63%	61%	0.329
▪ Retrograde	20%	18%	
▪ ADR	11%	10%	
▪ None	6%	11%	
First Crossing Strategy			
▪ Antegrade wiring	87%	87%	0.993
▪ Retrograde	11%	10%	
▪ ADR	3%	3%	
J-CTO score ^a	2.89 ± 1.10	2.77 ± 1.21	0.251
Progress CTO score ^a	1.27 ± 1.02	1.38 ± 1.02	0.238
Calcification (moderate/severe)	71%	74%	0.498
Proximal vessel tortuosity (moderate/severe)	35%	40%	0.193
Proximal cap ambiguity	26%	35%	0.052
In-stent restenosis	41%	20%	<0.001
Prior failure to open CTO	28%	24%	0.252
Side branch at the proximal cap	50%	55%	0.221
Blunt/no stump, %	49%	55%	0.178
Vessel diameter (mm) ^b	3.0 (2.5, 3.0)	3.0 (2.5, 3.0)	0.169
Occlusion length (mm) ^b	33 (21, 50)	25 (15, 40)	0.0004
Number of stents used ^a	2.52 ± 1.10	2.42 ± 1.13	0.344

(BMI: Body Mass Index, LVEF: Left Ventricular Ejection Fraction; CAD: Coronary Artery Disease; CABG: Coronary Artery Bypass Grafting; CVD: Cerebrovascular Disease; PVD: Peripheral Vascular Disease; CTO: chronic total occlusion; RCA: right coronary artery, LAD: left descending coronary artery, LCX: left circumflex coronary artery; LM: left main coronary artery; ADR: antegrade dissection and re-entry; J-CTO: Japan CTO score; PROG-RESS-CTO score: Prospective Global Registry for the Study of Chronic Total Occlusion Intervention score)

^a Mean ± standard deviation.

^b Median (interquartile ranges).

CTO lesions are summarized in Supplementary Table 3: rotational atherectomy and grenadoplasty were the most commonly used techniques.

4. Discussion

The main finding of our study is that use of laser in balloon uncrossable and balloon undilatable CTO lesions was associated with high technical and procedural success and similar major complication rates.

Laser was first approved by the U.S. Food and Drug Administration for PCI in 1992 [16] The term laser is obtained from the acronym "Light Amplification by Stimulated Emission of Radiation" [7] Laser ablates tissue in three ways: photochemical (fracture of molecular

bonds), photothermal (tissue vaporization) and photokinetic (quick expansion and collapse of the vapor bubbles breaks down the plaque) [7]. Use of laser can facilitate complex PCI. [2,7]

Potential treatment strategies for balloon uncrossable lesions are use of low profile semi-compliant balloons with lubricous coating, microcatheters, stronger guide catheter support, for example using guide catheter extensions or anchoring techniques. Second line treatments include laser atherectomy, balloon assisted microdissection, and rotational and orbital atherectomy. The third line strategy is subintimal dissection and re-entry. Strategies for treating balloon undilatable lesions include non-compliant balloons, ultrahigh pressure non-compliant balloons, cutting/scoring balloons, laser, rotational and orbital atherectomy and intravascular lithotripsy. [9] Rotational atherectomy can facilitate treatment of both balloon uncrossable and balloon undilatable lesions. Aggressive burr advancement should be avoided in balloon uncrossable lesions to reduce the risk of entrapment as only the distal part of the burr is coated with diamond crystals. [17] Orbital atherectomy can also treat balloon undilatable and balloon uncrossable lesions, but requires slow crown advancement in contrast to the rapid "pecking" motion recommended for rotational atherectomy. In a recently published meta-analysis, except for lower fluoroscopy time with orbital atherectomy, no significant differences were observed between orbital and rotational atherectomy in relation to procedural, periprocedural, and thirty day outcomes among patients with calcified coronary lesions. [18] Laser is an excellent treatment option for balloon uncrossable lesions as it can be advanced over any standard 0.014 in. guidewire, in contrast to orbital and rotational atherectomy that require specialized guidewires. Multiple passes may be required to cross the lesion. [19] Laser with simultaneous contrast injection can be effective in treating in-stent balloon undilatable lesions [2,8] and can sometimes be combined with brachytherapy to reduce the risk of recurrent restenosis. [20]

Ferdandez et al. examined laser use in 58 patients, 16 of whom had balloon uncrossable CTOs (in two of these laser was combined with rotational atherectomy) with procedural success of 87.5% and 2% incidence of complications. In the same study laser alone was used in two balloon undilatable CTO cases with 100% success rate and one case of Ellis class I perforation. [21] Another study examining laser use in veterans undergoing PCI reported balloon uncrossable lesions to be the most common indication for laser (43.8%) with 87.8% technical and 83.7% procedural success. The second most common indication was balloon undilatable lesions (40.8%) with 94.3% and 93.8%, technical and procedural success rates, respectively. [2] The LEONARDO study (Early outcome of high energy Laser (Excimer) facilitated coronary angioplasty ON hARD and complex calcified and balloOn-resistant coronary lesions) enrolled 80 patients with 100 lesions and reported 93.7% success rate (30 of 32) without any complications. [22] Finally, the ELLEMENT (Excimer Laser LEsion modification to expand non-dilatable stents) study examined laser at high energy with simultaneous contrast injection within under-expanded stents with 96.4% success and 7.1% incidence of periprocedural myocardial infarction. [23] Laser can be used over any standard 0.014 in. guidewire, which makes it easier to apply than other ablative devices that require use of a dedicated guidewire, such as rotational and orbital atherectomy.

5. Study limitations

Limitations of our study are the observational design, the lack of clinical event adjudication, and performance of all procedures at high-volume, experienced PCI centers, limiting the generalizability of our findings to centers with limited CTO PCI experience.

6. Conclusion

Laser can facilitate treatment of balloon uncrossable and balloon undilatable CTOs with high technical and procedural success and low complication rates. Given the observational design of our study, the

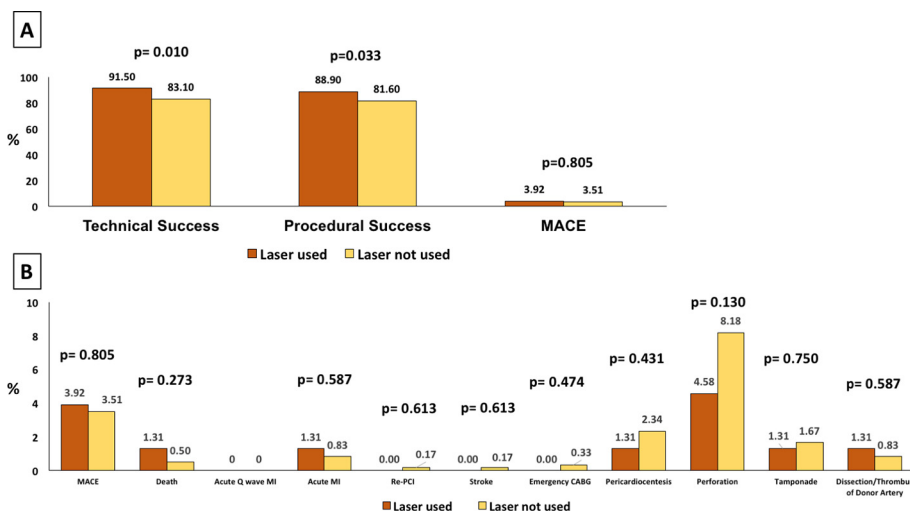


Fig. 2. A. Technical, procedural success and major cardiac events (MACE) among balloon uncrossable and undilatable procedures, classified according to laser use. B. Procedural complications among study procedures, classified according to laser use in balloon uncrossable and undilatable procedures. (MACE: major cardiac adverse events)

Table 2
Procedural characteristics and outcomes of study patients.

Variable	Laser used	Laser not used	P value
	(n = 153)	(n = 599)	
Technical Success	91.5%	83.1%	0.010
Procedural Success	88.9%	81.6%	0.033
Procedural time (min) ^b	169 (109, 231)	130 (87, 199)	<0.001
Fluoroscopy time (min) ^b	64 (40, 94)	50 (31, 81)	0.003
Air kerma radiation dose (Gray) ^b	2.50 (1.76, 4.20)	2.45 (1.37, 3.98)	0.455
Contrast volume ^b	200 (141, 295)	201 (150, 280)	0.567
MACE	3.92%	3.51%	0.805
Death	1.31%	0.50%	0.273
Acute Q wave MI	0%	0%	-
Acute MI	1.31%	0.83%	0.587
Re-PCI	0.00%	0.17%	0.613
Stroke	0.00%	0.17%	0.613
Emergency CABG	0.00%	0.33%	0.474
Pericardiocentesis	1.31%	2.34%	0.431
Perforation	4.58%	8.18%	0.130
Tamponade	1.31%	1.67%	0.750
Dissection/Thrombus of Donor Artery	1.31%	0.83%	0.587

(MACE: major cardiac adverse events; MI: myocardial infarction; PCI: percutaneous coronary intervention; CABG: Coronary Artery Bypass Grafting)

^b Median (interquartile ranges).

results should be considered hypothesis-generating, highlighting the need for further research.

Funding

Abbott Northwestern Hospital Foundation Innovation Grant and Gift from Joseph F. and Mary M. Fleischhacker Foundation.

Author statement

Judit Karacsonyi, MD, PhD: Conception and design, analysis and interpretation of data, drafting of the manuscript, critical revision of the manuscript for important intellectual content, final approval of the manuscript.

Khaldoon Alaswad, MD: Conception and design, drafting of the manuscript, critical revision of the manuscript for important intellectual content, final approval of the manuscript.

James W. Choi, MD: Conception and design, drafting of the manuscript, critical revision of the manuscript for important intellectual content, final approval of the manuscript.

Evangelia Vemmu, MD: Conception and design, analysis and interpretation of data, drafting of the manuscript, critical revision of the manuscript for important intellectual content, final approval of the manuscript.

Ilias D. Nikolakopoulos, MD: Conception and design, analysis and interpretation of data, drafting of the manuscript, critical revision of the manuscript for important intellectual content, final approval of the manuscript.

Paul Poommipanit, MD: Conception and design, drafting of the manuscript, critical revision of the manuscript for important intellectual content, final approval of the manuscript.

Nidal Abi Rafeh: Conception and design, drafting of the manuscript, critical revision of the manuscript for important intellectual content, final approval of the manuscript.

Ahmed ElGuindy: Conception and design, drafting of the manuscript, critical revision of the manuscript for important intellectual content, final approval of the manuscript.

Imre Ungi, MD, PhD: Conception and design, drafting of the manuscript, critical revision of the manuscript for important intellectual content, final approval of the manuscript.

Emmanouil S. Brilakis, MD, PhD: Conception and design, acquisition of data, analysis and interpretation of data, drafting of the manuscript, critical revision of the manuscript for important intellectual content, final approval of the manuscript.

Declaration of Competing Interest

Dr. Alaswad: consultant and speaker for Boston Scientific, Abbott Cardiovascular, Teleflex, and CSI.

Dr. Abi Rafeh: Proctor and consultant for BSC, Abbott and Shockwave Medical.

Dr. ElGuindy: received consultancy and proctorship fees from Medtronic, Asahi Intecc, Boston Scientific, and Terumo.

Dr. Egred: proctor for ELCA and reports honoraria and speaker fees from Philips, Abbott Vascular, Boston Scientific, Vascular Perspectives, Biosensors, Biotronik, and AstraZeneca.

Dr. Brilakis: consulting/speaker honoraria from Abbott Vascular, American Heart Association (associate editor *Circulation*), Amgen, Asahi Intecc, Biotronik, Boston Scientific, Cardiovascular Innovations Foundation (Board of Directors), ControlRad, CSI, Elsevier, GE Healthcare, InfraRedx, Medtronic, Siemens, and Teleflex; research support from Regeneron; owner, Hippocrates LLC; shareholder: MHI Ventures, Clearly Health.

All other authors: nothing to disclose.

Acknowledgments

Study data were collected and managed using Research Electronic Data Capture (REDCap) electronic data capture tools hosted at the Minneapolis Heart Institute Foundation (MHIF), Minneapolis, Minnesota. REDCap is a secure, web-based application designed to support data capture for research studies, providing: (1) an intuitive interface for validated data entry; (2) audit trails for tracking data manipulation and export procedures; (3) automated export procedures for seamless data downloads to common statistical packages; and (4) procedures for importing data from external sources.

Appendix A. Supplementary data

Supplementary data to this article can be found online at <https://doi.org/10.1016/j.ijcard.2021.05.015>.

References

- [1] C. McQuillan, M. Farag, M. Egred, Excimer laser coronary angioplasty: clinical applications and procedural outcome, in a large-volume tertiary Centre, *Cardiology*. 146 (2) (2021) 137–143.
- [2] J. Karacsonyi, E.J. Armstrong, H.T.D. Truong, et al., Contemporary use of laser during percutaneous coronary interventions: insights from the laser veterans affairs (LAVA) multicenter registry, *J. Invasive Cardiol.* 30 (6) (2018) 195–201.
- [3] M.B. Protty, H.I. Hussain, S. Gallagher, S. Al-Raisi, O. Aldalati, V. Farooq, A.S.P. Sharp, M. Egred, P. O'Kane, P. Ludman, R.A. Anderson, M.A. Mamas, T. Kinnaird, Excimer laser coronary atherectomy during complex PCI: An analysis of 1,471 laser cases from the British Cardiovascular Intervention Society database. *Catheter Cardiovasc Interv.* 97 (5) (2021) E653–E660, <https://doi.org/10.1002/ccd.29251> Epub 2020 Sep 18. PMID: 32946132.
- [4] S.M. Patel, N.R. Pokala, R.V. Menon, et al., Prevalence and treatment of “balloon-uncrossable” coronary chronic total occlusions, *J. Invasive Cardiol.* 27 (2) (2015) 78–84.
- [5] J. Karacsonyi, D. Karpaliotis, K. Alaswad, et al., Prevalence, indications and management of balloon uncrossable chronic total occlusions: insights from a contemporary multicenter US registry, *Catheter. Cardiovasc. Interv.* 90 (1) (2017) 12–20.
- [6] P. Tajti, D. Karpaliotis, K. Alaswad, et al., Prevalence, presentation and treatment of ‘Balloon Undilatable’ chronic Total occlusions: insights from a multicenter US registry, *Catheter. Cardiovasc. Interv.* 91 (4) (2018) 657–666.
- [7] M. Egred, E.S. Brilakis, Excimer laser coronary angioplasty (ELCA): fundamentals, mechanism of action, and clinical applications, *J. Invasive Cardiol.* 32 (2) (2020) E27–E35.
- [8] J. Karacsonyi, B.A. Danek, A. Karatasakis, I. Ungi, S. Banerjee, E.S. Brilakis, Laser coronary Atherectomy during contrast injection for treating an Underexpanded stent, *JACC Cardiovasc. Interv.* 9 (15) (2016) e147–e148.
- [9] C. McQuillan, Jackson MWP, E.S. Brilakis, M. Egred, Uncrossable and undilatable lesions—A practical approach to optimizing outcomes in PCI, *Catheter. Cardiovasc. Interv.* 97 (1) (2021) 121–126, <https://doi.org/10.1002/ccd.29001> Epub 2020 May 26. PMID: 32453918.
- [10] J. Nan, T.A. Joseph, M.R. Bell, M. Singh, Y. Sandoval, R. Gulati, Outcomes of excimer laser-contrast angioplasty for stent under-expansion, *EuroIntervention* 17 (1) (2021) 78–80, <https://doi.org/10.4244/EIJ-D-19-01074> PMID: 32583805.
- [11] P.A. Harris, R. Taylor, B.L. Minor, et al., The REDCap consortium: Building an international community of software platform partners, *J. Biomed. Inform.* 95 (2019) 103208.
- [12] P.A. Harris, R. Taylor, R. Thielke, J. Payne, N. Gonzalez, J.G. Conde, Research electronic data capture (REDCap)—a metadata-driven methodology and workflow process for providing translational research informatics support, *J. Biomed. Inform.* 42 (2) (2009) 377–381.
- [13] K. Thygesen, J.S. Alpert, A.S. Jaffe, et al., Third universal definition of myocardial infarction, *Circulation*. 126 (16) (2012) 2020–2035.
- [14] Y. Morino, M. Abe, T. Morimoto, et al., Predicting successful guidewire crossing through chronic total occlusion of native coronary lesions within 30 minutes: the J-CTO (multicenter CTO registry in Japan) score as a difficulty grading and time assessment tool, *JACC Cardiovasc. Interv.* 4 (2) (2011) 213–221.
- [15] G. Christopoulos, D.E. Kandzari, R.W. Yeh, et al., Development and validation of a novel scoring system for predicting technical success of chronic Total occlusion percutaneous coronary interventions: the PROGRESS CTO (prospective global registry for the study of chronic Total occlusion intervention) score, *JACC Cardiovasc. Interv.* 9 (1) (2016) 1–9.
- [16] S. Badr, I. Ben-Dor, D. Dvir, et al., The state of the excimer laser for coronary intervention in the drug-eluting stent era, *Cardiovasc. Revasc. Med.* 14 (2) (2013) 93–98.
- [17] E.S. Brilakis, Manual of Percutaneous Coronary Interventions, 1st ed. Elsevier, London, 2020.
- [18] S. Goel, R.T. Pasam, S. Chava, et al., Orbital atherectomy versus rotational atherectomy: a systematic review and meta-analysis, *Int. J. Cardiol.* 303 (2020) 16–21.
- [19] S. Ojeda, L. Azzalini, J. Suárez de Lezo, G.S. Johal, R. González, N. Barman, F. Hidalgo, N. Bellera, G. Dangas, A. Jurado-Román, A. Kini, M. Romero, R. Moreno, B. Garcia Del Blanco, R. Mehran, S.K. Sharma, M. Pan, Excimer laser coronary atherectomy for uncrossable coronary lesions. A multicenter registry, *Catheter. Cardiovasc. Interv.* (2020), <https://doi.org/10.1002/ccd.29392> Epub ahead of print. PMID: 33232583.
- [20] M. Megaly, M. Glogoza, I. Xenogiannis, et al., Outcomes with combined laser Atherectomy and intravascular brachytherapy in recurrent drug-eluting stent in-stent restenosis, *Cardiovasc. Revasc. Med.* 22 (2021) 29–33.
- [21] J.P. Fernandez, A.R. Hobson, D. McKenzie, et al., Beyond the balloon: excimer coronary laser atherectomy used alone or in combination with rotational atherectomy in the treatment of chronic total occlusions, non-crossable and non-expandable coronary lesions, *EuroIntervention*. 9 (2) (2013) 243–250.
- [22] V. Ambrosini, G. Sorropago, E. Laurenzano, et al., Early outcome of high energy laser (excimer) facilitated coronary angioplasty ON hARD and complex calcified and balloOn-resistant coronary lesions: LEONARDO study, *Cardiovasc. Revasc. Med.* 16 (3) (2015) 141–146.
- [23] A. Latib, K. Takagi, G. Chizzola, et al., Excimer laser LEsion modification to expand non-dilatatable stents: the ELLEMENT registry, *Cardiovasc. Revasc. Med.* 15 (1) (2014) 8–12.