

Henry Ford Health

Henry Ford Health Scholarly Commons

Anesthesiology Articles

Anesthesiology

5-20-2021

PROSPECT guideline for total hip arthroplasty: a systematic review and procedure-specific postoperative pain management recommendations

Marc Anger

Theodora Valovska
Henry Ford Health, tvalovs1@hfhs.org

Helene Beloeil

Philipp Lirk

Girish P. Joshi

See next page for additional authors

Follow this and additional works at: https://scholarlycommons.henryford.com/anesthesiology_articles

Recommended Citation

Anger M, Valovska T, Beloeil H, Lirk P, Joshi GP, Van de Velde M, and Raeder J. PROSPECT guideline for total hip arthroplasty: a systematic review and procedure-specific postoperative pain management recommendations. *Anaesthesia* 2021.

This Article is brought to you for free and open access by the Anesthesiology at Henry Ford Health Scholarly Commons. It has been accepted for inclusion in Anesthesiology Articles by an authorized administrator of Henry Ford Health Scholarly Commons.

Authors

Marc Anger, Theodora Valovska, Helene Beloeil, Philipp Lirk, Girish P. Joshi, Marc Van de Velde, and Johan Raeder

Guidelines

PROSPECT guideline for total hip arthroplasty: a systematic review and procedure-specific postoperative pain management recommendations

M. Anger,¹ T. Valovska,² H. Beloeil,³ P. Lirk,⁴ G. P. Joshi,⁵ M. Van de Velde,^{6,7} J. Raeder,^{8,9} on behalf of the PROSPECT Working Group* and the European Society of Regional Anaesthesia and Pain Therapy

1 Consultant, 3 Professor, Service d'Anesthésie Réanimation et Médecine Peri-opératoire, Université Rennes, Rennes, France

2 Resident, Department of Anesthesiology, Henry Ford Health Systems, Wayne State School of Medicine, Detroit, MI, USA

4 Associate Professor, Department of Anesthesiology, Brigham and Women's Hospital, Harvard Medical School, Boston, MA, USA

5 Professor, Department of Anesthesiology and Pain Management, University of Texas Southwestern Medical Center, Dallas, TX, USA

6 Professor, Department of Cardiovascular Sciences, Katholieke Universiteit Leuven, 7 Professor, Department of Anaesthesiology, UZLeuven, Leuven, Belgium

8 Professor, Department of Anaesthesiology, Oslo University Hospital, Oslo, 9 Professor, Division of Clinical Medicine, University of Oslo, Oslo, Norway

Summary

The aim of this systematic review was to develop recommendations for the management of postoperative pain after primary elective total hip arthroplasty, updating the previous procedure-specific postoperative pain management (PROSPECT) guidelines published in 2005 and updated in July 2010. Randomised controlled trials and meta-analyses published between July 2010 and December 2019 assessing postoperative pain using analgesic, anaesthetic, surgical or other interventions were identified from MEDLINE, Embase and Cochrane databases. Five hundred and twenty studies were initially identified, of which 108 randomised trials and 21 meta-analyses met the inclusion criteria. Peri-operative interventions that improved postoperative pain include: paracetamol; cyclo-oxygenase-2-selective inhibitors; non-steroidal anti-inflammatory drugs; and intravenous dexamethasone. In addition, peripheral nerve blocks (femoral nerve block; lumbar plexus block; fascia iliaca block), single-shot local infiltration analgesia, intrathecal morphine and epidural analgesia also improved pain. Limited or inconsistent evidence was found for all other approaches evaluated. Surgical and anaesthetic techniques appear to have a minor impact on postoperative pain, and thus their choice should be based on criteria other than pain. In summary, the analgesic regimen for total hip arthroplasty should include pre-operative or intra-operative paracetamol and cyclo-oxygenase-2-selective inhibitors or non-steroidal anti-inflammatory drugs, continued postoperatively with opioids used as rescue analgesics. In addition, intra-operative intravenous dexamethasone 8–10 mg is recommended. Regional analgesic techniques such as fascia iliaca block or local infiltration analgesia are recommended, especially if there are contra-indications to basic analgesics and/or in patients with high expected postoperative pain. Epidural analgesia, femoral nerve block, lumbar plexus block and gabapentinoid administration are not recommended as the adverse effects outweigh the benefits. Although intrathecal morphine 0.1 mg can be used, the PROSPECT group emphasises the risks and side-effects associated with its use and provides evidence that adequate analgesia may be achieved with basic analgesics and regional techniques without intrathecal morphine.

Re-use of this article is permitted in accordance with the Creative Commons Deed, Attribution 2.5, which does not permit commercial exploitation.

Correspondence to: J. Raeder

Email: johan.raeder@medisin.uio.no

Accepted: 3 April 2021

Keywords: analgesia; evidence-based medicine; pain; systematic review; total hip arthroplasty

*see Appendix 1

Twitter: @MarcVandeVelde6

Recommendations

- 1 Pre-operative exercise and education are recommended.
- 2 The basic analgesic regimen should include a combination of paracetamol and a non-steroidal anti-inflammatory drug or a cyclo-oxygenase-2-selective inhibitor administered pre-operatively or intra-operatively and continued postoperatively.
- 3 Spinal or general anaesthesia is recommended.
- 4 A single intra-operative dose of intravenous dexamethasone 8–10 mg is recommended for its analgesic and anti-emetic effects.
- 5 A single-shot fascia iliaca block or local infiltration analgesia is recommended.
- 6 If the patient has received spinal anaesthesia for the surgery, intrathecal morphine 0.1 mg could be considered.
- 7 Opioids should be reserved as rescue analgesics in the postoperative period.

Why was this guideline developed?

Total hip arthroplasty is a common surgical procedure and is associated with significant postoperative pain. Pain control can facilitate early postoperative rehabilitation, which is being increasingly encouraged in recent guidelines. The aim of this guideline is to provide clinicians with an updated evidence-based approach to pain management for elective total hip arthroplasty.

What other guidelines are available on this topic?

Several guidelines have been published assessing peri-operative care in total hip arthroplasty. However, some are focused on enhanced recovery after surgery or anaesthetic technique, and those specifically assessing peri-operative pain management focus on the efficacy of single interventions, broad techniques (e.g. regional analgesic techniques) or specific opioid-sparing strategies.

How does this guideline differ from other guidelines?

The present guideline applies the updated procedure-specific postoperative pain management (PROSPECT) methodology that critically evaluates the available literature. It considers the analgesic benefit of interventions against the backdrop of basic analgesics (i.e. paracetamol and non-steroidal anti-inflammatory drugs (NSAIDs) or cyclo-oxygenase-2 (COX-2)-selective inhibitors) and balances the procedure-specific efficacy and benefits of an intervention against its general risks and invasiveness. In that sense, it is more clinically applicable and pragmatic than statistical analysis used in meta-analyses, as well as focused on pain rather than overall enhanced recovery after surgery (ERAS) pathways or anaesthetic techniques.

Introduction

Total hip arthroplasty is a common surgical procedure aiming to improve mobility and quality of life in patients suffering from hip pain [1]. Adequate analgesia with minimal side-effects allows for early postoperative mobility, optimal functional recovery and decreased postoperative morbidity [2]. Despite being a frequently performed surgical procedure, there is high variability in the peri-operative anaesthetic and analgesic management for total hip arthroplasty [3, 4]. Recent guidelines have focused on ERAS [4] or anaesthetic technique [5] and those specifically assessing peri-operative pain management do not address all possible analgesic interventions in a single document [6, 7]. Also, for some recommendations [3–7] a detailed approach to the systematic review of literature is not provided, and lacks scientific discussion on the design of included randomised controlled trials, such as the efficacy when evidence-based basic simple analgesia had been included as active comparators [2]. One guideline is not updated [6].

The PROSPECT Working Group is a global collaboration of surgeons and anaesthetists formulating procedure-specific recommendations for pain

management after common but potentially painful operations [8]. The recommendations are based on a procedure-specific systematic literature review of randomised controlled trials and systematic reviews. The methodology also considers clinical practice, efficacy and adverse effects of analgesic drugs and techniques in order to provide overall recommendations [9].

The PROSPECT group has previously published a review on total hip arthroplasty in 2005 [10] that was updated in 2010 [11]. Of note, the previous update included the literature search from 1966 to July 2010 [11]. The aim of the present systematic review was to update the 2010 recommendations using the recently modified PROSPECT methodology [9], focusing on postoperative pain outcomes while assessing the effects of analgesic interventions in reference to the use of basic analgesics (paracetamol and NSAIDs or COX-2-selective inhibitors) and balancing risks and benefits of analgesic strategies.

Methods

The methods of this review adhered to the PROSPECT methodology as previously reported [9]. Specific to this study, the Embase, MEDLINE, PubMed and Cochrane Databases were searched for randomised controlled trials published between July 2010 and December 2019. The search terms related to pain and total hip arthroplasty included: "replacement" OR "prosthesis" OR "arthroplasty" AND "hip" AND "postoperative pain" OR "pain" OR "pain scale" or "rehabilitation" OR "pain management" OR "epidural" OR "spinal" OR "intrathecal anaesthesia" OR "peripheral nerve block" OR "nerve block" OR "local anaesthetics" OR "regional anaesthesia" OR "regional analgesia" OR "plexus block" OR "nerve block" OR "infiltration" OR "local infiltration analgesia" OR "lidocaine" OR "nonsteroidal anti-inflammatory drugs (NSAIDs)" OR "NSAIDs" OR "non-opioid analgesic" OR "opioid" OR "opioids" OR "dexamethasone" OR "gabapentin" OR "pregabalin" OR "ketamine" OR "paracetamol" OR "acetaminophen" OR "nefopam" OR "COX 2 selective inhibitor" OR "COX 2 inhibitor" OR "clonidine". We excluded any studies on acute hip fracture.

Only studies reporting either pain scores (verbal or numerical) or opioid consumption were included [9]. Systematic reviews and meta-analyses, when available, were used to check for studies not identified in our database search. Quality assessment of eligible studies was made according to PROSPECT methodology [9]. In brief, this involved a grading of allocation concealment (A–D); Jadad score (1–5); adequacy of statistical reporting (yes or no); and level of evidence (1–4). In the present report, we

defined a change of more than 10 mm on the visual analogue scale (VAS) or one point on a numerical rating score as clinically relevant [12]. Also statistically significant differences in analgesic opioid rescue medication or in opioid induced side-effects were used as valid outcomes.

For recommending an analgesic, at least two randomised controlled trials have to show efficacy. In addition, the efficacy of the analgesic intervention over the use of basic analgesics (paracetamol and NSAIDs or COX-2-selective inhibitors) was also considered. Furthermore, adverse effects and clinical aspects were evaluated. A subgroup developed draft recommendations, which were then circulated amongst all the members for review and comments. A modified Delphi approach was utilised as previously described [9]. This included obtaining feedback from PROSPECT members via email, followed by revised drafts of recommendations. This was followed by face-to-face discussions with the aim of developing a consensus. For conflicting recommendations, members voted via email. Once the members had opined, the lead authors drafted the final manuscript, which was ultimately approved by the full PROSPECT group.

Results

A total of 108 randomised controlled trials and 21 meta-analyses were included for the final qualitative analysis (Fig. 1). Summary recommendations on analgesic interventions are given in Table 1 and interventions that are not recommended are listed in Table 2. The methodological quality assessments of the randomised controlled trials are summarised in online Supporting Information Table S1. The characteristics of the included studies are shown in online Supporting Information Tables S2 and S3.

Pre-operative interventions

A single study assessed the effects of carbohydrate loading on postoperative pain and fatigue in hip arthroplasty patients [13], demonstrating a significant reduction of postoperative pain for the first 20 h following surgery. In a study by Goyal et al., the effect of management status (i.e. inpatient vs. day-case total hip arthroplasty) with similar postoperative analgesic protocols was considered [14]. Postoperative pain was significantly lower in day-case patients but this was not clinically significant. Pre-operative exercise and education were both found to be beneficial in reducing postoperative pain and improving functional outcomes in a meta-analysis conducted by Moyer et al. [15].

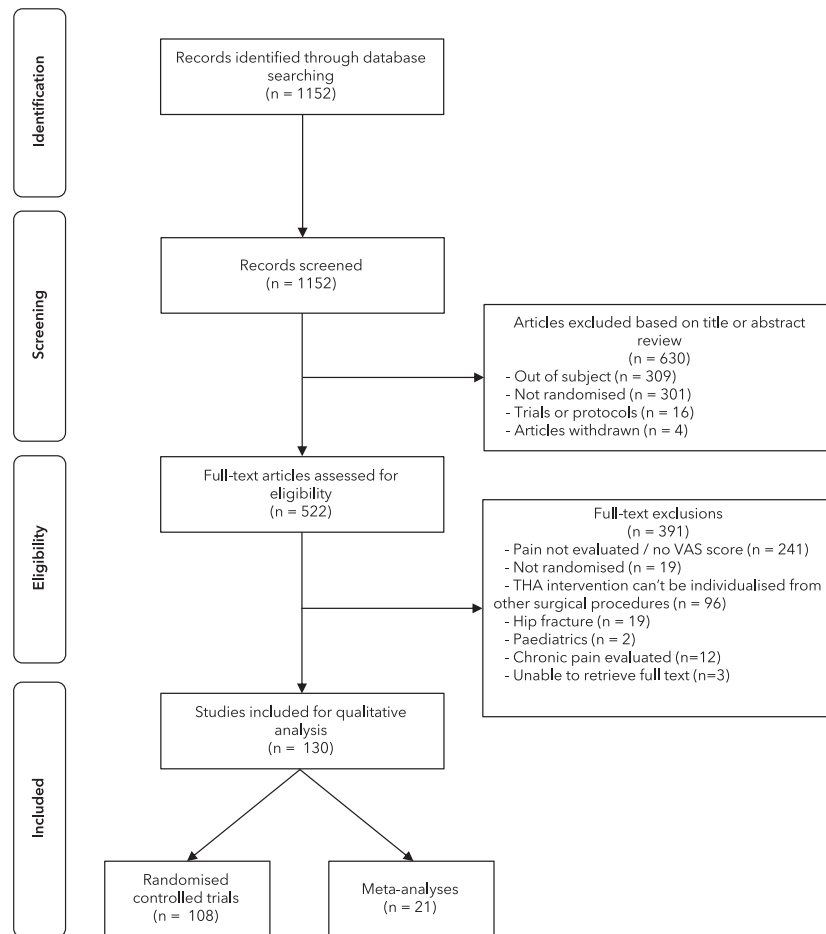


Figure 1 Flow diagram of studies identified, screened and included in this systematic review. VAS, visual analogue scale.

Table 1 Overall recommendations for pain management in patients undergoing total hip arthroplasty.

| |
|---|
| Pre-operative and intra-operative |
| Pre-operative exercise and education (Grade A) |
| General or spinal anaesthesia (Grade A) |
| Paracetamol (Grade A) |
| Non-steroidal anti-inflammatory drugs or cyclo-oxygenase-2-selective inhibitors (Grade A) |
| Dexamethasone 8–10 mg i.v. (Grade A) |
| Single-shot fascia iliaca block or local infiltration analgesia (Grade D) |
| If the patient has received spinal anaesthesia for the surgery, intrathecal morphine 0.1 mg could be considered (Grade D) |
| Postoperative |
| Paracetamol (Grade A) |
| Non-steroidal anti-inflammatory drugs or cyclo-oxygenase-2-selective inhibitors (Grade A) |
| Opioid for rescue (Grade D) |

Basic systemic non-opioid analgesics

Intravenous (i.v.) paracetamol was compared with placebo in two studies [16, 17], which showed lower pain intensity scores over the first 24 h and lower morphine consumption in the paracetamol groups. Westrich et al. [18] found no difference between i.v. vs. oral administration of paracetamol on postoperative pain outcomes. Paracetamol, anti-inflammatory drugs and placebo were recently compared in two studies. When taken individually, both drugs improved postoperative pain outcomes, whereas parecoxib plus paracetamol did not improve pain scores over parecoxib alone in one study [19], and paracetamol combined with ibuprofen did not result in a clinically relevant improvement over ibuprofen alone [20]. This suggests a limited impact of paracetamol when added to a regimen including COX-2-selective inhibitors or NSAIDs, but paracetamol is recommended as part of basic postoperative analgesia in general, due to minor

Table 2 Analgesic interventions that are not recommended for pain management in patients undergoing total hip arthroplasty.

| | Intervention | Reason for not recommending |
|----------------------------------|--|--|
| Pre-operative or intra-operative | Carbohydrate loading | Limited procedure-specific evidence |
| | Outpatient status | Limited procedure-specific evidence |
| | Pre-incisional COX-2-selective inhibitor vs. post-incisional | Limited procedure-specific evidence |
| | Gabapentinoids | Inconsistent evidence for single-dose. Procedure-specific evidence for multiple peri-operative doses, but extra side-effects |
| | Ketamine | Limited procedure-specific evidence |
| | Lateral femoral cutaneous block | Limited procedure-specific evidence |
| | Anterior quadratus lumborum block | Limited procedure-specific evidence |
| | Femoral nerve block | Procedure-specific evidence, but side-effects |
| | Lumbar plexus block | Procedure-specific evidence, but side-effects |
| | LIA adjuncts to local anaesthesia drugs | Inconsistent procedure-specific evidence |
| | LIA infusion or repeated injections | Inconsistent procedure-specific evidence |
| | Epidural analgesia | Procedure-specific evidence, but side-effects |
| | Postoperative | Tranexamic acid |
| Partial weight bearing | | Lack of procedure-specific evidence |
| Topical fibrin sealant | | Lack of procedure-specific evidence |
| TENS | | Limited procedure-specific evidence |
| Surgical technique | Anterior approach vs. posterolateral approach | Inconsistent procedure-specific evidence |
| | Minimally invasive vs. traditional incision | Inconsistent procedure-specific evidence, increased risks |

LIA, local infiltration analgesia; TENS, transcutaneous electrical nerve stimulation.

side-effects. Finally, a single study compared i.v. paracetamol with i.v. metamizole and found clinically insignificant reductions in morphine consumption and pain scores with metamizole [21], although pain scores in both groups were always lower than 40 mm on a VAS.

Three studies showed analgesic benefit of NSAID administration [22–24]. Regular i.v. diclofenac and orphenadrine infusions after surgery and at 12 h reduced morphine patient-controlled analgesia (PCA) consumption postoperatively [22]. McQuay et al. [23] showed that a combination of oral dexamethasone 25 mg with tramadol 75 mg was superior to both medications alone for postoperative pain control. In a three-group study, ketorolac improved pain scores and morphine consumption compared with a novel protein kinase C-epsilon inhibitor and placebo [24].

Four studies [25–28] specifically assessed controlling postoperative pain with pre-incisional COX-2-selective inhibitor administration. Two studies found that oral etoricoxib 2 h before surgery [26], or i.v. parecoxib or oral celecoxib 1 h before surgery [27] were associated with significantly lower postoperative pain scores and morphine consumption when compared with placebo. These benefits

were not found in another study with a 30-min pre-incisional i.v. parecoxib infusion [28]. Moreover, one study directly compared 30-min pre- vs. 30-min post-incisional i.v. 40 mg parecoxib administration [25] and found lower pain scores up to 6 h postoperatively and lower morphine consumption up to 24 h postoperatively with a pre-incisional protocol.

In conclusion, and in keeping with the PROSPECT basic analgesia recommendation [9], the administration of paracetamol in combination with NSAID or COX-2-selective inhibitors is recommended for total hip arthroplasty patients unless contraindicated. There is insufficient evidence to determine whether pre-operative COX-2 administration has an advantage over postoperative COX-2 administration. There is no procedure-specific evidence to choose a specific NSAID or COX-2-selective inhibitor.

Analgesic non-opioid adjuncts

Six studies showed a benefit on postoperative pain outcomes with glucocorticoid use [29–34]. Peri-operative 125 mg methylprednisolone compared with placebo reduced 24-h pain scores [31]. A second study showed analgesic benefit from 20 mg prednisolone pre-operatively followed by two postoperative doses of i.v. hydrocortisone

administered 8 h apart in patients with patient-controlled epidural analgesia, while pain scores did not differ [30]. Backes et al. [29] demonstrated that 10 mg of peri-operative dexamethasone had a significant effect, reducing mean VAS pain scores by > 20 mm, reducing opioid consumption in the first 24 h, with early ambulation and a shorter length of hospital stay. An additional dose of 10 mg dexamethasone at the postoperative 24-h mark showed continued effect, with lower morphine consumption on day two and a shorter length of stay when compared with a single dose. The efficacy of dexamethasone was demonstrated on top of adequate basic analgesia [32–34] showing improved postoperative pain outcomes with 8 or 10 mg, a lower incidence of postoperative nausea and vomiting and a shorter length of stay. Three meta-analyses showed benefits from glucocorticoids use on postoperative pain outcomes; time to discharge; and postoperative nausea and vomiting [35–37]; No major adverse events were described in these studies, other than a small but significant increase in blood glucose concentration in diabetic patients when dexamethasone was used [29,32]. The occurrence of postoperative infection did not differ [34, 35].

When considering gabapentinoids as the sole intervention, Paul et al. found no analgesic benefit when gabapentin 600 mg was administered pre-operatively followed up by a regimen of 200 mg three times daily for 3 days postoperatively [38]. However, Clarke et al. showed effectiveness of pre-operative pregabalin 150 mg administration continued postoperatively when added to a basic analgesic regimen of celecoxib and morphine PCA [39]. Carmichael et al. [40] investigated the combination of celecoxib and pregabalin (75 mg twice daily) for 2 weeks preceding and 3 weeks following surgery and found that patients in the treatment group experienced less acute pain on postoperative day one. However, morphine consumption did not differ, and there were more side-effects in the pregabalin-celecoxib group. The three meta-analyses included assessing the efficacy of gabapentin or pregabalin [41–43] in total hip arthroplasty found morphine-sparing effects, but reported side-effects such as dizziness, and were inconsistent regarding pain reduction. In conclusion, repeated doses of peri-operative gabapentinoids show evidence of pain reduction but are not recommended as routine medication due to clinically relevant side-effects.

The efficacy of intra-operative ketamine vs. pregabalin was compared in a four-group study consisting of ketamine alone, pregabalin alone, a

combination of pregabalin and ketamine or placebo [44]. However, no basic analgesia was used. Both ketamine and pregabalin significantly reduced 48-h morphine consumption with no difference in pain scores and side-effects (nausea; pruritus; dizziness). This sole study is insufficient evidence to recommend peri-operative ketamine or single-dose pregabalin.

Anaesthetic technique

The PROSPECT Group has previously recommended that the anaesthetic technique should not be selected solely for its effects on postoperative pain or opioid consumption [11]. However, three studies examining the effect of choice of anaesthetic technique are included in this review. General anaesthesia with a total i.v. anaesthesia approach was compared with spinal anaesthesia in a 120-patient study using adequate basic analgesia [45]. Results showed that patients receiving general anaesthesia had significantly higher pain scores during the first 2 postoperative hours but lower after 6 h compared with the spinal anaesthesia group. A second study [46] showed lower VAS pain scores and morphine consumption up to 24 h postoperatively with spinal or epidural vs. general anaesthesia but adequate basic analgesia was not used. Mei et al. investigated the efficacy of dexmedetomidine or propofol as sedatives in addition to regional anaesthesia and found no difference in pain outcomes, but a lower risk of delirium in the dexmedetomidine group [47]. In a recent meta-analysis, Yang et al. [48] showed significantly less pain when dexmedetomidine was part of the anaesthetic protocol. However, the reduction in pain in the studies on total hip arthroplasty was small, and bradycardia was reported as a significant and frequent side-effect with dexmedetomidine.

In conclusion, there is insufficient evidence to support a specific anaesthetic technique in favour of another in terms of postoperative analgesic benefits, although spinal anaesthesia may positively influence other postoperative outcomes when compared with general anaesthesia [5].

Peripheral nerve block

Single-shot peripheral nerve blocks have previously been recommended by the PROSPECT Group for total hip arthroplasty without further specification regarding the type of blocks [11]. Twenty-six new studies were available for review on this topic: 22 randomised controlled trials and four meta-analyses. The interventions studied were: femoral nerve block; lumbar plexus block; psoas compartment block; fascia iliaca block; lateral femoral cutaneous nerve block; and anterior quadratus lumborum block.

Six studies [49–54] assessed femoral nerve block for postoperative analgesia. When compared with no block with adequate basic analgesia, Kratz et al. showed that single-shot femoral nerve block significantly improved pain scores and reduced analgesic consumption, despite a high dropout rate [52]. In another study, patients receiving a femoral nerve block met earlier post-anaesthesia care unit (PACU) discharge criteria, with lower pain scores and analgesic consumption [51]. Continuous femoral nerve block was also compared with lumbar plexus block [49] and with epidural analgesia [54]. Similar pain and analgesic requirements were reported. When femoral nerve block was compared with fascia iliaca block, pain scores were higher in the femoral nerve block group (but only by 5 mm with both groups being < 15 mm on the VAS) [50]. Kuchalik et al. [53] showed that femoral nerve block proved inferior to local infiltration analgesia (LIA) for the first 24 postoperative hours on pain scores and morphine consumption, and with significantly more motor blockade in femoral nerve block group.

Fascia iliaca block was evaluated in six studies [55–60]. Shariat et al. [55] used fascia iliaca block as rescue analgesia in PACU, reporting that it did not improve pain scores or morphine consumption vs. placebo. However, another study showed clinically relevant significantly lower morphine consumption at 24 and 48 h with a fascia iliaca block compared with no block on top of multimodal basic analgesia [56]. Comparing fascia iliaca block with alternative anaesthetic techniques, Kearns et al. [57] showed that morphine consumption was higher with fascia iliaca block when compared with 0.1 mg intrathecal morphine, with no difference in pain scores or side-effects apart from 2 h shorter time to mobilisation in the fascia iliaca block group. Perry et al. [60] found similar data between fascia iliaca block and psoas compartment block. When compared with LIA [58, 59], postoperative pain outcomes did not differ; however the fascia iliaca block group showed more muscle weakness at 6 h in one study [58]. Finally, three recent meta-analyses [61–63], combining the existing data, all concluded that there was lower pain scores, lower morphine consumption and even shorter length of stay when fascia iliaca block was used, with no greater risk of falls [61].

Thybo et al. performed two studies on lateral femoral cutaneous block compared with placebo with adequate baseline multimodal analgesia [64, 65]. One study did not show any difference in pain scores [65], the other showed that lateral femoral cutaneous block reduced movement-related pain [64]. A double nerve block of lateral femoral cutaneous block and subcostal nerves via infiltration had no

effect on postoperative pain outcomes over placebo in a report from Bron et al. [66].

Six studies evaluated lumbar plexus block [67–72]. When compared with LIA [67, 68], lumbar plexus block did not show any benefit on postoperative pain and opioid consumption. Local infiltration analgesia had lower pain scores at 3 h postoperatively in one study [67]. Continuous lumbar plexus block was compared with paravertebral block performed at L2 by Wardhan et al. [70]. Morphine consumption during the first 24 h was higher in the paravertebral block group, but pain scores were similar. When lumbar plexus block was compared with 0.1 mg intrathecal morphine [72], patients in the latter group required less intra-operative opioids, less rescue morphine and had lower pain scores in PACU. However, they needed more rescue morphine in the subsequent 24 h and experienced increased pruritus. Also, ropivacaine 0.1% and 0.2% continuous lumbar plexus block have been compared [71], which demonstrated similar pain outcomes and motor block intensity. Lastly, Green et al. [69] considered an intra-operative, surgeon-delivered psoas compartment block performed during total hip arthroplasty vs. no block. Psoas compartment block prolonged the time to first request of rescue analgesia and reduced postoperative pain scores.

One study evaluated an anterior quadratus lumborum block compared with no block [73]. Patients in the treatment group showed lower morphine consumption and lower pain scores at 24 h, but not at other time-points.

In conclusion, femoral nerve block, lumbar plexus block, psoas compartment block, quadratus lumborum block and fascia iliaca block lowered postoperative pain scores and morphine consumption, whereas lateral femoral cutaneous block did not. At the time of our search, we only found one randomised controlled trial on quadratus lumborum block. The lumbar plexus block is a deep block with potential risks [74] and the femoral nerve block has a significant incidence of muscle weakness [74, 75], and are thus not recommended. The potential benefit of nerve blocks on postoperative pain should be balanced against the side-effects, such as delayed mobilisation, motor block or risk of falls. In recent meta-analyses, no more falls were reported with fascia iliaca block [61, 62], which is recommended as the preferred nerve block when a nerve block is indicated for total hip arthroplasty.

Local infiltration analgesia

Local infiltration analgesia was not part of previous PROSPECT recommendations, primarily due to inadequate

evidence. For the present review, single-injection LIA was directly compared with placebo or no injection in 15 randomised controlled trials [76–90]. Of these, five placebo-controlled randomised controlled trials showed lower pain scores, opioid consumption or shorter length of stay [83, 84, 86, 87, 89]. When compared with no injection, Busch et al. [85] showed significantly lower pain scores and morphine consumption, but basic analgesia was not used. Villatte et al. [88] reported a difference in pain scores, but this was not clinically meaningful. Another seven randomised controlled trials in which LIA was combined with adequate basic analgesia failed to show improvements in pain control [76–82]. In the meta-analyses of Ma et al., LIA resulted in significant benefits during the first 24 h in terms of less pain at rest and during movement, and a reduction in opioid consumption [92]. When bupivacaine was compared with liposomal bupivacaine for LIA, there were similar pain outcomes [93].

Two studies assessing multiple doses or continuous infusion of LIA compared with placebo [94, 95] found improved postoperative pain scores and morphine consumption at 48–72 h with a pericapsular infusion via a catheter. However, a systemic effect of local anaesthesia cannot be ruled out, and three studies with a similar design failed to show any benefit [96–98].

When comparing a multimodal pain regimen containing LIA and patient-controlled epidural analgesia, pain scores during movement favoured the epidural group. However, for the primary outcome of readiness for hospital discharge, there was no difference [99]. In a three-group study [100] comparing a multi-drug LIA regimen, morphine PCA and epidural analgesia, patients with LIA reported reduced pain scores and morphine consumption compared with those receiving morphine PCA. No difference was observed when compared with epidural. Yan et al. [101] compared LIA with epidural in a meta-analysis of nine studies and found no significant difference between the LIA and the epidural group 48–72 h after surgery for pain with movement, but less pain at 24 h in the epidural group [101].

Two studies compared LIA with intrathecal morphine 0.1 mg [102, 103]. One study [102], found no differences in pain scores or postoperative nausea and vomiting. Although patients in the LIA group required more rescue oxycodone, they mobilised better at 6 h after surgery as well as the following morning [102]. The second study [103] showed that intrathecal morphine was more effective in the first 24 h compared with multi-drug LIA, but patients in this group had higher morphine consumption after 24 h and

experienced more postoperative nausea and vomiting and pruritus.

Three meta-analyses [104–106] indicated that multi-drug LIA had lower postoperative pain scores, lower opioid consumption and in one meta-analyses a shorter length of hospital stay [105]. Comparing LIA, peripheral nerve block and placebo in a network meta-analysis [107] including 35 randomised controlled trials and 2296 patients, the LIA treatment group had lower postoperative pain scores and opioid consumption at 24 h vs. placebo, whereas peripheral nerve block failed to do the same. However, there was no difference between peripheral nerve block and LIA on these outcomes. In conclusion, single-injection LIA has analgesic effect with no side-effects.

Epidural analgesia

Epidural levobupivacaine with sufentanil adjuvant was compared with oral controlled-release oxycodone [108]. Epidural analgesia provided better dynamic pain relief (mean VAS reduction from 3.0 to 1.7 on a 0–10 scale) and lower opioid consumption on day one postoperatively. However, oral oxycodone was more effective on pain control at rest on postoperative days two and three. The modest differences in pain reduces the impact of these results.

Adjuvant epidural therapies were addressed in three studies [109–111]. The following had beneficial effects on postoperative pain outcomes: 8 mg epidural dexamethasone [110], 75 mg epidural magnesium [109] and epidural ketamine [109, 111]; however, adequate basic analgesia was not used in these studies.

In conclusion, epidural analgesia is effective, but is not recommended due to well-recognised side-effects in lower limb surgery, such as limb weakness, bladder dysfunction and delayed mobilisation [112].

Spinal analgesia

Seven studies [58, 73, 102, 103, 113–115] evaluated the effectiveness of adding intrathecal analgesia for postoperative pain after total hip arthroplasty. Comparison of intrathecal morphine to peripheral nerve block [58, 73] or LIA [102, 103] is discussed in previous paragraphs. Evaluating intrathecal morphine doses of 0.05 mg vs. 0.1 mg showed that patients receiving 0.1 mg had lower pain scores and a longer duration of analgesia [113] but use of basic analgesia was not reported. Similar postoperative nausea and vomiting frequency was found in both groups, but patients receiving the higher dose experienced pruritus more often.

Intrathecal adjuvants have also been evaluated in two other studies [114, 115]. Intrathecal ketorolac 2 mg showed no benefit on postoperative pain outcomes [114] but intrathecal or i.v. magnesium lowered pain scores and 24-h morphine consumption vs. no adjuvants [115].

In conclusion, when spinal anaesthesia is used for surgery, there is evidence for analgesic effect of intrathecal morphine 0.1 mg, which could be considered.

Operative techniques

We included 16 randomised controlled trials and three meta-analyses comparing surgical techniques. These interventions include drains [116–119]; different conventional surgical approaches [120–124]; and minimally invasive approaches to hip arthroplasty [125–133]. Pain was a secondary outcome in most of these studies, and a basic analgesic regimen was often inadequate or not specified. Considering the use of postoperative drains vs. no drains, pain scores were similar in both groups [116–118], but one study reported higher pain scores in the patients with a drain [119]. Thus, drains are not recommended to improve pain outcomes.

Comparing the direct anterior surgical approach with the posterolateral approach, three studies [120–122] found lower pain scores with the direct anterior surgical approach on the first postoperative day, but with less than 10-mm difference on the VAS. Pooling these results and others, a meta-analysis by Wang et al. [123], confirmed direct anterior surgical approach to be associated with less postoperative pain than a posterolateral approach to total hip arthroplasty, but was associated with a longer duration of surgery. Putananon et al. [124], showed that, despite experiencing lower postoperative pain with a lateral vs. anterior vs. posterior approach, surgical complications were seen more frequently in the same order, respectively.

Three studies supported improved postoperative pain outcomes with a minimally invasive operative approach vs. conventional approach [125, 126, 132], but surgical complications were more frequent in the minimally invasive approach group in one study [132]. However, five other studies did not show any difference on postoperative pain outcomes, comparing a minimally invasive approach to a conventional approach [127–130, 133]. Finally, a meta-analysis of 2849 patients [131] showed a clinically insignificant benefit on pain scores with the minimally invasive approach, but with a five-fold higher risk of iatrogenic nerve damage in this group when compared with a conventional approach.

One study showed similar pain scores and morphine consumption comparing a bipolar sealer and standard electrocautery [134].

In conclusion, there is inconclusive evidence in terms of postoperative pain for choosing a specific surgical approach. Thus, surgical technique should depend on surgeon and patient preference.

Postoperative interventions

Four studies evaluated postoperative opioid administration [135–138]. Rothwell et al. showed that PCA with i.v. morphine had no benefits over oral oxycodone [135]. One study found no differences in pain scores between i.v. morphine vs. a combination of i.v. oxycodone and morphine [137]; while i.v. fentanyl showed lower pain scores and lower morphine consumptions than i.v. oxycodone [138]. Lastly, Musclow et al. examined the effectiveness of adding 30 mg oral modified-release morphine every 12 h to a paracetamol/NSAIDs/morphine PCA regimen vs. placebo. Modified-release morphine did not prove effective on pain scores but was associated with significantly more opioid-related side-effects [136].

Analgesic effects of several other postoperative interventions have been examined. There were no clinical differences in pain outcomes between partial weight-bearing compared with full weight-bearing after cementless total hip arthroplasty [139]. Further, dressing type [140] or topical administration of fibrin sealant [141] did not make any difference. A single study [142] examining transcutaneous electrical nerve stimulation showed a reduction on postoperative fentanyl consumption at 24 h, but no effect on pain scores. Despite a reduction in blood loss, tranexamic acid administration proved inconsistent on improving pain outcomes [143, 144].

Discussion

This systematic review of total hip arthroplasty examined the effects of peri-operative analgesic, anaesthetic and surgical techniques, as well as other interventions, on postoperative pain. The updated recommendations are presented in Table 1. The strength of this study stems from the PROSPECT methodology [9], which goes beyond making recommendations based on the simple statistical analysis of the available evidence. The included studies are interpreted preferably based on the use of basic analgesics (paracetamol with NSAIDs or COX-2-selective inhibitors) and balancing the benefits and adverse effects of the intervention, as well as assimilating this information in a clinical context. More importantly, significant attention is given to the modern approach of early ambulation after total hip arthroplasty as well as performance of total hip arthroplasty on a short-stay or day-case basis. Furthermore, the changes in surgical

techniques, which have allowed for reduced postoperative pain and more rapid recovery, are also considered.

We would like to emphasise that the previous literature searches were performed between 1966 and July 2010, while this one is performed between July 2010 and December 2019. Of note, the databases searched and the inclusion criteria for the reviews are identical, although the PROSPECT methodology of interpretation of included studies has changed.

There are significant differences between these updated recommendations and our previous recommendations [11]. For example, previously recommended approaches such as femoral nerve block, lumbar plexus block and epidural analgesia are no longer recommended due to the availability of evidence supporting better and safer alternatives such as fascia iliaca block and LIA. In fact, even in the previous recommendation it was emphasised that lumbar plexus block provides superior pain relief to femoral nerve block, and that femoral nerve block may have negative effects on postoperative ambulation [11].

Previously [11] LIA was not recommended due to inconsistent evidence. In contrast, single injection LIA may now be considered based on supportive studies. The PROSPECT Group emphasises the considerable heterogeneity and variability of published LIA studies with regard to analgesic effect, technique, volume and dose of local anaesthetic used and the drug combinations used [77–92]. In addition, the studies are inconsistent with regard to the comparator groups (placebo vs. no injection vs. other analgesic technique) and single-shot or catheter techniques. Also, in most studies of multi-drug LIA, there was no control for potential systemic effects of the additives in the mixtures. The PROSPECT Group emphasises that with modern surgical techniques and the correct implementation of basic analgesia and multimodal analgesia (paracetamol, NSAIDs and dexamethasone) the added value of LIA techniques still warrant further validation [145, 146]. Therefore, the PROSPECT Group strongly encourages further well-conducted studies in this area.

There was significant conflict amongst the PROSPECT members regarding the use of intrathecal morphine 0.1 mg, and a consensus could not be reached. Delphi voting revealed four members to be in favour of recommending the use of intrathecal morphine and nine members against. Therefore, if intrathecal morphine is used, the PROSPECT Group reminds clinicians of the risks and benefits associated with its use. In favour of

intrathecal morphine is the documented analgesia it provides for at least 24 h postoperatively and the limited adverse effects with small doses (≤ 0.1 mg morphine) [147, 148]. However, pruritus and postoperative nausea and vomiting are associated with intrathecal morphine [103, 113]. It was thought that even if the incidence of these adverse events may be relatively lower with intrathecal morphine 0.1 mg, they may still delay ambulation and oral intake, and influence patient satisfaction [103, 113]. Indeed, adequate multimodal analgesia with paracetamol, NSAIDs and dexamethasone, without intrathecal morphine, together with more recent surgical techniques, may be sufficient to provide patients with good pain relief [145, 146, 149].

Dexamethasone was not recommended in the previous guidelines due to limited procedure-specific evidence. However, based on recent evidence, dexamethasone 8–10 mg i.v. is recommended. The safety of a single dose of steroids is well documented [150, 151]. Equipotent doses of alternative glucocorticoids seem to be equally effective, whereas multiple doses beyond 24 h are not recommended due to insufficient studies and concern related to the potential side-effect profile. Gabapentinoids have shown opioid-sparing effects but can cause sedation; blurred vision; dizziness [41]; interfere with early mobilisation; and cause orthostatic intolerance [152], and thus are not recommended. Intra-operative ketamine is not recommended due to limited procedure-specific evidence and potential psychotropic side-effects [153]. Neuraxial anaesthesia has been recommended because it is associated with improved postoperative outcomes compared with general anaesthesia [5]. However, its benefits with regard to postoperative pain control remains inconclusive.

The limitations in this review are, among others, related to those of the included studies. Many of the analgesic interventions were not evaluated against a control group that included an optimised multimodal analgesic regimen such as paracetamol and NSAIDs or COX-2-selective inhibitors. There was considerable heterogeneity between studies such as unstandardised anaesthetic techniques, variable analgesic dosing regimens, variable methods of administration, variable control groups, as well as variable time-points of pain assessments. Heterogeneous control groups were also documented by Karlsen et al. [154]. Other limiting factors include selection bias by the primary reviewers. Selection bias could have developed because all studies fulfilling the search requirements were split between two reviewers, and then included or excluded based on Jadad score requirements. This method also allows for

human error, where an appropriate study could have been missed by a reviewer and excluded. Unfortunately, none of the included studies assessed patients at high risk of excessive postoperative pain (e.g. chronic opioid use, chronic pain states or significant psychiatric disorders). It is possible that analgesic approaches not recommended in this review due to limited analgesic efficacy and/or concerns of adverse effects may be appropriate in situations where one or more of the primary recommendations are contraindicated or otherwise not appropriate to use. Also, it may be appropriate to use additional analgesic interventions beyond the primary recommendations in patients with an anticipated higher than average risk of strong postoperative pain (e.g. chronic opioid use, chronic pain states or significant psychiatric disorders).

In summary, this review has identified an analgesic regimen for optimal pain management after elective total hip arthroplasty (Table 1). We have also identified analgesic interventions that are not recommended for routine pain management in this patient population (Table 2). Future studies should be adequately powered with standardised anaesthetic regimens and use adequate basic analgesia to account for discrepancies between treatment and control groups. Focus should be on pain and appropriate analgesic treatment in a short-stay context, as this is evolving as the method of choice in terms of rapid rehabilitation. Outcomes, such as time to ambulation, hospital length of stay and the occurrence of chronic pain or chronic opioid consumption should be included in the scope of future studies, as these are closely related to the degree of postoperative pain.

Acknowledgements

PROSPECT is supported by an unrestricted grant from the European Society of Regional Anaesthesia and Pain Therapy. In the past, PROSPECT has received unrestricted grants from Pfizer Inc. New York, NY, USA and Grunenthal, Aachen, Germany. GJ has received honoraria from Baxter and Pacira Pharmaceuticals. FB has received honoraria from Pfizer, The Medicine Company, Abbott France and Nordic Pharma France. HK has received honoraria from Pfizer and Grunenthal. SS's institution has received research and travel funding and speaking and consulting honoraria from bioCSL, Eli Lilly, Indivior, iX Biopharma and Pfizer. NR has received honoraria from Baxter and Sintetica. MVdV received honoraria from Sintetica, Grunenthal, Vifor Pharma, MSD, Nordic Pharma, CLS Behring, Janssen Pharmaceuticals, Heron Therapeutics and Aquettant. No other or competing interests declared.

Appendix 1. PROSPECT Working Group

G. P. Joshi, E. Pogatzki-Zahn, M. Van de Velde, H. Kehlet, F. Bonnet, N. Rawal, P. Lavand'homme, H. Beloeil, J. Raeder, A. Sauter, E. Albrecht, P. Lirk, S. Freys, D. Lobo, T. Volk, M. Werner, M. Bonnet.

References

1. Maradit Kremers H, Larson DR, Crowson CS, et al. Prevalence of total hip and knee replacement in the United States. *Journal of Bone and Joint Surgery* 2015; **97**: 1386–97.
2. Joshi GP, Kehlet H. Postoperative pain management in the era of ERAS: an overview. *Best Practice and Research Clinical Anaesthesiology* 2019; **33**: 259–67.
3. Geisler A, Dahl JB, Thybo KH, et al. Pain management after total hip arthroplasty at five different Danish hospitals: a prospective, observational cohort study of 501 patients. *Acta Anaesthesiologica Scandinavica* 2019; **63**: 923–30.
4. Soffin EM, Gibbons MM, Ko CY, et al. Evidence review conducted for the agency for healthcare research and quality safety program for improving surgical care and recovery: focus on anaesthesiology for total hip arthroplasty. *Anesthesia and Analgesia* 2019; **128**: 454–65.
5. Memtsoudis SG, Cozowicz C, Bekeris J, et al. Anaesthetic care of patients undergoing primary hip and knee arthroplasty: consensus recommendations from the International Consensus on Anaesthesia-Related Outcomes after Surgery group (ICAROS) based on a systematic review and meta-analysis. *British Journal of Anaesthesia* 2019; **123**: 269–87.
6. Højer Karlsen AP, Geisler A, Petersen PL, Mathiesen O, Dahl JB. Postoperative pain treatment after total hip arthroplasty: a systematic review. *Pain* 2015; **156**: 8–30.
7. Min B-W, Kim Y, Cho H-M, et al. Perioperative pain management in total hip arthroplasty: Korean hip society guidelines. *Hip and Pelvis* 2016; **28**: 15–23.
8. Lee B, Schug SA, Joshi GP, et al. Procedure-specific pain management (PROSPECT) – An update. *Best Practice and Research Clinical Anaesthesiology* 2018; **32**: 101–11.
9. Joshi GP, Van de Velde M, Kehlet H, et al. PROSPECT Working Group Collaborators. Development of evidence-based recommendations for procedure-specific pain management: PROSPECT methodology. *Anaesthesia* 2019; **74**: 1298–304.
10. Fischer HBJ, Simanski CJP. A procedure-specific systematic review and consensus recommendations for analgesia after total hip replacement. *Anaesthesia* 2005; **60**: 1189–202.
11. PROSPECT. Systematic review of operative analgesia for total hip arthroplasty. 2010. <https://esraeurope.org/prospect/procedures/total-hip-arthroplasty-2010/summary-recommendations-16/> (accessed 01/09/2020).
12. Myles PS, Myles DB, Gallagher W, et al. Measuring acute postoperative pain using the visual analog scale: the minimal clinically important difference and patient acceptable symptom state. *British Journal of Anaesthesia* 2017; **118**: 424–9.
13. Harsten A, Hjartarson H, Toksvig-Larsen S. Total hip arthroplasty and perioperative oral carbohydrate treatment: a randomised, double-blind, controlled trial. *European Journal of Anaesthesiology* 2012; **29**: 271–4.
14. Goyal N, Chen AF, Padgett SE, et al. Otto Aufranc Award: a multicenter, randomized study of outpatient versus inpatient total hip arthroplasty. *Clinical Orthopaedics and Related Research* 2017; **475**: 364–72.
15. Moyer R, Ikert K, Long K, Marsh J. The value of preoperative exercise and education for patients undergoing total hip and

- knee arthroplasty: a systematic review and meta-analysis. *Journal of Bone and Joint Surgery Reviews* 2017; **5**: e2.
16. Sinatra RS, Jahr JS, Reynolds L, et al. Intravenous acetaminophen for pain after major orthopedic surgery: an expanded analysis. *Pain Practice* 2012; **12**: 357–65.
 17. Takeda Y, Fukunishi S, Nishio S, Yoshiya S, Hashimoto K, Simura Y. Evaluating the effect of intravenous acetaminophen in multimodal analgesia after total hip arthroplasty: a randomized controlled trial. *Journal of Arthroplasty* 2019; **34**: 1155–61.
 18. Westrich GH, Birch GA, Muskat AR, et al. Intravenous vs oral acetaminophen as a component of multimodal analgesia after total hip arthroplasty: a randomized, blinded trial. *Journal of Arthroplasty* 2019; **34**: S215–S220.
 19. Camu F, Borgeat A, Heylen RJ, Viel EJ, Boye ME, Cheung RY. Parecoxib, propacetamol, and their combination for analgesia after total hip arthroplasty: a randomized non-inferiority trial. *Acta Anaesthesiologica Scandinavica* 2017; **61**: 99–110.
 20. Thybo KH, Hägi-Pedersen D, Dahl JB, et al. Effect of combination of paracetamol (acetaminophen) and ibuprofen vs either alone on patient-controlled morphine consumption in the first 24 hours after total hip arthroplasty: the PANSOID randomized clinical trial. *Journal of the American Medical Association* 2019; **321**: 562–71.
 21. Oreskovic Z, Bicanic G, Hrabac P, Tripkovic B, Delimar D. Treatment of postoperative pain after total hip arthroplasty: comparison between metamizol and paracetamol as adjunctive to opioid analgesics—prospective, double-blind, randomised study. *Archives of Orthopaedic and Trauma Surgery* 2014; **134**: 631–6.
 22. Gombotz H, Lochner R, Sigl R, Blasl J, Herzer G, Trimmel H. Opiate sparing effect of fixed combination of diclophenac and orphenadrine after unilateral total hip arthroplasty: a double-blind, randomized, placebo-controlled, multi-centre clinical trial. *Wiener Medizinische Wochenschrift* 2010; **160**: 526–34.
 23. McQuay HJ, Moore RA, Berta A, et al. Randomized clinical trial of dexamethasone/paracetamol 25 mg/75 mg in moderate-to-severe pain after total hip arthroplasty. *British Journal of Anaesthesia* 2016; **116**: 269–76.
 24. Moodie JE, Bisley EJ, Huang S, Pickthorn K, Bell G. A single-center, randomized, double-blind, active, and placebo-controlled study of KAI-1678, a novel PKC-epsilon inhibitor, in the treatment of acute postoperative orthopedic pain. *Pain Medicine* 2013; **14**: 916–24.
 25. Bao Y, Fang J, Peng L, et al. Comparison of preincisional and postincisional parecoxib administration on postoperative pain control and cytokine response after total hip replacement. *Journal of International Medical Research* 2012; **40**: 1804–11.
 26. Renner B, Walter G, Strauss J, Fromm MF, Zacher J, Brune K. Preoperative administration of etoricoxib in patients undergoing hip replacement causes inhibition of inflammatory mediators and pain relief. *European Journal of Pain* 2012; **16**: 838–48.
 27. Ittichaikulthol W, Prachanpanich N, Kositchaiwat C, Intapan T. The post-operative analgesic efficacy of celecoxib compared with placebo and parecoxib after total hip or knee arthroplasty. *Journal of the Medical Association of Thailand* 2010; **93**: 937–42.
 28. Peng H-M, Wang L-C, Wang W, et al. Preemptive analgesia with parecoxib in total hip arthroplasty: a randomized, double-blind, placebo-controlled trial. *Pain Physician* 2018; **21**: 483–8.
 29. Backes JR, Bentley JC, Politi JR, Chambers BT. Dexamethasone reduces length of hospitalization and improves postoperative pain and nausea after total joint arthroplasty: a prospective, randomized controlled trial. *Journal of Arthroplasty* 2013; **28**: 11–7.
 30. Sculco PK, McLawhorn AS, Desai N, Su EP, Padgett DE, Jules-Elysee K. The effect of perioperative corticosteroids in total hip arthroplasty: a prospective double-blind placebo controlled pilot study. *Journal of Arthroplasty* 2016; **31**: 1208–12.
 31. Lunn TH, Andersen LØ, Kristensen BB, et al. Effect of high-dose preoperative methylprednisolone on recovery after total hip arthroplasty: a randomized, double-blind, placebo-controlled trial. *British Journal of Anaesthesia* 2013; **110**: 66–73.
 32. Dissanayake R, Du HN, Robertson IK, Ogden K, Wiltshire K, Mulford JS. Does dexamethasone reduce hospital readiness for discharge, pain, nausea, and early patient satisfaction in hip and knee arthroplasty? a randomized, controlled trial. *Journal of Arthroplasty* 2018; **33**: 3429–36.
 33. Lei Y, Huang Q, Xu B, Zhang S, Cao G, Pei F. Multiple low-dose dexamethasone further improves clinical outcomes following total hip arthroplasty. *Journal of Arthroplasty* 2018; **33**: 1426–31.
 34. Lei Y-T, Xu B, Xie X-W, Xie J-W, Huang Q, Pei F-X. The efficacy and safety of two low-dose peri-operative dexamethasone on pain and recovery following total hip arthroplasty: a randomized controlled trial. *International Orthopaedics* 2018; **42**: 499–505.
 35. Yang Q, Zhang Z, Xin W, Li A. Preoperative intravenous glucocorticoids can decrease acute pain and postoperative nausea and vomiting after total hip arthroplasty: a PRISMA-compliant meta-analysis. *Medicine* 2017; **96**: e8804.
 36. Li X, Sun Z, Han C, He L, Wang B. A systematic review and meta-analysis of intravenous glucocorticoids for acute pain following total hip arthroplasty. *Medicine* 2017; **96**: e6872.
 37. Fan Z-R, Ma J, Ma X-L, et al. The efficacy of dexamethasone on pain and recovery after total hip arthroplasty. *Medicine* 2018; **97**: e0100.
 38. Paul JE, Nantha-Aree M, Buckley N, et al. Randomized controlled trial of gabapentin as an adjunct to perioperative analgesia in total hip arthroplasty patients. *Canadian Journal of Anesthesia* 2015; **62**: 476–84.
 39. Clarke H, Pagé GM, McCartney CJL, et al. Pregabalin reduces postoperative opioid consumption and pain for 1 week after hospital discharge but does not affect function at 6 weeks or 3 months after total hip arthroplasty. *Survey of Anesthesiology* 2016; **60**: 171.
 40. Carmichael NME, Katz J, Clarke H, et al. An intensive perioperative regimen of pregabalin and celecoxib reduces pain and improves physical function scores six weeks after total hip arthroplasty: a prospective randomized controlled trial. *Pain Research and Management* 2013; **18**: 127–32.
 41. Mao Y, Wu L, Ding W. The efficacy of preoperative administration of gabapentin/pregabalin in improving pain after total hip arthroplasty: a meta-analysis. *BMC Musculoskeletal Disorders* 2016; **17**: 373.
 42. Han C, Li X-D, Jiang H-Q, Ma J-X, Ma X-L. The use of gabapentin in the management of postoperative pain after total hip arthroplasty: a meta-analysis of randomised controlled trials. *Journal of Orthopaedic Surgery and Research* 2016; **11**: 79.
 43. Li F, Ma J, Kuang M, et al. The efficacy of pregabalin for the management of postoperative pain in primary total knee and hip arthroplasty: a meta-analysis. *Journal of Orthopaedic Surgery and Research* 2017; **12**: 49.
 44. Martinez V, Cymerman A, Ben Ammar S, et al. The analgesic efficiency of combined pregabalin and ketamine for total hip arthroplasty: a randomised, double-blind, controlled study. *Anaesthesia* 2014; **69**: 46–52.
 45. Harsten A, Kehlet H, Ljung P, Toksvig-Larsen S. Total intravenous general anaesthesia vs. spinal anaesthesia for total hip arthroplasty: a randomised, controlled trial. *Acta Anaesthesiologica Scandinavica* 2015; **59**: 298–309.

46. Liang C, Wei J, Cai X, Lin W, Fan Y, Yang F. Efficacy and safety of 3 different anesthesia techniques used in total hip arthroplasty. *Medical Science Monitor* 2017; **23**: 3752–9.
47. Mei B, Meng G, Xu G, et al. Intraoperative sedation with dexmedetomidine is superior to propofol for elderly patients undergoing hip arthroplasty: a prospective randomized controlled study. *Clinical Journal of Pain* 2018; **34**: 811–7.
48. Yang Q, Ren Y, Feng B, Weng X. Pain relieving effect of dexmedetomidine in patients undergoing total knee or hip arthroplasty. *Medicine* 2020; **99**: e18538.
49. Ilfeld BM, Mariano ER, Madison SJ, et al. Continuous femoral versus posterior lumbar plexus nerve blocks for analgesia after hip arthroplasty: a randomized, controlled study. *Anesthesia and Analgesia* 2011; **113**: 897–903.
50. Yu B, He M, Cai G-Y, Zou T-X, Zhang N. Ultrasound-guided continuous femoral nerve block vs continuous fascia iliaca compartment block for hip replacement in the elderly. *Medicine* 2016; **95**: e5056.
51. Wiesmann T, Steinfeldt T, Wagner G, Wulf H, Schmitt J, Zoremba M. Supplemental single shot femoral nerve block for total hip arthroplasty: impact on early postoperative care, pain management and lung function. *Minerva Anestesiologica* 2014; **80**: 48–57.
52. Kratz T, Dette F, Schmitt J, Wiesmann T, Wulf H, Zoremba M. Impact of regional femoral nerve block during general anesthesia for hip arthroplasty on blood pressure, heart rate and pain control: A randomized controlled study. *Technology and Health Care* 2015; **23**: 313–22.
53. Kuchálik J, Magnuson A, Lundin A, Gupta A. Local infiltration analgesia or femoral nerve block for postoperative pain management in patients undergoing total hip arthroplasty. A randomized, double-blind study. *Scandinavian Journal of Pain* 2017; **16**: 223–30.
54. Nishio S, Fukunishi S, Juichi M, et al. Comparison of continuous femoral nerve block, caudal epidural block, and intravenous patient-controlled analgesia in pain control after total hip arthroplasty: a prospective randomized study. *Orthopedic Reviews* 2014; **6**: 5138.
55. Shariat AN, Hadzic A, Xu D, et al. Fascia iliaca block for analgesia after hip arthroplasty: a randomized double-blind, placebo-controlled trial. *Regional Anesthesia and Pain Medicine* 2013; **38**: 201–5.
56. Desmet M, Vermeulen K, Van Herreweghe I, et al. A longitudinal supra-inguinal fascia iliaca compartment block reduces morphine consumption after total hip arthroplasty. *Regional Anesthesia and Pain Medicine* 2017; **42**: 327–33.
57. Kearns R, Macfarlane A, Grant A, et al. A randomised, controlled, double blind, non-inferiority trial of ultrasound-guided fascia iliaca block vs. spinal morphine for analgesia after primary hip arthroplasty. *Anaesthesia* 2016; **71**: 1431–40.
58. Gasanova I, Alexander JC, Estrera K, et al. Ultrasound-guided suprainguinal fascia iliaca compartment block versus periarticular infiltration for pain management after total hip arthroplasty: a randomized controlled trial. *Regional Anesthesia and Pain Medicine* 2019; **44**: 206–11.
59. McGraw-Tatum MA, Groover MT, George NE, Urse JS, Heh V. A prospective, randomized trial comparing liposomal bupivacaine vs fascia iliaca compartment block for postoperative pain control in total hip arthroplasty. *Journal of Arthroplasty* 2017; **32**: 2181–5.
60. Perry CR Jr, Fahs AM, Kurdziel MD, Koueiter DM, Fayne RJ, Verner JJ. Intraoperative psoas compartment block vs preoperative fascia iliaca block for pain control after direct anterior total hip arthroplasty: a randomized controlled trial. *Journal of Arthroplasty* 2018; **33**: 1770–4.
61. Zhang X-Y, Ma J-B. The efficacy of fascia iliaca compartment block for pain control after total hip arthroplasty: a meta-analysis. *Journal of Orthopaedic Surgery and Research* 2019; **14**: 33.
62. Cai L, Song Y, Wang Z, She W, Luo X, Song Y. The efficacy of fascia iliaca compartment block for pain control after hip arthroplasty: a meta-analysis. *International Journal of Surgery* 2019; **66**: 89–98.
63. Gao Y, Tan H, Sun R, Zhu J. Fascia iliaca compartment block reduces pain and opioid consumption after total hip arthroplasty: a systematic review and meta-analysis. *International Journal of Surgery* 2019; **65**: 70–9.
64. Thybo KH, Mathiesen O, Dahl JB, Schmidt H, Hägi-Pedersen D. Lateral femoral cutaneous nerve block after total hip arthroplasty: a randomised trial. *Acta Anaesthesiologica Scandinavica* 2016; **60**: 1297–305.
65. Thybo KH, Schmidt H, Hägi-Pedersen D. Effect of lateral femoral cutaneous nerve-block on pain after total hip arthroplasty: a randomised, blinded, placebo-controlled trial. *BMC Anesthesiology* 2016; **16**: 21.
66. Bron JL, Verhart J, Sierevelt IN, De Vries D, Kingma HJ, Rademakers MV. No effect of double nerve block of the lateral cutaneous nerve and subcostal nerves in total hip arthroplasty. *Acta Orthopaedica* 2018; **89**: 272–7.
67. Fahs AM, Koueiter DM, Kurdziel MD, Huynh KA, Perry CR, Verner JJ. Psoas compartment block vs periarticular local anesthetic infiltration for pain management after anterior total hip arthroplasty: a prospective, randomized study. *Journal of Arthroplasty* 2018; **33**: 2192–6.
68. Johnson RL, Amundson AW, Abdel MP, et al. Continuous posterior lumbar plexus nerve block versus periarticular injection with ropivacaine or liposomal bupivacaine for total hip arthroplasty: a three-arm randomized clinical trial. *Journal of Bone and Joint Surgery* 2017; **99**: 1836–45.
69. Green C, Byrne AM, O'Loughlin P, Molony D, Harmon D, Masterson E. Surgeon delivered psoas compartment block in total hip arthroplasty. *Journal of Arthroplasty* 2014; **29**: 393–6.
70. Wardhan R, Auroux A-SM, Ben-David B, Chelly JE. Is L2 paravertebral block comparable to lumbar plexus block for postoperative analgesia after total hip arthroplasty? *Clinical Orthopaedics and Related Research* 2014; **472**: 1475–81.
71. Wilson SH, Auroux A-SM, Eloy JD, Merman RB, Chelly JE. Ropivacaine 0.1% versus 0.2% for continuous lumbar plexus nerve block infusions following total hip arthroplasty: a randomized, double blinded study. *Pain Medicine* 2014; **15**: 465–72.
72. Fredrickson MJ, Danesh-Clough TK. Spinal anaesthesia with adjunctive intrathecal morphine versus continuous lumbar plexus blockade: a randomised comparison for analgesia after hip replacement. *Anaesthesia and Intensive Care* 2015; **43**: 449–53.
73. Kukreja P, MacBeth L, Sturdivant A, et al. Anterior quadratus lumborum block analgesia for total hip arthroplasty: a randomized, controlled study. *Regional Anesthesia and Pain Medicine* 2019; **44**: 1075–9.
74. Auroy Y, Benhamou D, Bargues L, et al. Major complications of regional anesthesia in France: the SOS Regional Anesthesia Hotline Service. *Anesthesiology* 2002; **97**: 1274–80.
75. Kolaczko JG, Knapik DM, Salata MJ. Peri-operative pain management in hip arthroscopy: a systematic review of the literature. *Journal of Hip Preservation Surgery* 2019; **6**: 353–63.
76. Lunn TH, Husted H, Solgaard S, et al. Intraoperative local infiltration analgesia for early analgesia after total hip arthroplasty: a randomized, double-blind, placebo-controlled trial. *Regional Anesthesia and Pain Medicine* 2011; **36**: 424–9.
77. Dobie I, Bennett D, Spence DJ, Murray JM, Beverland DE. Periarticular local anesthesia does not improve pain or

- mobility after total hip arthroplasty. *Clinical Orthopaedics and Related Research* 2012; **470**: 1958–65.
78. Andersen LØ, Otte KS, Husted H, Gaarn-Larsen L, Kristensen B, Kehlet H. High-volume infiltration analgesia in bilateral hip arthroplasty. A randomized, double-blind placebo-controlled trial. *Acta Orthopaedica* 2011; **82**: 423–6.
 79. Hofstad JK, Winther SB, Rian T, Foss OA, Husby OS, Wik TS. Perioperative local infiltration anesthesia with ropivacaine has no effect on postoperative pain after total hip arthroplasty. *Acta Orthopaedica* 2015; **86**: 654–8.
 80. den Hartog YM, Mathijssen NMC, van Dasselar NT, Langendijk PNJ, Vehmeijer SBW. No effect of the infiltration of local anaesthetic for total hip arthroplasty using an anterior approach: a randomised placebo controlled trial. *Bone and Joint Journal* 2015; **97-B**: 734–40.
 81. Zoric L, Cuvillon P, Alonso S, et al. Single-shot intraoperative local anaesthetic infiltration does not reduce morphine consumption after total hip arthroplasty: a double-blinded placebo-controlled randomized study. *British Journal of Anaesthesia* 2014; **112**: 722–8.
 82. Hirasawa N, Kurosaka K, Nishino M, Nakayama T, Matsubara M, Tsukada S. No Clinically important difference in pain scores after total hip arthroplasty between periarticular analgesic injection and placebo: a randomized trial. *Clinical Orthopaedics and Related Research* 2018; **476**: 1837–45.
 83. Titman S, Hommel A, Dobrydnjov I, Johansson A. The efficacy of high volume of local infiltration analgesia for postoperative pain relief after total hip arthroplasty under general anaesthesia - a randomised controlled trial. *International Journal of Orthopaedic and Trauma Nursing* 2018; **28**: 16–21.
 84. Ban W-R, Zhang E-A, Lv L-F, Dang X-Q, Zhang C. Effects of periarticular injection on analgesic effects and NSAID use in total knee arthroplasty and total hip arthroplasty. *Clinics* 2017; **72**: 729–36.
 85. Busch CA, Whitehouse MR, Shore BJ, MacDonald SJ, McCalden RW, Bourne RB. The efficacy of periarticular multimodal drug infiltration in total hip arthroplasty. *Clinical Orthopaedics and Related Research* 2010; **468**: 2152–9.
 86. Murphy TP, Byrne DP, Curtin P, Baker JF, Mulhall KJ. Can a periarticular levobupivacaine injection reduce postoperative opiate consumption during primary hip arthroplasty? *Clinical Orthopaedics and Related Research* 2012; **470**: 1151–7.
 87. Chen DW, Hu C-C, Chang Y-H, Lee MS, Chang C-J, Hsieh P-H. Intra-articular bupivacaine reduces postoperative pain and meperidine use after total hip arthroplasty: a randomized, double-blind study. *Journal of Arthroplasty* 2014; **29**: 2457–61.
 88. Villatte G, Engels E, Erivan R, et al. Effect of local anaesthetic wound infiltration on acute pain and bleeding after primary total hip arthroplasty: the EDIPO randomised controlled study. *International Orthopaedics* 2016; **40**: 2255–60.
 89. Liu W, Cong R, Li X, Wu Y, Wu H. Reduced opioid consumption and improved early rehabilitation with local and intraarticular cocktail analgesic injection in total hip arthroplasty: a randomized controlled clinical trial. *Pain Medicine* 2011; **12**: 387–93.
 90. Nakai T, Nakamura T, Nakai T, Onishi A, Hashimoto K. A study of the usefulness of a periarticular multimodal drug cocktail injection for pain management after total hip arthroplasty. *Journal of Orthopaedics* 2013; **10**: 5–7.
 91. Tan NL, Gotmaker R, Barrington MJ. Impact of local infiltration analgesia on the quality of recovery after anterior total hip arthroplasty: a randomized, triple-blind, placebo-controlled trial. *Anesthesia and Analgesia* 2019; **129**: 1715–22.
 92. Ma H-H, Chou T-FA, Tsai S-W, Chen C-F, Wu P-K, Chen W-M. The efficacy of intraoperative periarticular injection in Total hip arthroplasty: a systematic review and meta-analysis. *BioMed Central Musculoskeletal Disorders* 2019; **20**: 269.
 93. Perets I, Walsh JP, Mu BH, et al. Intraoperative infiltration of liposomal bupivacaine vs bupivacaine hydrochloride for pain management in primary total hip arthroplasty: a prospective randomized trial. *Journal of Arthroplasty* 2018; **33**: 441–6.
 94. Aguirre J, Baulig B, Dora C, et al. Continuous epicapsular ropivacaine 0.3% infusion after minimally invasive hip arthroplasty: a prospective, randomized, double-blinded, placebo-controlled study comparing continuous wound infusion with morphine patient-controlled analgesia. *Anesthesia and Analgesia* 2012; **114**: 456–61.
 95. Fusco P, Cofini V, Petrucci E, et al. Continuous wound infusion and local infiltration analgesia for postoperative pain and rehabilitation after total hip arthroplasty. *Minerva Anestesiologica* 2018; **84**: 556–64.
 96. Solovyova O, Lewis CG, Abrams JH, et al. Local infiltration analgesia followed by continuous infusion of local anesthetic solution for total hip arthroplasty: a prospective, randomized, double-blind, placebo-controlled study. *Journal of Bone and Joint Surgery* 2013; **95**: 1935–41.
 97. Specht K, Leonhardt JS, Revald P, et al. No evidence of a clinically important effect of adding local infusion analgesia administered through a catheter in pain treatment after total hip arthroplasty. *Acta Orthopaedica* 2011; **82**: 315–20.
 98. Andersen KV, Nikolajsen L, Daugaard H, Andersen NT, Haraldsted V, Søballe K. Local infiltration analgesia is not improved by postoperative intra-articular bolus injections for pain after total hip arthroplasty. *Acta Orthopaedica* 2015; **86**: 647–53.
 99. Jules-Elysee KM, Goon AK, Westrich GH, et al. Patient-controlled epidural analgesia or multimodal pain regimen with periarticular injection after total hip arthroplasty. *Journal of Bone and Joint Surgery* 2015; **97**: 789–98.
 100. Pandazi A, Kanellopoulos I, Kalimeris K, et al. Periarticular infiltration for pain relief after total hip arthroplasty: a comparison with epidural and PCA analgesia. *Archives of Orthopaedic and Traumatic Surgery* 2013; **133**: 1607–12.
 101. Yan H, Cang J, Xue Z, Lu J, Wang H. Comparison of local infiltration and epidural analgesia for postoperative pain control in total knee arthroplasty and total hip arthroplasty: A systematic review and meta-analysis. *Bosnian Journal of Basic Medical Sciences* 2016; **16**: 239–46.
 102. Rikalainen-salmi R, Förster JG, Mäkelä K, et al. Local infiltration analgesia with levobupivacaine compared with intrathecal morphine in total hip arthroplasty patients. *Acta Anaesthesiologica Scandinavica* 2012; **56**: 695–705.
 103. Kuchálik J, Granath B, Ljunggren A, Magnuson A, Lundin A, Gupta A. Postoperative pain relief after total hip arthroplasty: a randomized, double-blind comparison between intrathecal morphine and local infiltration analgesia. *British Journal of Anaesthesia* 2013; **111**: 793–9.
 104. Jiang J, Teng Y, Fan Z, Khan MS, Cui Z, Xia Y. The efficacy of periarticular multimodal drug injection for postoperative pain management in total knee or hip arthroplasty. *Journal of Arthroplasty* 2013; **28**: 1882–7.
 105. Marques EMR, Jones HE, Elvers KT, Pyke M, Blom AW, Beswick AD. Local anaesthetic infiltration for peri-operative pain control in total hip and knee replacement: systematic review and meta-analyses of short- and long-term effectiveness. *BioMed Central Musculoskeletal Disorders* 2014; **15**: 1–20.
 106. Wang Y, Gao F, Sun W, Wang B, Guo W, Li Z. The efficacy of periarticular drug infiltration for postoperative pain after total hip arthroplasty: a systematic review and meta-analysis. *Medicine* 2017; **96**: e6401.
 107. Jiménez-Almonte JH, Wyles CC, Wyles SP, et al. Is local infiltration analgesia superior to peripheral nerve blockade for

- pain management after total hip arthroplasty: a network meta-analysis. *Clinical Orthopaedics and Related Research* 2016; **474**: 495–516.
108. Divella M, Cecconi M, Fasano N, et al. Pain relief after total hip replacement: oral CR oxycodone plus i.v. paracetamol versus epidural levobupivacaine and sufentanil. A randomized controlled trial. *Minerva Anestesiologica* 2012; **78**: 534–41.
 109. Banwait S, Sharma S, Pawar M, Garg R, Sood R. Evaluation of single epidural bolus dose of magnesium as an adjuvant to epidural fentanyl for postoperative analgesia: a prospective, randomized, double-blind study. *Saudi Journal of Anaesthesia* 2012; **6**: 273–8.
 110. Gendy HAE, El Gendy HA, Elsharnouby NM. Ultrasound guided single injection caudal epidural anesthesia of isobaric bupivacaine with/without dexamethasone for geriatric patients undergoing total hip replacement surgery. *Egyptian Journal of Anaesthesia* 2014; **30**: 293–8.
 111. Erol İM, Özdoğan L, Örnek D, et al. Effect of ketamine on the quality of anesthesia and postoperative analgesia in epidural anesthesia. *Journal of Experimental and Clinical Medicine* 2014; **6**: 83–9.
 112. Spreng UJ, Dahl V, Hjall A, Fagerland MW, Ræder J. High-volume local infiltration analgesia combined with intravenous or local ketorolac+morphine compared with epidural analgesia after total knee arthroplasty. *British Journal of Anaesthesia* 2010; **105**: 675–82.
 113. Damevski V, Damevska G, Palasevska L, Nojkov O. Postoperative intrathecal analgesia for primary total hip arthroplasty—comparative clinical examination of two different small doses of morphium hydrochloride. *Bratislavske Lekarske Listy* 2011; **112**: 497–500.
 114. Wang L, Bauer M, Curry R, Larsson A, Sessler DI, Eisenach JC. Intrathecal ketorolac does not improve acute or chronic pain after hip arthroplasty: a randomized controlled trial. *Journal of Anesthesia* 2014; **28**: 790–3.
 115. Samir EM, Badawy SS, Hassan AR. Intrathecal vs intravenous magnesium as an adjuvant to bupivacaine spinal anesthesia for total hip arthroplasty. *Egyptian Journal of Anaesthesia* 2013; **29**: 395–400.
 116. Koyano G, Jinno T, Koga D, Hoshino C, Muneta T, Okawa A. Is closed suction drainage effective in early recovery of hip joint function? Comparative evaluation in one-stage bilateral total hip arthroplasty. *Journal of Arthroplasty* 2015; **30**: 74–8.
 117. Kleinert K, Werner C, Mamisch-Saupe N, Kalberer F, Dora C. Closed suction drainage with or without re-transfusion of filtered shed blood does not offer advantages in primary non-cemented total hip replacement using a direct anterior approach. *Archives of Orthopaedic and Trauma Surgery* 2012; **132**: 131–6.
 118. Horstmann WG, Kuipers BM, Slappendel R, Castelein RM, Kollen BJ, Verheyen CCPM. Postoperative autologous blood transfusion drain or no drain in primary total hip arthroplasty? A randomised controlled trial. *International Orthopaedics* 2012; **36**: 2033–9.
 119. von Roth P, Perka C, Dirschedl K, et al. Use of Redon drains in primary total hip arthroplasty has no clinically relevant benefits. *Orthopedics* 2012; **35**: e1592–e1595.
 120. Barrett WP, Turner SE, Leopold JP. Prospective randomized study of direct anterior vs postero-lateral approach for total hip arthroplasty. *Journal of Arthroplasty* 2013; **28**: 1634–8.
 121. Christensen CP, Jacobs CA. Comparison of patient function during the first six weeks after direct anterior or posterior total hip arthroplasty: a randomized study. *Journal of Arthroplasty* 2015; **30**: 94–7.
 122. Zhao H-Y, Kang P-D, Xia Y-Y, Shi X-J, Nie Y, Pei F-X. Comparison of early functional recovery after total hip arthroplasty using a direct anterior or posterolateral approach: a randomized controlled trial. *Journal of Arthroplasty* 2017; **32**: 3421–8.
 123. Wang Z, Hou J-Z, Wu C-H, et al. A systematic review and meta-analysis of direct anterior approach versus posterior approach in total hip arthroplasty. *Journal of Orthopaedic Surgery and Research* 2018; **13**: 229.
 124. Putananon C, Tuchinda H, Arirachakaran A, Wongsak S, Narinsorasak T, Kongtharvonskul J. Comparison of direct anterior, lateral, posterior and posterior-2 approaches in total hip arthroplasty: network meta-analysis. *European Journal of Orthopaedic Surgery and Traumatology* 2018; **28**: 255–67.
 125. Mjaaland KE, Kivle K, Svenningsen S, Pripp AH, Nordsletten L. Comparison of markers for muscle damage, inflammation, and pain using minimally invasive direct anterior versus direct lateral approach in total hip arthroplasty: A prospective, randomized, controlled trial. *Journal of Orthopaedic Research* 2015; **33**: 1305–10.
 126. Dienstknecht T, Lüring C, Tingart M, Grifka J, Sendtner E. Total hip arthroplasty through the mini-incision (Micro-hip) approach versus the standard transgluteal (Bauer) approach: a prospective, randomised study. *Journal of Orthopaedic Surgery* 2014; **22**: 168–72.
 127. Müller M, Schwachmeyer V, Tohtz S, et al. The direct lateral approach: impact on gait patterns, foot progression angle and pain in comparison with a minimally invasive anterolateral approach. *Archives of Orthopaedic and Traumatic Surgery* 2012; **132**: 725–31.
 128. Müller M, Tohtz S, Winkler T, Dewey M, Springer I, Perka C. MRI findings of gluteus minimus muscle damage in primary total hip arthroplasty and the influence on clinical outcome. *Archives of Orthopaedic and Traumatic Surgery* 2010; **130**: 927–35.
 129. Inaba Y, Kobayashi N, Yukizawa Y, Ishida T, Iwamoto N, Saito T. Little clinical advantage of modified Watson-Jones approach over modified mini-incision direct lateral approach in primary total hip arthroplasty. *Journal of Arthroplasty* 2011; **26**: 1117–22.
 130. Della Valle CJ, Dittle E, Moric M, Sporer SM, Buvanendran A. A prospective randomized trial of mini-incision posterior and two-incision total hip arthroplasty. *Clinical Orthopaedics and Related Research* 2010; **468**: 3348–54.
 131. Smith TO, Blake V, Hing CB. Minimally invasive versus conventional exposure for total hip arthroplasty: a systematic review and meta-analysis of clinical and radiological outcomes. *International Orthopaedics* 2011; **35**: 173–84.
 132. Brismar BH, Hallert O, Tedhamre A, Lindgren JU. Early gain in pain reduction and hip function, but more complications following the direct anterior minimally invasive approach for total hip arthroplasty: a randomized trial of 100 patients with 5 years of follow up. *Acta Orthopaedica* 2018; **89**: 484–9.
 133. Khan RJK, Maor D, Hofmann M, Haebich S. A comparison of a less invasive piriformis-sparing approach versus the standard posterior approach to the hip: a randomised controlled trial. *Journal of Bone and Joint Surgery British* 2012; **94**: 43–50.
 134. Barsoum WK, Klika AK, Murray TG, Higuera C, Lee HH, Krebs VE. Prospective randomized evaluation of the need for blood transfusion during primary total hip arthroplasty with use of a bipolar sealer. *Journal of Bone and Joint Surgery* 2011; **93**: 513–8.
 135. Rothwell MP, Pearson D, Hunter JD, et al. Oral oxycodone offers equivalent analgesia to intravenous patient-controlled analgesia after total hip replacement: a randomized, single-centre, non-blinded, non-inferiority study. *British Journal of Anaesthesia* 2011; **106**: 865–72.
 136. Musclow SL, Bowers T, Vo H, Glube M, Nguyen T. Long-acting morphine following hip or knee replacement: a randomized,

- double-blind, placebo-controlled trial. *Pain Research and Management* 2012; **17**: 83–8.
137. Joppich R, Richards P, Kelen R, et al. Analgesic efficacy and tolerability of intravenous morphine versus combined intravenous morphine and oxycodone in a 2-center, randomized, double-blind, pilot trial of patients with moderate to severe pain after total hip replacement. *Clinical Therapeutics* 2012; **34**: 1751–60.
 138. Kim MK, Ahn SE, Shin E, Park SW, Choi J-H, Kang HY. Comparison of analgesic efficacy of oxycodone and fentanyl after total hip replacement surgery: a randomized controlled trial. *Medicine* 2018; **97**: e13385.
 139. Markmiller M, Weiß T, Kreuz P, Rüter A, Konrad G. Partial weightbearing is not necessary after cementless total hip arthroplasty. *International Orthopaedics* 2010; **35**: 1139–43.
 140. Ravnskog F-A, Espehaug B, Indrekvam K. Randomised clinical trial comparing hydrofiber and alginate dressings post-hip replacement. *Journal of Wound Care* 2011; **20**: 136–42.
 141. Zhao Z, Ma X, Ma J, Sun X, Li F, Lv J. A systematic review and meta-analysis of the topical administration of fibrin sealant in total hip arthroplasty. *Scientific Reports* 2018; **8**: 78.
 142. Lan F, Ma YH, Xue JX, Wang TL, Ma DQ. Transcutaneous electrical nerve stimulation on acupoints reduces fentanyl requirement for postoperative pain relief after total hip arthroplasty in elderly patients. *Minerva Anestesiologica* 2012; **78**: 887–95.
 143. Wang D, Yang Y, He C, et al. Effect of multiple doses of oral tranexamic acid on haemostasis and inflammatory reaction in total hip arthroplasty: a randomized controlled trial. *Thrombosis and Haemostasis* 2019; **119**: 92–103.
 144. Fraval A, Effeney P, Fiddelaers L, Smith B, Towell B, Tran P. OBTAIN A: outcome benefits of tranexamic acid in hip arthroplasty. a randomized double-blinded controlled trial. *Journal of Arthroplasty* 2017; **32**: 1516–9.
 145. Andersen LØ, Kehlet H. Analgesic efficacy of local infiltration analgesia in hip and knee arthroplasty: a systematic review. *British Journal of Anaesthesia* 2014; **113**: 360–74.
 146. Coenders MJ, Mathijssen NMC, Vehmeijer SBW. Three and a half years' experience with outpatient total hip arthroplasty. *Bone and Joint Journal* 2020; **102**: 82–9.
 147. Bai JW, Singh M, Short A, et al. Intrathecal morphine and pulmonary complications after arthroplasty in patients with obstructive sleep apnea. *Anesthesiology* 2020; **132**: 702–12.
 148. Albrecht E, Bayon V, Hirotsu C, Ja'bari A, Heinzer R. Intrathecal morphine and sleep apnoea severity in patients undergoing hip arthroplasty: a randomized, controlled, triple-blinded trial. *British Journal of Anaesthesia* 2020; **125**: 811–7.
 149. Fraser JF, Danoff JR, Manrique J, Reynolds MJ, Hozack WJ. Identifying reasons for failed same-day discharge following primary total hip arthroplasty. *Journal of Arthroplasty* 2018; **33**: 3624–8.
 150. Vuorinen MA, Palanne RA, Mäkinen TJ, Leskinen JT, Huhtala H, Huotari KA. Infection safety of dexamethasone in total hip and total knee arthroplasty: a study of eighteen thousand, eight hundred and seventy-two operations. *International Orthopaedics* 2019; **43**: 1787–92.
 151. Jørgensen CC, Pitter FT, Kehlet H. Lundbeck foundation center for fast-track hip and knee replacement collaborative group. Safety aspects of preoperative high-dose glucocorticoid in primary total knee replacement. *British Journal of Anaesthesia* 2017; **119**: 267–75.
 152. Skarin MU, Rice DA, McNair PJ, Kluger MT. Orthostatic intolerance following hip arthroplasty: incidence, risk factors and effect on length of stay: a prospective cohort study. *European Journal of Anaesthesiology* 2019; **36**: 123–9.
 153. Avidan MS, Maybrier HR, Abdallah AB, et al. Intraoperative ketamine for prevention of postoperative delirium or pain after major surgery in older adults: an international, multicentre, double-blind, randomised clinical trial. *Lancet* 2017; **390**: 267–75.
 154. Karlsen AP, Mathiesen O, Dahl JB. Heterogenic control groups in randomized, controlled, analgesic trials of total hip and knee arthroplasty. *Minerva Anestesiologica* 2018; **84**: 346–62.

Supporting Information

Additional supporting information may be found online via the journal website.

Table S1 Quality assessment and level of evidence assigned to the randomised trials included in this review.

Table S2 Summary of key results from randomised controlled trials evaluating systemic analgesics, systemic analgesic adjuncts, regional analgesia and surgical procedures in patients undergoing total hip arthroplasty.

Table S3 Summary of key results from studies evaluating systemic analgesics, regional analgesia, perineural analgesic adjuncts and surgical procedures used to support interventions that are not recommended for analgesic benefit in patients undergoing total hip arthroplasty.