



ISSN 2456-3110

Vol 3 · Issue 5

Sep-Oct 2018

Journal of Ayurveda and Integrated Medical Sciences

www.jaims.in

JAIMS



Charaka
Publications

Indexed

A Single Case Study on treatment of Ileocaecal Tuberculous Sinus with *Kadali Kshara Varti*

Dr. Sumera Afreen Fatima,¹ Dr. Shailaja S. V.²

¹Post Graduate Scholar, ²Professor & HOD, Dept. of Shalya Tantra, Sri Kalabyraveshwara Swamy Ayurvedic Hospital and Research Center, Bengaluru, Karnataka, INDIA.

ABSTRACT

Abdominal tuberculosis (TB) is an uncommon affliction in adolescence. It is usually associated with pulmonary tuberculosis. The disease is caused by lymphohaematogenous spread after primary infection in the lung or ingestion of infected sputum and has a typically nonspecific presentation. The occurrence of ileocaecal TB is probably from the contiguous spread of an abdominal focus or mesenteric lymph node. Ileocaecal TB is a rare entity, with very few reported cases in the literature. We report here a case of abdominal TB that manifested in the infection of an abdominal wall resulting in sinus at inguinal region and there by highlighting the Ayurvedic management of abdominal sinus by the use of *Kshara Varti*. *Kshara Varti* is the chief modality in the treatment in the Ayurvedic science and has been explained in *Nadivrana*.

Key words: Abdominal Tuberculosis, Ileocaecal Tuberculosis, Sinus, *Kshara Varti*.

INTRODUCTION

Abdominal TB is defined as TB infection involving the gastrointestinal tract, peritoneum, mesentery, abdominal lymph nodes and solid visceral organs such as liver, pancreas and spleen. It is sixth most common type of extra pulmonary TB, affecting primarily young adults. It is relatively rare in children. While the ileocecal junction is the most common site reported for abdominal TB, the peritoneum and lymph nodes are the most common sites involved in children with abdominal TB. *Mycobacterium tuberculosis* and *bovis* (transmitted through unpasteurized dairy products)

are the main pathogens involved. The diagnosis is often delayed because of its non-specific and protean clinical presentation.^[3] It is a condition that mimics a variety of inflammatory, infectious and neoplastic gastrointestinal diseases. Fever, abdominal pain and weight loss are the most common symptoms found in children with abdominal TB. There are three patterns of clinical presentation depending on the predominant symptoms, intestinal (colicky abdominal pain, vomiting and gaseous abdominal distension), peritoneal (abdominal distension and ascites) and asymptomatic. Our patient had evidence of abdominal TB, had symptoms like the swelling at right inguinal region later discharge from right inguinal region. The diagnosis was established with USG abdomen.

Delay in diagnosis of abdominal TB is associated with high morbidity and mortality, if left untreated.

PATIENT DETAILS

A 35 year old female patient by Hindu religion approached opd of SKAMCH & RC on 16-1-2018 for treatment.

Pradhana Vedana: Pain and pus discharge at the site of right lower abdomen since 1 month.

Address for correspondence:

Dr. Sumera Afreen Fatima

Post Graduate Scholar, Dept. of Shalya Tantra, Sri Kalabyraveshwara Swamy Ayurvedic Hospital and Research Center, Bengaluru, Karnataka, India.

E-mail: sumera.afreen2@gmail.com

Submission Date : 19/08/2018 Accepted Date: 29/09/2018

Access this article online

Quick Response Code



Website: www.jaims.in

DOI: 10.21760/jaims.v3i5.13849

Anubandha Vedana: Generalised weakness, loss of appetite, loss of weight

Vedana Vruttanta

The patient was apparently healthy one month back then gradually she noticed pus discharge from the previous surgical scar associated with pain and occasional fever with chills for which she consulted nearby clinic and took treatment (details not known).

The pain persisted and gets aggravated when patient use to do her house hold works and gets relief from pain on rest. More pus discharge noted on doing straineous works.

Fever was on and off more in the evening time.

Patient continued with the same treatment but she did not get any relief.

Hence she came to SKAMCH & RC, OPD of Shalya Tantra for further treatment

Poorva Vyadhi Vruttanta: N/K/C/O - DM and HTN

Kautumbika Vruttanta: All family members are said to be healthy except patient.

Poorva Chikitsa Vruttanta:

On 8-8-2016, patient consulted Victoria hospital with complaints of persistent pain abdomen (right inguinal region) where CT Scan was done which revealed ileocaecal wall thickening with mesenteric lymphadenopathy.

Later colonoscopy was done on 20-8-2016 and condition was diagnosed as abdominal tuberculosis after biopsy (reports not available) for which treatment was started.

- Injection Streptomycin 15mg IM, weekly twice for 4 weeks
- AKT4 - 6 months
- AKT3 - 3 months

Patient noticed painful swelling in inguinal region after 3 months of complete treatment for which she consulted SKAMCH & RC and was advised USG abdomen on 23-8-2017, and reports were suggestive

of right inguinal hernia for which she was posted EUA followed by surgery.

The abdomen was opened and, it was found that there was no hernials ac, instead pus collection was found which was drained out and enlarged lymph node was excised.

The HPE impression was granulomatous inflammation suggestive of tuberculosis.

- ATT started
- Inj Streptomycin twice a week for two weeks
- AKT4 - 6 months
- Alternate day wound dressing was done.

Advice on Discharge

- To continue ATT
- Ashwagandha Rasayana - 2tsp bd with milk for 2 months.
- Syp Mannol - 3tsp bd with milk, for 1 month.

On 23 oct 2017, patient noticed pus discharge from previous surgical scar.

USG was done and impression was collection in the right iliac fossa. Small incision was made under local anaesthesia and collection was drained out. The patient was advised regular dressing on alternate days. The pus discharge persisted for which MRI was done on 16-12-2017, and impression was sinus tract draining exteriorly, for which treatment was planned accordingly.

On Examination

Lean built, poorly nourished, Pallor - Absent, Oedema - Absent, Icterus - absent, Cyanosis - absent, lymph nodes - not palpable.

Systemic Examination

Respiratory system: NVBS heard.

Cardiovascular system: S1 & S2 heard.

Gastrointestinal system: P/A - soft, non-tender, BS ++.

Examination of Sinus^[4]

Inspection

Position - right inguinal region

Number - 1

Discharge - Pus discharge - profuse

Opening of sinus - wide and the margin is thin blue

Surrounding skin - Inflammatory

Palpation

1. Tenderness - present

2. Wall of the sinus - not thick

3. Mobility - mobile

Examination of lymph nodes : Regional lymph nodes were not palpable.

Examination with a probe

- Under all aseptic precautions probing was done.
- The depth of the sinus was approx 3 inches, width - 2.5 cm diameter.
- Direction of the sinus - oblique towards median plain and extending from skin down to the deeper tissues.
- Pus stain noted on probe

Prayoga Shaala Pareeksha (Investigations)

Date	Complaints	Investigation	Impression
8-8-2016	Persistent abdomen pain	CT - Scan	Ileocaecal wall thickening with lymphadenopathy
20-8-2016	-do-	Coloscopy with biopsy	Abdominal tuberculosis
23-8-2017	Painful swelling in inguinal region	USG abdomen and pelvis	Direct inguinal hernia
29-8-2017	-do-	Lymph node biopsy	Granulomatous inflammation

23-10-2017	Pain abdomen, pus discharge	USG abdomen	Collection in right iliac fossa
16-12-2017	Pus discharge	MRI of pelvis	Iliopsoas abscess with sinus tract draining exteriorly

Lab investigation

Hb - 11.3gm%, TC - 8960 cells/cubic mm, Bleeding time - 2min 30sec, Clotting time - 4min 30 sec, Random Blood Sugar - 109mg/dl, HBsAG - Non reactive, HIV 1 & 2 - Non reactive, ESR - 40mm/Hour, ECG - Normal.

Vyavachhedaka Nidana / Differential Diagnosis

Vataja Nadi Vrana, Pittaja Nadi Vrana, Kaphaja Nadi Vrana, Shalyaja Nadi Vrana, Osteomyelitis, Actinomycosis, Tuberculous Fistula, Sinus of ileocaecal tuberculosis with lymphadenitis.

Vyadhi Vinishchaya

Shalyaja Nadi Vrana / Sinus of ileocaecal tuberculosis with lymphadenitis

Chikitsa advised - Kadali Kshara Varti



Procedure of Kshara Varti

The Kshara Varti was prepared with Kadali Kshara as per standard protocol^[5] was used and the drug used for treatment explained under one among the Kshara Dravya in classics.^[6]

Kshara Varti was prepared by as follows,

- 4-5 strands of gauge was taken.
- Mrudu Kadali Kshara was smeared over the strands of gauge and a wick was prepared.
- And kept for drying in the Kshara Sutra cabinet.

Then,

- Patient was made to lie down in left lateral position.
- The part was cleaned with betadine solution.
- Then probing was done to assess the depth of the sinus.
- Then pus was drained out followed by insertion of Kadali Kshara Varti of appropriate length.
- Then dressing was done.
- Patient was advised to come for dressing on every 3rd day.

Internal medications given

1. Tab. Triphala Guggulu 2 - 0 - 2 AF with warm water for 1 month
2. Tab. Gandhaka Rasayana 1 - 1 - 1 AF with warm water for 1 month
3. Patient was advised to come on every 3rd day for Varti insertion.

Observations during the course of treatment till recovery

- Excess pus discharge noted from sinus tract initially.
- Pain, Pus, discharge, foul smell and tenderness all reduced gradually.
- The length of the sinus reduced considerably.
- Symptoms resolved.

Observation Table

Date	Pain	Pus discharge	Foul smell	Tenderness
16-1-2018	++	+++	+++	++
23-1-	++	+++	+++	++

2018				
30-1-2018	++	++	++	++
7-2-2018	+	+	+	+
13-2-2018	+	-	-	-
20-2-2018	-	-	-	-
27-2-2018	-	-	-	-
11-4-2018	-	-	-	-

Fig. 1: Observation before Kshara Varti insertion

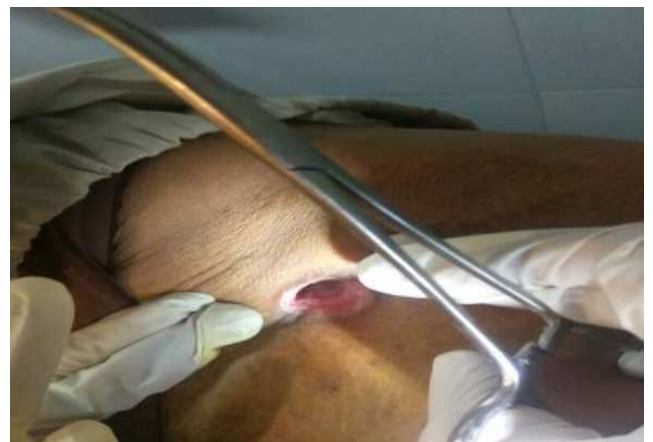

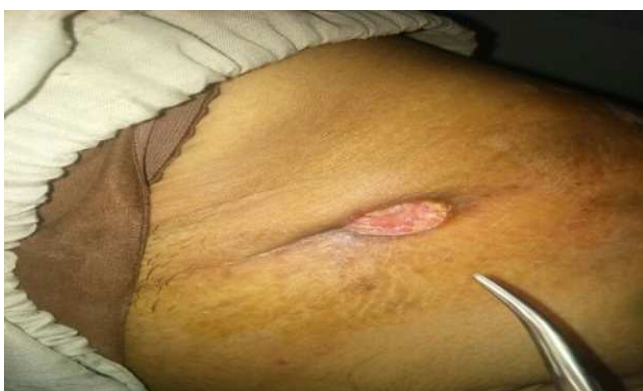
Fig. 2: Kshara Varti insertion

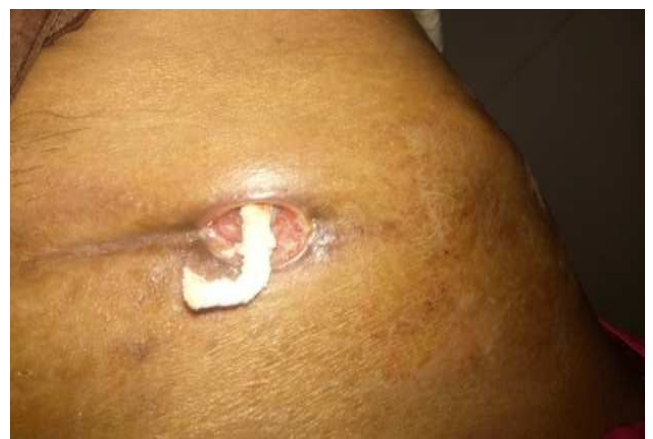

Fig. 3, 4, 5: Gradual healing after *Kshara Varti* insertion

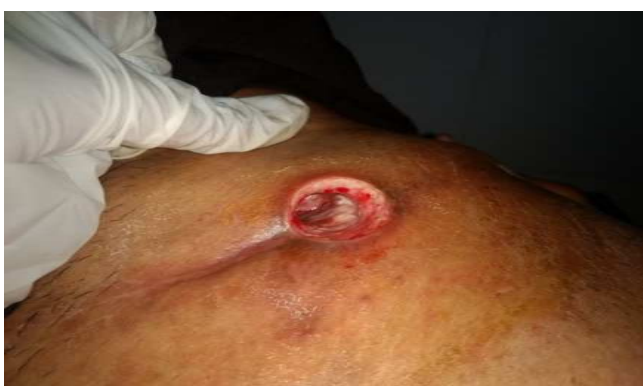
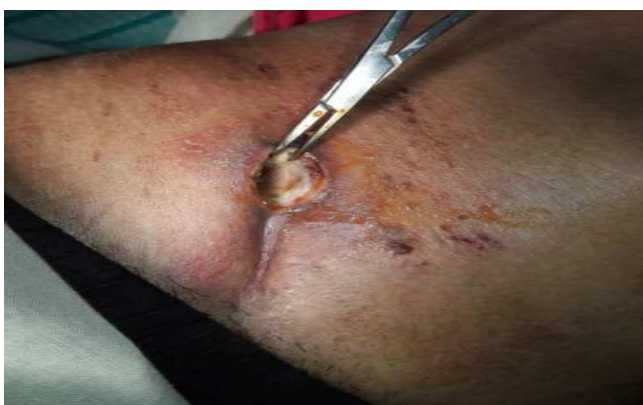
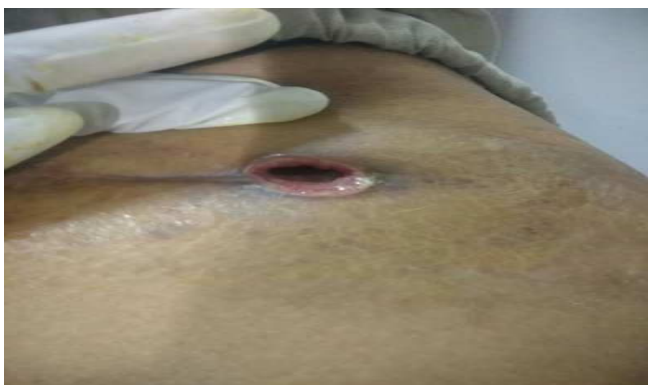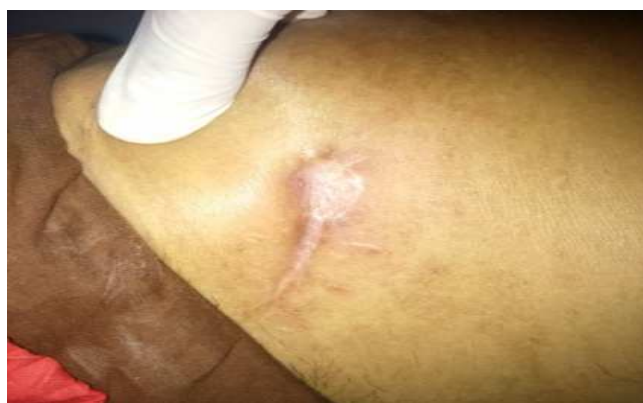Fig. 6: Observation on 20-2-2018



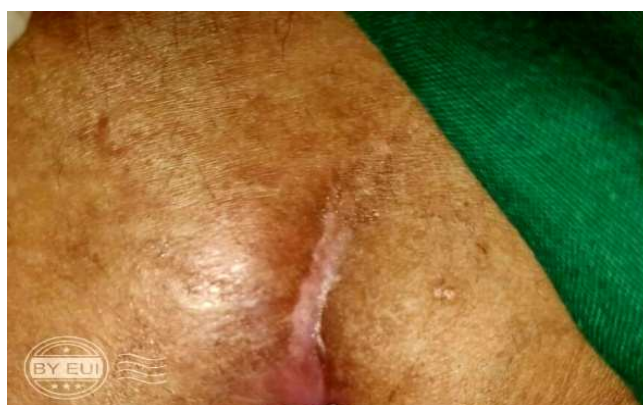
- Noticed healthy granulation tissue around the sinus cavity.
- No pus discharge.
- Mild pain.
- From here onwards varti insertion was stopped and *Jatyadi Taila* dressing was done.

Fig. 7: Observation on 9-5-2018



- Healing sinus tract.
- No opening
- No discharge
- Relief from symptoms

Fig. 8: Observation on 10-7-2018



- Sinus tract completely healed
- Relief from symptoms

DISCUSSION

Mode of action of *Ksharavarti* in sinus secondary to abdominal tuberculosis: By application of *Kshara Varti*

it does the *Shodhana* (cleansing)^[7] of the pus discharge which helps in *Ropana* (healing).^[8] The medicaments which are used to prepare the *Varti* will slough out the fibrous tissue of the track (debridement by the *Ksharana* process) and stimulates the healthy granulation tissue for healing.

CONCLUSION

The present study highlights the benefits of *Kadali Kshara Varti* with a marked reduction of symptoms to pain, irritation, inflammation, pus discharge. Complete healing of tuberculous sinus occurred by 5 months without any complications. The procedure throughout its course was safe without causing any significant discomfort to the patient.

REFERENCES

1. Sushruta Samhita with commentary of Dalhana, edited by Vaidya Jadavaji Trikamji Acharya, Chowakhamba Surbharti Prakashan, Varanasi, reprint, Chikitsa Sthana, 1st Chapter, Verse, 2009; 44: 824-401.
2. Sushruta Samhita with commentary of Dalhana, edited by Vaidya Jadavaji Trikamji Acharya, Chowakhamba Surbharti Prakashan, Varanasi, reprint, Nidana Sthana, 10th Chapter, and Verse, 2009; 29-33: 824-307,308.
3. SRB'S Manual of Surgery by Srirambhatrao, 3rd edition 2009, published by Jitendar P Vij, 11th chapter, 1198-512.
4. A manual on clinical surgery by Dr. S Das ,9th edition august 2011, published by Dr S Das , 5th chapter, 650-76,77,78 .
5. SK Sharma, KR Sharma and Kulwant Singh: Kshara Sutra Therapy in Fistula-in-ano And other Ano- Rectal Disorders, R.A.V. publications, Publishaed by Rashtriya Ayurveda Vidyapeeth (National Academy of Ayurveda Autonomous Body under the Ministry of Health and Family Welfare Govt. of India Road No.66 Punjabi Bagh (West), New Delhi-110026, 05th chapter, 1994-95; 221: 43-59.
6. Sushruta: Sushruta Samhita with commentary of Dalhana, edited by Vaidya Jadavaji Trikamji Acharya, Chowakhamba surbharti prakashan, Varanasi, reprint, sutra Sthana, 11th Chapter, Verse, 2009; 11: 824-47
7. Sushruta: Sushruta Samhita with commentary of Dalhana, edited by Vaidya Jadavaji Trikamji Acharya, Chowakhamba surbharti prakashan, Varanasi, reprint, Chikitsa Sthana, 1st Chapter, Verse, 2009; 9: 824-398.
8. Sushruta: Sushruta Samhita with commentary of Dalhana, edited by Vaidya Jadavaji Trikamji Acharya, Chowakhamba surbharti prakashan, Varanasi, reprint, Chikitsa Sthana, 1st Chapter, Verse, 2009; 9: 824-398.

How to cite this article: Dr. Sumera Afreen Fatima, Dr. Shailaja S. V. A Single Case Study on treatment of Ileocaecal Tuberculous Sinus with Kadali Kshara Varti. J Ayurveda Integr Med Sci 2018;5:225-230. <http://dx.doi.org/10.21760/jaims.v3i5.13849>

Source of Support: Nil, **Conflict of Interest:** None declared.
