



ISSN 2456-3110

Vol 3 · Issue 3

May-June 2018

Journal of
**Ayurveda and Integrated
Medical Sciences**

www.jaims.in

JAIMS



Charaka
Publications

Indexed

Unilateral variation in branching pattern of Right Axillary Artery - A Case Report

Dr. B Muraleedhar,¹ Dr. Chandrasekar Kuppi²

¹Associate Professor & Head, Dept. of Shareera Rachana, Grameena Ayurvedic Medical College, Terdal, Tq. Jamkhandi Dist. Bagalkot, ²Secretary, Professor & Head, Dept. of Rasashastra and Baishajya Kalpana, Sharada Ayurvedic Medical College, Yadagiri, Karnataka, INDIA.

ABSTRACT

The Axillary artery is the continuation of the subclavian artery and is a major artery of the upper limb. During the routine dissection for Undergraduate Ayurvedic Medical Students of Sharada Ayurvedic Medical College, Yadgir, Karnataka, India, in the Department of Anatomy, we come across a variation in branching pattern of second and third part of right axillary artery in male cadaver approximately 55 years of age. The first part of axillary artery was found to be normal. In the second part of axillary artery we observed two branches, first one is thoracoacromial artery arose as usual second branch given common trunk which is further divided into lateral thoracic artery and subscapular artery. Even third part of axillary artery gave one common trunk that terminated by bifurcating into Anterior Circumflex Humeral Artery and Posterior Circumflex Humeral Artery.

Key words: Axillary Artery, Thoraco-Acromial Artery, Anterior And Posterior Circumflex Humeral Artery, Common Trunk, , Subscapular Artery, Lateral Thoracic Artery.

INTRODUCTION

The Axillary artery is the continuation of the subclavian artery and is a major artery of the upper limb. It enters the axilla by passing behind the approximately midpoint of the clavicle on the outer border of the first rib and later terminates as the brachial artery at the lower boarder of teres major. It is divided into three parts by its relation to the pectoralis minor and gives six branches. First part of axillary artery is proximal to pectoralis minor and it

has one branch i.e. superior thoracic artery. Second part axillary artery is posterior to pectoralis minor and it has two branches, thoracoacromion artery which pierces the clavipectoral fascia and lateral thoracic artery. Third part of axillary artery is distal to pectoralis minor and it has three branches, subscapular artery, anterior circumflex humeral artery and posterior circumflex humeral artery.^[1]

CASE REPORT

During periodic dissection of an approximately 55 years old male cadaver for Ayurvedic Undergraduate in the department of Anatomy (*Shareera Rachana*) at Sharada Ayurvedic Medical College, Yadgir, Karnataka, India, a variation in the branching pattern of right axillary artery was observed. Dissection was carried out as per Cunningham practical manual. The first part of axillary artery was found to be normal and that given one branch that is superior thoracic artery. Variation was observed in the second and third part of axillary artery. In the second part of axillary artery, we observed mainly two branches, first one is thoracoacromial artery and second one is common

Address for correspondence:

Dr. B. Muraleedhar

Associate Professor & Head, Dept. of Shareera Rachana, Grameena Ayurvedic Medical College, Terdal, Tq. Jamkhandi, Dist. Bagalkot, Karnataka, INDIA.

E-mail: anatomymuralee@gmail.com

Submission Date: 22/05/2018 Accepted Date: 27/06/2018

Access this article online

Quick Response Code

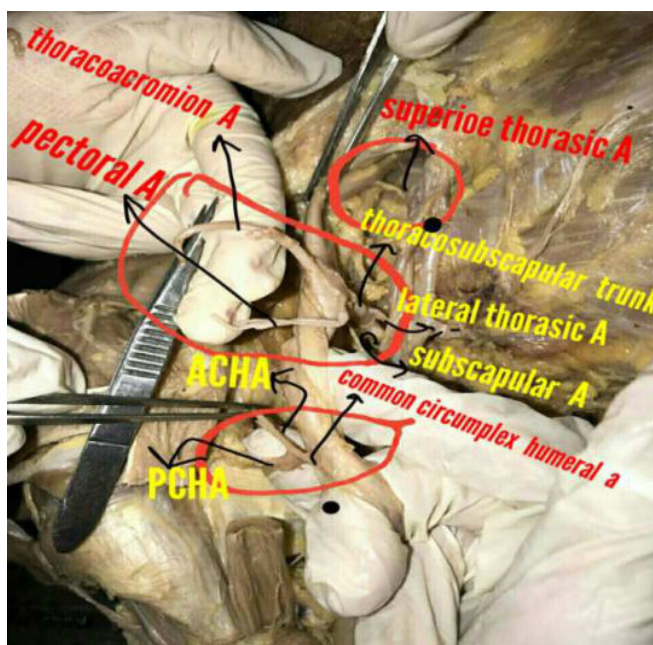


Website: www.jaims.in

DOI: 10.21760/jaims.v3i3.12905

trunk. Thoracoacromion artery arose as usual but gave three branches namely clavicular branch, acromion branch, deltoid branch, instead of four, the fourth branch that is Pectoral branch arose near to root of thoracoacromial artery. The common trunk was originated from the second part of right axillary artery which further divided into two branches; they are lateral thoracic artery and subscapular artery which usually emerges from third part of axillary artery. Subscapular artery later gave two branches as circumflex scapular artery and thoraco dorsal artery. In the third part of axillary artery we have observed that only one common trunk was originated and further bifurcating into Anterior Circumflex Humeral Artery and Posterior Circumflex Humeral Artery. First part of axillary artery gave one branch and second part gave two branches, third part gave only one branch in the present case study.

Figure 1: Axillary Artery branching pattern variation.



DISCUSSION

Anomalies in axillary artery with regard to origin, course and branching patterns are not frequent. During embryogenesis the lateral branch of seventh cervical inter segmental artery becomes enlarged to form the axial artery of upper limb which on further development becomes axillary, brachial, its bud gives rise to radial and ulnar arteries.^{[2],[3]}

Arey LB observed that, the unusual blood vessels may be due to,

1. The choice of unusual paths in primitive vascular plexuses.
2. The persistence of vessels which are normally obliterates.
3. The disappearance of vessels which are normally retained
4. Incomplete development and fusion and absorption of the parts which are usually distinct.^[4]

Samta *et.al.* reported that out of 50 cases, in 36 (68%) cases having classic pattern of branching and 14 (28%) cases having variation in branching pattern of axillary artery. Second part of axillary artery shows 12% and third part of axillary artery shows 16% Variation. In 30% of cases, subscapular artery can arise from a common trunk with posterior circumflex humeral artery. Occasionally the subscapular, circumflex humeral and profunda brachii arteries arise in common trunk and also observed that in 4% cases posterior circumflex humeral artery is a large trunk arises with the subscapular artery.^[5] In our present case we observed variation in second and third part of axillary artery.

Swamy Ravindra Shantakumar and K. G. Mohandas Rao reported that the first part of axillary artery gave rise to superior thoracic artery as usual, but the second part gave a common trunk which divided into the lateral thoracic and subscapular arteries. The third part of the artery gave origin to anterior and posterior circumflex humeral arteries.^[6] This study is very close to our present case observation, but only difference is that, in our study anterior and posterior circumplex arteries originated from common trunk but Swamy Ravindra *et.al.* has reported that they originated separately from third part of axillary artery.

Rajesh astik *et.al.* 2012 dissected eighty upper limbs. They found six different arteries. The lateral thoracic artery arose from subscapular artery in nine cadavers, unilaterally in two cases and bilaterally in seven cases. Absence of thoracoacromial artery trunk with origin of

all branches was directly from axillary artery bilaterally in three cases. A division of thoracoacromial trunk give rise to deltoacromial and claviopectoral trunks in these cadavers. From third part of axillary artery, a common trunk gave origin to anterior and posterior circumflex humeral arteries, subscapular arteries and profundabrachii arteries in five cadavers double posterior circumflex humeral artery was found.^[7]

In the present case report, we observed the variation in second and third part of axillary artery to the second part of axillary artery, thoracoacromial artery arose as usual but gave three branches instead of four and the fourth branch arose near to thoracoacromial artery. There also arose a common trunk from the second part which gave two branches, they are lateral thoracic artery and subscapular artery. Subscapular artery later gave two branches as circumflex scapular artery and thoraco dorsal artery.

CONCLUSION

The knowledge of these variations is necessary for the surgeons considering the frequency of procedures performed in this region, while vascular surgeons performing interventional or diagnostic procedures in cardiovascular diseases, radiologist in imaging techniques, in carrying out surgical and anaesthetic procedures involving axillary artery. Second knowledge of axillary artery variation is important for surgeons next to the popliteal artery; the axillary artery is more frequently lacerated by violence than any other injury. It is found to be ruptured in an attempt to reduce old dislocations, especially when artery is adherent to articular capsule.

REFERENCES

1. Susan standing. Pectoral girdle, Shoulder region and axilla in the anatomical basis of clinical practice, Gray's Anatomy.40th ed.London: Churchill Livingstone 2008.p.817.
2. Tan C B, Tan C K. An unusual course and relations of the human axillary artery. Singapore Med J 1994; 35: 263-264.
3. Jurjus AR, Correa-De-Aruaujo R, Bohn RC. Bilateral double axillary artery: embryological basis and clinical implications. Clin Anat 1999; 12:135-140.
4. Arey LB. Developmental Anatomy.6th ed. Philadelphia, W.B.Saunders. 1957;375-77.
5. S. Gaur, S. K. Katariya, H. Vaishnani et al., "A cadaveric study of branching pattern of the axillary artery," International Journal of Biological and Medical Research, vol. 3, no. 1, pp. 1388-1391, 2012.
6. Swamy Ravindra Shantakumar and K. G. Mohandas Rao, "Variant Branching Pattern of Axillary Artery: A Case Report," Case Reports in Vascular Medicine, vol. 2012, Article ID 976968, 3 pages, 2012.
7. ASTIK, Rajesh and DAVE, Urvi.Variations in branching pattern of the axillary artery: a study in 40 human cadavers. *J. vasc. bras.* [online]. 2012, vol.11, n.1, pp.12-17. ISSN 1677-5449. <http://dx.doi.org/10.1590/S1677-54492012000100003>.

How to cite this article: Dr. B Muraleedhar, Dr. Chandrasekar Kuppi. Unilateral variation in branching pattern of Right Axillary Artery - A Case Report. *J Ayurveda Integr Med Sci* 2018;3:237-239. <http://dx.doi.org/10.21760/jaims.v3i3.12905>

Source of Support: Nil, **Conflict of Interest:** None declared.
