

A Rare Case of Mesenteric Trauma after a Clandestine Abortion in Morocco

Et-Tayab Ouazzani^{a*}, Younes Hamdouni^b, Tarik Souiki^c, Imane Toughrai^d,
karim ibn Majdoub^e, EL bachir Benjelloun^f, khalid Mazaz^g

^{a,b,c,d,e,f,g}General Surgery Department, Hassan II university Hospital, Fes, Morocco

^aEmail: docteur.ouazzani@gmail.com

^bEmail: dryounes1983@gmail.com

^cEmail: souikit@yahoo.fr

^dEmail: thoughimane@gmail.com

^eEmail: ibnmajdoubkarim@gmail.com

^fEmail: benjelloun19@gmail.com

^gEmail: khali.mazaz@gmail.com

Abstract

In Morocco abortion is illegal; this is why the termination of pregnancy is performed in unsafe conditions which may lead to uterine perforation, mesenteric trauma, uncontrolled hemorrhage and even death. The small bowel is the most commonly injured due to its pelvic location and mobility. We report a case of 28-year-old nulliparous married female who presented to the emergency department after a failed abortion procedure. We performed haemostatic suture of the uterine lesion then resection of the injured distal bowel, and then a stoma was confected. The patient was discharged after 2 weeks of hospitalisation. Three months later; the stoma reversal surgery was done without complication. This case underlines the need for a regulation of a safe abortion in the world.

Keywords: Mesenteric Trauma; clandestine abortion; surgical emergency.

1. Introduction

Unsafe abortion is defined by the world health organization WHO as a procedure meant to terminate an unintended pregnancy that is performed by individuals without the necessary skills, or in an environment that does not conform to the minimum medical standards, or both [1].

* Corresponding author.

Various types of complications after uterine perforation have been reported but the mesenteric trauma is rarely disclosed in the literature review. This kind of complication is a really a surgical emergency.

2. Case report

We report a case of 28-year-old nulliparous married female who presented to the emergency department after a clandestine abortion procedure occurred by untrained medical doctor. The patient was hemodynamically unstable with tachycardia (heart rate of 140 pulses/min) , hypotension 90/60 mmHg and a Glasgow score of 13. We admitted her directly to the operation room .The exploratory laparotomy revealed a uterine perforation with a of 1.2 meter devitalization of the distal bowel .The mesentery was still bleeding (figure 1, 2). Firstly we performed a haemostatic suture of the mesentery, then reparation of the uterine lesion, followed by resection of the necrotic small bowel with an ileostomy placed in the right iliac fossa. The patient was discharged after 2 weeks in stable condition .Three months later; the stoma reversal surgery was done without complication.

3. Discussion

In the world, 45% of all abortions occurred every year is unsafe referred to the latest statistics of the WHO realized between 2010 and 2014 and 97% done in developing countries in Asia, Latin America and Africa . In developed regions, it is estimated that 30 women die for every 100 000 unsafe abortions. That number rises to 220 deaths per 100 000 unsafe abortions in developing regions and 520 deaths per 100 000 unsafe abortions in sub-Saharan Africa [1]. In countries like Morocco where abortion still not legalized, women forced to approach paramedical workers or traditional healer to get rid of unwanted pregnancy. Uterine perforation and bowel injuries are the most dreaded complications that arise after unsafe abortion. Intestinal injury can occur in form of perforation, hematoma, contusion or transection. Mesenteric injury is one of the rarest complications reported so far. Bowel perforation is a rare but serious complication of surgical abortion, which is usually seen when abortion is performed illegally by untrained persons [2]. The bowel may be injured with the uterine curette, ovum forceps, uterine sound, or even the plastic cannula. Bowel perforation occurs when the posterior vaginal wall or uterus is perforated, allowing the instrument to pierce the underlying structures [3]. The most commonly injured portions of the bowel is the ileum and sigmoid, due to their pelvic location [4]. In the present case, the mesenteric was injured by the uterine curette after the perforation of the uterine cavity. There are two types of pathophysiologic processes to explain the clinical presentation: small bowel obstruction and the mesenteric or uterine bleeding. The diagnosis is performed in preoperative examination if the patient conducted directly to the operation room or by the CT scan if she is hemodynamically stable [5]. In our case the diagnosis is quickly suspected because we had a shocked patient with uterine bleeding and an acute abdomen. There are a lot of difficulties to characterize the lesions that require surgical repair and in order to avoid operative delay, surgical exploration is carried out systematically for the least suspicion of intestinal and mesenteric injury. Surgical intervention for all hemodynamically stable patients with suspected bowel or mesenteric injury has led to a high rate of non-therapeutic laparotomy up to 44% for intestinal lesions and up to 31% for mesenteric injuries [6]. In our university hospital we don't use laparoscopy for emergencies so the laparotomy is the only method to treat this kind of surgical emergencies. The restoration of the bowel continuity depends upon patient condition and the duration of the peritoneal contamination. In most cases, one stage repair or resection with restoration of

continuity can be performed for both small intestinal and colonic lesions [7]. If there is any delay in surgical intervention, a stoma is preferable; especially in cases of colonic perforation [8] in our case we had performed a stoma of the small bowel because the patient was shocked so the risk for a post-operative peritonitis for anastomotic leak was high.

4. Conclusion

Mesenteric trauma after an unsafe abortion is a surgical emergency so in most cases the diagnosis is performed after an exploratory laparotomy in a shocked patient. The bowel and mesenteric injuries may result from direct luminal trauma after uterine perforation or secondarily from vascular interruption or infection [9]. To avoid all fatal consequences of this public health problem we need not only to legalize abortion but also to spread information and awareness of a safe pregnancy termination and try to improve the quality of the health system of the developing countries.

5. Recommendations

- the first recommendation should be a regulation of a safe termination of pregnancy
- the diagnostic algorithm depends of the clinical presentation of the patient.
- Emergency laparotomy/laparoscopy is necessary to prevent the progressive bowel distention with ensuing ischemic necrosis and/or subsequent perforation of the bowel.
- The population of these patients is young, mostly without comorbidities and can compensate significant pathophysiologic stress such as small bowel obstruction and/or perforation sometimes accompanied by various degrees of hemorrhage.

References

- [1]. Bela Ganatra, Caitlin Gerds, Clémentine Rossier, Brooke Ronald Johnson, Özge Tunçalp, Anisa Assifi, Gilda Sedgh, Susheela Singh, Akinrinola Bankole, Anna Popinchalk, Jonathan Bearak, Zhenning Kang, Leontine Alkema, Global, regional, and subregional classification of abortions by safety, 2010–14: estimates from Bayesian hierarchical model, *The Lancet*, Volume 390, Issue 10110, 2017, Pages 2372-2381, ISSN 0140-6736, [https://doi.org/10.1016/S0140-6736\(17\)31794-4](https://doi.org/10.1016/S0140-6736(17)31794-4).
- [2]. Jhobta RS, Attri AK, Jhobta A. Bowel injury following induced abortion. *Int J Gynaecol Obstet.* 2007;7(1):24-27
- [3]. Coffman S. Bowel injury as a complication of induced abortion. *Am Surg.* 2001;7(10):924-26
- [4]. Osime U. Intestinal injury following induced abortion. "A report of 4 cases" *Nig Med J.* 1978;7(4):378-80.
- [5]. Augustin G, Majerović M, Luetić T. Uterine perforation as a complication of surgical abortion causing small bowel obstruction: a review. *Arch Gynecol Obstet.* 2013 Aug;288(2):311-23. doi: 10.1007/s00404-013-2749-4. Epub 2013 Feb 12. PMID: 23400356.
- [6]. Killeen KL, Shanmuganathan K, Poletti PA, Cooper C, Mirvis SE. Helical computed tomography of bowel and mesenteric injuries. *J Trauma.* 2001 Jul;51(1):26-36. doi: 10.1097/00005373-200107000-

00005. PMID: 11468463

- [7]. Renz BM, Feliciano DV. Unnecessary laparotomies for trauma: a prospective study of morbidity. *J Trauma*. 1995 Mar;38(3):350-6. doi: 10.1097/00005373-199503000-00007. PMID: 7897713.
- [8]. Stefanou CK, Stefanou SK, Tepelenis K, Flindris S, Tsiantis T, Spyrou S. A big mesenteric rupture after blunt abdominal trauma: A case report and literature review. *Int J Surg Case Rep*. 2019;61:56-59. doi: 10.1016/j.ijscr.2019.06.041. Epub 2019 Jul 9. PMID: 31336242; PMCID: PMC6656956.
- [9]. Scott M. Kambiss, DO, Milo L. Hibbert, MD, Christian Macedonia, MD, Mark E. Potter, MD, Uterine Perforation Resulting in Bowel Infarction: Sharp Traumatic Bowel and Mesenteric Injury at the Time of Pregnancy Termination, *Military Medicine*, Volume 165, Issue 1, January 2000, Pages 81–82, <https://doi.org/10.1093/milmed/165.1.81>

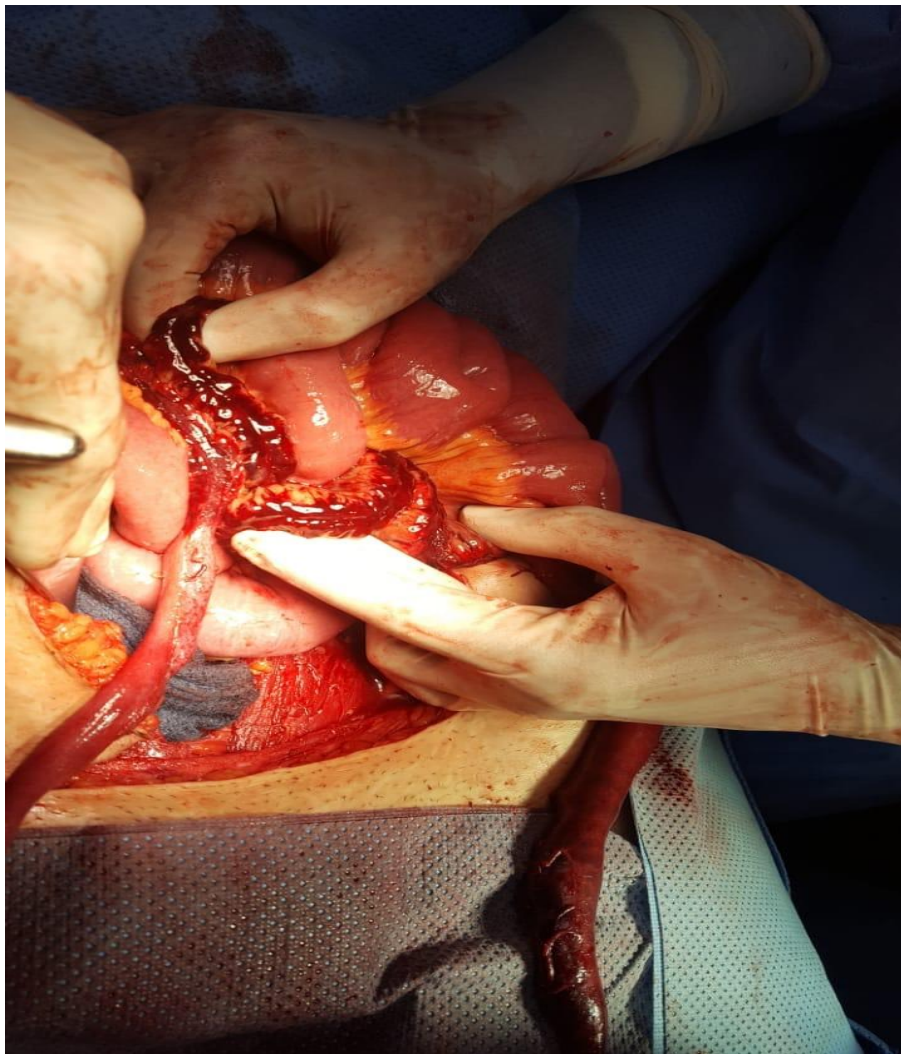


Figure 1: Preoperative image of the mesenteric injury

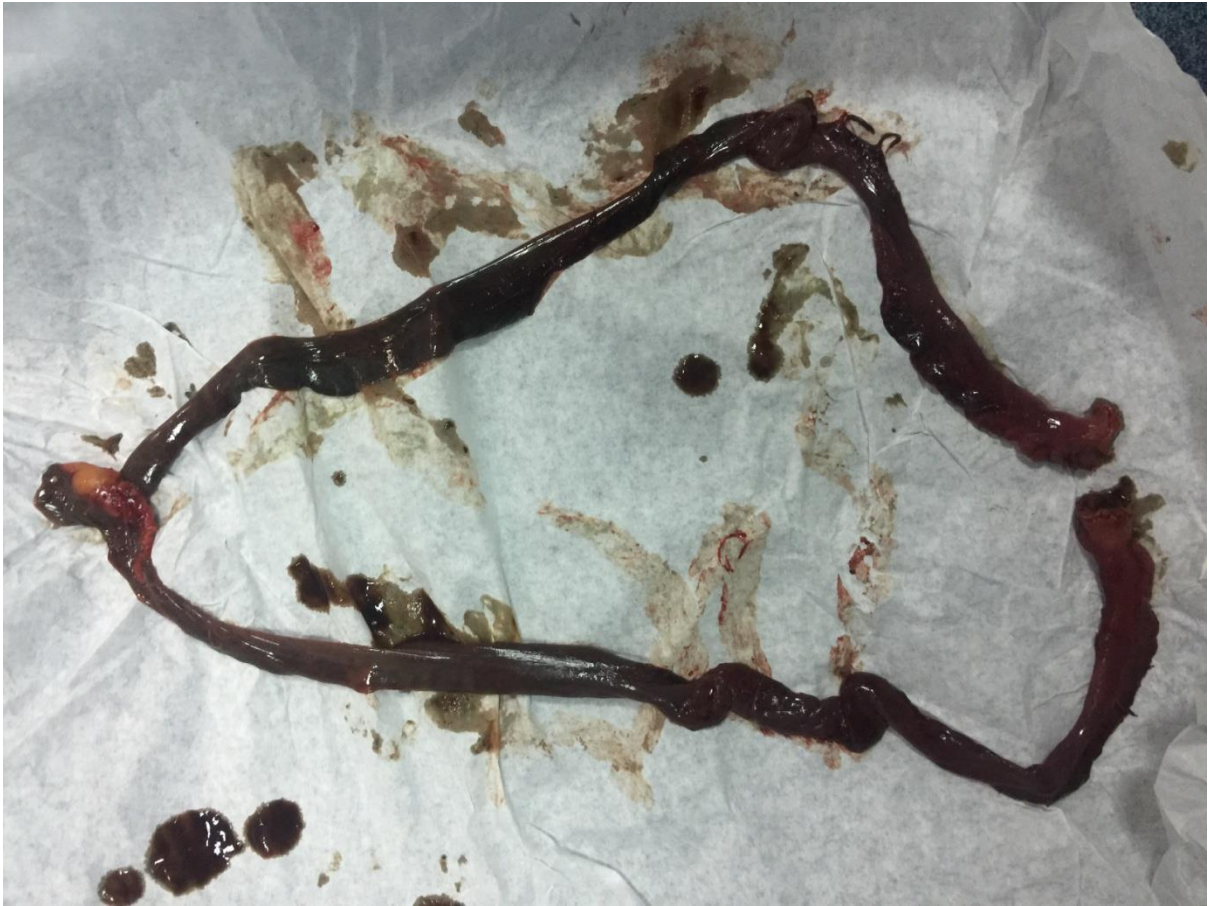

Figure 2: Post-operative image of the necrotized bowel