

**THE FUNCTIONAL ANATOMY OF THE NECK AND FORELIMBS OF THE
CAPE GOLDEN MOLE, *CHRYSOCHLORIS ASIATICA* (LIPOTYPHILA:
CHRYSOCHLORIDAE)**

GILLIAN M PUTTICK AND JENNIFER U M JARVIS
Zoology Department, University of Cape Town, Rondebosch.

Accepted: March 1977

ABSTRACT

The anatomy of the neck and forelimb of *Chrysochloris asiatica* is described and illustrated. The sequence of events during digging and modifications for fossorial action are described. Modifications include the appearance of a third bone in the forearm; the shortening and fusion of bones in the manus; enlarged processes on the scapula, humerus and ulna for greater muscle attachment; enlarged neck muscles and a dip in the spine in the cervical region to accommodate these and the enlarged shoulder muscles; an enlarged occiput for insertion of the powerful neck muscles; a greatly enlarged triceps and movement of the shoulder girdle to a position anterior to that normal in mammals. The possibility of the third forearm bone being the ossified tendon of a flexor muscle is discussed, without any conclusion being reached as to its true origin.

INTRODUCTION

The golden mole has become specialized externally for a subterranean existence. The eyes, external ears and tail are vestigial or absent, the body is cylindrical and the limbs short. The forelimbs bear two large claws and the muzzle bears a hard leathery pad.

The family Chrysochloridae (Class Insectivora, Order Lipotyphla) occurs mainly in southern Africa, but can also be found on a few mountain ranges in the rest of Africa. *Chrysochloris asiatica* (Linnaeus), the Cape golden mole, occurs in the western Cape Province and perhaps in Damaraland (Meester 1968). It burrows immediately below the surface and its tunnels are marked (on the surface) by 'runs' of uplifted soil. Deeper burrows and mole hills are occasionally made.

Dobson (1882) has undertaken some work on the anatomy of *Chrysochloris rutilans* now *Amblysomus hottentotus* (Smith, 1829), *C. villosa* now *Chrysospalax villosus* (Smith, 1933) and *C. trevelyani* now *Chrysospalax trevelyani* (Günther, 1875); and Parsons (1901) has worked on *C. trevelyani*. The paucity of literature on the forelimb especially prompted Campbell (1938) to discuss the earlier papers and examine the findings presented in them. Slonaker (1920) did the same, and also investigated the anatomy of the American mole *Scalops aquaticus*.

Zoologica Africana 12(2): 445-458 (1977)

The basic shoulder anatomy in *Chrysochloris* is similar to that of cursorial mammals and of fossorial mammals other than the true moles (Talpidae). This implies that *C. asiatica* digs by means of running motions of the forelimbs while bracing itself with the hindlimbs (Campbell 1938).

The papers mentioned above do not explain the complete mechanism of digging nor do they devote sufficient attention to several anatomical peculiarities in the forelimb. The present paper presents a more complete investigation of the shoulder and forelimb anatomy and function in *C. asiatica*.

MATERIALS AND METHODS

Both live and dead moles were used for this study. The dead animals were deep frozen until required, while live animals were kept in buckets of sand in the laboratory and fed on earthworms.

The skeletal and muscular adaptations to burrowing were determined by gross dissection of both fresh animals and animals preserved in 70 per cent alcohol. The bones of the manus were identified with the aid of X-ray photographs of dead moles.

The digging movements of a live mole were X-rayed. The mole was placed in a tube measuring 6 cm in diameter and made of exposed X-ray film. It was loosely packed with coarse sawdust and stoppered at each end. X-rays at the speed of six frames per second were taken to determine the sequence of digging movements. A ciné X-ray film was also made.

Ground sections of the third bone and radius were prepared to show their cellular structure.

RESULTS AND DISCUSSION

Digging sequence

Figure 1 shows the sequence of events during the digging of a superficial (or foraging) burrow. Both the head and forelimbs play an important role in this exercise, which can be divided into a power and a recovery phase.

The power or digging stroke consists of a powerful and rapid down- and backward thrust of the forelimbs with a simultaneous series of upward thrusts of the head (Figure 1 A-C). Flexure of the spine increases the thrust of the forelimbs which appears to serve mainly to counter the upward thrusts of the head. The hindlimbs brace the body during the power stroke and thus prevent any backward movement. The powerful thrusts of the head serve to clear a space in front of the mole by displacing the soil in front and above the animal, and form the ridge of soil on the surface which is a characteristic feature of this type of burrowing. No mole-hill is formed and little soil is pushed behind the animal by the limbs.

Towards the end of the power stroke the hind limbs begin to move forward. This occurs when the forelimbs have moved down far enough to provide purchase against the soil

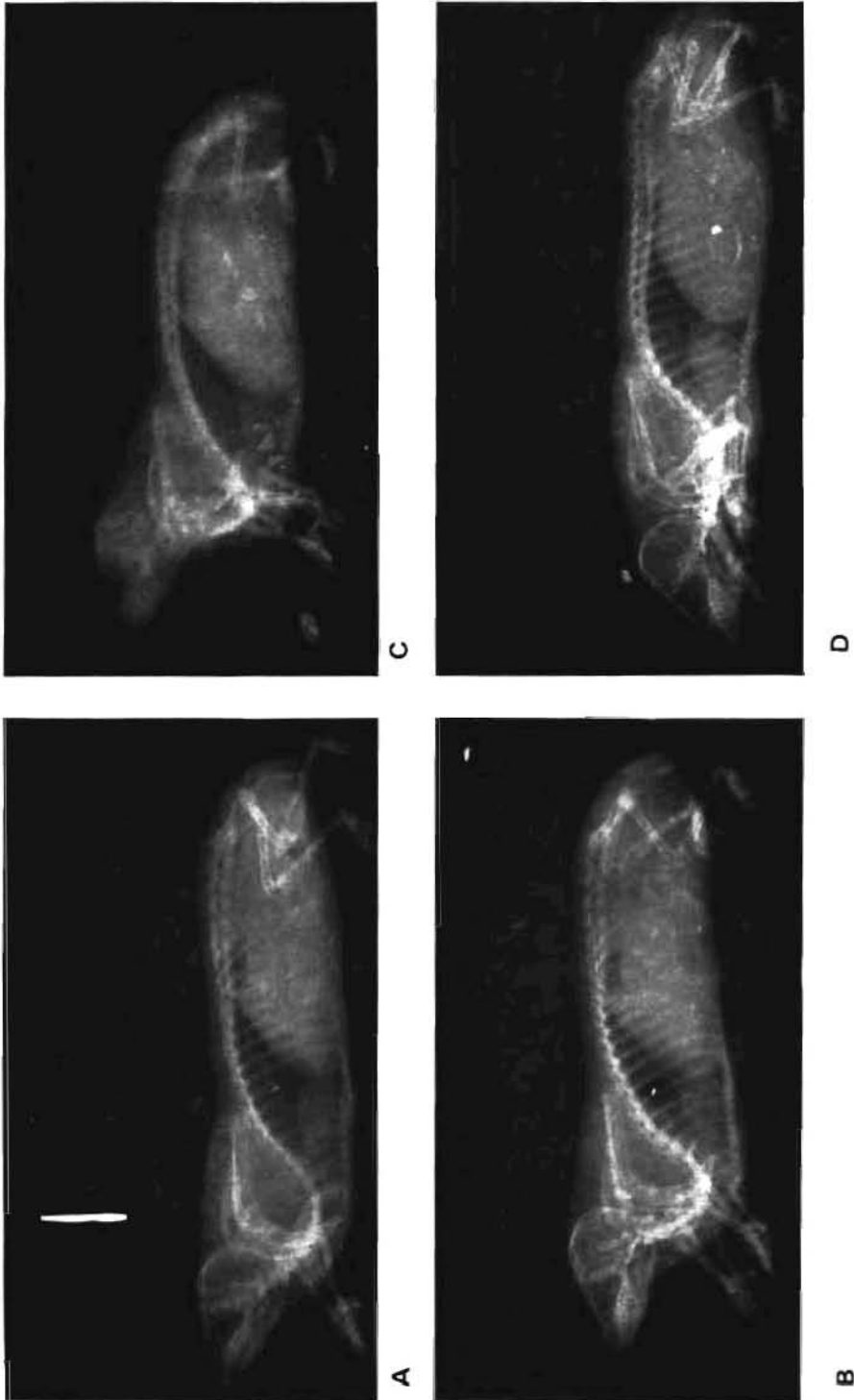


FIGURE 1
Radiographs showing the digging sequence in *Chrysochloris asiatica*. A - C: power stroke. D: end of recovery stroke.

(Figure 1C). At the end of the power stroke, the forelimbs lie against the abdomen and the head and neck are directed upwards.

The recovery stroke (Figure 1D) involves both the forward movement of the body of the mole into the space created by the previous power stroke, and also the repositioning of the forelimbs and head in preparation for the next power stroke. The forelimbs are brought forward in two phases: flexure at the elbow and wrist brings the forearm up close to the body; rotation of the humerus then pushes the whole forearm forwards. Some pronation of the forelimb also takes place. The head is lowered and this, together with the forward movement of the hindlimbs and body, arches the back convexly.

It should be emphasized here that the above digging sequence can be varied and frequently the power stroke ends at a point where the forelimbs are directed vertically or slightly posterior to the body. The extent of the power stroke is probably dependent on the speed of digging and also on the soil resistance. Digging movements when the mole is deep in the soil and thus unable to displace the soil with its head have not been observed.

Skeletal modifications for digging

The forelimb shows more adaptations for digging than any other part of the skeleton. The shoulder joint is situated far anteriorly and the resulting forward shift of the centre of gravity of the mole allows more power to be employed in forward locomotion. To compensate for this anterior shift of the shoulder joint, the sternum and scapula have elongated and the latter bone consequently reaches as far back along the thorax as is normal in mammals. The well-developed clavicle has shifted anteriorly, articulates with the humerus and abuts on the sternum to take some of the stresses caused by digging (Kistin 1929).

The spine of the scapula is greatly enlarged and provides a large surface area for attachment of the shoulder muscles used in digging. Lateral movement of the humerus at the gleno-humeral joint is prevented by elongated acromion and metacromion processes - a feature also found in fossorial rodents (Lehmann 1963). The gleno-humeral joint is placed low on the side of the body, thus increasing the moment of the humerus.

The humerus is short and greatly thickened. A large surface for muscle attachment is provided by an enlarged internal tuberosity, an elongated internal condyle and a prominent deltopectoral ridge. A well-marked olecranon fossa is also a feature of the humerus.

The radius is short and slightly flattened with its greatest diameter lying in the plane of movement (horizontal) to add strength to the bone. It bears two flattened facets distally for articulation with the carpal bones.

The ulna has a remarkably developed olecranon process which equals two-sevenths of the total length of the bone and provides a large area for attachment of the powerful extensor muscles of the forearm. Lateral movement of the forearm is prevented to a great extent by the elongated internal condyle of the humerus and the enlarged olecranon process of the ulna. This, together with the modifications at the gleno-humeral joint, restrict the movements of the forelimb largely to an antero-posterior motion.

A third bone is present in the forearm lying ventral to the ulna (Figure 2:tb). This bone is as long as the radius and extends along the distal three-fifths of the ulna to the carpus. Its

proximal end is extended into a long and a short process; the former is linked to the long process of the internal condyle of the humerus by tendons. Distally, two tendons run from the third bone to the unguis phalanges of digits two and three. These tendons both pass through tendinous loops situated on metacarpals two and three. Flower (1876:249) describes a third bone in the forearm of the Cape golden mole which he states "appears to be an ossification in one of the flexor tendons". Macalister (1878) and Dobson (1882) also describe the bone, Dobson calling it the ossified tendon of the *flexor digitorum profundus*. Hildebrand (1974) states that the bone replaces the flexor of the largest claw in *Amblysomus*. In *Chrysochloris* the *flexor digitorum profundus* is present (Figure 7) and inserts broadly on the third bone. Therefore it appears that this bone is the ossified tendon of the muscle.

The claws of the forelimb are extended when the mole is standing. This pulls the tendons of the third bone of the forearm so that it lies against the ulna. Increased tension on the proximal tendons of the third bone when the forearm is flexed results in flexure of the hand. The third bone moves away from the ulna during the downstroke (powerstroke) of the forelimb, possibly because straightening of the forearm moves the bone closer to the internal condyle of the humerus, thus decreasing the tension in the tendons linking the two bones.

The carpals in the manus are short and flattened where they articulate with the radius and ulna, thus reducing the lateral rotation of the manus. Digits one, two and four all have one metacarpus and two phalanges. The third digit, however, consists of a metacarpus and a single phalanx, the latter lying underneath a very large claw. It appears that the two phalanges have fused to form a strengthened support to the claw. A firm resistance to the soil during digging is provided by the fusion and reduction of the bones of the manus, as well as by the enlargement of the third claw.

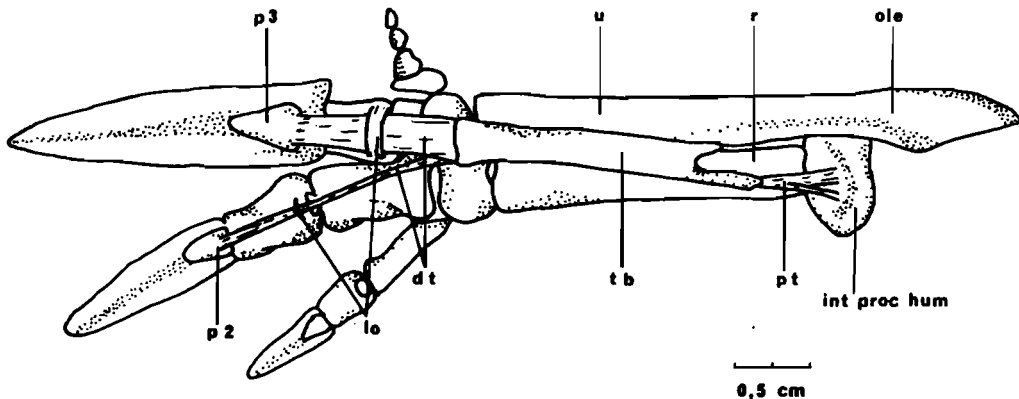


FIGURE 2

Ventral surface of the bones of the left manus showing the third bone in the forearm. For abbreviations see p. 458.

Other skeletal modifications related to digging include a rounded and expanded occipital region of the skull to provide the necessary surface area for attachment of the well-developed neck musculature, a vertebral column which dips deeply in the cervical and anterior thoracic region to accommodate the neck and shoulder musculature, an expanded first rib, and a greatly elongated thorax with 19 pairs of ribs providing a large area for attachment of the retractor muscles of the forelimbs (Figure 3).

Modifications of the musculature related to digging

With a few exceptions, the muscles of the back, shoulder and forelimb of *C. asiatica* are very similar to those described by Dobson (1882) for *C. rutilans* (now *Amblysomus hottentotus*) and by Campbell (1938) for *C. trevelyani* (now *Chrysoxpalax trevelyani*). The descriptions which follow will therefore not be detailed; differences will be outlined where relevant.

Muscles of the back and shoulder (Figures 4 and 5)

The *trapezius* consists of a thin anterior portion, the *trapezius anticus* and a long straplike posterior portion, the *trapezius posticus*. The former arises from the occipital ridge of the skull and inserts onto the spine of the scapula, while the latter arises from the ninth dorsal spinous process and inserts onto the posterior border of the spine of the scapula. Both fix the scapula to the thorax to provide a firm base for the action of the forelimb.



FIGURE 3

Radiograph showing lateral aspect of the pectoral girdle and forelimb.

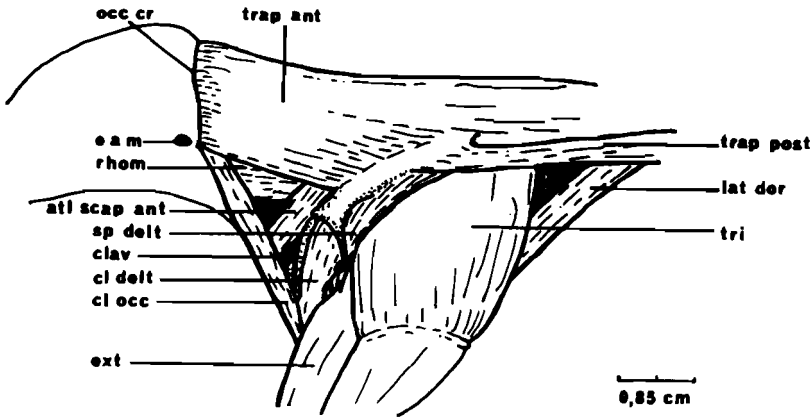



FIGURE 4

Left lateral view of the superficial cervical, scapular and humeral muscles. For abbreviations see p. 458.

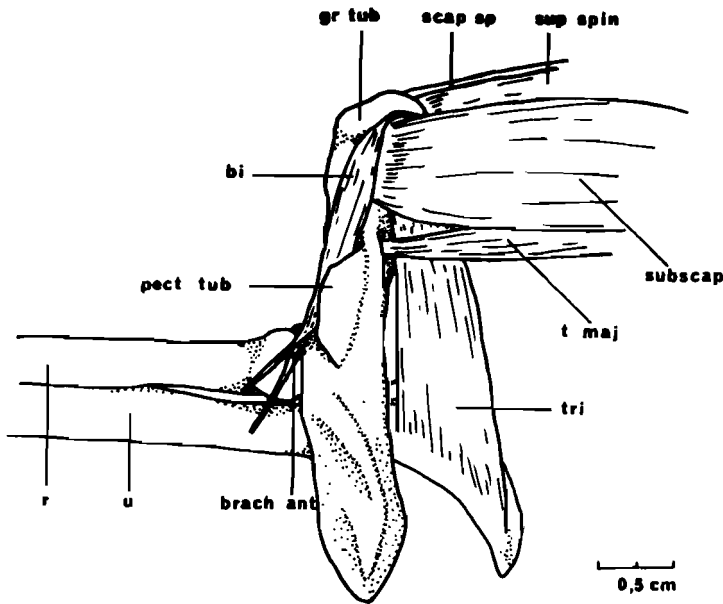


FIGURE 5

Medial aspect of scapular and upper forelimb muscles of the right forelimb. For abbreviations see p. 458.

The *rhomboideus* consists of two portions, a superficial mass arising from the occipital ridge ventral to the origin of the *trapezius anticus* and inserting medially on the acromion process and the spine of the scapula, and a deep portion (not illustrated) lying medial to the superficial mass and arising from the outer portion of the occipital ridge. It inserts onto the ridge leading from the spine to the vertebral margin of the scapula. The *rhomboideus* serves the same function as the *trapezius*.

The *splenius capitis* (not illustrated) arises mid-ventrally from the neck ventral to the *rhomboideus* and passes anteriorly to insert on the occiput ventral to the *rhomboideus*. The *biventer cervicis* (not illustrated) arises from the fourth and fifth cervical vertebrae and inserts ventral to the insertion of the *splenius capitis*. The *cleido-occipitalis* arises ventrally from the medial third of the clavicle and inserts ventral to the *trapezius* on the antero-lateral portion of the occipital ridge. These three muscles serve to lift the head.

The *atlantoscapularis* has two parts arising ventrally from the transverse process of the atlas and passing ventral to the clavicle and *deltoideus* to insert posterior to the base of the acromion process of the scapula and ventral to the insertion of the *trapezius anticus*. Some controversy exists in the literature regarding the homology of this muscle. Dobson (1882) describes in *C. rutilans* (*A. hottentotus*) a slender *laevator claviculae* running next to a slender *laevator scapulae* to insert on the metacromion process of the scapula. Campbell (1938) rejects Dobson's homology and describes these "laevators" as two segments of the *atlantoscapularis anterior*. However, Campbell does allow that the muscle may be a *laevator claviculae* which has migrated from the insertion on the clavicle to the acromion process of the scapula. Contraction of the *atlantoscapularis* prevents backward displacement of the scapula.

The *laevator angulae scapulae* and *serratus magnus* (not illustrated) appear to arise as a single sheet of muscle stretching from the third cervical vertebra to the ninth thoracic vertebra. The insertion extends from the clavicular articulation on the acromion process, along the edge of the spine of the scapula and onto the fascia of the *supraspinatus*. The muscles thus run dorsally from their insertion, over the vertebral margin of the scapula and then ventrally to the wide origin on the vertebrae. They serve to fix the forelimb firmly to the trunk.

The *subclavius* (not illustrated) arises ventrally from the transverse process of the *manubrium sterni* and inserts on the distal third of the clavicle, the greater tuberosity of the humerus, the glenoid margin of the scapula and the fascia of the *supraspinatus*. It links the forelimb to the trunk in the pectoral region.

Muscles of the upper forelimb

The *pectoralis* (not illustrated) arises ventrally from the sternum, the expanded first rib and the ventral region of the remaining ribs. The insertion of the major part of the muscle, the sternal part, is on the delto-pectoral tuberosity of the humerus. The part arising from the ribs inserts on the lesser tuberosity. The *pectoralis* serves to adduct the forelimb.

The *cleidodeltoideus* arises ventrally from the outer third of the clavicle and part of the anterior margin of the metacromion process of the scapula. It inserts onto the humerus

distal to the insertion of the pectoral muscles and serves to abduct the forelimb.

The *supraspinatus* arises from the entire supraspinous fossa of the scapula and inserts on the proximal surface of the greater tuberosity of the humerus. The *infraspinatus* (not illustrated) is concealed by the spinodeltoid. It arises laterally from the infraspinous fossa of the scapula and inserts on the greater tuberosity of the humerus. The *supra-* and *infra-spinatus* serve to fix the shoulder joint and also to rotate the forelimb to a small degree.

The *spinodeltoideus* arises laterally from the suprascapula and the scapular spine from its root to the level of the glenoid cavity. It inserts on the lateral edge of the humerus between the greater tuberosity and the deltopectoral tuberosity. It encloses the *infraspinatus* dorsally and posteriorly and attaches to the fascia of the latter. It abducts the forelimb.

The *subscapularis* arises laterally from almost the whole subscapular fossa. It inserts onto the lesser tuberosity of the humerus and serves to fix the shoulder joint.

The *teres major* arises from the inferior angle of the scapula and inserts on the medial edge of the humerus. Campbell (1938) noted that Dobson (1882) described it as the *teres minor*, but Parsons (1901) determined its true homology.

The *latissimus dorsi* consists of a larger superficial and a smaller deep aberrant part. The former has a wide origin stretching from thoracic vertebra nine to rib five and inserting on the elongated median condyle of the humerus, and also on the fascia of the forearm flexors. The deep *latissimus dorsi* arises from the twelfth to the seventeenth ribs and inserts on the superficial surface of the *pectoralis superficialis* by means of a short aponeurosis. The *teres major* and the *latissimus dorsi* contribute to the power stroke by retracting the forelimb, i.e. flexing the humerus.

The scapular head of the *triceps* is very large and arises from the vertebral edge of the infraspinous fossa of the scapula. It inserts on the margin of the elongated olecranon process of the ulna. The two humeral heads are much smaller and arise between the head and lesser tuberosity of the humerus. The greatly enlarged *triceps* contributes to the power stroke by extension of the lower arm.

The single head of the *biceps* arises by a tendon from the dorsal margin of the glenoid cavity. The muscle lies in the bicipital groove in the humerus, curves ventral to the deltopectoral process and inserts on the ulnar side of the radius. The *biceps* flexes the lower arm during the recovery stroke.

The *brachialis anticus* arises distal to the origin of the humeral head of the *triceps* and inserts on the radial surface of the ulna, distal to the insertion of the *biceps* on the ulnar surface of the radius. Dobson (1882) found no trace of this muscle in *C. rutilans* (*A. hottentotus*) but Campbell (1938) describes it in *C. trevelyani* (*Chrysospalax trevelyani*). However, Campbell describes the insertion as being fused with that of the *biceps* on both radius and ulna. It also flexes the lower arm.

The *anconeus* arises from the olecranal fossa of the humerus and inserts on the distal third of the posteroventral surface of the olecranon process of the ulna. It aids the powerstroke by extending the lower arm.

Muscles of the lower forelimb (Figures 6, 7)

The extensor muscles serve to 'open' the hand by elevating the wrist and extending the digits.

The *extensor digitorum communis* arises from the dorsal surface of the external condyle of the humerus and divides into three parts of equal size. The lateral part inserts on the metacarpal of the third digit and the middle part inserts on the phalanx of the third digit. The medial part runs through a ligamentous loop on the metacarpal of the third digit and inserts on the distal phalanx of the second digit. Dobson (1882) found that this muscle comprises only two parts in *C. rutilans* (*A. hottentotus*). The medial part inserts on the base of the single phalanx of the third digit and the lateral part on the metacarpal of the fourth digit.

The *extensor minimi digiti* arises from the dorsal surface of the external condyle of the humerus, passes through a ligamentous loop on the metacarpal of the fourth digit and inserts on the distal phalanx of this digit.

The *extensor indicis* arises from the ventral surface of the external condyle and forms a long tendon which passes ventral to those of the *extensor digitorum communis* to insert on the metacarpals of the second digit. The *extensor indicis* inserts on the metacarpal of the first digit in *C. rutilans* (*A. hottentotus*) (Dobson 1882).

The *extensor ossi metacarpi pollicis* (not illustrated) arises from the proximal half of the dorsal surface of the shaft of the ulna, ventral to the origin of the *extensor indicis*. It forms a long tendon which runs ventral to those of the *extensor digitorum communis* to insert on the metacarpal of the first digit.

The *extensor carpi ulnaris* (not illustrated) arises from the lateral aspect of the distal third of the olecranon process of the ulna and inserts on the unciform bone. This muscle arises by two heads in *C. rutilans* (*A. hottentotus*). The medial part inserts on the base of the single phalanx of digit three and the lateral part on the metacarpal of digit four (Dobson 1882).

The *extensor carpi radialis* arises from the external condyle of the humerus and inserts on the radial side of the second metacarpal.

The *supinator brevis* (not illustrated) arises from the extremity of the external condyle of the humerus and inserts on the proximal half of the shaft of the radius. It supinates the forearm.

The flexor muscles serve to 'close' the hand by depressing the wrist and flexing the digits. The *flexor digitorum profundus* has a broad origin on the ulna from the lateral aspect of the olecranon process, the lateral aspect of the ulna proximally and the medial aspect of the ulna distally. It inserts in part on the shorter proximal process of the third forearm bone by means of a short tendon. The rest of the muscle inserts directly on the medial aspect of the third forearm bone. The *flexor digitorum sublimis* is a small muscle arising from the lateral aspect of the long process of the internal condyle of the humerus. It inserts on the distal phalanx of digit two.

The *dorso-epitrochlearis* (not illustrated). Some fibres of the *latissimus dorsi* pass forward from the long process of the internal condyle of the humerus and insert medially on the proximal third of the third forearm bone. Dobson (1882) states that these may represent the

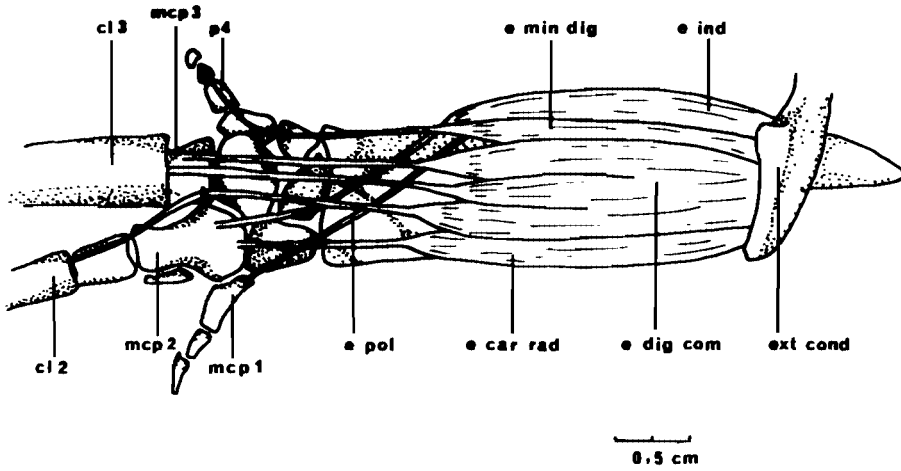


FIGURE 6

Dorsal aspect of the extensor muscles of the right forearm. For abbreviations see p. 458.

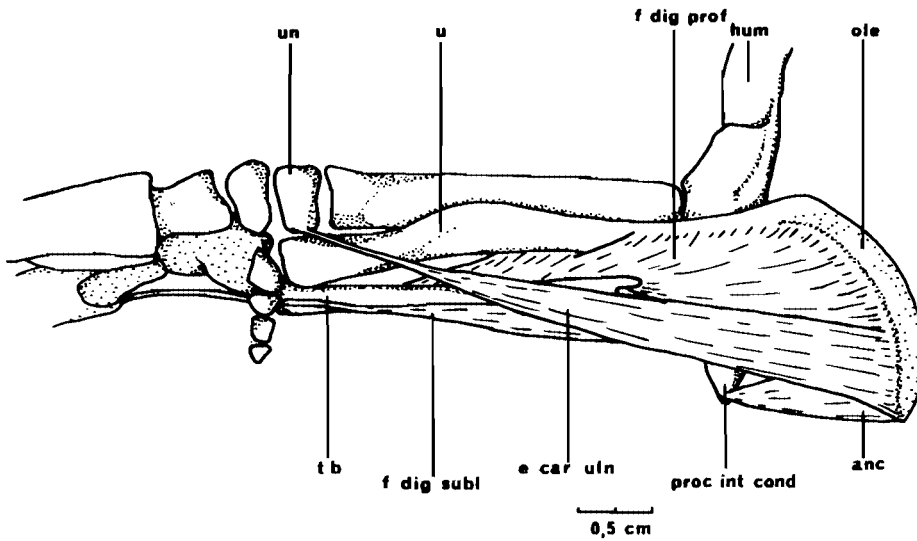


FIGURE 7

Lateral aspect of the flexor muscles of the left forearm. For abbreviations see p. 458.

dorso-epitrochlearis. It aids the power stroke by retracting the forearm.

The *flexor carpi radialis* (not illustrated) arises from the medial aspect of the long process of the internal condyle of the humerus. It passes through a ligamentous loop on the ventral surface of the distal head of the radius and inserts ventrally on the metacarpal of digit two.

The *pronator radii teres* (not illustrated) arises on the long process of the internal condyle of the humerus, medial to the origin of the *flexor carpi radialis*. It has a broad insertion on the medial aspect of the radius. It pronates the forearm.

Striking modifications of the above-mentioned muscles for digging are the much enlarged neck muscles, particularly the *trapezius anticus*, the *rhomboideus* and the *splenius capitis*. The *trapezius* and *rhomboideus* serve both to lift the head and to fix the scapula relative to the thorax and thus provide a firm base from which the forelimbs can act. The muscles responsible for resisting displacement of the shoulder joint, namely the *subscapularis*, *supraspinatus* and *infraspinatus* are also well developed.

The *serratus magnus* and *laevator angulae scapulae* which provide support for the body on the pectoral girdle normally insert on the medial surface of the scapula. In *C. asiatica*, however, their insertion has migrated over the dorsal edge of the scapula to the lateral surface. The pulley thus formed provides greater leverage for the thorax relative to the forelimb.

Most of the power for the downward digging stroke is provided by well-developed *triceps* and *anconeus* muscles which retract the forearm, and by the *teres major* and *latissimus dorsi* which retract the humerus. In most mammals the *latissimus dorsi* inserts near the head of the humerus; it acts as a third class lever and is suitable for speed. In *C. asiatica* the insertion has moved distally to increase the length of the power arm, making the lever more suitable for power. Gray (1968) points out that the ability of the scapula to resist backward displacement by the *latissimus dorsi* is largely due to the simultaneous forward pull on the scapula exerted by muscles operating between the neck and the scapula - mainly the *atlantoscapularis anterior*. Because the insertion of the *latissimus dorsi* has shifted distally, there is an increased need to resist backward displacement of the glenoid. This is possibly the reason for the doubling of the *atlantoscapularis anterior* which Campbell (1938) describes. Even if one part of the *atlantoscapularis* is, as Dobson states, a *laevator clavicularae*, the need to resist backward displacement would explain the migration of its insertion from the clavicle to the acromion process. The other retractor of the humerus, the *teres major*, is very weak and its function has probably been taken over in two ways. Firstly, the *latissimus dorsi* is sufficiently well-developed to provide the power for flexure of the humerus on its own and secondly, the *triceps* provides most of the power for the backward digging stroke.

The pronator muscles are well developed. Some pronation of the limb probably occurs on the recovery stroke. By contrast the supinators are relatively weak and this, in conjunction with the limiting effect of the wrist, elbow and shoulder joints on lateral movement, suggests that supination is uncommon.

The function of the *flexor digitorum profundus* and the suggestion that the third bone in the forearm is an ossified tendon of this muscle deserve some comment. This muscle is

wholly tendinous in *Talpa* (Yalden 1966); it inserts on the process of the internal condyle of the humerus. Yalden found that rotation of the humerus pulls on this tendon, straightening the wrist from the extreme extended position and also pushing the radius distally with the same effect. Besides straightening the wrist, the antagonism between the radius and the tendon provides the forelimb with greater rigidity and thus imparts a good degree of directionality to the movement of the forelimb. It appears that a similar action is possible in *Chrysochloris*.

The fact that the forearm flexors are relatively reduced in *Chrysochloris* would support the supposition that the straightening of the wrist is achieved mechanically by movement of the humerus and changes in the tension of the tendons of the third bone. Contraction of the *flexor digitorum profundus* produces flexure from the straight position by pulling the bone back towards the olecranon process. The tendinous insertions of the bone on the phalanges of digits two and three prevent radial and lateral rotation of the phalanges relative to the carpi and thus direct movement in the horizontal plane. The third bone would also tend to prevent pronation of the radius and ulna.

The ground sections showed that the third bone was indistinguishable histologically from the radius. Its origin could be proved conclusively by embryological studies.

In conclusion, a cursorial style of forelimb movement has been modified for burrowing in *C. asiatica*. The chief modifications are the appearance of a third bone in the forearm; the shortening and fusion of bones in the manus; enlarged processes on the scapula, humerus and ulna for greater muscle attachment; enlarged neck muscles and a dip in the spine in the cervical region to accommodate these and the enlarged shoulder muscles; enlarged occiput for insertion of the powerful neck muscles; a greatly enlarged triceps and movement of the shoulder girdle to a position anterior to that normal in mammals.

ACKNOWLEDGEMENTS

We are grateful to Dr A Goldin and Dr B Cremin who took the X-rays, Professor Keen who made the general radiograph of *C. asiatica* available and Mr W Kemlo who had the ground bone sections prepared. Financial assistance was provided by the CSIR. A grant in aid of publication from the University of Cape Town is gratefully acknowledged.

REFERENCES

- CAMPBELL, B 1938. A reconsideration of the shoulder musculature of the Cape golden mole. *J. Mammal.* 19: 234-241.
- DOBSON, G E 1882-1892. *A monograph of the Insectivora, systematic and anatomical.* London: John van Voorst.
- FLOWER, W H 1876. *Osteology of the Mammalia.* London: MacMillan.
- GRAY, J 1968. *Animal locomotion.* London: Weidenfeld & Nicolson.
- HILDEBRAND, M 1974. *Analysis of vertebrate structure.* John Wiley & Sons.

- KISTIN, A D 1929. The mole clavicle. *J. Mammal.* 10: 305-313.
- LEHMANN, W H 1963. The forelimb architecture of some fossorial rodents. *J. Morph.* 113: 59-76.
- MICALISTER, A 1878. *Morphology of vertebrate animals*. London: Longmans Greene.
- MEESTER, J 1968. Lipotyphla: Chrysochloridae. *Smithson. Inst. Preliminary identification manual for African mammals*, 23.
- PARSONS, F G 1901. On the muscles and joints of the giant golden mole (*Chrysochloris trevelyani*). *Proc. zool. Soc. Lond.* 1901. 26-34.
- SLONAKER, J H 1920. Some morphological changes for adaptation in the mole. *J. Morph.* 34: 335-373.
- VALDEN, D W 1966. The anatomy of mole locomotion. *J. Zool. Lond.* 149: 55-64.

Abbreviations for figures

anc = anconeus	lo = loops
atl scap ant = atlantoscaphularis anterior	mcp 1 = metacarpal 1
bi = biceps	mcp 2 = metacarpal 2
brach ant = brachialis anticus	mcp 3 = metacarpal 3
clav = clavicle	occ α = occipital crest
cl 2 = claw 2	ole = olecranon
cl 3 = claw 3	pect tub = pectoral tuberosity
cl delt = cleidodeltoideus	p 2 = phalanx 2
cl occ = cleido-occipital	p 3 = phalanx 3
d t = distal tendon (of third forearm bone)	p 4 = phalanx 4
ext = extensors	proc int cond = process of the internal condyle
e car rad = extensor carpi radialis	p t = proximal tendon (of third forearm bone)
e car uln = extensor carpi ulnaris	r = radius
e dig com = extensor digitorum communis	rhomb = rhomboideus
e ind = extensor indicis	scap sp = spine of scapula
e min dig = extensor minimi digiti	sp delt = spinodeltoideus
e pol = extensor pollicis	subscap = subscapularis
e a m = external auditory meatus	sup spin = supraspinatus
ext cond = external condyle	t maj = teres major
f dig prof = flexor digitorum profundus	tt b = third bone
f dig subl = flexor digitorum sublimis	trap ant = trapezius anticus
gr tub = greater tuberosity	trap post = trapezius posticus
hum = humerus	tri = triceps
int proc hum = internal process of humerus	u = ulna
lat dor = latissimus dorsi	un = unciform bone