

Naringen Ameliorates Cyanide-induced Testicular and Epididymal Changes in Swiss Albino Mice (*Mus musculus*)

¹Sanni A.M., ²Idaguko C.A., ³Abdulazeez D.O., ⁴Adeleke O.S. and ⁵Falana B.A.

ABSTRACT

Cyanide is one of the toxic, hazardous metals widely dispersed in the environment at high levels. The aim of this study is to evaluate the ameliorative role of Naringenin on male reproductive parameters in cyanide exposed mice.

A total number of 28 Albino mice were divided into four groups, each group comprises of 7 mice (n= 7). The animals were housed in a well-lighted and ventilated plastic cages at a controlled temperature with 12h light/dark cycle maintained throughout the experimental period. All the Mice were acclimatized for 2 weeks before commencement of the study. Group 1 were control mice, group 2 received cyanide (1.2mg/kg bw) only, group 3 received Cyanide (1.2mg/kg bw) and Naringenin (50mg/kg bw) daily and group 4 received a daily administration of Naringenin (50mg/kg bw). All the treatments were done at 7:00 am every morning and the experiment lasted for 14 days. Twenty-four hours after 14th day of treatment, animals were sacrificed by cervical dislocation. Blood samples were collected via Ocular sinus into lithium-heparin bottles for haematological and hormonal assay. The right testis was excised and quickly placed in Bouin's fluid and processed for histological examination while the left testis was placed in sucrose and processed for antioxidant assay.

Results from this study showed significant reduction in serum testosterone levels, oxidative damage, reduced packed cell volume (PVC), reduced body weight gain and degenerative testicular microarchitecture in mice exposed to cyanide compared to control. Administration of Naringenin reversed almost all the abnormalities in the parameters investigated showing significant protection against cyanide induced toxicity in mice.

It is concluded that Naringenin showed affordable protection against cyanide induced toxicity on male reproductive profile.

Keywords: Naringenin, cyanide, oxidative damage, testis.

*Corresponding Author

Dr. Falana B.A.

<http://orchid.org/0000-0002-94179464>

E-mail: benedict.falana@uniosun.edu.ng

¹Department of Anatomy, Faculty of Basic Medical Sciences, Osun State university, Osogbo, Nigeria

²Department of Anatomy, Edo University Iyamho.

³Department of Anatomy, Faculty of Basic Medical Science, University of Medical Sciences, Ondo, Ondo State, Nigeria.

^{4,5}Department of Anatomy, Faculty of Basic Medical Sciences, Osun State university, Osogbo, Nigeria.

Received: March 10, 2019

Accepted: March 11, 2020

Published: December 31, 2020

Research Journal of Health Sciences subscribed to terms and conditions of Open Access publication. Articles are distributed under the terms of Creative Commons Licence (CC BY-NC-ND 4.0). (<http://creativecommons.org/licenses/by-nc-nd/4.0>).

<https://dx.doi.org/10.4314/rejhs.v8i4.9>

Effet de la naringénine sur les lésions testiculaires et épидидymales indiquées par le cyanure chez la souris albino suisse (*mus musculus*)

¹Sanni A.M., ²Idaguko C.A., ³Abdulazeez D.O., ⁴Adeleke O.S. and ⁵Falana B.A.

Résumé

Le cyanure est l'un des métaux toxiques et dangereux largement dispersés dans l'environnement à des niveaux élevés. Le but de cette étude est d'évaluer le rôle d'amélioration de la naringénine sur les paramètres reproducteurs mâles chez les souris exposées au cyanure.

Un nombre total de 28 souris albinos a été divisé en quatre groupes, chaque groupe comprenant 7 souris (n = 7). Les animaux ont été logés dans des cages en plastique bien éclairées et ventilées à une température contrôlée avec un cycle lumière/obscurité de 12 h maintenu pendant toute la période expérimentale. Toutes les souris ont été acclimatées pendant 2 semaines avant le début de l'étude. Le groupe 1 était des souris témoins, le groupe 2 a reçu du cyanure (1,2 mg/kg pc) uniquement, le groupe 3 a reçu du cyanure (1,2 mg / kg pc) et de la naringénine (50 mg/kg pc) par jour et le groupe 4 a reçu une administration quotidienne de naringénine (50 mg/kg pc). Tous les traitements ont été effectués à 7h00 tous les matins et l'expérience a duré 14 jours. Vingt-quatre heures après le 14^e jour de traitement, les animaux ont été sacrifiés par luxation cervicale. Les échantillons de sang étaient dosage hormonal. Le testicule droit a été excisé et rapidement placé dans le liquide de Bouin et traité pour un examen histologique tandis que le testicule gauche a été placé dans du saccharose et traité pour un dosage antioxydant.

Les résultats de cette étude ont montré une réduction significative des taux sériques de testostérone, des dommages oxydatifs, une réduction du volume de cellules compactées (PVC), une réduction du gain de poids corporel et une microarchitecture testiculaire dégénérative chez les souris exposées au cyanure par rapport au contrôle. L'administration de naringénine a inversé presque toutes les anomalies des paramètres étudiés montrant une protection significative contre la toxicité induite par le cyanure chez la souris. Il est conclu que la naringénine a montré une protection abordable contre la toxicité induite par le cyanure sur le profil reproducteur masculin.

Mots-clés : Naringénine, cyanure; dommages oxydatifs; testicules

*Corresponding Author

Dr. Falana B.A.

<http://orcid.org/0000-0002-94179464>

E-mail: benedict.falana@uniosun.edu.ng

¹Department of Anatomy, Faculty of Basic Medical Sciences, Osun State university, Osogbo, Nigeria

²Department of Anatomy, Edo University Iyamho.

³Department of Anatomy, Faculty of Basic Medical Science, University of Medical Sciences, Ondo, Ondo State, Nigeria.

^{4,5}Department of Anatomy, Faculty of Basic Medical Sciences, Osun State university, Osogbo, Nigeria.

Received: March 10, 2019

Accepted: March 11, 2020

Published: December 31, 2020

Research Journal of Health Sciences subscribed to terms and conditions of Open Access publication. Articles are distributed under the terms of Creative Commons Licence (CC BY-NC-ND 4.0). (<http://creativecommons.org/licenses/by-nc-nd/4.0>).

<https://dx.doi.org/10.4314/rejhs.v8i4.9>

INTRODUCTION

Infertility is one of the most important complications in gynecology and is explained as the inability to achieve pregnancy after one year of unprotected intercourse (without the use of any contraceptive method)(Moridi *et al.*, 2019).

Estimates from 1997 suggest that worldwide about five percent of all heterosexual couples have an unresolved problem with infertility (Mustafa *et al.*, 2019). Many more couples, however, experience involuntary childlessness for at least one year: estimates range from 12% to 28%. 20-30% of infertility cases are due to male infertility, 20-35% are due to female infertility, and 25-40% are due to combined problems in both parts. In 10-20% of cases, no cause is found (Mustafa *et al.*, 2019). Male infertility is most commonly due to deficiencies in the semen, and semen quality is used as a surrogate measure of male fecundity (Mustafa *et al.*, 2019).

The term “cyanides” is used to describe compounds which contain in their structure the $C \equiv N$ group (Gensa 2019). In the environment, cyanides can be found in many different forms (Gensa 2019). Cyanide, hydrocyanic acid, hydrogen cyanide (HCN) and prussic acid are all terms relating to the same toxic principle (Gensa 2019). Cyanide is responsible for several health complications such as Konzo disease, thyroid goiter and tropical ataxic neuropathy, incidences of cretinism, stunted growth in children and deaths, epilepsy as well as behavioral and emotional abnormalities in children(Mushumbusi 2020).

Naringenin is one of the most important naturally-occurring flavonoid, predominantly found in some edible fruits, like Citrus species and tomatoes, and figs belonging to smyrna-type *Ficus carica* (Salehi *et al.*, 2019). Chemically named as 2,3-dihydro-5,7-dihydroxy-2-(4-hydroxyphenyl)-4H-1-benzopyran-4-one, naringenin shows a molecular weight of 272.26 (C₁₅H₁₂O₅) (Salehi *et al.*, 2019). Naringin (NG) is a flavone found in citrus fruits, tomatoes, cherries, grapefruit, and cocoa (Alboghobeish *et al.*, 2019). This compound acts as a nontoxic natural product with several functions, such as anticancer, anti-oxidative, anti-inflammatory, nephron-protective and hepatoprotective activities (Alboghobeish *et al.*, 2019). In one study, it was reported that NG restored normal testicular function, including sperm parameters in type 1 diabetic rats (Alboghobeish *et al.*, 2019).

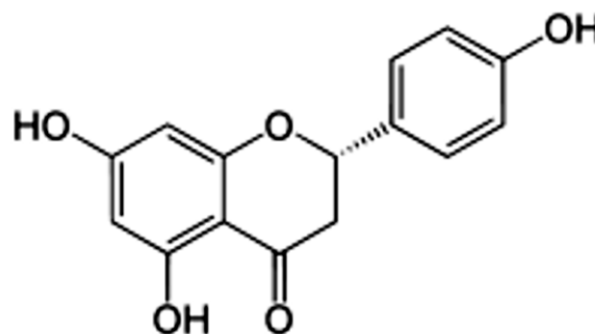


Figure 1. Naringenin has the skeleton structure of a flavanone with three hydroxy groups at the 4', 5, and 7 carbons. It may be found in the aglycol form, naringenin, or in its glycosidic form, naringin, which has the addition of the disaccharide neohesperidose attached via a glycosidic linkage at carbon 7 (Salehi *et al.*, 2019).

Testis

Each testis is surrounded by a thick capsule of dense connective tissue, the **tunica albuginea** (Junqueira and Carneiro 2007). The tunica albuginea is thickened on the posterior surface of the testis to form the **mediastinum testis**, from which fibrous septa penetrate the gland, dividing it into about 250 pyramidal compartments called the **testicular lobules** (Junqueira and Carneiro 2007). These septa are incomplete, and there is frequent intercommunication between the lobules (Junqueira and Carneiro 2007). Each lobule is occupied by one to four **seminiferous tubules** enmeshed in a web of loose connective tissue that is rich in blood and lymphatic vessels, nerves, and **interstitial cells**, also known as **Leydig cells** (Junqueira and Carneiro 2007). Seminiferous tubules produce male reproductive cells, the spermatozoa, whereas interstitial cells secrete testicular androgens (Junqueira and Carneiro 2007).

During embryonic development the testes develop retroperitoneally in the dorsal wall of the abdominal cavity (Junqueira and Carneiro 2007). They migrate during fetal development and become positioned within the scrotum, at the ends of the spermatic cords (Junqueira and Carneiro 2007). Because of this migration, each testis carries with it a serous sac, the **tunica vaginalis**, derived from the peritoneum (Junqueira and Carneiro 2007). The tunic consists of an outer parietal layer and an inner visceral layer, covering the tunica albuginea on the anterior and lateral sides of the testis (Junqueira and Carneiro 2007).

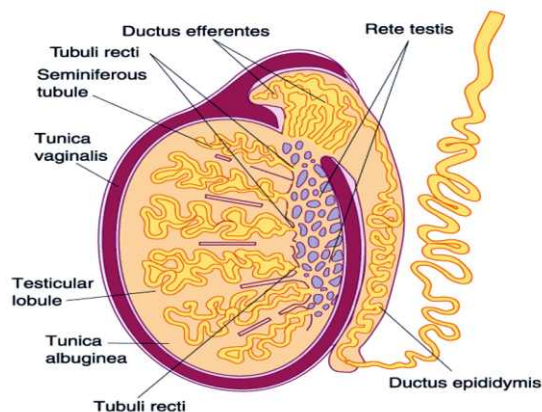


Figure 2: Diagram showing the testis and its various parts (Junqueira and Carneiro 2007).

Reproductive Effects

No studies were located regarding reproductive effects in humans after any route of exposure, but a few studies reported reproductive effects in animals exposed via the oral route. Reproductive effects were the only adverse effects observed in rats and mice ingesting, respectively, 12.5 or 24.3 mg CN/kg/day as sodium cyanide in the drinking water for 13 weeks.

Naringenin

1. Antioxidant

Naringenin has been shown to have significant antioxidant properties. Naringenin may exert their hepatoprotective effects in APAP-administered rats via enhancement of the antioxidant defense system and suppression of inflammation and apoptosis (Ahmed *et al.*, 2019).

2. Anticancer

Naringenin has a wide spread pharmacological properties such as anti-inflammatory, antimutagenic, antiatherogenic, hepatoprotective and anticancer with low or intrinsic toxicity (Vishnu *et al.*, 2019).

Cytotoxicity has been induced reportedly by naringenin in cancer cells from breast, stomach, liver, cervix, pancreas, and colon tissues, along with leukaemia cells (Kanno *et al.*, 2005). The first theory is that naringenin inhibits aromatase, thus reducing growth of the tumor (van Meeuwen *et al.*, 2007).

Experimental Animals and Care

Twenty eight (28) male Swiss albino mice and Twelve (12) female Swiss albino mice (for Fertility study) with an average weight of $80g \pm 10g$. The animals were divided into four groups (1-4). Group 1 was designated as the control group which received physiological saline while Mice of Group 2 received cyanide (1.2mg/kg body weight) only, group 3 received cyanide (1.2mg/kg body weight) and Naringenin (50mg/kg body weight) daily and group 4 received a daily administration of Naringenin (50mg/kg body weight), respectively. All the treatments were done at 7:00 am every morning and the experiment lasted for 14 days. Drug administration was dispensed to the experimental animals with a calibrated syringe fitted with a beaded oral cannula.

The mice were on a daily basis fed with mice feed which was bought from Ogoole feed and flour mill limited, Ogberin, Ede. Proper aeration was maintained by use of well-spaced and gauzed cages and a hygienic environment was ensured. Naringenin powder and Cyanide were purchased from Sigma-Aldrich Chemical Co., USA. All protocols and treatment procedures were done according to the Institutional Animal Care and Use Committee (IACUC) guidelines and as approved by the Health Research and Ethics Committee (HREC) of the Faculty of Basic Medical Sciences Ethics Review Committee, Osun State University, Osogbo, Nigeria.

Animal Sacrifice

Twenty-four hours after 14th day of treatment, animals were sacrificed by cervical dislocation. Blood samples were collected via cardiac puncture into lithium-heparin bottles for hormonal assay. The right testis was excised and quickly placed in Bouin's fluid and processed for histological examination while the left testis was placed in sucrose and processed for antioxidant assay.

Sperm count assay

Sperm Motility was assessed by the method described by Rouge and Bowen 2002. The spermatozoa were counted by hemocytometer. The count was done under a light microscope at $\times 400$ magnifications and expressed as $\times 10^6/ml$.

Sperm Morphology

Moreover, to examine the sperm morphology, a drop of the sperm suspension was placed on a glass slide and a smear was prepared. The smear was fixed in ethanol for 1 h, stained with Haematoxylin and Eosin, washed, dried, and examined with a light microscope at a magnification of $\times 100$. These findings were expressed as percentage (%) of morphological abnormal sperm.

Histological studies

Routine Haematoxylin and Eosin (H&E), Masson trichrom (Mt), and Periodic Acid Schiff (PAS) stains was carried out. The testes were fixed in Bouin's fluid, dehydrated in ascending grades of alcohol, cleared in Xylene and infiltrated in molten paraffin wax. Before finally embedded in molten paraffin wax to form block.

Mating

Mating was done using Macondes *et al.*, (2002) method. Treated male micewere introduced into the female's cages that have been confirmed to be in their proestrous phases. This was done to reduce encourage the acceptance of the male mice by the female mice for mating purposes. The presence of sperm plug ascertained that mating has taken place, hence the day following the day of male introduction was taken as day 1 of pregnancy (Oderinde *et al.*, 2002)

Determination of Antioxidant Activities

Determination of SOD, CAT, GSH and MDA activities was carried out on the testes of treated mice using spectrophotometric technique. Each of the assay kits were procured from Bio Legend Inc., San Diego, CA, USA. Testes (in sucrose at 4° C) from mice across groups were weighed and pulverized in 0.25 M sucrose (Sigma) with the aid of an automated homogenizer at 4°C. Lysates from the testes were centrifuged for 10 minutes in a microfuge at 12,000 rpm to obtain the supernatant containing organelle fragments and synaptosomes.

Statistical Analysis

All quantitative data were analyzed using GraphPad Prism® (version 6) software. Body weight, Semen Analysis, and Hormonal Analysis outcomes were plotted in ANOVA followed with Tukey's multiple comparisons test. Significance was set at $p < 0.05^*$ (95% confidence interval). The results were represented in bar charts with error bars to show the mean and standard error of mean respectively.

RESULTS

Morphological Observations

The body weights of the animals were taken on the first day of administration and the day of sacrifice. The weight gain was estimated as the difference between the initial weight of the animal and the final weight.

Hormonal Analysis

The serum testosterone levels were estimated following the biochemical assay. The values obtained were subjected to statistical analysis and the data obtained are presented in the table below.

Table 1: Table showing the mean and standard error of mean (SEM) of serum testosterone level in the various experimental groups and control group. 1= control group, 2= cyanide (1.2mg/kg body), 3= naringenin+cyanide (50mg/kg body) of naringenin and (1.2mg/kg body) of cyanide and 4= naringenin (50mg/kg body).

GROUPS	MEAN (ng/ml)	SEM
1 control	7.35	0.266
2 cyanide	4.22	0.692
3 cyanide+naringenin	6.82	0.449
4 naringenin	7.99	0.517

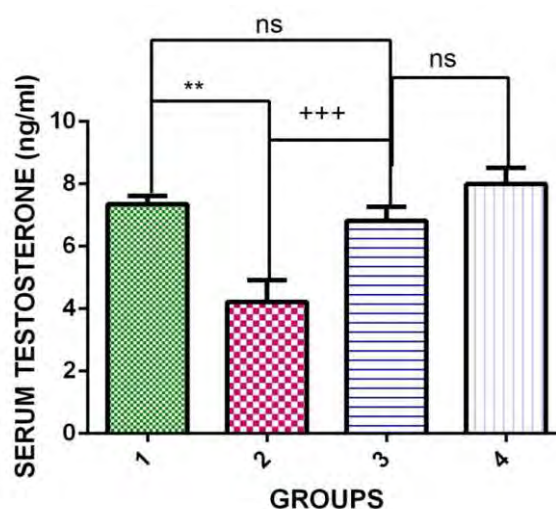


FIGURE 3: Chart showing the levels of serum testosterone. 1= control group, 2= cyanide (1.2mg/kg body), 3= naringenin+cyanide (50mg/kg body) of naringenin and (1.2mg/kg body) of cyanide and 4= naringenin (50mg/kg body). * is the significant level

of difference in comparison to the control group 1 while+ is the significant level of difference in comparison to group 2 while P value is less than 0.05. **ns** means not significant

Semen Analysis

The sperm count, sperm motility, and sperm morphology was analyzed after the caudal epididymis of the rats were excised. The data obtained was subjected to statistical analysis and the data obtained is presented in tables and graphs below.

Table 2: table showing the mean and standard error of mean (SEM) of total sperm count in the various experimental groups and control group. 1= control group, 2= cyanide (1.2mg/kg body), 3= naringenin+cyanide (50mg/kg body) of naringenin and (1.2mg/kg body) of cyanide and 4= naringenin (50mg/kg body).

Total Sperm count TSC (x10⁶/ml)	
GROUPS	VALUES
1	180.47±4.27
2	120.06±1.12*
3	160.00±3.09*
4	184.40±2.25*

Data were presented as mean and standard error of mean (Mean ± SEM) *(P<0.05) – statistical significant difference when compared across groups.

Table 3: table showing the mean and standard error of mean (SEM) of sperm motility in the various experimental groups and control group. 1= control group, 2= cyanide (1.2mg/kg body), 3= naringenin+cyanide (50mg/kg body) of naringenin and (1.2mg/kg body) of cyanide and 4= naringenin (50mg/kg body).

GROUPS	Sperm motility (%)	
	Motile	Non-Motile
1	89.17±2.19	10.83±1.89
2	66.14±2.64*	31.86±2.87*
3	84.26±3.08*	15.74±3.18*
4	90.37±1.34*	9.63±1.70*

Data were presented as mean and standard error of mean (Mean ± SEM) *(P<0.05) – statistical significant difference when compared across groups.

Table 4: table showing the mean and standard error of mean (SEM) of sperm morphorlogyin the various experimental groups and control group. 1= control group, 2= cyanide (1.2mg/kg body), 3= naringenin+cyanide (50mg/kg body) of naringenin and (1.2mg/kg body) of cyanide and 4= naringenin (50mg/kg body).

GROUPS	Sperm morphology (%)	
	Normal	Abnormal
1	82.43±1.31	17.57±1.31
2	45.05±2.09	54.95±2.09
3	70.67±1.24	29.33±1.24
4	80.14±2.05	19.86±2.05

Antioxidant Parameters

1. SOD Profiles Decreases Following Cyanide Administration

Results from spectrophotometric assay showed that SOD levels in the cyanide treated mice were significantly decreased in comparison to the control group and naringenin treated groups. SOD level in thenaringenin+cyanide treated mice increased but were not stastically significant when compared with the control group.

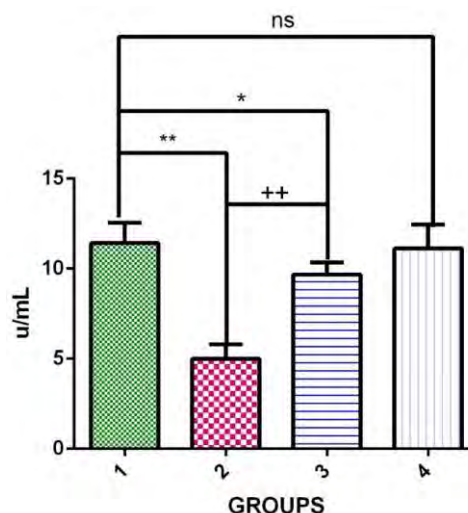


FIGURE 3: Chart showing the levels of testicular Superoxide Dismutase level. 1= control group, 2= cyanide (1.2mg/kg body), 3= naringenin+cyanide (50mg/kg body) of naringenin and (1.2mg/kg body) of cyanide and 4= naringenin (50mg/kg body). * is the significant level of difference in comparison to the control group 1 while+ is the significant level of difference in comparison to group 2 while P value is less than 0.05. **ns** means not significant

2. Naringenin maintained the integrity of Cellular Catalase Activity

Results from spectrophotometric assay showed that the level catalase activity (CAT) in the cyanide treated micewere significantly decreased in comparison to the control group and naringenin treated groups. CAT level in thenaringenin+cyanide treated mice increased but were not statically significant when compared with the control group.

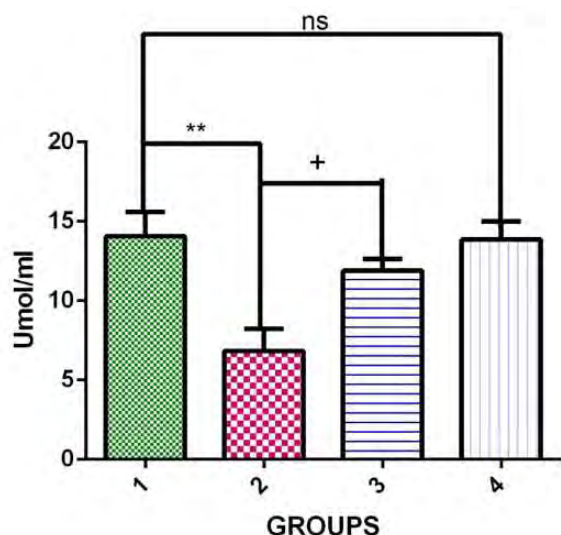


Figure 4: Chart showing the levels of Catalase activity across the experimental groups. 1= control group, 2= cyanide (1.2mg/kg body), 3= naringenin+cyanide (50mg/kg body) of naringenin and (1.2mg/kg body) of cyanide and 4= naringenin (50mg/kg body). * is the significant level of difference in comparison to the control group 1 while+ is the significant level of difference in comparison to group 2 while P value is less than 0.05. **ns**means not significant

3 Naringenin prevented Testicular Lipid Peroxidation

Malondialdehyde (MDA) level significantly increased in the testes of mice treated with Cyanide when compared with the control group. Rats treated with naringeninhad significantly lower MDA level when compared with Cyanide group.Naringeninreversed and prevented the Cyanide-induced increase in MDA levels in the testes of treated mice.

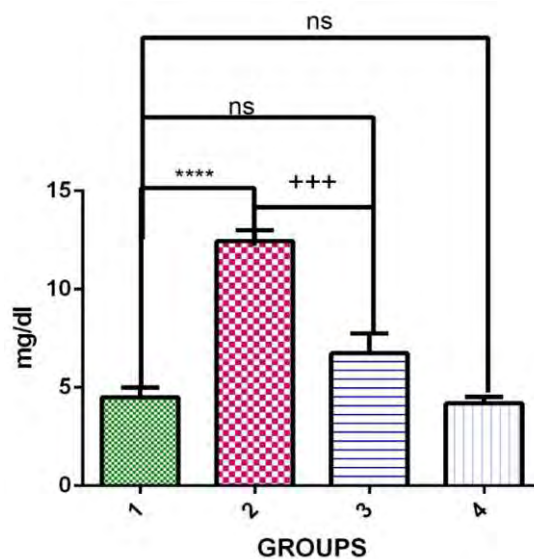


Figure 5: Chart showing the MDA levels across the experimental groups. 1= control group, 2= cyanide (1.2mg/kg body), 3= naringenin+cyanide (50mg/kg body) of naringenin and (1.2mg/kg body) of cyanide and 4= naringenin (50mg/kg body). * is the significant level of difference in comparison to the control group 1 while+ is the significant level of difference in comparison to group 2 while P value is less than 0.05. **ns**means not significant

4. Naringenin maintained the integrity of Testicular Glutathione levels

Results from spectrophotometric assay showed that the level glutathione (GSH) in the cyanide treated micewere significantly decreased in comparison to the control group and naringenin treated groups. GSH level in thenaringenin+cyanide treated mice increased but were not statically significant when compared with the control group.

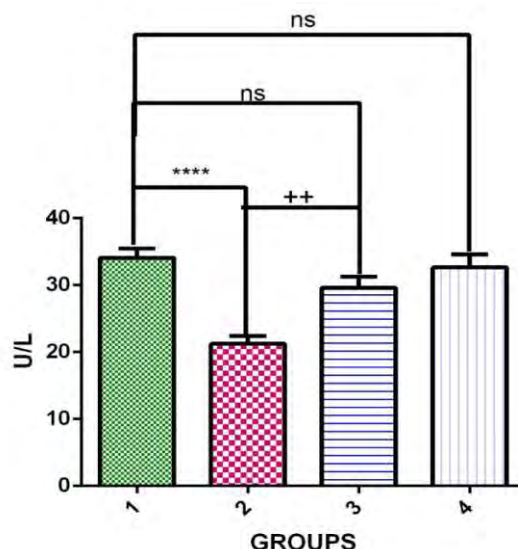


Figure 5: Chart showing the Testicular Glutathione levels across the experimental groups. 1= control group, 2= cyanide (1.2mg/kg body), 3= naringenin+cyanide (50mg/kg body) of naringenin and (1.2mg/kg body) of cyanide and 4= naringenin (50mg/kg body). * is the significant level of difference in comparison to the control group 1 while+ is the significant level of difference in comparison to group 2 while P value is less than 0.05. **ns** means not significant

HEMATOLOGICAL PARAMETERS

Various hematological parameters were analyzed after the blood was collected via cardiac puncture. The data obtained was subjected to statistical analysis and the data obtained is presented in Table 5.

Table 5: table showing the mean and standard error of

Table 5

Parameters	Group 1 (Control)	Group 2 (Cyanide)	Group 3 (Cyanide+Naringenin)	Group 4 (Naringenin)
PVC (%)	43.20 ± 0.6633 N=5	25.80 ± 1.241 N=5 ****	40.60 ± 2.159 N=5 +++; ns	42.20 ± 0.8602 N=5 ++++; ns
WBC	10900 ± 400.0 N=5	4700 ± 374.2 N=5 ****	10300 ± 374.2 N=5 ++++; ns	10800 ± 463.7 N=5
Neutrophil	65.60 ± 3.203 N=5	70.80 ± 1.685 N=5 ***	60.20 ± 2.010 N=5 Ns	65.40 ± 3.776 N=5 Ns
Lymphocyte	23.80 ± 1.068 N=5	39.40 ± 1.503 N=5 ***	26.00 ± 2.345 N=5 ++; ns	24.40 ± 1.778 N=5 Ns

mean (SEM) of hematological parameters in the various experimental group and control group. 1= control group, 2= cyanide (1.2mg/kg body), 3= naringenin+cyanide (50mg/kg body) of naringenin and (1.2mg/kg body) of cyanide and 4= naringenin (50mg/kg body).

Data were presented as mean and standard error of mean (Mean ± SEM) * is the significant level of difference in comparison to the control group 1 while+ is the significant level of difference in comparison to group 2 while P value is less than 0.05. **ns** means not significant

Histological Examination

Plate 1: Photomicrographs cytoarchitectural presentations of testicular general morphology Male albino Mice. 1= control group, 2= cyanide (1.2mg/kg body), 3= naringenin+cyanide (50mg/kg body) of

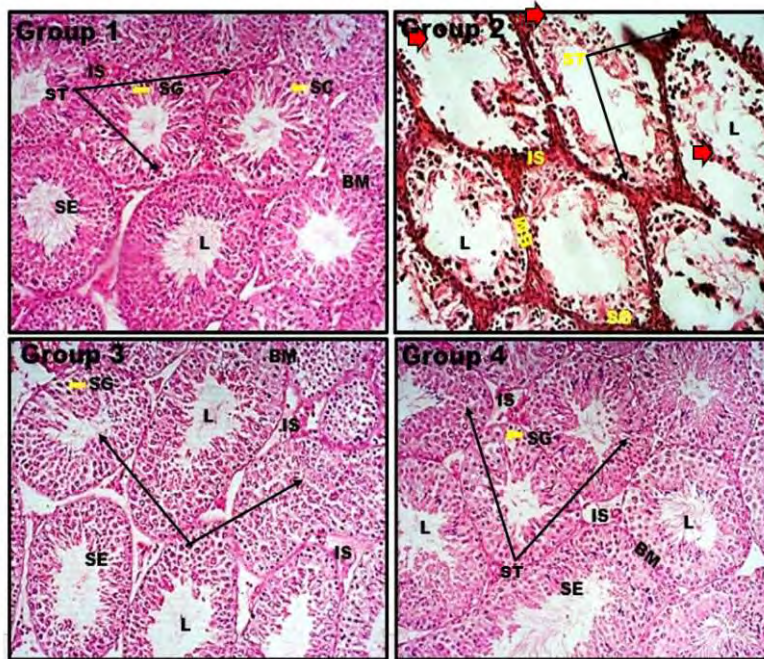


Plate 1

naringenin and (1.2mg/kg body) of cyanide and 4= naringenin (50mg/kg body). Hematoxylin and Eosin stain, (X100). Several seminiferous tubules, seminiferous epithelium (SE), basement membrane (BM), lumen (L) and interstitial space (SE) and spermatogonia cells (SG) are well outlined.

Results obtained demonstrated that the control group (group 1) and the naringenin treated group (group 4) showed normal testicular architecture without any observable presentation of spermatogenic arrest and the lumen could also be observed with the presence of spermatozoa. The basement membrane is thin and the interstitial space contains Leydig cells.

The cyanide (1.2mg/kg body) treated group (group 2) contrastingly, showed severe observable degenerative changes (Red arrows) characterized by maturation arrest of the spermatogenic cell line in several seminiferous tubules, widened lumen that lack spermatozoa, fragmented basement membrane, pyknotic Leydig cells and irregular seminiferous epithelium.

Interestingly, the naringenin+cyanide treated group (group 3) showed mildly similar morphological presentation with similar staining intensity and cellular density when compared with the control and naringenin treated groups (1 and 4). The testicular

cytoarchitecture was well structured and delineated as against the cyanide treated group (group 2).

Plate 2: Photomicrographs cytoarchitectural presentations of testicular general morphology Male albino Mice. 1= control group, 2= cyanide (1.2mg/kg body), 3= naringenin+cyanide (50mg/kg body) of naringenin and (1.2mg/kg body) of cyanide and 4= naringenin (50mg/kg body). Masson trichrome stain, (X100).

The connective tissue components of the control group (group 1) and naringenin (group 4) treated groups appeared intact and characterized by organized connective tissue septa, robust interstitial tissue with well distributed blood vessels and Leydig cells.

The cyanide (1.2mg/kg body) treated group (group 2) show sparse interstitial tissue with poorly stained CT septae. The Leydig cells appear chromatolysed (red circle).

The testicular cytoarchitecture of naringenin + cyanide treated mice appear normal and is characterized by well-stained connective tissue stroma intersperse with blood vessels and Leydig cells.

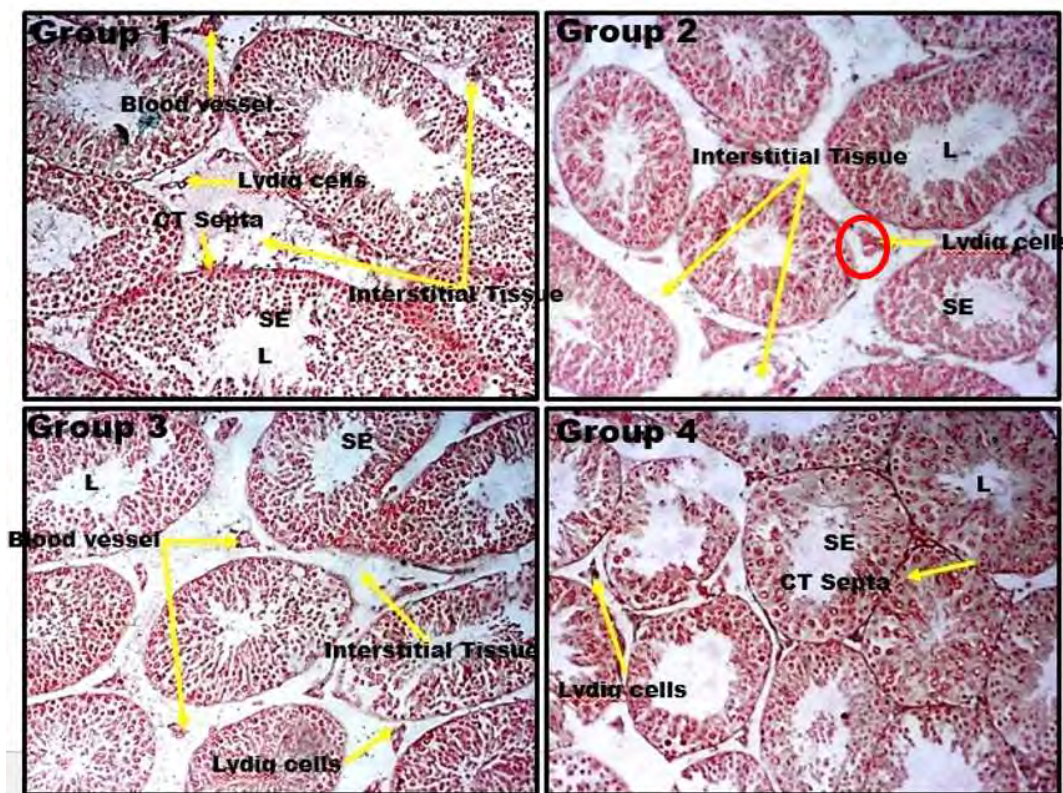


Plate 2:

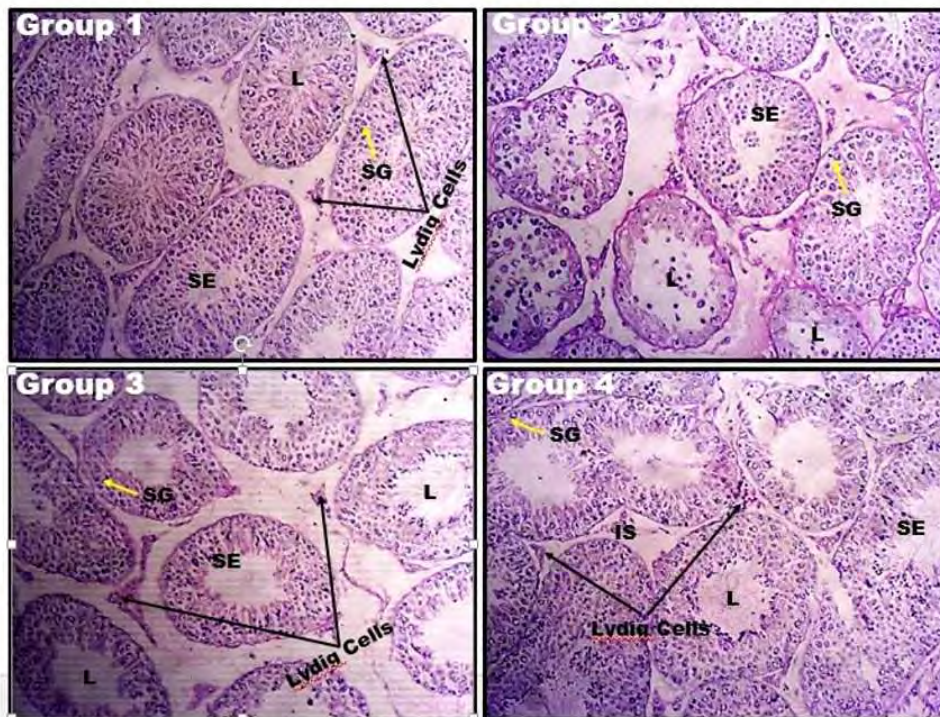


Plate 3:

Plate 3: Photomicrographs cytoarchitectural presentations of testicular general morphology Male albino Mice. 1= control group, 2= cyanide (1.2mg/kg body), 3= naringenin+cyanide (50mg/kg body) of naringenin and (1.2mg/kg body) of cyanide and 4= naringenin (50mg/kg body). Periodic Acid Schiff (PAS) stain, (X100). Several seminiferous tubules, seminiferous epithelium (SE), basement membrane (BM), lumen (L) and interstitial space (SE) and spermatogonia cells (SG) are well outlined.

The glycoprotein contents of the testes in the control group (group 1) and the naringenin treated group (group 4) appear normal as evident by the intensity of the stain. The Lumen of the seminiferous tubules in these groups are filled with mature spermatozoa and lydig cells in the interstitial space appear normal.

The cyanide (1.2mg/kg body) treated group (group 2) show low staining intensity which may signify low glycoprotein content. The lumen appears widened and void of mature spermatozoa.

The naringenin+cyanide treated group (group 3) showed mildly similar morphological presentation with similar staining intensity and cellular density when compared with the control and naringenin treated groups (1 and 4). The testicular cytoarchitecture was well structured and delineated as against the cyanide treated group (group 2).

DISCUSSION

The present study demonstrated the protective potential of naringenin against cyanide-induced testicular damage. Many reports have shown that cyanide induces oxidative stress in testicular tissues (Yant *et al.*, 2003). Cyanide causes lipid peroxidation and decreases the activity of enzymes that protect against oxidative damage in testicular tissue of cyanide-treated mice. The present study showed that cyanide administration causes an increased oxidative stress in the cells of testes, which was manifested by an increase in MDA level and decrease in antioxidants GSH, SOD and CAT. The level of tissue MDA is reported to be a reliable marker of lipid peroxidation (Del Rio *et al.*, 2005). The present observation is in agreement with previous findings showing an increase in renal MDA level and decrease in the testicular antioxidant activity of GSH in cyanide-medicated rats (Ilbey *et al.*, 2009)

In this study, the decrease in body weight observed in the cyanide treated mice might be due to the fact that cyanide causes loss of appetite and irritation of the gastrointestinal tract. Body weights were increased extensively by the administration of naringenin compared with the cyanide group.

Hematological effects of cyanide as observed in this study show an increase in count of lymphocytes and neutrophils while PCV count dropped

significantly. Cyanide accumulation in the blood can destroy erythrocytes through generation of ROS which may be the reason for the low PCV count recorded in the cyanide group (Group 2). High lymphocyte count in this group which form part of the body's defense system, may be a response to ROS generation induced by cyanide. These findings are in tandem with reports by other researchers (Kurmar *et al.*, 2004). These parameters were inverse in groups treated with naringenin (Groups 3 and 4). A good explanation for this may be the ability of naringenin to scavenge ROS and maintain the levels of endogenous antioxidants.

The results of the present research showed that cyanide exposure caused significant reductions in epididymal sperm concentration, suppression of sperm progress motility, and normal/abnormal sperms ratio. Many studies on reproductive system of male animals have documented cyanide as a toxicant for testicular tissue and functions (Yamamoto *et al.*, 2005) such as significant reductions in the number of spermatozoa within the epididymis in mice treated with cyanide. One possible explanation is that these compounds may be toxic to testicular histological structure.

In the present work, cyanide exposure induced testicular structural abnormalities including distortion and shrinkage of the seminiferous tubules due to a decrease in the number of germ cells. These results were confirmed by morphometrical analysis of the height of the epithelial lining which was significantly decreased in comparison with the control. Similar effects were observed by Ebeye *et al.* (2015) after cyanide treatment. It was speculated that cyanide has led to DNA damage and mutagenic alterations. Cyanide has evoked a genotoxic response upon generation of oxidative stress (Gabbianelli *et al.* 2009). Moreover, reduction of testosterone level may lead to separation of germ cells from the epithelium and impair the cytoarchitecture of the testis (Elbetieha *et al.* 2001).

With reference to the connective tissue content in the current study, Mason trichrome examination revealed thickening and irregularity. Some reports have shown that certain stimulants may induce myoid cells to produce more collagen and extracellular matrix (Santoro *et al.* 1999). Increased production of glycosaminoglycans and proteoglycans has been considered a defence reaction against the damaging effect of free radicals (Jedlinska *et al.*, 2006). Naringenin on the other hand protected the testis against damage with a morphology that was

consistent with that of the control group. The presence of mature spermatozoa in the seminiferous tubules agrees with the results obtained from sperm analysis.

CONCLUSION

It was concluded that Naringenin administration mitigates cyanide-induced testicular toxicity in *Mus Musculus*.

CONFLICT OF INTEREST

We declare that there is no potential conflict of interest.

REFERENCES

1. Moridi, A., Roozbeh, N., Yaghoobi, H., Soltani, S., Dashti, S., Shahrahmani, N., Banaei, M.(2019). *Etiology and risk factors associated with infertility*. International Journal of Women's Health and Reproduction Sciences, 7(3):346-353.
2. Mustafa, M., Sharifa A.M., Hadi, J., Iliam E.M., Aliya S.(2019). *Male and Female Infertility: Causes, And Management*. IOSR Journal of Dental and Medical Sciences, 18(13): 27-32.
3. Gensa, U.(2019). *Review on Cyanide Poisoning in Ruminants*. Journal of Biology, Agriculture and Healthcare, 9(6): 1-12.
4. Mushumbusi, C.B., Max, R.A., Bakari, G.G., Mushi, J.R., Balthazary, S.T. (2020). *Cyanide in Cassava Varieties and People's Perception on Cyanide Poisoning in Selected Regions of Tanzania*. Journal of Agricultural Studies, 8(1): 180-193.
5. Salehi, B., Tsouh Fokou, P.V., Sharifi-Rad, M., Zucca, P., Pezzani, R., Martins, N., Sharifi-Rad, J.(2019). *The Therapeutic Potential of Naringenin: A Review of Clinical Trials*. Multidisciplinary Digital Publishing Institute, 12(11): 1-18.
6. Alboghobeish, S., Mahdavinia, M., Zeidooni, L., Samimi, A., Oroojan, A.G., Alizadeh, S., Dehghani, M.A., Ahangarpour, A., Khorsandi, L.(2019). *Efficiency of naringin against reproductive toxicity and testicular damages induced by bisphenol A in rats*. Iranian Journal of Basic Medical Sciences, 22(3): 315-523.
7. Junqueira L.C., Carneira J. (2007). *Basic Histology text and atlas*. McGraw-Hill's Access Medicine, 11(21): 1-22.
8. Lee, C.C., Young Cho, A., Yoon, W., Yun, H., Kang, J.W., Lee, J.(2019). *Cocrystal Formation via*

Resorcinol-Urea Interactions: Naringenin and Carbamazepine. Journal of American Chemical Society, 19(7): 3807-3814.

9. Ahmed, O.M., Fahim, H.I., Ahmed, H.Y., Al-Muzafar, H.M., Ahmed, R.R., Amin, K.A., El-Nahass, E., Abdelazeem, W.H.(2019). *Naringenin in N-Acetyl-p-aminophenol-Induced Liver Injury in Wistar Rats.* Journal of Oxidative Medicine and Cellular Longevity, <https://doi.org/10.1155/2019/2745352>
10. Del Rio, D., Stewart, A.J., and Pellegrini, N.(2005) A review of recent studies on malondialdehyde as toxic molecule and biological marker of oxidative stress. *Nutrition, metabolism and cardiovascular diseases*, **15**(4):316-328.
11. Ebeye, O.A., Ekundina, V.O., Ekele, C.M., Eboh, D.E.(2015). The histological effect of *Cnidioscolusaconitifolius* aqueous leaf extracts on the architecture of the ovary, testis and sperm cells of adult wistar rats. *International Journal of Herbs and Pharmacological Research*, **4**(1):7-17.
12. Vishnu Varthan, V.J., Srividya, A.R., Sathish Kumar, M.N., (2013). Role of Naringin and Naringenin in Various Diseased Conditions - A Review. *International Journal for Pharmaceutical Research Scholars*, **2**(1): 198-212
13. Elbetieha, A., Da'as, S.I., Khamas, W., and Darmani, H.(2001). Evaluation of the toxic potentials of cypermethrin pesticide on some reproductive and fertility parameters in the male rats. *Archives of environmental contamination and toxicology*, **41**(4):522-528.
14. Felgines, C., Texier, O., Morand, C., Manach, C., Scalbert, A., Régerat, F., Révész, C.(2000). Bioavailability of the flavanone, naringenin and its glycosides in rats. *American Journal of Physiology-Gastrointestinal and Liver Physiology*, **279**(6): G1148-G1154.
15. Gabbianelli, R., Falcioni, M.L., Cantalamessa, F., Nasuti, C.(2009) Permethrin induces lymphocyte DNA lesions at both Endo III and Fpg sites and changes in monocyte respiratory burst in rats. *Journal of Applied Toxicology*, **(4)**:317-322.
16. Ilbey, Y.O., Ozbek, E., Cekmen, M., Simsek, A., Otunctemur, A., Somay, A.(2009). Protective effect of curcumin in cisplatin-induced oxidative injury in rat testis: mitogen-activated protein kinase and nuclear factor-kappa B signaling pathways. *Human reproduction*, **24**(7):1717-1725.
17. Marcondes, F.K., Bianchi, F.J., and Tanno, A.P.(2002). Determination of the estrous cycle phases of rats: some helpful considerations. *Brazilian journal of Biology*, **62**(4A):609-614.
18. Oderinde, O., Noronha, C., Oremosu, A., Kusemiju, T., Okanlawon, O.A.(2002). Abortifacient properties of aqueous extract of *Carica papaya* (Linn) seeds on female Sprague-Dawley rats. *The Nigerian postgraduate medical journal*, **9**(2):95-98.
19. Santoro, G., Romeo, C., Impellizzeri, P., Gentile, C., Anastasi, G., Santoro, A.(2000).. Ultrastructural and immunohistochemical study of basal lamina of the testis in adolescent varicocele. *Fertility and sterility*, **73**(4):699-705.
20. Wang, J., Yang, Z., Lin, L., Zhao, Z., Liu, Z., Liu, X.(2012). Protective effect of naringenin against lead-induced oxidative stress in rats. *Biological trace element research*, **46**(3):354-259.
21. Yamamoto, T., Fukushima, T., Kikkawa, R., Yamada, H., Horii, I.(2005). Protein expression analysis of rat testes induced testicular toxicity with several reproductive toxicants. *The Journal of toxicological sciences*, **30**(2):111-126.
22. Yáñez, J.A., Remsberg, C.M., Miranda, N.D., Vega-Villa, K.R., Andrews, P.K., Davies, N.M.(2008). Pharmacokinetics of selected chiral flavonoids: hesperetin, naringenin and eriodictyol in rats and their content in fruit juices. *Biopharmaceutics & drug disposition*, **29**(2):63-82.