

ORIGINAL RESEARCH

Orofacial tumours and tumour-like lesions in children treated at Muhimbili National Hospital, Tanzania

Gift G. Natana, Boniphace M. Kalyanyama and Alison N. M. Simon

Department of Oral and Maxillofacial Surgery, School of Dentistry, Muhimbili University of Health and Allied Sciences, Dar es Salaam, Tanzania

Correspondence: Gift G. Natana giftnatana@gmail.com

Submitted: 12 February 2018 Accepted: 30 October 2018 Published: 15 February 2019

Introduction: Orofacial tumours and tumour-like lesions occur at any age. An increasing occurrence has made these tumours a significant cause of morbidity and mortality in children.

Objective: To determine the clinicopathological characteristics and treatment modalities of orofacial tumours and tumour-like lesions in children at Muhimbili National Hospital.

Methods: Children aged below 18 years with orofacial tumours and tumour-like lesions were interviewed using a structured questionnaire and clinically examined. The data were analysed using statistical package for social sciences (SPSS) version 20.0. Statistical significance was considered at a p-value of < 0.05.

Results: 121 children aged 4 days to 17 years (mean= 8.56 years \pm 5.5 SD), 52.1 % being male, participated in the study. The age groups 0-5 years (38%) and 11-15 years (28.1%) were most affected- p-value 0.38. The majority (86%) of the lesions were benign; haemangioma was the most (16.4%) common benign tumour. Dentigerous cyst was the most (7.8%) frequent tumour-like lesion observed, while Burkitt's lymphoma and squamous cell carcinoma were the most common malignant lesions. Swelling was the most common clinical feature in all tumours and tumour-like lesions and surgery was the most common treatment.

Conclusion: Benign orofacial tumours and tumour-like lesions were the types most commonly seen among children in Tanzania.

Key words: orofacial, tumours, tumour-like lesions, children, Tanzania.

INTRODUCTION

Orofacial tumours and tumour-like lesions occur at any age. An increasing occurrence has made these tumours a significant cause of morbidity and mortality in children.

^[1] The spectrum of diseases differs from that in adults as does the behaviour of certain lesions. ^[2] Some lesions change with development of the body and therefore their management changes as well. ^[3] Various reports have discussed the frequency, clinical presentation, histopathological characteristics and management of orofacial tumours and tumour-like lesions in children. Making comparisons between published series is difficult because of the differing descriptive criteria. ^[3, 4] In East Africa, and in Tanzania particularly, ^[5] reports are limited so this study aimed at addressing this shortfall in our knowledge.

The objective of the study is to determine the clinicopathological characteristics and treatment modalities of orofacial tumours and tumour-like lesions in Tanzanian children.

METHOD

The study was conducted at the Departments of Oral and Maxillofacial Surgery and Otorhinolaryngology (ORL) of Muhimbili National Hospital (MNH) Dar es Salaam, which receives patients from all over Tanzania.

Patients less than 18 years old with orofacial tumours and tumour-like lesions who attended MNH from September 2016 to March 2017 were studied. Clinical diagnoses were confirmed histologically. The lesions were classified as benign tumours, malignant tumours or tumour-like lesions. Those with no histological diagnosis or with

Citation: Natana et al, Orofacial tumours and tumour-like lesions in children treated at Muhimbili National Hospital, Tanzania, South Sudan Medical Journal 2019; 12(1):5-8 © 2019 The Author (s) **License:** This is an open access article under [CC BY-NC-ND](https://creativecommons.org/licenses/by-nc-nd/4.0/)

Table 1. Distribution of benign orofacial tumours by age and sex among children treated at MNH

Histological type	Age Group Years								Total n (%)
	0 - 5		6 - 10		11- 15		16 - <18		
	M	F	M	F	M	F	M	F	
Ameloblastic Fibroma	1	-	-	-	-	-	-	-	1 (1.5)
Ameloblastoma	-	-	-	-	2	-	-	1	3 (4.6)
Cystic Hygroma	1	1	-	-	-	-	-	-	2 (3.0)
Desmoplastic fibroma	-	-	-	-	1	-	-	-	1 (1.5)
Fibromatosis	-	-	1	-	-	-	-	-	1(1.5)
Fibroma	1	1	-	-	-	2	-	1	5 (7.6)
Haemangioma	1	7	-	2	1	3	1	2	17 (25.7)
Giant cell tumour	-	-	-	-	-	-	1	-	1 (1.5)
Lipoma	-	1	-	-	-	-	-	-	1 (1.5)
Lymphangioma	3	9	2	-	-	-	-	-	14 (21.3)
Neuroectodermal tumour of infancy	1	2	-	-	-	-	-	-	3 (4.6)
Neurofibroma	-	-	1	-	1	2	-	-	4 (6.0)
Odontoma	-	-	2	-	-	-	-	-	2 (3.0)
Ossifying Fibroma	1	-	2	-	4	2	1	-	10 (15.2)
Schwannoma	-	1	-	-	-	-	-	-	1(1.5)
Total by sex	9	22	8	2	9	9	3	4	
Total n (%)	31(47)		10(15.1)		18(27.3)		7(10.7)		66 (100)

inconclusive results and terminally ill children were excluded. Statistical package (SPSS) version 20.0. (SSPS Inc. Chicago IL, USA) was used in the analysis.

Ethical approval was obtained from the Research and Publications Committee of the Muhimbili University of Health and Allied Sciences.

RESULTS

Demographic characteristics

A total of 121(63 males, 58 females) children with orofacial tumours and tumour-like lesions, age ranging from 4 days to 17 years (mean= 8.6 years ± 5.5 SD) were treated in the hospital during the study period. The age group 0-5 years was the most affected (38%) followed by the 11-15 years age group (28.1%) p-value 0.38.

Frequency of orofacial tumours and tumour-like lesions

Of the 38 histological types of lesions detected 86% were benign lesions. Haemangioma was the most frequent benign tumour (25.7%), followed by lymphangioma (21.6%) (Table 1). Fibrous dysplasia was the most frequent

(23.7%) tumour-like lesion followed by dentigerous cyst (21%). The most frequently observed malignant tumours (14%) were Burkitt's lymphoma (BL) and squamous cell carcinoma (SCC) each affecting 23.5% participants.

Clinical presentation

The mean duration of the lesions at presentation in the hospital was three months (range less than a month to 15 years). The maxilla was the commonest (30%) site for the benign orofacial tumours, followed by the submandibular region (26.9%). About 47% of malignant tumours were located in the mandible, the other common sites included the gingivae (41.1%), submandibular region (41.1%), and the cheek (23.5%). 34% of the tumour-like lesions were located in the mandible. Itching was the commonest symptom (13.2%), followed by pain (8.6%) and paraesthesia (7.7%). Toothache was reported by 6.7% and 5.8% had fever. In malignant tumours, pain and fever were the most (47%) frequent symptoms. All the patients presented with swellings. In benign lesions, discoloration of the skin or mucosa was encountered in 26%, difficult mouth opening in 10.6%, displaced teeth in 8.6% and ulceration in 6.7%. Malignant lesions also

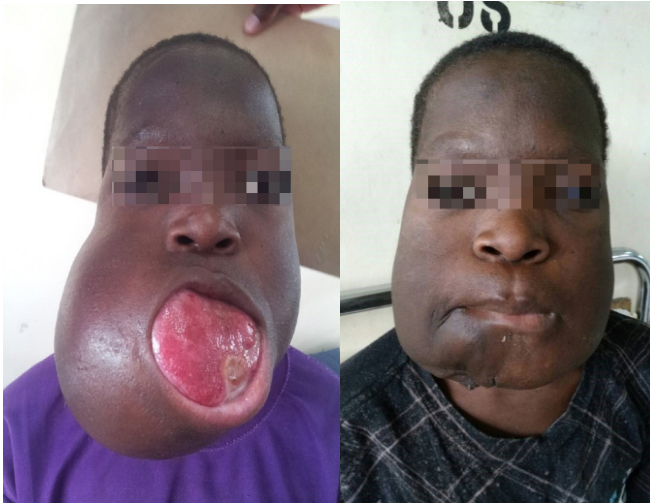


Figure 1. Photograph of a 14 years old male with central giant cell granuloma of the mandible before and two weeks after tumour enucleation and curettage (Photos by Dr Natana 2017 – patient gave permission).

presented with ulceration in 64.7% participants, bleeding in 47%, difficult mouth opening in 41.1% and loose teeth in 41.1%. Benign lesions tend to be about 6 – 10 cm in diameter while malignant ones were larger at about 15 cm.

Treatment

Surgical en bloc excision or enucleation was carried out for 53% of benign tumours (p-value 0.001). Radical surgical resection was used in the 6% who had ameloblastomas; 20 patients (30.3%) were referred abroad. Sclerosing agents were used in 6% who had vascular lesions and observation in the 4.5% with fibrous dysplasia and ranula. Surgical curettage, remodelling and enucleation were the commonest methods used for tumour-like lesions. Wide surgical excision was the commonest treatment applied in 76.4% participants with malignant lesions with chemotherapy in 47% and radiotherapy in 17.6% as adjunctive therapies following surgery.

DISCUSSION

Children constituted 23.4% of all the patients with orofacial tumours and tumour-like lesions who were treated at MNH, consistent with other African studies.^[5] with males more frequently affected than females as seen in Kenya.^[6] However, the opposite has been reported in other studies.^[7] Although the lesions were more frequent in 0 – 5 and 11 – 15 year olds, other reports are at variance with this finding.^[8]

Benign lesions were more common compared to malignant lesions as reported in other studies^[1]. There may be several reasons for this including changes in management approaches, time of year of this study and even a change of occurrence. However, a previous study at

MNH had indicated predominance of malignant tumours^[1]. A predominance of haemangioma and lymphangioma in the study is probably because MNH is the main referral centre for vascular tumours in Tanzania. Developmental cysts were the most common tumour-like lesions as found elsewhere.^[9]

Burkitt's lymphoma and squamous cell carcinoma (SCC) in children aged 0-10 years are rare in other continents^[10]; however, while SCC was thought to be primarily a disease affecting elderly males^[11], it was found across all age groups. The known risk factors for SCC in adults which include smoking, high consumption of alcohol, chewing of betel and chronic irritation are not relevant in children. Therefore, a genetic predisposition, viral infections and immunosuppression have been postulated as likely risk factors.^[12]

As in other studies^[13] all presented with swelling in the orofacial region. Other presentations included eye problems such as epiphora, proptosis and diplopia in malignant tumours indicating the infiltrative nature of the tumours. Benign and malignant lesions share some presenting features, therefore clinicians must have a high diagnostic index for suspected nodules on the oral mucosa to avoid delayed management.^[13]

Surgery was the mainstay of treatment^[2] (Figure 1). Ameloblastoma tumours were huge requiring aggressive surgery, although reconstruction to preserve the shape and function of the jaws were not offered generally. A previous study on the postoperative quality of life of adult patients with ameloblastoma in Tanzania concluded that the patients were invariably affected by lack of reconstructive surgery^[14]. Some of our patients with vascular tumours were referred to India.

Wide surgical excision with curative intent was used for malignant tumours. The histological type, grade and stage of the tumour in addition to the subsequent report of the status of the margins determined the need of a patient for postoperative adjuvant therapy. All participants with malignant salivary gland tumours and three who had SCC underwent wide surgical excision as a sole treatment with a disease-free margin that obviated the use of radiotherapy. Radiotherapy has been reported before to impair growth of facial structures and increase the risk of second malignancy in children.^[15]

CONCLUSIONS

Benign orofacial tumours and tumour-like lesions were the types most commonly seen in children in Tanzania. However, the overlap of clinical presentations means that clinicians must be alert to the fact that some lesions clinically thought to be benign might be malignant. There is a need to raise public awareness about these lesions to improve early reporting.

Conflict of interest: None

Sources of funding: Nil.

References

1. Kalyanyama BM, Oral tumours in Tanzanian children based on biopsy materials examined over a 15-year period from 1982 to 1997. *Int Dent J.* 2002;52(1):10–4.
2. Akay MC. Multidisciplinary Management of Benign Jaw Tumors in Children. *Textbook of Advanced Oral and Maxillofacial Surgery Volume 2*, Izmir, Turkey: 2015. 1–34.
3. Wang Y. Retrospective Survey of Biopsied Oral Lesions in Pediatric Patients. *J Formos Med Assoc;* 2009;108(11):862–71.
4. Mouchrek M. Oral and maxillofacial biopsied lesions in Brazilian pediatric patients: A 16-year retrospective study. *Rev Odonto Cienc.* 2011;26(3):222–6.
5. Kamulegeya A. Oral maxillofacial tumors and tumor-like conditions: A Ugandan survey. *Pediatr Surg Int.* 2011; 27(9):925–30.
6. Okumu SB, Clinical features and types of paediatric orofacial malignant neoplasms at two hospitals in Nairobi, Kenya. *J Cranio-Maxillofacial Surg.* 2012;40(1).
7. Richter GT, Friedman AB. Hemangiomas and Vascular Malformations: Current Theory and Management. *Int J Pediatr.* 2012;2012:1–10.
8. Rwakatema DS. An audit of Paediatric Orofacial Lesions at the Kilimanjaro Christian Medical Centre in Moshi , Tanzania. *Surg Sci.* 2011;476–80.
9. Aflatoon K, Aboulafia AJ, McCarthy EF, Frassica FJ, Levine AM. Pediatric soft-tissue tumors. *J Am Acad Orthop Surg.* 2003;11(5):332–43.
10. Liu X, Gao X, Liang X, Tang Y. The etiologic spectrum of head and neck squamous cell carcinoma in young patients. *Oncotarget.* 2016;7(40):226–38.
11. Ritwik P, Cordell KG, Brannon RB. Minor salivary gland mucoepidermoid carcinoma in children and adolescents : a case series and review of the literature. *J Med Case Rep;* 2012;6(1):1.
12. Modi PJ, Shah NA. Orbital tumors in children : a descriptive study at tertiary care centre. *Natl J Med Res.* 2013;3(4):362–6.
13. Vale EB, Ramos-Perez FM etal. Review of oral biopsies in children and adolescents : a clinicopathological study of a case series. *J Clin Exp Dent [Internet].* 2013;5(3):144–9.
14. Simon EN. Odontogenic tumours in Tanzania with emphasis on epidemiology, quality of life after treatment and mandibular reconstruction [Internet]. Radboud University Nijmegen; 2005. 75-90
15. Chadha NK, Forte V. Pediatric head and neck malignancies. *Curr Opin Otolaryngol Head Neck Surg.* 2009.