

ORIGINAL RESEARCH

Endomyocardial fibrosis: is it a systemic disease?

Juergen Freers^a, Victoria Masembe^a, Rolf Schmauz^b, Frederick Kidaaga^c, Harriet Mayanja-Kizza^a

^a Department of Medicine, Makerere University Kampala, Uganda

^b General Practice of Pathology, Papenburg, Germany

^c Department of Pathology, Makerere University Kampala, Uganda

Correspondence to: Juergen Freers freersjuergen@yahoo.com

BACKGROUND: Patients with endomyocardial fibrosis (EMF) characteristically present with gross ascites and absent or minimal pedal oedema. This has long puzzled clinicians, especially since this clinical picture remains the same regardless of whether there is left, right or biventricular ventricular heart failure. The development of ascites, therefore, may not be directly and solely related to changes in the heart, but to local changes in the peritoneum. In order to investigate this possibility we performed peritoneal biopsies on 28 EMF patients.

METHODS: Successful peritoneal biopsies were performed on 28 EMF patients and 11 age-matched healthy controls who had died in road accidents.

RESULTS: All 28 patients (100%) showed complete or partial peritoneal fibrosis. Twenty Six (93%) had additional signs of chronic peritonitis characterised mainly by lymphocytes (92%) eosinophils (27%) and plasma cells (23%). Neutrophils were not seen. Vascularisation was common (87%) with an increase in capillaries and granulation tissue. Other components were Russel bodies (50%), deposits of fibrin (50%) and haemosiderin pigment (32%). Only two samples showed fibrosis without signs of inflammation. None of the controls showed any of these changes.

CONCLUSION: Peritoneal fibrosis was found in all and peritonitis in most of our EMF patients. This suggests that pathology of EMF is not confined to the heart but also involves the peritoneum. This local peritoneal inflammation may explain why marked ascites is often present with little or no peripheral oedema, and why conventional heart failure treatment is of limited value.

Key words: peritoneal-fibrosis, endomyocardial-fibrosis, ascites, histology, echocardiography

Introduction

Although rare elsewhere EMF is a common heart disease in certain geographical clusters such as in Uganda, Mozambique, Nigeria, Ivory Coast, Kerala (India) and Brazil. In Uganda it is associated with eosinophilia and poverty, females are twice as often affected compared to males and show a bimodal age distribution with peaks at around 12 and 27 years [1, 2] and can account for up to 20% of patients seen with cardiovascular diseases [3]. Fibrotic lesions of varying severity occur in one or both ventricles. Five patterns have been observed on autopsy:

1. Affecting atrio-ventricular (AV) valves causing mitral or tricuspid incompetence
2. Affecting the only the apex causing restriction of ventricular filling.
3. Affecting AV-valves and apex leading to both of the above.
4. Stretching from AV- valve to apex with the same symptoms.
5. Patchy fibrosis which is rare.

Right and bi-ventricular EMF leads to a distortion of the cardiac shape with retraction of the right ventricle

appearing as a notch on echocardiography. The characteristic clinical features are gross ascites with little or no pedal oedema (see Figure 1a and 1b) and may appear even before signs and symptoms of cardiac disease. Often the abdomen is painful on palpation. Other EMF typical features are hepatosplenomegaly (see Figure 1c), raised jugular venous pressure (see Figure 2) and proptosis. Up to 75% of patients show an eosinophilia with abnormal eosinophils [1] and the ascites is usually (78%) an exudate [4]. The typical socio-economic history includes poverty, unbalanced diet with high tuber consumption and severe lack of protein, especially animal protein. There are geographical predilection sites for EMF in Uganda and EMF with patients being predominantly of Rwandan or Bagandan origin.

Some textbooks attribute the symptoms of EMF to the degree of fibrosis and its laterality in the heart - fibrosis of the right ventricle being associated with ascites and pedal oedema, and fibrosis of the left ventricle with pulmonary congestion. Hurst's "The Heart" 13th Edition 2011 [5] and the older version of Harrison's Principles of Internal Medicine of 2003 [6] whereas in the latest 19th Edition 2015 the symptoms are not described explicitly. However, ascites, often with abdominal pain and minimal or absent pedal oedema is the most common feature of EMF

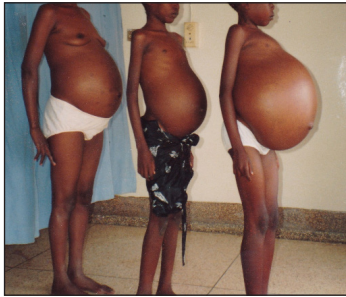

Figure 1a. Ascites lateral view

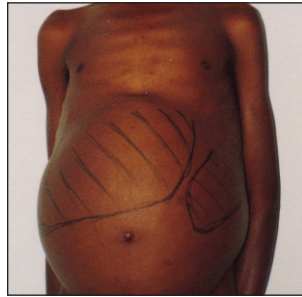

Figure 1b. Hepatosplenomegaly

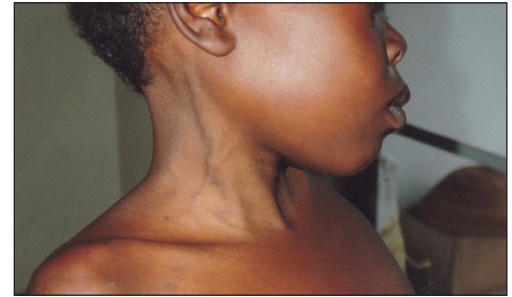

Figure 2. Raised jugular venous pressure

irrespective of which ventricle is involved, and gross ascites can be present even when fibrosis is entirely confined to the left ventricle [7]. Moreover, the ascites of EMF-patients is protein rich and has higher white blood cell counts than ascites from patients with congestive cardiac failure [8, 4]. In order to determine if this exudative ascitic fluid was a result of inflammation, or some other process, peritoneal biopsies from both EMF patients and healthy controls were examined. Some cases of EMF are shown in Figures 1 and 2.

Methods

Twenty-eight patients between the age-groups of 10 and 50 years old with a diagnosis of EMF were enrolled in the study. The diagnosis of EMF was based on clinical and echocardiographical observations by two independent cardiologists. To make a diagnosis of EMF combinations of the above mentioned clinical, paraclinical and echocardiographical criteria were used (socio-economic history, eosinophilia, exudative ascites and the typical echocardiographic features as described above).

Peritoneal tissue was obtained by an aseptic technique using an Abram’s needle in all patients with frank ascites and in two other patients with abdominal swelling without ascites by a mini-laparotomy [9]. Control biopsy specimens were taken from eleven age-matched previously healthy persons who had died from road traffic accidents.

The design of the study did not allow us to take pericardial or pleurabiopsies although pericardial effusion and to a lesser extend pleura effusion were seen.

Results

Inventory of cases

Twenty-eight patients were studied. There was a male to female ratio of 1:3.3. Males tended to be younger. The mean age for males was 18.8 years (range 11 – 25 years) and for females 25.6 years (range 14 – 41 years). Duration of symptoms varied between 10 days to 182 months. Blood values in means (and range) were ESR 38 (5-110) mm in the first hour by the Westergren method; total white cell count 4,900 (3,500-7,900) cells/mm³, eosinophil count 640 (40-2240) cells/mm³. Fifteen patients (42%) showed eosinophilia with more than 500 cells/mm³ including 4 patients (9%) in the range of the hypereosinophilic syndrome with more than 1,500 cells/mm³. Serum protein was 6.2 (2.8-9.9) g/dl, serum albumin 3.0 (0.2-4.3) g/dl.

Half of the patients showed biventricular EMF, 30% only left and 20% only right ventricular disease. Abdominal distension with abdominal pain was seen in all patients. Two patients had abdominal distension without fluid. All others had ascites. Nineteen patients had a pericardial effusion (53%). Minor pedal oedema were seen in 8 patients (22.2%), and none had gross oedema

Mean ascitic total protein was 3.2gm/dl (0.7 to 7.9 gm/dl) and albumin 1.5 gm/dl (0.2 to 3.5gm/dl). According to total protein content ascites was classified in 75% as exudative.

Table 1. Frequency and density of inflammatory cells seen in peritoneal biopsies from 26 EMF patients

Cell type	Frequency		Density		
	n	%	mild	moderate	marked
Lymphocytes	24	92	15	2	1
Eosinophils	7	27	6	1	-
Plasma cells	6	23	5	1	-

Density according to number of cells in high power fields: mild=1-4, moderate=5-9, marked=10+.

Table 2. Frequency and density of various deposits seen in peritoneal biopsies from 26 EMF patients

Cell type	Frequency		Density		
	n	%	mild	moderate	marked
Russel bodies+	13	50	5	4	4
Fibrin**	13	50	5	6	2
Haemosiderin**	8	32	3	3	2

*Densities according to number of +Russel bodies seen in the biopsy: mild=1-4, moderate=5-9, marked=10+;

**fraction of biopsy tissue showing fibrin or staining for haemosiderin pigment, respectively: mild= <1/3, moderate=>1/3, marked=>2/3.

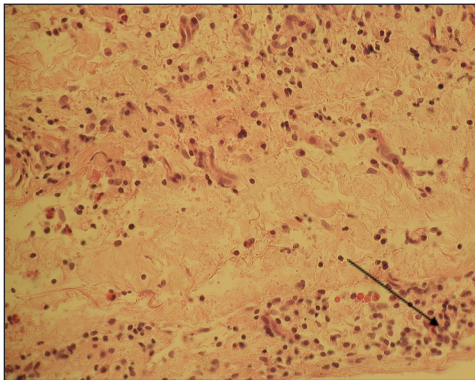


Figure 3. A mixed cellular infiltrate of lymphocytes, eosinophils and plasma cells. Russell bodies are distinct in the right lower corner, and there is concomitant increase in vascularisation (H&E, objective x 20)

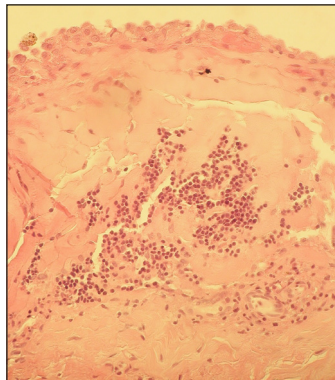


Figure 4. Serosal lining with activated mesothelial cells over an area with chronic inflammation and fibrosis (H&E, objective x 10).

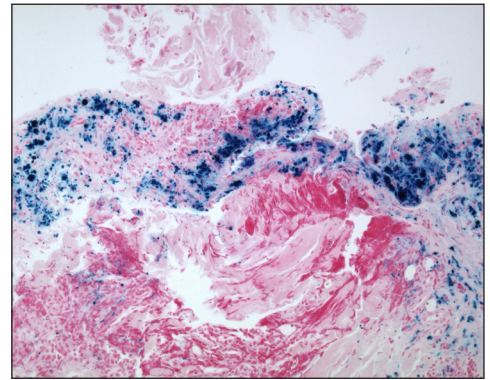


Figure 5. Marked deposits of fibrin (red) and haemosiderin pigment (blue; Prussian blue)

Histology

All peritoneal biopsies showed varying degrees of fibrosis. Fifty per cent showed activated mesothelial cells, and in one case fibrosis was the only other change.

Ninety three per cent of the patients (N=26) showed mild or moderate inflammatory changes indicative of chronic peritonitis. Severe inflammation with dense infiltrates were not seen. Lymphocytes predominated. Plasma cells and eosinophils were less common. Neutrophils were not seen (Table 1). All three cellular components were found in only three patients. Seven patients showed two cell types. Lymphocytes alone were most commonly seen and showed marked variation in density. In two samples the cells were focally numerous and formed lymphoid aggregates. Plasma cells and eosinophils were present mainly in mild infiltrates. Mild vascularisation was noted in 88% showing an increase in capillaries or formation of granulation tissue. This tended to be associated with lymphocytic infiltrates.

Other components of inflammation were seen in the form of Russell bodies, fibrin and haemosiderin pigment in frequencies and graded densities not very different from each other (Table 2). Their respective frequencies were 50%, 50% and 32%, and they were distributed in the tissue with densities ranging from mild to severe.

Peritoneal biopsies from 11 controls showed several types of tissue, namely fascial and adipose tissue, mostly covered by a serosal lining with a collagenous band, and striated muscle. These tissues appeared to be normal with no features similar to those in the EMF group.

Discussion

This first report of the peritoneal histology of EMF patients suggests that the exudative nature of ascitic fluid found in this condition may be as a result of an inflammatory process. Lymphocytes, plasma cells, deposits

of fibrin and activated mesothelial cells are features similar to those in synovial tissues in non-active rheumatoid arthritis. Additional findings not seen in other types of peritonitis are mild eosinophilia, high content of Russell bodies indicating hypersecretion of immunoglobulins, frequent deposits of haemosiderin pigment and marked fibrosis. There is also concomitant vascularisation often seen in many other types of inflammation.

Inflammation may account for abdominal pain and distension, which are frequently observed in EMF patients even before the appearance of ascites. It may also explain the marked ascites and lack of pedal oedema observed even in pure left ventricular disease. There are other reports of extra-cardiac lesions in EMF. An immunofluorescent study on autopsy material showed fibrin in a number of organs, which were not seen in tissues from cases with myocardial infarction and hypertensive heart disease [10]. Small granulomata were detected in the liver in a high proportion of cases [11]. The high frequency of pericardial effusions suggests that inflammatory processes may affect the pericardium as well as the peritoneum and other serosal membranes [7]. Moreover, fibrosis may be seen not only in the heart and peritoneum but also in skeletal muscle. It is possible, therefore, that EMF could be a widespread systemic disease, and not just confined to the heart [12].

Fibrosis and associated fibrin deposits may impair the resorptive capacity of the peritoneum and hence explain the failure of diuretics to reduce ascites. Looking for signs of abdominal inflammation and fibrosis might not only be of diagnostic assistance in early EMF where echocardiographic findings are still equivocal, but could also lead to a more appropriate therapy with anti-inflammatory drugs. Anecdotal reports suggest that the use of anti-inflammatory therapy late in the course of the disease reduces the number of abdominal paracentesis required to alleviate abdominal discomfort. Such

treatment, if prescribed early in the disease process when there is little or no echocardiographically visible cardiac involvement might delay or even prevent progression to irreversible cardiac damage. A controlled trial of anti-inflammatory therapy is needed to test this hypothesis.

Conflict of Interest Statement: There is no conflict of interest.

(All figures by Juergen Freers.)

References

1. Mayanja-Kizza H, Gerwing E, Rutakingirwa M, Mugerwa R, Freers J.: Tropical Endomyocardial Fibrosis in Uganda: The Tribal and Geographic Distribution, and the Association with Eosinophilia. *Tropical Cardiology* 2000; 103: 45-48
2. Rutakingirwa M, Ziegler JL, Newton R, Freers J. Poverty and Eosinophilia are Risk Factors for Endomyocardial Fibrosis (EMF) in Uganda. *Trop. Med. & International Health*, Volume 4, No 3, PP 229-235, March 1999
3. Freers J, Ziegler J, Mayanja-Kizza H, Rutakingirwa M. Echocardiographic diagnosis of heart disease in Uganda. *Tropical Doctor*, July 1996, 26, 216/95. 1-4
4. Mayanja-Kizza H, Freers J, Rutakingirwa M. Ascites in Endomyocardial fibrosis. *Charles Hastings Postgraduate Journal*, July 1997; 4: 28-30
5. Brian D. Hoit, ed., Restrictive, Obliterative, and Infiltrative Cardiomyopathies, Endomyocardial Diseases. In Hurst's The Heart 13th Edition, McGraw-Hill, New York 2011; 865
6. Neal K. Lakdawala, Lynne Warner Stevenson, Joseph Loscalzo, eds., Cardiomyopathy and Myocarditis, Endomyocardial Disease. In: Harrison's Principles of Internal Medicine, 19th Edition, McGraw-Hill, New York, 2015; 1567-1568.
7. Freers J, Mayanja-Kizza H, Rutakingirwa M, Gerwing E. Endomyocardial Fibrosis: Why is there striking ascites with little or no peripheral oedema? *Lancet*, January 20, 1996; 347:197
8. Freers J, Hakim J, Mayanja-Kizza H and Parry E: The Heart. Diseases of Body Systems. In: Parry E et al., Eds. Principles of Medicine in Africa. 4th Edition, Cambridge University Press, 2013
9. Masembe V. Peritoneal findings and ascitic fluid findings among patients with endomyocardial fibrosis in Mulago Hospital. M. med. Medicine Diss., Makerere University, Kampala, May 2000.
10. Van der Geld H, Peetoom F, Somers K, Kanyerezi BR. Immun-histological and Serological Studies in Endomyocardial Fibrosis. *Lancet* 1966; 1210-1214
11. Osunkoya B O, Carlisle R, Dawodu A H, Basile U. Histopathology of extracardiac tissue in endomyocardial fibrosis. *Afr. J. Med. Sci.* 1972; 3: 275-282
12. Freers J, Masembe V, Schmauz R and Mayanja-Kizza H: Peritoneal fibrosis and muscle fibrosis are part of the Endomyocardial Fibrosis (EMF) Syndrome. *Lancet*, 2000 Vol. 355:1994