

## Case Report

# Heterotopic Pregnancy in a Natural Conception Following Failed Contraceptive Practice

Mbamara Sunday Uche, Mbah Ikenna Chinwenmeri<sup>1</sup>

Departments of Obstetrics and Gynecology and <sup>1</sup>Radiology, Abuja Clinics Limited, Ministers' Hill Maitama, Federal Capital Territory, Abuja, Nigeria

### ABSTRACT

This report presents another rare case of spontaneous simultaneous intrauterine and extrauterine tubal pregnancies following failed progestogen-only injectable contraceptive. The ruptured heterotopic pregnancy was diagnosed in unruptured state but could not be treated because the couple did not believe/accept the diagnosis and consequently withheld their consent. The patient underwent emergency laparotomy and evacuation of products of intrauterine pregnancy. A high index of suspicion is necessary to ensure early diagnosis and management.

**KEY WORDS:** Contraceptive, emergency, heterotrophic, laparotomy, pregnancy

## INTRODUCTION

Heterotopic pregnancy (HP) involves intrauterine pregnancy coexisting with pregnancies at different sites. The various locations noted include fallopian tube, caesarean scar, abdomen, omentum, cornua, and cervix.<sup>[1]</sup> The most common combination is an intrauterine gestation and extrauterine gestation most of which are sited in the tubes (90%).<sup>[2,3]</sup> It can occur in both spontaneous natural conception or assisted productive technology (ART). The incidence of HP in natural conception is quoted as 1 in 30,000 pregnancies<sup>[4]</sup> but as high as 1 in 100 in ART.<sup>[5]</sup> HP is a potentially fatal condition that has high maternal morbidity or even mortality if there is a misdiagnosis and or a delay in the diagnosis. It is also a cause of pregnancy wastages. We present a case of ruptured HP, which was diagnosed in unruptured state, but could not be treated because the couple did not believe/accept the diagnosis and consequently withheld their consent. She underwent emergency laparotomy and evacuation of products of intrauterine pregnancy.

Limited Maitama on the 23<sup>rd</sup> of February 2011 with a referral letter and an ultrasound scan (USS) report revealing missed abortion from a primary care hospital under the National Health Insurance Scheme.

She did not have any complaints on presentation. She went to the referral clinic on suspicion that she might be pregnant despite the fact that she has been on progesterone only contraceptive injections since her last confinement in 2007. The home pregnancy test was positive, and the clinic's Blood beta human chorionic gonadotropin ( $\beta$ -HCG) test was also positive. The abdominal scan done at the primary care center revealed missed abortion at 9 weeks gestation hence the reason for her referred to Abuja Clinics Limited for secondary care.

She was not sure of her last menstrual period due to menstrual irregularity caused by the progesterone only contraceptive injections. She had a regular 28 days cycle and 4 days flow

## CASE REPORT

A 35-year-old G7P6 + 0 Nigerian housewife presented at the gynecology outpatient department of Abuja Clinics

### Address for correspondence

Dr. Mbamara Sunday Uche,  
Box 354, Amaraku P.O, Imo State, Nigeria.  
E-mail: Kensusunny30@yahoo.co.uk

### Access this article online

Quick Response Code	Website: www.jbcrs.org
	DOI: ***

This is an open access article distributed under the terms of the Creative Commons Attribution-NonCommercial-ShareAlike 3.0 License, which allows others to remix, tweak, and build upon the work non-commercially, as long as the author is credited and the new creations are licensed under the identical terms.

**For reprints contact:** reprints@medknow.com

### How to cite this article: \*\*\*

prior to the commencement of the injectable contraceptive. She had a stillbirth in 2005. All her deliveries were by spontaneous vertex delivery. There was no history of the pelvic inflammatory disease. She neither smoked nor drank alcohol. Her medical and surgical history was not contributory.

On examination, there was nothing significant. Repeat endovaginal USS revealed intrauterine missed abortion, right luteal cysts and right viable ectopic pregnancy [Figure 1].

She was counseled extensively with her husband on the later ultrasonographic findings, the management options, possible complications, and prognosis. She accepted to undergo laparoscopic surgery + suction evacuation, but her husband vehemently rejected surgical treatment of the ectopic pregnancy claiming that such pathology does not exist. He also posited that her doctor only referred her for the evacuation of the product of conception. He angrily left the hospital with his wife.

She represented 2 days later with the lower abdominal pain of 10 h duration. The pain that was located at the suprapubic region was of sudden onset, sharp, severe, and stabbing. There was dizziness, weakness, and fainting sensation. There was no vaginal bleeding or constitutional symptom.

For the above symptoms, she first presented at the referral primary care hospital where two doses of injections

suspected to be analgesic were administered and referred back to our clinic.

On examination in the casualty, she was markedly pale. Her pulse was 130 bpm, fast, small volume and weak while her blood pressure was 90/50 mmHg. There was guarding and marked tenderness at the lower abdomen. A diagnosis of shock due to ruptured ectopic heterotrophic pregnancy was made.

The couple was counseled extensively, and the husband gave their consent for emergency laparotomy after wide consultations with their other relatives. Laboratory investigations showed packed cell volume 12%, white blood cell 6000/mm<sup>3</sup>, neutrophils 57 and lymphocyte 34%. Her urinalysis was essentially normal. She was negative to HIV I and II, hepatitis C virus, hepatitis B surface antigen and venereal disease research laboratory screening tests.

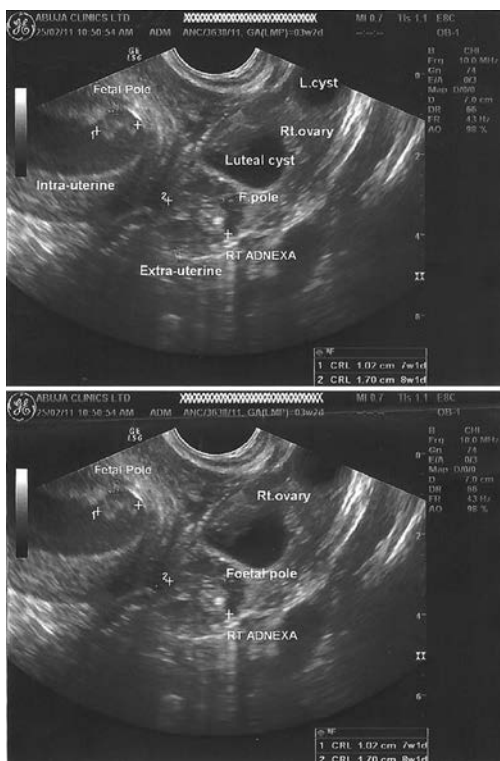
Immediate resuscitative measures were commenced, and she was taken from the casualty directly to the operating theater for exploratory laparotomy and evacuation of the product of intrauterine conception. She had right salpingectomy and evacuation of retained products of conception using manual vacuum aspirator (MVA).

The intraoperative findings include hemoperitoneum >3000 ml, ruptured ampullary gestation of the right fallopian tube, fragments of products of conception adherent to the right ovary, normal left ovary and tubes, and bulky anteverted anteflexed uterus. Cervical Os was slightly open. The procedures were done under general anesthesia. She received three units of blood intraoperatively and the fourth unit on the ward. The medications given include Intravenous fluids, prophylactic antibiotics, analgesics, and hematinics. She was discharged within 72 h of admission.

## DISCUSSION

HP is the spontaneous simultaneous occurrence of intrauterine and extrauterine pregnancies. It is one of the rare events in gynecology with an estimated incidence of 1 in 30000 pregnancies. However, this incidence has been rising as a result of ART. Although HP can occur without any identifiable risk factors, the associated risks include ART, tubal surgery, and tubal damage. The only risk identified in our patient is the black origin and use of injectable progesterone only contraceptive.

HP is usually asymptomatic but often presents with features of ruptured ectopic pregnancy. In this case, it was picked up by transvaginal sonography (TVS) during the assessment of suspected missed abortion.



**Figure 1:** Endovaginal ultrasound scan showing the intra and extra-uterine gestation and right luteal cyst

The intrauterine pregnancy was nonviable while the extrauterine pregnancy was viable and unruptured at her initial presentation TVS ultrasound scan. Other combinations such as viable intrauterine and extrauterine pregnancy, bilateral ectopic pregnancies and a combination of normal pregnancy and choriocarcinoma have been documented.

The fact that the tubal ectopic pregnancy was not diagnosed in the first transabdominal USS but was later picked up on the repeat endovaginal scan shows the difficulties associated with the diagnosis of heterotopic pregnancy as have been corroborated in other reports.<sup>[6]</sup> It has been reported by other researchers that often times whenever USS reveals an intrauterine pregnancy the search for the possibility of coexisting ectopic pregnancy is limited and this could be what happened in our case.<sup>[6]</sup> This case, therefore, corroborates other report suggesting that the diagnosis of intrauterine pregnancy does not exclude totally the possibility of the simultaneous existence of ectopic pregnancy.<sup>[6-8]</sup>

Various treatment modalities have been applied in the treatment of heterotopic pregnancy. The treatment option depends on the location of the ectopic gestation, the size of gestation, whether ruptured or unruptured and the viability or otherwise of the intrauterine gestation. Expectant management is usually considered inappropriate because neither  $\beta$ -HCG nor ultrasound scans can accurately predict the outcome of the ectopic pregnancy. Medical management with Methotrexate may be inappropriate where the intrauterine pregnancy is viable. Selective embryo reduction by direct local injection of potassium chloride or hyperosmolar glucose into the ectopic gestational sac under ultrasound or laparoscopic guidance has been documented.<sup>[9,10]</sup>

Delay in diagnosis and management could be fatal to the mother. In this case, the delay was due to patient-related factors. The couples objected to surgical/medical intervention on the unruptured tubal pregnancy positing that the doctor who referred them only asked them to come for evacuation and also doubted the possibility of such a diagnosis. The earlier USS diagnosis of only intrauterine pregnancy gave false reassurance to the patients resulting in complexities in diagnoses, management, and counseling of the patient. He was also reassured by the report of the first ultrasound scan. This delay resulted in the rupture of the ectopic pregnancy, massive hemorrhage, and emergency exploratory laparotomy. Despite a relatively early diagnosis of HP in the index case, it still ended up in emergency laparotomy due to the couple's attitude; believe system and probably poor counseling content by the referral doctor. The attitude of the couple reveals the difficulties that obstetricians and gynecologist face in our environment. More so it exposes the problems associated

with referrals in our environment especially where the final diagnosis is different from the primary diagnosis before referral. Probably the attitude of the couple would have been different if the HP was diagnosed prior to referral.

Laparoscopic surgery should have been the treatment of choice in our patient if they had accepted the initial counseling by the Gynaecologist. She underwent laparotomy with right salpingectomy and suction evacuation of the intrauterine product of conception using manual vacuum aspirator (MVA). These treatments were appropriate because the intrauterine pregnancy had failed, and she had ruptured ectopic pregnancy with marked hemodynamic instability. The definitive surgery that can be done depends on the location of the ectopic pregnancy, whether ruptured or unruptured and the state of the contralateral tube or the need to preserve the tubes. The success of laparotomy in the management of ruptured HP has been well documented in several studies.<sup>[11,11]</sup> Conservative management could be a great challenge as serial  $\beta$ -HCG is not useful in diagnosis and follow-up<sup>[12]</sup> and medical management with methotrexate is contraindicated with viable intrauterine pregnancy. Successful expectant management has been documented as an option in symptom-free patients where the ectopic pregnancy has no cardiac activity.

## CONCLUSION

We advocate that a thorough evaluation of the entire pelvis and adnaxae using endovaginal ultrasound even when intrauterine pregnancy has been confirmed should be routinely performed in the first trimester. Although the diagnosis of HP is challenging, but a high index of suspicion could improve its pick up. Training, retraining and proper certification of sonographers will help improve on their performances. Timely intervention will reduce the case fatality rate, reduce morbidity and where the intrauterine component is alive and viable will present the intrauterine pregnancy with a greater chance of successful obstetric outcome.

Adequate counseling and patient education will help in getting the required cooperation from the patients and their relatives. Improvement in the content of counseling and medical education will improve the confidence of the general public and patients on their caregivers/doctors.

## Financial support and sponsorship

Nil.

## Conflicts of interest

There are no conflicts of interest.

## REFERENCES

1. Mayer RB, Yaman C, Ebner T, Shebl O, Sommergruber M, Hartl J, *et al.* Ectopic pregnancies with unusual location and an angular pregnancy: Report of eight cases. *Wien Klin Wochenschr* 2012;124:193-7.
2. Rathod S, Samal SK. A rare case of heterotopic pregnancy with ruptured left rudimentary horn pregnancy. *J Clin Diagn Res* 2015;9:QD03-4.
3. Fritz MA, Speroff L. Ectopic pregnancy. In: Fritz MA, editor. *Clinical Gynecological Endocrinology and Fertility*. 8<sup>th</sup> ed. New Delhi: Wolters Kluwer Health/Lippicott Williams and Wilkins; 2011. p. 1408-9.
4. Pan HS, Chuang J, Chiu SF, Hsieh BC, Lin YH, Tsai YL, *et al.* Heterotopic triplet pregnancy: Report of a case with bilateral tubal pregnancy and an intrauterine pregnancy. *Hum Reprod* 2002;17:1363-6.
5. Habana A, Dokras A, Giraldo JL, Jones EE. Cornual heterotopic pregnancy: Contemporary management options. *Am J Obstet Gynecol* 2000;182:1264-70.
6. Shetty SK, Shetty AK. A case of heterotopic pregnancy with tubal rupture. *J Clin Diagn Res* 2013;7:3000-1.
7. Ljuca D, Hudic I, Hadzimehmedovic A. Heterotopic pregnancy in natural conception – Our initial experience: Case report. *Acta Clin Croat* 2011;50:249-52.
8. Fisher SL, Massie JA, Blumenfeld YJ, Lathi RB. Sextuplet heterotopic pregnancy presenting as ovarian hyperstimulation syndrome and hemoperitoneum. *Fertil Steril* 2011;95:2431.e1-3.
9. Salomon LJ, Fernandez H, Chauveaud A, Doumerc S, Frydman R. Successful management of a heterotopic caesarean scar pregnancy: Potassium chloride injection with preservation of the intrauterine gestation: Case report. *Hum Reprod* 2003;18:189-91.
10. Strohmer H, Obruca A, Lehner R, Egarter C, Husslein P, Feichtinger W. Successful treatment of a heterotopic pregnancy by sonographically guided instillation of hyperosmolar glucose. *Fertil Steril* 1998;69:149-51.
11. Georgiou EX, Domoney C, Savage P, Stafford M. Heterotopic abdominal pregnancy with persistent trophoblastic tissue. *Acta Obstet Gynecol Scand* 2011;90:551-3.
12. Baxi A, Kaushal M, Karmalkar H, Sahu P, Kadhi P, Daval B. Successful expectant management of tubal heterotopic pregnancy. *J Hum Reprod Sci* 2010;3:108-10.