

## Original Article

# Evaluation of Ovarian Lesions Inducing Endometrial Hyperplasia or Carcinoma in a Tertiary Care Hospital in Southern India

Shalinee Rao, Shivani Rao<sup>1</sup>, Sharda Lall<sup>2</sup>, Raghavan Narasimhan

Department of Pathology, Jawaharlal Nehru Institute of Postgraduate Medical Education and Research, Puducherry, <sup>1</sup>Department of Community Medicine, Saveetha Medical College, <sup>2</sup>Wellness Therapist (Basil), Tech-Med Health Care, Chennai, Tamil Nadu, India

## ABSTRACT

**Background:** Excessive and prolonged estrogenic stimulation results in endometrial hyperplasias or endometrioid adenocarcinomas. One of the major reasons for an excess endogenous estrogen production is estrogen secreting ovarian lesions which could either be neoplastic or non-neoplastic. **Aims:** This was a study done to evaluate and correlate presence of ovarian lesions in uterus harboring endometrial hyperplasia or endometrial carcinoma. **Materials and Methods:** This was a retrospective study conducted at a referral hospital in South India over a 16-year period. Histology of ovaries were studied in panhysterectomy cases with a tissue diagnosis of endometrial hyperplasia or endometrial carcinoma. The data was evaluated as only percentage. **Results:** A total of 118 specimens revealed pathological proliferative lesion of the endometrium with endometrial hyperplasias occurring in 78 (66.1%) and endometrioid adenocarcinoma in the remaining 40 (33.9%) cases. Fifty-two cases showed lesions in ovary/ovaries. Forty-two (35.6%) of them revealed estrogen-secreting lesions in ovaries. The rest showed non-estrogen producing lesions. Follicular cyst was the predominant estrogen elaborating lesions in the ovary with 23 cases (44.2%). In 21.1% of cases, ovaries featured stromal hyperplasia and 7.7% showed granulosa cell tumor. Only one (1.9%) case of thecoma was identified. Two cases showed twin lesions with follicular cyst and stromal hyperplasia. All patients except for one were in post-menopausal age group. **Conclusion:** Follicular cyst was the predominant lesion associated with endometrial hyperplasia and endometrioid adenocarcinoma of endometrium in post-menopausal age group. In addition, hyperplastic lesions in endometrium can occur in non-hormonal secreting ovarian epithelial tumors possibly due to functioning stromal cells.

**KEY WORDS:** Carcinoma, endometrium, estrogen, hyperplasia, ovary

## INTRODUCTION

It was Gusberg in 1947, who documented the relationship between prolonged estrogen administration, obesity, oligomenorrhea and dysfunctional uterine bleeding.<sup>[1]</sup> Later Smith *et al.*, in 1975 confirmed the association between unopposed estrogen therapy and endometrial carcinoma.<sup>[2]</sup> Excessive and prolonged levels of estrogenic stimulation results in endometrium hyperplasia, which further progresses to endometrial adenocarcinoma.<sup>[3]</sup> Hyperplasia most commonly occurs around menopause or in association with persistent anovulation in young women. Hyperestrogenic state could either result from excessive endogenous production or exogenous intake of estrogen. It may result from prolonged use of exogenous estrogen for postmenopausal symptoms or due to pathological

ovarian conditions such as polycystic ovarian disease (Stein-Leventhal syndrome), stromal hyperplasia, severe luteal insufficiency, abnormal persistence of Graffian follicle, obesity and functioning granulosa cell tumor or thecoma<sup>[2,4,5]</sup> Thecomas are almost always estrogenic and in 10% of cases it may occur in a luteinized forms resulting in virilizing symptoms.<sup>[6]</sup> Therefore, thecomas are associated with either estrogenic or androgenic manifestation. This was a study done to evaluate and correlate presence of ovarian lesions in uterus harboring endometrial hyperplasias or endometrial carcinomas.

## MATERIALS AND METHODS

This was a descriptive retrospective study conducted at a referral hospital in South India to include cases over a 16-year period. Histology of ovary was studied in cases with uterus harboring endometrial hyperplasia or endometrioid adenocarcinoma. The data was evaluated as only percentage.

### Access this article online

#### Quick Response Code



#### Website:

[www.jbcrs.org](http://www.jbcrs.org)

#### DOI:

10.4103/2278-960X.118657

#### Address for correspondence:

Dr. Shalinee Rao,  
Additional Professor, Department of Pathology, Virbhadra Road,  
AIIMS Rishikesh, Rishikesh - 249 201, Uttarakhand, India.  
E-mail: [shalineerao@gmail.com](mailto:shalineerao@gmail.com)

**Inclusion criteria**

Study cases included only patients who underwent hysterectomy with bilateral salpingo-oophorectomy.

**Exclusion criteria**

Cases with a coexisting uterine leiomyoma were excluded from the study. The study on preneoplastic conditions of endometrium was undertaken only after its approval in institute board meeting.

**RESULTS**

A total of 118 cases of hysterectomy specimen with oophorectomy were selected for the study [Table 1], which showed hyperplasia in 78 cases [Table 2] and endometrioid adenocarcinoma in 40 cases. All of these cases had presented clinically with dysfunctional uterine bleeding. Only one patient was in reproductive age group while the rest were in postmenopausal period.

Forty-two cases had estrogen-secreting lesions in the ovaries with predominant lesion being follicular cyst in 23 cases [Figure 1] followed by stromal hyperplasia [Table 3]. Four cases showed granulosa cell tumor [Figure 2] and one showed thecoma in the ovary. Two cases showed dual lesions in ovaries with stromal hyperplasia [Figure 3] and follicular cysts. Fifteen cases of adenocarcinoma of endometrium and 27 cases of hyperplasias had an estrogen-secreting lesion in their ovary [Table 4]. Out of 23 cases of follicular cyst, 18 showed hyperplasias and 5 had adenocarcinoma. One case was of a cystoglandular hyperplasia and another had a endometrioid adenocarcinoma of endometrium. Endometrium in granulosa cell tumor cases showed cystoglandular hyperplasia in 2 cases and complex hyperplasia with atypia and an adenocarcinoma of endometrium in 1 case each. About 12.8% of cases showed non-estrogen secreting pathological lesions. Age of the patients with stromal hyperplasia ranged from 35 years to 78 years with a mean of 52.7 years and median of 50 years.

**DISCUSSION**

In the present study, 35.6% cases had an ovarian lesion with the most common lesion being follicular cyst in 23 cases (19.5%). Follicular cysts result from distension of developing atretic follicles. They may occur at any age from infancy to menopause and are asymptomatic in the majority of cases.<sup>[7]</sup> In children, follicular cysts may be seen in precocious puberty, and during the reproductive life they may be associated with endometrial hyperplasia. The presence of follicular cyst along with adenocarcinoma or hyperplasia suggests direct relationship with hyperestrogenic state.

**Table 1: Hyperplastic endometrial lesions/carcinomas in hysterectomy specimens of cases studied**

Hyperplasia	Carcinoma	Total of cases
78 (66.1%)	40 (33.9%)	118

**Table 2: Types of hyperplasias detected in cases studied**

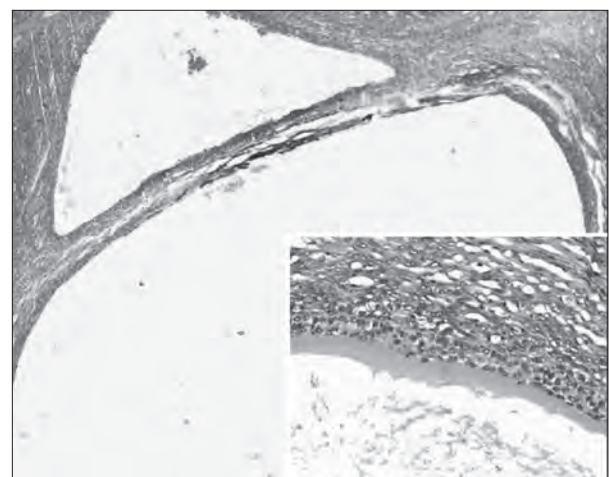
Hyperplasia	Total number of cases	Frequency in percentage
Simple hyperplasia	59	75.6
Complex hyperplasia without atypia	11	14.1
Complex hyperplasia with atypia	8	10.3
Total number of hyperplasia	78	100

**Table 3: Histomorphology of ovary in hyperplastic lesions/ carcinoma of endometrium**

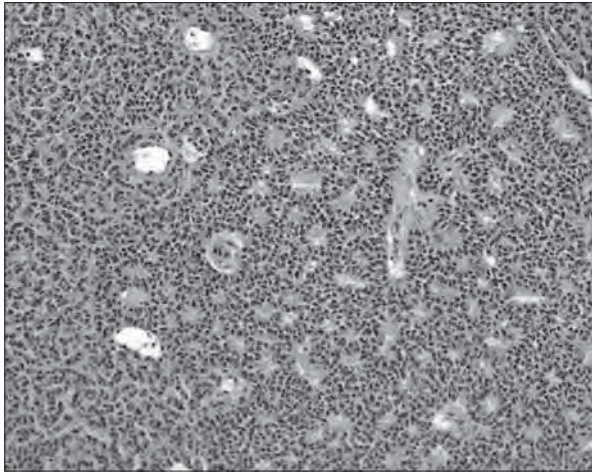
Ovarian lesions	Number of cases	Frequency in percentage
Follicular cyst	23	44.2
Stromal hyperplasia	11	21.1
Granulosa cell tumor	4	7.7
Thecoma	1	1.9
Follicular cyst with stromal hyperplasia	2	3.8
Endometrioid carcinoma	1	1.9
Serous cystadenocarcinoma	4	7.7
Mucinous cystadenocarcinoma	2	3.8
Papillary adenocarcinoma	1	1.9
Mature cystic teratoma	2	3.8
Endometriosis	1	1.9
Total	52	100

**Table 4: Estrogen secreting ovarian lesions and endometrial status in study cases**

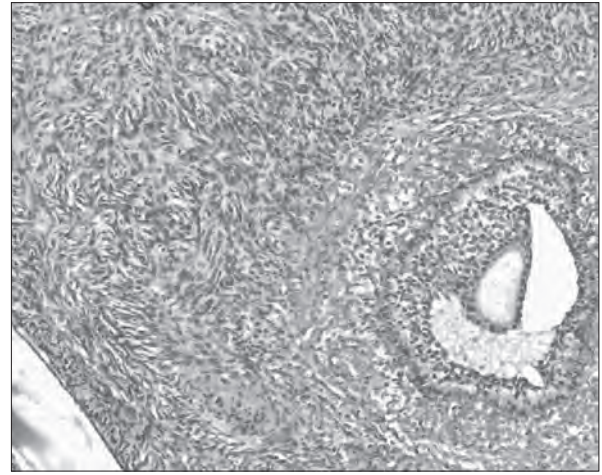
Estrogen secreting ovarian lesion	Hyperplasia	Adenocarcinoma	Total number of cases
Follicular cyst	18	5	23
Stromal hyperplasia	4	7	11
Granulosa cell tumor	3	1	4
Follicular cyst and stromal hyperplasia	1	1	2
Thecoma	0	1	1
Endometrioid carcinoma	1	0	1
Total no of cases	27	15	42



**Figure 1:** Ovary show multiple follicular cysts (H and E, × 20); Inset show cyst with the innermost layer of granulosa cells surrounded by two layers of theca cells (H and E, ×200)



**Figure 2:** Granulosa cell tumor showing microfollicular pattern arrangement with Call-Exner bodies (H and E, ×100)



**Figure 3:** Ovarian cortex show nests of plump luteinized stromal cells. Adjacent to this is a graafian follicle (H and E, × 100)

In our study, 92.35% cases of stromal hyperplasia occurred in postmenopausal women. Stromal hyperplasia is characterized by a diffuse or nodular non-neoplastic proliferation of plum ovarian cortical stromal cell encroaching upon the medulla.<sup>[8]</sup> Stromal hyperplasia is seen most commonly in postmenopausal patients and may be associated with raised androgen levels and also with endometrial adenocarcinoma. Stromal hyperplasia is quite often bilateral, and may be associated with normal sized or enlarged ovaries.<sup>[9]</sup> Ovarian cut surface generally appears firm white to yellow.<sup>[10]</sup> In a study by Yin *et al.*, obesity, arteriolar nephrosclerosis, endometrial over growths and uterine leiomyomas were considerably more common in the women having ovarian stromal hyperplasia.<sup>[11]</sup> This explains the finding of proliferative endometrial lesions in 9.32% of cases displaying stromal hyperplasia. It is not rare to find two estrogen secreting lesions together in ovaries. Stromal luteomas and thecomas can occur together against a background of stromal hyperplasia resulting in excessive production of estrogen. The combination we found was of stromal hyperplasia and follicular cysts in 2 cases (1.69%).

Ovarian thecoma, an uncommon benign tumor of stromal cell origin that represents 1% of all ovarian tumors is encountered more often in women of perimenopausal and postmenopausal group. This study identified only one case of thecoma with an estrogenic effect in a patient who presented with an endometrial adenocarcinoma. Review of literature reveals a variable incidence of granulosa cell tumor with endometrial carcinoma.<sup>[12]</sup> In our study we found 4 cases (3.4%) of granulosa cell tumor associated with proliferative lesions in endometrium. Studies in the past suggest that hyperplasia of endometrium regresses and returns to normal cyclical pattern after the removal of granulosa cell tumor.<sup>[12]</sup> Hence, removal of uterus is

unwarranted and should be avoided in case of hyperplasia associated with granulosa cell tumor.

In the present study we did not encounter any case of Stein–Leventhal syndrome on histopathology. Probable reasons for not identifying any such case in our study could be due to the fact that we included only cases that had undergone hysterectomy with oophorectomy, which is not a treatment for Stein–Leventhal syndrome. In fact, the usual specimen who received histopathology in Stein–Leventhal syndrome is either an endometrial curettage to evaluate endometrium for dysfunctional uterine bleeding or a wedge biopsy of ovary which is received as a therapeutic measure. Chronic anovulation following Stein–Leventhal syndrome results in unopposed estrogenic stimulation of the endometrium leading to hyperplasia to well-differentiated endometrial adenocarcinoma.

We encountered one case of endometrioid carcinoma of ovary in this study that was associated with complex hyperplasia without atypia. Zaino *et al.*, in a study on endometrioid carcinoma of the ovary found an association of endometrioid carcinoma of ovary with endometrial hyperplasia and adenocarcinoma of endometrium, the well-differentiated type.<sup>[13]</sup>

Non-estrogen secreting tumors were also found in ovaries in cases with endometrial hyperplasias and endometrial carcinomas. Most of them were surface epithelial tumors except for one case which was of germ cell origin, a mature cystic teratoma. In a study by Suzuki *et al.*, on estrogen production by epithelial tumors of ovary and dermoid tumors, it was found that cystic hyperplasia and adenomatous hyperplasias of endometrium accounted for 13% and 8.7% of cases, respectively.<sup>[14]</sup> Tokunaga *et al.*, in detail studied a case of endometrioid carcinoma of ovary with elevated serum estradiol levels and significantly

thickened endometrium.<sup>[15]</sup> They further confirmed the presence of enzymes needed for production of estradiol by tumor cells based on immunohistochemical study findings. According to Tokunaga *et al.*, epithelial ovarian carcinoma cells could produce estradiol possibly by interaction between carcinoma cells and ovarian stromal cells. They concluded that the high amount of estradiol in their study case was due to intra-tumoral production of estrogen.<sup>[15]</sup> Hence, malignant epithelial tumors with a functioning stroma should also be considered while investigating ovarian neoplasm with estrogen production in elderly age group. In our study, the serum estrogen levels were not evaluated.

In the present study about 35.6% of cases presented with ovarian lesions leading to hyperestrogenic state. We speculate that in rest of the cases, the etiology could be an extra-ovarian cause for the hyperestrogenic state. Due to retrospective nature of the study, information such as exogenous estrogen therapy and body mass index to evaluate obesity as the cause, could not be retrieved. Sherman *et al.*, in their study on measurement of ovarian volume by ultrasound documented that there was an increased risk of endometrial adenocarcinoma in postmenopausal women with large ovaries.<sup>[16]</sup>

In a study by Telemann *et al.*, 68% of cases with uterine leiomyoma, various degree of hyperplasia and estrogen secreting ovarian lesions were reported.<sup>[17]</sup> They found simple hyperplasia as the predominant pattern and hence suggested that presence of leiomyoma confers a protective role as it also captures estrogen thereby making the hormonal dose less effective for progression to higher grade of hyperplasia/carcinoma. Therefore, we excluded the cases of hyperplasia/carcinoma having a coexisting uterine leiomyoma (estrogen responsive lesion) to study only the effect of ovarian lesions on endometrium.

Since follicular cyst was the most common finding in this study with endometrial hyperplasia, it could be suggested that on visualizing cystic lesion in ovaries with significant thickening in endometrium by transvaginal ultrasound of a patient with dysfunctional uterine bleeding, possible administration of drug-inducing ovulation may resolve the ovarian lesions thereby preventing serious effect on endometrium.<sup>[18]</sup>

## CONCLUSION

Follicular cyst was the predominant estrogen producing lesion in cases with endometrial hyperplasias and carcinomas with dysfunctional uterine bleeding. Hence, an early identification with initiation of treatment may prevent over-stimulation of endometrium and avert neoplastic transformation. In addition, the presence of epithelial

ovarian malignancy in association with endometrial hyperplasia suggests estrogen elaboration through epithelium–stromal interaction.

## REFERENCES

- O'Dowd MJ, Philipp EE. Cancer of the uterus. The history of Obstetrics and Gynaecology. 1<sup>st</sup> ed. New York: Parthenon Publishing Group; 1994. p. 571-80.
- Smith DC, Prentice R, Thompson DJ, Hermann WL. Association of exogenous estrogen and endometrial carcinoma. *New England J Med* 1975;293:1164-7.
- Rao S, Sundaram S, Narasimhan R. Biological behavior of preneoplastic conditions of the endometrium: A retrospective 16-year study in south India. *Indian J Med Paediatr Oncol* 2009;30:131-5.
- Kumar V, Abbas AK, Fausto N, Aster J. Robbins and Cotran Pathologic Basis of Disease. 8<sup>th</sup> ed. Philadelphia: Elsevier; 2010. p. 1030.
- Kreiger N, Marrett LD, Clarke EA, Hilditch S, Woolever CA. Risk factors for adenomatous endometrial hyperplasia: A case-control study. *Am J Epidemiol* 1986;123:291-301.
- Lee MH, Moon YJ, Ha CW, Hoh JK. Ovarian thecoma with virilizing manifestations. *Yonsei Med J* 2009;50:169-73.
- Stevens ML, Plotka ED. Functional lutein cyst in a postmenopausal woman. *Obstet Gynecol* 1977;50:27-9.
- Fujii S, Kiyokawa T, Tsukihara S, Senda T, Tahara T, Kaminou T, *et al.* Magnetic resonance imaging findings of ovarian stromal hyperthecosis. *Acta Radiol* 2009;50:954-7.
- Brown DL, Henrichsen TL, Clayton AC, Hudson SB, Coddington CC 3<sup>rd</sup>, Vella A. Ovarian stromal hyperthecosis: Sonographic features and histological associations. *J Ultrasound Med* 2009;28:587-93.
- Young RH, Clement PB. Miscellaneous primary tumors, secondary tumors and non-neoplastic lesions of the ovary. In: Sterberg SG, Mills SE, Carter D, Editors. *Sternberg's Diagnostic Surgical Pathology*. 5<sup>th</sup> ed., Philadelphia: Lippincott Williams and Wilkins; 2009. p. 2367.
- Yin PH, Sommers SC. Some pathologic correlations of ovarian stromal hyperplasia. *J Clin Endocrinol Metab* 1961;21:472-7.
- Young RH, Scully RE. Sex cord – stromal, steroid cell and other ovarian tumours with endocrine, paraendocrine and paraneoplastic manifestations. In: Kurman RJ, editor. *Blaustein's pathology of the female genital tract*. 5<sup>th</sup> ed. New York, NY: Springer-Verlag; 2002. p. 905-66.
- Zaino RJ, Unger ER, Whitney C. Synchronous carcinoma of the uterine corpus and ovary. *Gynecol Oncol* 1984;19:329-35.
- Suzuki M, Sekiguchi I, Tamada T. Estrogen production by epithelial ovarian tumours and dermoid cyst. *Nihon Sanka Fujinka Gakkai Zasshi* 1986;38:303-10.
- Tokunaga H, Akahira J, Suzuki T, Moriya T, Sasano H, Ito K, *et al.* Ovarian epithelial carcinoma with estrogen – producing stroma. *Pathol Int* 2007;57:285-90.
- Sherman ME, Lacey JV, Buys SS, Reding DJ, Berg CD, William C, *et al.* Ovarian volume: Determinants and associations with cancer among postmenopausal women. *Cancer Epidemiol Biomarkers Prev* 2006;15:1550-4.
- Telemann S, Mihailovici MS. Morphological correlations between lesions. *Rev Med Chir Soc Med Nat Iasi* 2003;107:379-82.
- Rodin DA, Fisher AM, Clayton RN. Cycle abnormalities in infertile women with regular menstrual cycles: Effects of clomiphene citrate treatment. *Fertil Steril* 1994;62:42-7.

**How to cite this article:** Rao S, Rao S, Lall S, Narasimhan R. Evaluation of ovarian lesions inducing endometrial hyperplasia or carcinoma in a tertiary care hospital in Southern India. *J Basic Clin Reprod Sci* 2013;2:123-6.

**Source of Support:** Nil, **Conflict of Interest:** None declared