

Case Report

Puerperal Superior Sagittal Sinus Thrombosis and Pulmonary Embolism: A Case Report and Review of Literature

Owolabi Lukman Femi, H Mohammed¹, BM Musa², DA Ibrahim³, BA Gwaram⁴, AI Dutse⁴

Departments of Medicine, Neurology Unit, ¹Dermatology Unit, ²Pulmonology Unit, ³Rheumatology Unit, ⁴Hematology Unit, Aminu Kano Teaching Hospital, Bayero University, Kano, Nigeria

ABSTRACT

Superior sagittal sinus thrombosis is a rare and often misdiagnosed disorder. Its occurrence with pulmonary embolism (PE) is much rarer, more so when it occurs in the setting of puerperium. Although cerebral sagittal sinus thrombosis can occur at any time during life, women are particularly vulnerable before delivery and during the puerperal period due to the hypercoagulable state of pregnancy. We report a case which describes the challenging clinical course of a young woman who developed superior sagittal sinus thrombosis and PE during puerperium.

KEY WORDS: Embolism, puerperium, pulmonary, sagittal sinus, thrombosis

INTRODUCTION

Superior sagittal sinus thrombosis is a relatively rare and often misdiagnosed condition. Its occurrence simultaneously with pulmonary embolism (PE) is much rarer. In general, the incidence of cerebral venous thrombosis, of which superior sagittal sinus thrombosis is a type, is estimated to be around 0.22/100,000/year in adults,^[1] and 11.6/100,000/year in obstetric patients.^[2] Western studies have shown relative rarity of puerperal cerebral venous thrombosis; Carroll *et al.*^[3] and Cross *et al.*^[4] independently reported the incidence of cerebral venous thrombosis to be 1 in 2500 deliveries.

Because superior sagittal sinus thrombosis often presents with diverse set of symptoms that makes diagnosing it a huge task, it commonly poses diagnostic challenges such that it can be easily missed or mistaken for more common neurological conditions. Thus, a high level of suspicion is required for its diagnosis and management.

Although recognized for more than 100 years,^[5] it has only in recent years come to be diagnosed frequently ante-mortem. This is partly due to greater awareness among physicians

and neurologists and partly due to improved non-invasive imaging techniques.^[6]

The mechanism by which cerebral venous thrombosis manifests can be broadly classified into two. First, there could be thrombosis of cerebral veins or dural sinus leading to cerebral parenchymal lesions or dysfunction. Second, there may be occlusion of the dural sinus and consequently reduced cerebral spinal fluid absorption and elevated intracranial pressure.^[7]

Although sagittal sinus thrombosis like cerebral venous thrombosis can occur at any time during life, women are particularly vulnerable before delivery and during the postpartum period because of the hypercoagulable state that accompanies pregnancy. PE from a dural sinus thrombosis is uncommon but when it coexists with sinus thrombosis it often carries a poor prognosis.^[6]

Postpartum or puerperal sagittal sinus thrombosis associated with PE is a rare clinical entity. We present a case of a woman who developed superior sagittal sinus thrombosis associated with PE during puerperal period.

CASE REPORT

This was a case report of a 25-year-old Nigerian woman who presented to the emergency unit with the major

Access this article online

Quick Response Code	Website: www.jbcrs.org
	DOI: ***

Address for correspondence

Dr. Owolabi Lukman Femi,
Department of Medicine, Neurology Unit, Aminu Kano Teaching Hospital,
Bayero University, PMB 3452, Kano, Nigeria.
E-mail: drlukmanowolabi@yahoo.com

complaint of severe headache, right sided weakness, double vision, impaired vision and progressive deterioration of her consciousness level that occurred 3 days after a normal spontaneous vaginal delivery of her first baby. She had an uneventful period of pregnancy; she had spontaneous delivery at 40 weeks of gestational age. She was neither hypertensive nor diabetic. She had no signs of infection, deep vein thrombosis (DVT) or eclampsia during pregnancy. She had no pregnancy in the past or history of contraceptive use. There was no significant past medical history.

On admission, she had no edema of the extremities, her temperature was 36.8°C and body mass index was 20 kg/m², she was drowsy and had mild right hemiparesis (power grade 4). She had cranial nerve sixth and seventh palsy, her pupils were 2-3 mm, she had prompt pupillary reflex bilaterally and bilateral papilledema. No abnormality was detected on other systemic examinations. All hematologic, rheumatologic and cardiologic work-ups including electrolytes, blood count, coagulation test and renal function test were within the normal limits.

The initial diagnosis was left hemispheric stroke? Cause and she was managed accordingly (mannitol, clopidogrel and physiotherapy). After 3 days on admission, she became breathless; there were no features suggestive of aspiration or DVT, no associated cough, orthopnea or paroxysmal nocturnal dyspnea. She also developed an episode of generalized tonic clonic seizure while on admission. Chest examination showed tachypnea (respiratory rate of 36/min) however her breath sound was vesicular and there was no added sound. Oxygen saturation level was 80% at room air, Doppler ultrasound for DVT in the lower limbs was normal bilaterally and the D-dimer was elevated (3.2 µg/mL).

Pulmonary thromboembolism was suspected. The diagnosis was also upheld by the chest physician and clinical hematologist.

Brain computerized tomography (CT) was inconclusive, T1-weighted and T2-weighted magnetic resonance imaging (MRI)

showed a hyperintense signal from the thrombosed sagittal sinus [Figure 1]. The patient was further managed with 100% oxygen, carbamazepine, intravenous heparin and warfarin, keeping international normalized Ratio between 2.5 and 3.5. She is currently in a stable clinical state.

DISCUSSION

Diagnosis of cerebral sinus vein thrombosis, including superior sagittal sinus thrombosis, has always been

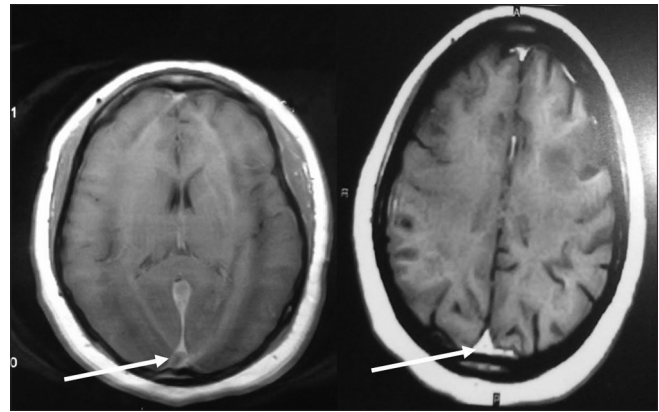


Figure 1: T1-weighted magnetic resonance imaging showing a hyperintense signal from the thrombosed sagittal sinus

difficult. Many times, diagnosis of the superior sagittal sinus thrombosis was observed only at autopsy, thereby raising the suspicion that it is very often a lethal neurological disorder.^[8] The first case of puerperal sagittal sinus thrombosis was described by Abercrombie in 1828^[9] and in 1829, Tonnelle^[10] published a review on the subject. The epidemiology of superior sagittal sinus thrombosis disease has evolved considerably during recent decades with the current predilection involving primarily young and middle-aged people.^[11]

Presentation of sagittal sinus thrombosis may be acute, which occur within 48 h, sub-acute, which occur between 2 days and 1 month and chronic which occur after more than 30 days.

Acute presentation is known to be commoner in puerperal cases than in non-puerperal patients^[12] which possibly explains acute occurrence of the symptoms in our patient. Nonetheless, gradual increase in symptoms and a fluctuating course is commonly seen in cerebral venous thrombosis from other causes.^[11]

The index patient presented few days after delivery. Puerperal or postpartum period is reported as a risk factor for superior sagittal sinus thrombosis and other cerebral venous thrombosis.

Potential risk factors for peripartum cerebral venous thrombosis and stroke were evaluated in a study conducted on United State National Hospital Discharge Survey data between 1979 and 1991. The study also identified an increased risk of peripartum cerebral venous thrombosis in younger women and in women during puerperal period particularly those that had a cesarean delivery.^[2,13] Needless to state that, generally, pregnant women are 4-5 times more likely to develop venous thromboembolism than women who are not pregnant.^[14] The predisposition to

develop venous thromboembolism occurs as a result of the hypercoagulable state of pregnancy that has likely evolved to protect women from hemorrhage during miscarriage and childbirth.^[15]

Apart from puerperium, the other risk factors for superior sagittal sinus include pregnancy, oral contraceptive use, cancer, hypercoagulable state, myoma uteri, vasculitis, inflammatory bowel disease, head trauma, intracranial or systemic infections, dehydration, substance abuse and Behcet's disease.^[16,17]

The mode of initial presentation in the index case agrees with what obtains in the previously reported cases in the literature. The most common presenting symptom is headache (80-90%) that could be isolated in up to 5% of cases.^[17,18] In the International Study on Cerebral Vein and Dural Sinus Thrombosis, focal or generalized seizures and paresis were seen in up to 40% of patients, a figure that is far higher than in cohort of patients with arterial stroke. Papilledema was also present in around 30% while visual loss was seen in 13%. Mental status change and aphasia were reported in around 20% of patients and approximately 10% presented with coma.^[17-19] Our patient had all the aforementioned symptoms, however, the initial diagnosis of arterial stroke was made because the symptom complex with which the patient presented with is more commonly seen in patients with arterial stroke, emphasizing the fact that a high index of suspicion is required to make the right diagnosis of superior sagittal sinus thrombosis.

Our patient also had features suggestive of PE. Given that she did not have any of the well-established risk factors for a PE such as long bone fractures, DVT, hypercoagulability and prolonged immobilization, hence, the possibility that her PE could have resulted from superior sagittal sinus thrombosis.

The association of sagittal sinus thrombosis and PE may be related to a detached thrombus from the cranial venous sinus and subsequent embolization to the lung through the venous system. The combination, though very rare, appears to have been forgotten and was alluded to by Diaz *et al.*, as "a syndrome rediscovered in their report."^[20] Because neurological symptoms appeared earlier than those of the respiratory symptoms, we think that the sagittal sinus thrombosis might have formed before the pulmonary thrombus.

Earlier studies showed that it is possible for venous thrombus to break off and embolise to the lungs resulting in PE.^[16,21] This situation is said to occur in about 10% of cases but carries a poor prognosis.^[20] In a review of the literature covering between 1942 and 1990, 11.3% of cases of venous sinus thrombosis were associated with pulmonary emboli

and mortality was higher in those with associated embolism than in those without embolism.^[20] Therefore, even in patients with no evidence of systemic thrombosis, but who have sagittal sinus thrombosis, the possibility of dislodging pulmonary emboli should be strongly considered.^[14]

As seen in our patient, the confirmation of a diagnosis of sagittal sinus thrombosis is based on demonstration of the thrombus by neuroimaging. Contrast axial CT images may show the "typical" empty delta sign, however, this is seen only in 20% of cases.^[22] Like in the index case, MRI is usually the investigation of choice for demonstrating sagittal sinus thrombosis, as it may exclude significant alternative diagnoses and will also demonstrate cerebral venous infarction complicating cerebral venous occlusion.^[6] Nonetheless, difficulties in diagnosis arise due to unusual normal anatomical variants and in situations where there is near-occlusion of the sagittal sinus.^[23]

The patient was treated with intravenous heparin and warfarin. Heparin and warfarin administration is the standard treatment for superior sagittal sinus thrombosis. This therapy, which is generally continued until the patient stabilizes does not aim at lysing the sinus thrombus, rather, it prevents new thrombus formation.^[24,25] However, intracranial hemorrhage is a significant potential consequence of this therapy; thus, the benefits of anticoagulation must be carefully balanced against the risks of hemorrhage. Up to date, there has not been strong evidence in support of an alternative treatment modality; endovascular thrombolysis, over anticoagulation therapy for the management of central venous sinus thrombosis.^[26]

Although the clinical presentation is highly variable, the diagnosis of superior sagittal thrombosis sinus as well as other central venous sinus thrombosis should be given consideration in a young and middle-aged woman in puerperal period with recent unusual headache or focal neurological deficit in the absence of the usual vascular risk factors.

CONCLUSION

The case presented demonstrated that sagittal sinus thrombosis may present during puerperium to the obstetrician and physician in a number of ways. High index of suspicion is required for its diagnosis which can be confirmed using MRI technique in most cases and even though it occurs rarely, PE should be watched out for in such patients. It also highlighted the consideration of sagittal sinus thrombosis in a patient who may present with clinical signs and symptoms of stroke during the puerperium especially in resource poor settings where neuroimaging may be a challenge.

REFERENCES

1. Ferro JM, Correia M, Pontes C, Baptista MV, Pita F. Cerebral Venous Thrombosis Portuguese Collaborative Study Group (Venoport). Cerebral vein and dural sinus thrombosis in Portugal: 1980-1998. *Cerebrovasc Dis* 2001;11:177-82.
2. Lanska DJ, Kryscio RJ. Risk factors for peripartum and postpartum stroke and intracranial venous thrombosis. *Stroke* 2000;31:1274-82.
3. Carroll JD, Leak D, Lee HA. Cerebral thrombophlebitis in pregnancy and the puerperium. *Q J Med* 1966;35:347-68.
4. Cross JN, Castro PO, Jennett WB. Cerebral strokes associated with pregnancy and the puerperium. *Br Med J* 1968;3:214-8.
5. Bousser MG. Cerebral venous thrombosis: Nothing, heparin, or local thrombolysis? *Stroke* 1999;30:481-3.
6. Kimber J. Cerebral venous sinus thrombosis. *QJM* 2002;95:137-42.
7. Sudharani B, Stephanie S, Jennifer AN, Alejandro RC. Cerebral venous thrombosis secondary to severe iron deficiency anemia: A case study. *Cancer Clin Oncol* 2012;1:91-8.
8. Nakase H, Takeshima T, Sakaki T, Heimann A, Kempinski O. Superior sagittal sinus thrombosis: A clinical and experimental study. *Skull Base Surg* 1998;8:169-74.
9. Abercrombie J. *Pathological and Practical Researches on Diseases of the Brain and Spinal Cord*. Edinburgh: Waugh and Innes; 1828. p. 83-5.
10. Tonnelle ML. Review of venous sinus disease. *J Hebd Med* 1829;5:337-40.
11. Debasis B, Kausik D. Cerebral venous sinus thrombosis. *Med Update* 2012;22:592-7.
12. Cantú C, Barinagarrementeria F. Cerebral venous thrombosis associated with pregnancy and puerperium. Review of 67 cases. *Stroke* 1993;24:1880-4.
13. Lanska DJ, Kryscio RJ. Peripartum stroke and intracranial venous thrombosis in the National Hospital Discharge Survey. *Obstet Gynecol* 1997;89:413-8.
14. Heit JA, Kobbervig CE, James AH, Petterson TM, Bailey KR, Melton LJ 3rd. Trends in the incidence of venous thromboembolism during pregnancy or postpartum: A 30-year population-based study. *Ann Intern Med* 2005;143:697-706.
15. James AH, Jamison MG, Brancazio LR, Myers ER. Venous thromboembolism during pregnancy and the postpartum period: Incidence, risk factors, and mortality. *Am J Obstet Gynecol* 2006;194:1311-5.
16. Stam J. Cerebral venous and sinus thrombosis: Incidence and causes. *Adv Neurol* 2003;92:225-32.
17. Ferro JM, Canhão P, Stam J, Bousser MG, Barinagarrementeria F, ISCVT Investigators. Prognosis of cerebral vein and dural sinus thrombosis: Results of the International Study on Cerebral Vein and Dural Sinus Thrombosis (ISCVT). *Stroke* 2004;35:664-70.
18. Cumurciuc R, Crassard I, Sarov M, Valade D, Bousser MG. Headache as the only neurological sign of cerebral venous thrombosis: A series of 17 cases. *J Neurol Neurosurg Psychiatry* 2005;76:1084-7.
19. Stam J. Thrombosis of the cerebral veins and sinuses. *N Engl J Med* 2005;352:1791-8.
20. Diaz JM, Schiffman JS, Urban ES, Maccario M. Superior sagittal sinus thrombosis and pulmonary embolism: A syndrome rediscovered. *Acta Neurol Scand* 1992;86:390-6.
21. Ferro JM. Causes, predictors of death, and antithrombotic treatment in cerebral venous thrombosis. *Clin Adv Hematol Oncol* 2006;4:732-3.
22. Ameri A, Bousser MG. Cerebral venous thrombosis. *Neurol Clin* 1992;10:87-111.
23. Provenzale JM, Joseph GJ, Barboriak DP. Dural sinus thrombosis: Findings on CT and MR imaging and diagnostic pitfalls. *AJR Am J Roentgenol* 1998;170:777-83.
24. Bousser MG, Russell RR. *Cerebral Venous Thrombosis*. London: Saunders; 1997.
25. Chow K, Gobin YP, Saver J, Kidwell C, Dong P, Viñuela F. Endovascular treatment of dural sinus thrombosis with rheolytic thrombectomy and intra-arterial thrombolysis. *Stroke* 2000;31:1420-5.
26. Canhão P, Falcão F, Ferro JM. Thrombolytics for cerebral sinus thrombosis: A systematic review. *Cerebrovasc Dis* 2003;15:159-66.

How to cite this article:****

Source of Support: Nil, **Conflict of Interest:** None declared