

Neurodegenerative Potential of the Aqueous Leaf Extract of *Ocimum gratissimum*: A Histological and Biochemical Study

Ajibola, Musa Iyiola^a, Ibrahim, Ridwan Babatunde^a, Imam, Aminu^b Masud, Mustapha Akajewole^b, Safiriyu, Abass^c, Etibor, Akhigbe Temitope^a

^a Department of Human Anatomy, Kampala International University, Western Campus, Ishaka-Bushenyi, Uganda.

^b Department of Anatomy, University of Ilorin, Ilorin, Nigeria.

^c Department of Human Physiology, Kampala International University, Western Campus, Ishaka-Bushenyi, Uganda.

*Corresponding Author Address: Ajibola, Musa Iyiola Department of Anatomy, Kampala International University, Western Campus, Ishaka-Bushenyi, Uganda. E-mail: musaiyiola@gmail.com Tel No: +256750631617.

ABSTRACT

Ocimum gratissimum is an herbaceous perennial shrub which is widely distributed in many regions. It is consumed in food as seasoning locally in Nigeria. In the present study, the effect of the acute administration of the aqueous leaf extract of *Ocimum gratissimum* (AeOG) on prefrontal cortical neurons was checked to assess its neurotoxicity potential. Thirty adult male Wistar rats weighing between 190-210 g were divided into 5 groups (n=6). Group A (control) received 1 ml of normal saline (p.o), groups B-E received 100, 200, 300 and 400 mg/kg AeOG (p.o) respectively. Treatment lasted for fourteen days. Twenty-four hours after treatment, animals were sacrificed and their brains were removed. The prefrontal cortices neuronal morphology was studied using haematoxylin and eosin (H&E) stain; while activities of acid phosphatase (ACP) and alkaline phosphatase (ALP) were assayed in the cerebral homogenate. AeOG administration at doses 300 and 400 mg/kg cause neuronal fragmentation and central chromatolysis with significant ($P<0.05$) increases in the activities of cerebral ACP and ALP. Our findings show that the acute use of AeOG caused neuronal fragmentation and central chromatolysis which are response to axonal injuries and may leads to onset of neurodegenerative diseases and affect cognitive and executive functions of the prefrontal cortex.

Key words: *Ocimum gratissimum*, Acid Phosphatase (ACP), Alkaline Phosphatase (ALP), Neurodegenerative diseases, Rat.

INTRODUCTION

Herbs have been shown to have useful significant medicinal effects, both in their natural state, and as a source of pharmaceuticals (Memory, 2001). The use of plants in low and middle income countries has never stopped gaining popularity. In these countries, it is often the main therapeutic system majority of people resort to (WHO, 2007, Kamboj, 2000). Increasing use as oppose to enough scientific evidence on the safety of medicinal plants have raised concerns regarding the safety and detrimental effects of these remedies (Saad et al, 2006).

Ocimum gratissimum Linn (Lamiaceae) is a shrub widely distributed in many regions. In Nigeria, it is referred to as "efirin", "Nchonwu" and "Daidoya" respectively by the

Yoruba, Igbo and Hausa tribes of Nigeria (Effraim et al., 2000). In Nigeria and most parts of West Africa, it is used as a spice and condiment in dishes, because of its high pungent flavour of clove. Traditionally, it is used locally for managing skin diseases, inflammation, insomnia, diarrhoea and liver disease (Iwu 1993, sofowora, 1995).

Phytochemical screening of the aqueous leaf extract of *O. gratissimum* (AeOG) had shown the plant to contain alkaloids, saponins, tannins, alkaloids, anthraquinone, flavonoids, steroids, terpenoids and cardiac glycosides (Holets et al., 2003; Akinyemi et al., 2005; Akinmoladun et al., 2007). In addition, leaves of *Ocimum gratissimum* reveal the presence

Received 28th April 2015. Edited 25th September 2015. Published online 27th September 2015. To cite: Ajibola MI, Ibrahim RB, Imam AM, Mustapha A, Safiriyu A, Etibor AT. Neurodegenerative Potential of the Aqueous Leaf Extract of *Ocimum gratissimum*: A Histological and Biochemical Study Anatomy Journal of Africa. 2015. Vol 4 (2): 563 – 570.

of essential oils such as eugenol, cineole, ocimol, tetratriacontane, gratimissin, gratimissic acid and β -caryophyllene (Sainsbury and Sofowora, 1971)). The hepatoprotective (Bhakta et al, 2001), antibacterial (Perumal et al, 1998), anti-diabetic (Esposito et al, 1991), anti-tumour (Gupta et al, 2000)), laxative (Akanmu et al, 2004) and antioxidant (Luximon-Ramma, 2002) activities of essential oils in *Ocimum gratissimum* have been reported.

MATERIALS AND METHODS

Preparation of extract of the aqueous leaf extract of Ocimum gratissimum

Fresh leaves of *Ocimum gratissimum* plant were purchased from a herb seller in Ilorin. Identification was done by Dr. K.S Olorunmaiye at the Herbarium of the Department of Plant Biology, University of Ilorin. The plant material was rinsed; air dried, blended and extracted using a Soxhlet extractor. The blended plant material (100 g) was placed in the Soxhlet chamber and extracted with 1250 cm³ of distilled water. The concentrated plant material was then evaporated in an oven at a regulated temperature of 40°C.

Animal care

Thirty adult male albino Wistar rats weighing between 190-210 g were used for this study. The animals were procured from the animal house of the department of Biochemistry, University of Ilorin. The rats were housed in wooden cages under light and dark cycle at room temperature with proper aeration and cross ventilation at the animal house of the department of Anatomy, University of Ilorin, Nigeria. Prior to the experiment, the rats were allowed to acclimatize for one week. The animals were fed with pelletized feed and water was given *ad libitum*. The ethical committee of the college of health sciences, University of Ilorin reviewed and approved the procedures and experiments. Throughout the experimental period, animals were handled and maintained in accordance with the guidelines of the Institutional Animal Care and Use Committee (IACUC).

Animal Grouping

The present study was carried out to assess the effect the acute administration of *Ocimum gratissimum* has on integrity of prefrontal cortical neurons and cerebral phosphatase profile of adult Wistar rats. The choice of prefrontal cortex was based on its involvement in cognitive and executive functions (Glenn et al, 2009, Miller et al, 2002). It is among those brain regions having the highest baseline metabolic activity at rest and involve in decision making and behaviour (Gusnard et al, 2001).

The rats were divided into five groups A, B, C, D and E consisting of six animals each.

Group A (Control group): Animal in this group received 1 ml of normal saline (p.o).

Group B: Animals in this group received AeOG (100 mg/kg; p.o).

Group C: Animals in this group received AeOG (200 mg/kg; p.o).

Group D: Animals in this group received AeOG (300 mg/kg; p.o).

Group E: Animals in this group received AeOG (400 mg/kg; p.o).

Administration lasted for 14 days.

Sacrifice

Twenty-four hours after the last administration, the animals were sacrificed by cervical dislocation. Their cerebrum were excised, the prefrontal cortex dissected, fixed in 10% formal calcium solution and processed for histological examination. For enzyme studies, the whole cerebrum was quickly weighed, homogenized in 0.25 M cold sucrose solution.

Histology of the prefrontal cortex

After fixation, tissues were dehydrated and embedded in paraffin wax. 8 μ m thick tissue sections were obtained using the Reichert-Jung 2050 rotary microtome; sections were stained in Haematoxylin and eosin for general neuronal outline. Images were examined under a light microscope and images captured using Olympus BH2 microscope.

Quantitative enzyme assay

After homogenization, tissue samples were centrifuged at 5000 rpm for five minutes. The

supernatant was stored at -80°C and used for the quantitative estimation of the activities of alkaline phosphatase (ALP) and acid phosphatase (ACP) spectrophotometrically using RANDOX's kit (Antrium, UK) within 48 h.

Statistical Analysis

Data were analysed by Microsoft Excel program for windows software. Results were expressed as mean \pm (S.E.M) and subjected to statistical analysis using the analysis of variance ANOVA and student's t-test. Statistical significance was set at $P < 0.05$.

RESULTS

Effects of AeOG on cerebral alkaline phosphatase (ALP) levels

The oral administration of AeOG increased the cerebral levels of alkaline phosphatase across the group. This increase was significant ($P < 0.05$) at doses 300 and 400 mg/kg when compared to the control group (Fig.1).

Effects of AeOG on cerebral acid phosphatase (ACP) levels

The oral administration of AeOG significantly ($P < 0.05$) increased the cerebral levels of acid phosphates in a dose dependent manner when compared to the control group (Fig. 2).

Histological observation

Histological analysis of the prefrontal cortical neurons of Wistar rats exposed to AeOG reveals different changes. The histology of the

control animals reveals intact neuronal arrangements with well-defined nucleus (Fig.3A). In the 100 mg/kg AeOG treated animals; the neuronal arrangements were intact and similar when compared to the control group (Fig. 3B). With increasing doses of AeOG, histological changes were seen within the neurons of the exposed animals. In the 200 mg/kg exposed groups, mild chromatolysis was noticed within prefrontal cortical neurons (Fig.3C) while in the 300 mg/kg exposed animals, neuronal swellings coupled with central chromatolysis were seen in the neurons (Fig.3D). In the 400 mg/kg exposed animals, dying neurons with distorted cytoarchitecture and central chromatolysis were seen (Fig.3E).

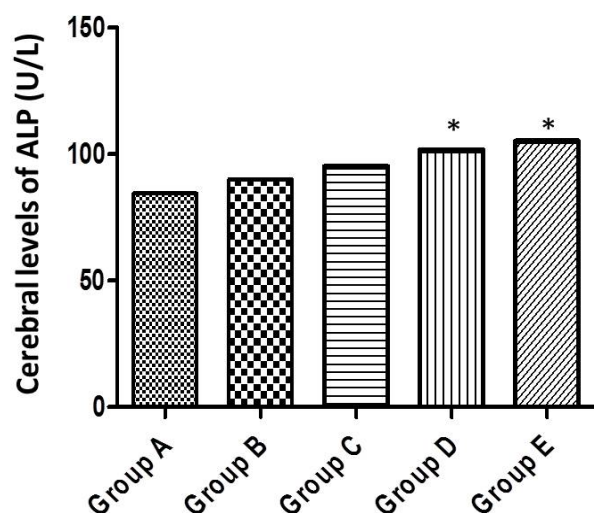


Figure 1: Shows effect of AeOG on the activity of cerebral alkaline phosphatase (ALP)

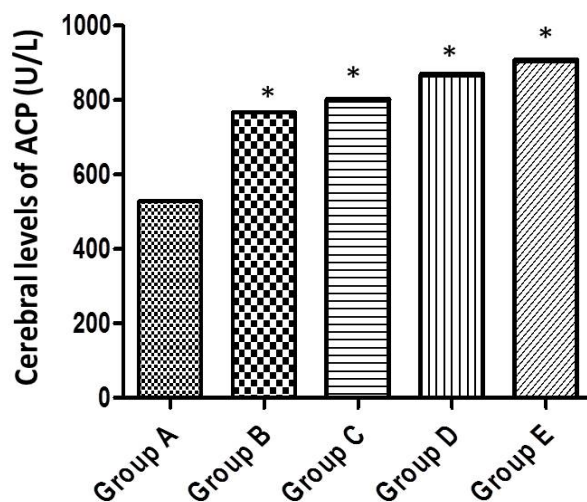


Figure 2: Shows effect of AeOG on the activity of cerebral acid phosphatase (ACP)

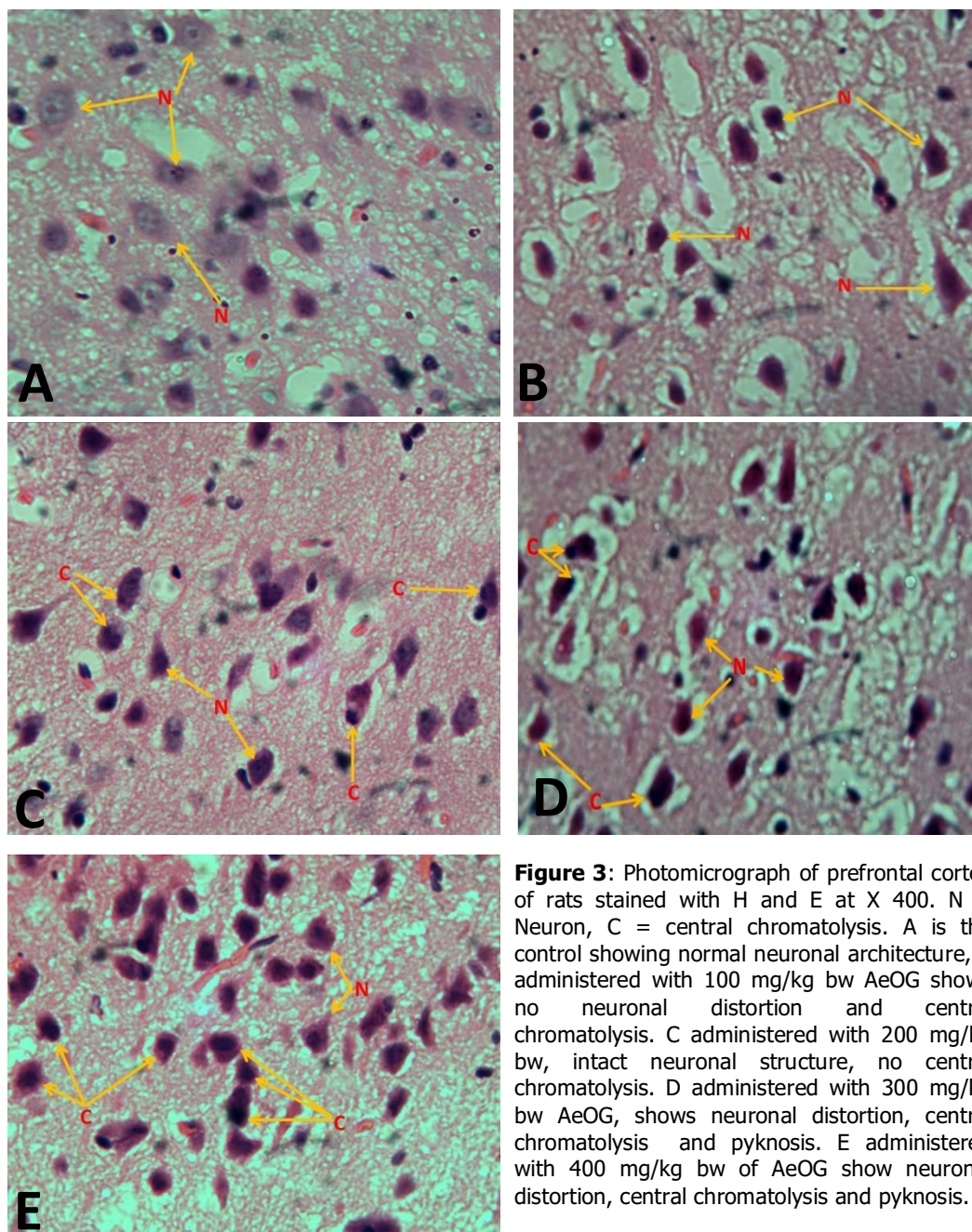


Figure 3: Photomicrograph of prefrontal cortex of rats stained with H and E at X 400. N = Neuron, C = central chromatolysis. A is the control showing normal neuronal architecture, B administered with 100 mg/kg bw AeOG shows no neuronal distortion and central chromatolysis. C administered with 200 mg/kg bw, intact neuronal structure, no central chromatolysis. D administered with 300 mg/kg bw AeOG, shows neuronal distortion, central chromatolysis and pyknosis. E administered with 400 mg/kg bw of AeOG show neuronal distortion, central chromatolysis and pyknosis.

DISCUSSION

Acid phosphatase is an enzyme of the lysosomal membrane (Zhang et al., 2009). ACP was chosen for assay on the basis of its specificity for lysosomal membrane. It gives a picture of the sequence of cell damage if any after exposure to insults resulting from chemical compounds (Chu and Lin, 1998).

The increase in ACP activity observed following administration of AeOG could be a consequence of *de novo* synthesis induction by accumulation of saponins, one of the

phytochemicals in the extract, in the brain. Saponins have been implicated to have complexation with cholesterol to form pores in cell membrane bilayers like in red cell membranes, where complexation leads to haemolysis on intravenous injection (Francis et al, 2002). Another possible explanation is the release of the enzymes from the brain lysosomal membrane, which is an indication of tissue damage.

The increase in the activities phosphatases (ALP and ACP) in the groups treated with AeOG as shown above is an indication of neurotoxic effect of the extract. These results were consistent with Obianime et al, (2011) who reported a significant increase in total acid phosphatase and prostatic acid phosphatase after administration of crude extract of *ocimum gratissimum*. For ACP, this may occur as a result of increase in the synthesis of the enzyme by Golgi-lysosomal system of the phagocytes into the digestive vacuoles in response to cell death or pores in the membrane that may be triggered by stress or hyperstimulatory activity of the extract (Al-Ali and Robinson, 1982).

Histological observations revealed normal neuronal outline with intact cellular architecture in control animals (fig 3). The central chromatolysis observed in the animals exposed to 300 and 400 mg/kg AeOG conformed to an increase activity of ACP (Fig 3D and E). This is characterised by widely spaced, distorted, enlarged neuronal cells and central chromatolysis which are indications of axonal injuries. This indicates the neurodegenerative potential of AeOG at high doses.

Recent studies have proven that AeOG has hepatoprotective, antioxidant (Rabelo *et al.*, 2003; Odukoya *et al.*, 2005; Leal *et al.*, 2006; Aprioku and Obianime, 2008) and antibacterial effects due to presence of antioxidants such as flavonoids and polyphenols in the extract (Effraim et al, 2000,

Abdulazeez et al, 2013)). It has also been reported to suppresses the hematopoietic system an attribute linked to its presence of saponin (Jimoh et al, 2009). From these reports, it may be concluded that AeOG has both antioxidant and oxidant properties, depending on the tissue/organ system under investigation or the duration of administration. From the phytochemical analysis of AeOG, it can be easily deduced that it has complex and large amounts of secondary metabolites which include oxidants (saponins, triterpenes and alkaloids) and antioxidants (eugenol, flavonoids, citral, linalool).

Results from the present study reveal that AeOG has neurodegenerative potential especially at high concentration. AeOG cause no significant neurodegenerative changes in Wistar rats at low doses (Fig 3B and C), while in high doses it was toxic to prefrontal cortical neurons (Fig 6 and 7). The reason was probably that AeOG has multiple actions, such as antioxidation (Nwanjo and Oze, 2006, Akinmoladunn et al, 2007) thus inducing apoptosis.

In conclusion results from our study reveal that the aqueous leaves extract of *ocimum gratissimum* has neurodegenerative potential initiated by membrane malformation and lysosomal activity. The neurodegeneration was found to be dose dependent. Though, *ocimum gratissimum* is a popular condiment/seasoning and herbal medicine in Africa, its chronic usage is not advisable for sound brain activity.

REFERENCES

1. Abarikwu SO, Iserhienrhien BO, Badejo TA. 2013. Rutin and selenium attenuated cadmium-induced testicular pathophysiology in rats. *Hum Exp Toxicol.*, 32: 395-406.
2. Abdulazeez MA, Ibrahim K, Bulus K, Babvoshia HB and Abdullahi Y. 2013. Effect of combined use of *Ocimum gratissimum* and *Vernonia amygdalina* extract on the activity of angiotensin converting enzyme, hypolipidemic and antioxidant parameters in streptozotocin-induced diabetic rats; *african journal of biochemistry*, 7(9), 165-173.
3. Akanmu MA, Iwalewa EO, Elujoba AA, Adelusola KA. 2004. Toxicity potentials of *Ocimum gratissimum* fruits as laxative with reference to Senna. *African J of Biomedical Research*, 7(1): 23-26.

4. Akinmoladun AC, Ibukun EO, Afor E, Obuotor EM, Farombi EO. 2007. Phytochemical constituent and antioxidant activity of extract from the leaves of *Ocimum gratissimum*. *Sci. Res. Essay*, 2(5):163-166.
5. Akinyemi KO, Oladapo CE, Okwara CC and Fasure KA. 2005. Screening of crude extracts of six medicinal plants used in South-West Nigerian unorthodox medicine for anti-methicillin resistant *Staphylococcus aureus* activity. *BMC Complement. Altern. Med*, 5: 6-10.
6. Aprioku JS, and Obianime AW. 2008. Antioxidant activity of the aqueous crude extract of *Ocimum gratissimum* Linn. leaf on basal and cadmium-induced serum levels of phosphatases in male guinea-pigs. *JASEM*, 12: 33-39.
7. Baker JR, Hew H, Fishman WH. 1998. The use of a chioral hydrate formaldehyde fixative solution in enzyme histochemistry. *J. Histochem. Cytochem*, 6: 244-250.
8. Becker NH, Goldfischer S, Shin W, Novikoff AB. 2000. The localization of enzyme activities in the rat brain. *J. Riophys. Biochem. Cytol.*, 8: (149-663, 19(10).
9. Bhakta T, Banerjee S, Subhash C. 2001. Hepatoprotective activity of *Ocimum gratissimum* leaf extract. *Phytomedicine*, 8 (3): 220-224.
10. Bhattacharya R, Tulsawani R. 2008. *In vitro* and *in vivo* evaluation of various carbonyl compounds against cyanide toxicity with particular reference to alpha-ketoglutaric acid. *Drug Chem Toxicol.*, 31(1): 149 - 61.
11. Chu TM and Lin MF. 1998. PSA and acid phosphatase in the diagnosis of prostate cancer. *J. Clin. Ligand Assay*, 21: 24-34.
12. Deepmala J, Deepak M, Srivastav S, Sangeeta S, Kumar SA, et al. 2013. Protective effect of combined therapy with dithiothreitol, zinc and selenium protects acute mercury induced oxidative injury in rats. *J Trace Elem Med Biol.*, 27: 249-256.
13. Di Filippo M, Tambasco N, Muzi G, Balucani C, Saggese E, Parnetti L, Calabresi P, Rossi A. 2008. Parkinsonism and cognitive impairment following chronic exposure to potassium cyanide. *Mov. Disord.* 23(3): 468-470.
14. El-Ghawabi G, De Flipe J. 2005. A correlative electron microscopic studies of basket cells. *Neuro. Sci.*, 17: 991-1009.
15. Ephraim KD, Salami HA and Osewa TS. 2000. Effect of Aqueous leaf Extract of *Ocimum gratissimum* on Heamatological and Biochemical Parameters in Rabbits. *African Journal of Biomedical Research* 3:175-179.
16. Esposito AM, Diaz A, deGracia I, de-Tello R, Gupta MP.1991. Evaluation of traditional medicine: effects of *Cajanus cajan* L and of *Ocimum gratissimum* L on carbohydrate metabolism in mice. *Rev Med Panama*, 16: 39-45.
17. Fishman WH, Baker JR. 1956. Cellular localization of l-glucuronosidase in rat tissues. *J. Histochem. Cytochem.*, 4: 570-587.
18. Francis G, Zohar K, Harinder PS, Makkar and Klaus B. 2002. "The biological action of saponins in animal systems: a review". *British Journal of Nutrition*, 88 (6): 587-605.
19. Glenn AL, Raine A, Schug RA. 2009. The Neural Correlates of Moral Decision-Making in Psychology. *Molecular Psychiatry* 14: 5-6
20. Gupta M, Mazumder UK, Rath N, Mukhopadhyay DK. 2000. Antitumour activity of methanolic extract of *Ocimum gratissimum* L. Stem against Ehrlich ascites carcinoma. *J Ethnopharmacol.* 72: 151-156.
21. Gusnard DA, Akbudak E, Shulman GL, Raichle ME. 2001. Medial Prefrontal Cortex and Self-referential Mental Activity: Relation to a Default Mode of Brain Function. *Nat Acad Sci. PNAS* 98 (7): 4259-4264
22. Holets FB, Ueda-Nakamura T, Dias BP, Cortez, DAG, Diaz JA and Nakamura CV. 2003. Effect of essential oil of *Ocimum gratissimum* on the trypanosomatid *Herpetomonas samuelpessoai*. *Acta Protozool.*, 42: 269-276.
23. Iwu MM. 1993. Hand book of African medicinal plants. CRC press, New York. Pp 214 – 215.
24. Kamboj VP. 2000. Herbal medicine, general articles. *Curr sci*: 78: 35 – 39

25. Leal PF, Chaves F, Celio M, Ming LC, Petenate AJ and Angela MMA. 2006. Global yields, chemical compositions and antioxidant activities of Clove basil (*Ocimum gratissimum* L.) extracts obtained by supercritical fluid extraction. *J. Food Process Eng.*, 29: 547-559.
26. Luximon-Ramma A, Bahorun T, Soobrattee MA and Aruoma OI. 2002. Antioxidant activities of phenolic, proanthocyanidins and flavonoid components in extracts of *Ocimum gratissimum*. *J Agric Food Chem.*, 50: 5042-5047.
27. Miller EK, Freedman DJ, Wallis JD. 2002. "The Prefrontal Cortex: Categories, Concepts and Cognition". *Philos. Trans. R. Soc. Lond B Biol Sci* 357(1424): 1123–36
28. Nwanjo HU and Oze GO. 2007. Hypolipidaemic and antioxidant properties of *Ocimum gratissimum* on diabetic rats. *Plant Prod. Res. J.* 11:1-4.
29. Obianime AW, Aprioku JS, and Esomonu C. 2011. The effect of aqueous ocimum gratissimum leaf extract on some biomedical and haematological parameters in male mice: *Asian j. of Biological Sciences*, 4(1): 44-52.
30. Odukoya OA, Ilori OO, Sofidiya MO, Aniunoh OA, Lawal BM and Tade IO. 2005. Antioxidant activity of Nigerian dietary spices. *Elect. J. Environ. Agric. Food Chem.*, 4: 1086-1093.
31. Olusegun RJ, Josiah O, Luqman AO, Ayokunle O and Sikiru AB. 2008. Effect of extract of ocimum gratissimum on the hemetological parameters, *Nigeria journal of cell Biology*: Pp 33-37.
32. Perumal SR, Ignacimuthu S, Sen A. 1998. Screening of 34 Indian medicinal plants for antibacterial properties. *J Ethnopharmacol.* 62:173-182.
33. Prabhakaran K, Li L, Zhang L, Borowitz JL, Isom GE. 2007. Upregulation of BNIP3 and translocation to mitochondria mediates cyanide-induced apoptosis in cortical cells. *Neuroscience*, 150(1): 159-167.
34. Rabelo M, Souza EP, Soares PMG, Miranda AV, Matos, FJA, and Criddle DN. 2003. Antinociceptive properties of the essential oil of *Ocimum gratissimum* L. (Labiatae) in mice. *Braz. J. Med. Biol. Res.*, 36:521-524.
35. Saad B, Azaizeh H, Abu-Hijleh G, Said S. 2006. Safety of traditional Arab herbal medicine. *Evidence based complementary and alternative medicine*, 3:433-439.
36. Sainsbury M and Sofowora EA. 1971. Essential oil from the leaves and inflorescence of *ocimum gratissimum*. *Photochemistry* 10:3309-3310.
37. Skene CD, Philip S. 2006. "Saponin-adsorbed particulate vaccines for clinical use". *Methods* 40 (1): 53–9.
38. Sofowora A. 1993: Medicinal Plants and traditional medicine. Spectrum books Ltd. Ibadan Nigeria. Pp 224 – 227.
39. Soler-Martín C, Riera J, Seoane A, Cutillas B, Ambrosio S, Boadas-Vaello P, Llorens J. 2009. The targets of acetone cyanohydrin neurotoxicity in the rat are not the ones expected in an animal model of konzo. *Neurotoxicol Teratol.* 32(2): 289-294.
40. Venn-Watson SK, Ridgway SH. 2007. Big brains and blood glucose: common ground for diabetes mellitus in humans and healthy dolphins. *Comp Med.*, 57(4): 390-395.
41. Watt JM and Breyer-Brandwisk MJ. 1962. The medicinal and poisonous plants of southern and Eastern Africa. 2nd edn. E. and S. Livingston, Edinburgh. Pp. 1425.
42. WHO. 2007. WHO Guidelines for assessing quality of herbal medicines with reference to contaminants and residues. *World Health Organization, Geneva*, 2007.
43. Wintola OA, Sunmonu TO, Afolayan AJ. 2011. Toxicological evaluation of aqueous extract of *Aloe ferox* Mill. in loperamide-induced constipated rats. *Hum. Exp. Toxicol.*, 30(5):425-31.
44. Zhang XH, Wang Q, Gerald W, Hudis CA, Norton L, Smid M, Foekens JA and Massague J. 2009. Latent bone metastasis in breast cancer tied to Src dependent survival signals. *Cancer Cell*, 16, 67–78.

