

## A STUDY ON THE INSERTION CHARACTERISTICS OF RECTUS MUSCLES AND ITS RELATION WITH THE AXIAL LENGTH OF EYE BALL IN CADAVERIC EYES FROM AN EASTERN INDIAN POPULATION

Somnath Mukhopadhyay<sup>1</sup>, Sajib Chakraborty<sup>2</sup>, Manjari Chatterjee<sup>3</sup>, Himadri Datta<sup>4</sup>

1. Department of Ophthalmology, Nil Ratan Sircar (NRS) Medical College and Hospital, Kolkata, West Bengal, India.
2. Department of Anatomy, College of Medicine and Sagore Dutta Hospital, Kolkata, West Bengal, India.
3. Department of Anatomy, Medical College, Kolkata, West Bengal, India.
4. Department of Eye bank and Cornea, Regional Institute of Ophthalmology (RIO), Kolkata, West Bengal, India.

\*Correspondence to: Dr Somnath Mukhopadhyay, 402A NSC Bose Road, Kolkata-700047, West Bengal, India Phone: 91-9434375472. Mail: [dr\\_somnath@hotmail.com](mailto:dr_somnath@hotmail.com)

### ABSTRACT

The primary aim was to record measurements of relevant anatomy of recti muscle insertions in relation to limbus and with each other, and also to find whether these measurements vary with the axial length of the eyeball in an eastern Indian perspective. Eye balls ( n= 64, 20 female and 44 male) from Institutional eye bank were examined, within eight hours of death of the donor, under operating microscope by a single observer between May 2009 to April 2010. The mean distance from limbus to each rectus muscle at midpoint and at each end of insertion was measured by Castroviejo caliper. Additional parameters studied were length of each rectus muscle insertion ('width'), distance between each rectus muscle insertion and measurement of axial length using 10 MHz ultrasonic A scan probe. Data collected was entered in Microsoft Office Excel 2007 and analysed by using statistical software SPSS 10. The frequency was calculated in percentages. Criteria for significance used in the study was at  $p < 0.05$ . The mean age of the donors was 71 years with a range of 26-86 years. Statistically significant difference ( $p < 0.05$ ) was found between male and female eyes regarding distance of limbus to midpoint point of only medial rectus muscle insertion. No statistically significant ( $p > 0.05$ ) difference was found between male and female eyes regarding length of line of rectus muscles insertion. No statistically significant correlation ( $p > 0.05$ ) was observed between the axial length and various measurements of rectus muscle insertion. Results of this study might help local strabismologists in reevaluation of the spiral of Tillaux based on regional (Eastern Indian) perspective.

**Key words:** Eye ball; Rectus muscles; Rectus muscle insertion; Axial length; Indian population.

### INTRODUCTION

Motility of eye ball is governed by six extra ocular muscles out of which the four recti are of paramount importance. Dynamic balance between the extra ocular muscles is needed for maintaining binocular single vision, the supreme function of human eye ball. Any deviation from this balance usually manifests in strabismus (Sevel, 1986). Surgical management of strabismus is gaining more popularity among the strabismologists in the last two decades. Detailed anatomy of extra ocular muscles especially their insertion patterns (the Spiral of Tillaux) are of extreme importance in strabismus surgeries (both strengthening and weakening procedures including reoperations, alphabet patterns of vertical deviations and transposition operations for paralytic squint). Strabismus surgeries are formulated based on readily available nomograms based on studies (many of them a century old) involving western population. This might not be suitable in our perspective. Data obtained from regional cohort of our study (covering eastern Indian population group) will freshly relook at the rectus muscle insertion characteristics and to help local strabismologists to modify the universal nomogram, thus might help them to plan squint surgeries better.

## MATERIALS AND METHODS

This was an institution based cross sectional descriptive type of study in which the anatomical parameters of the four recti muscles and axial length of enucleated eyeballs were recorded in aseptic conditions under operating microscope. The duration of the study was from May 2009 to April 2010. The study was conducted in the tissue bank, department of cornea of our institute. The study population consisted of 64 eyeballs of adults collected by the institutional eye bank. Institutional ethical committee permission was obtained before the start of the study.

Enucleated cadaveric eyes of adults (both sexes and both sides) without any obvious deformity or injury were selected for the study. Measurements were obtained within eight hours of death of the person. Side determination of the selected eyeballs followed by the identification of the site of all four recti muscles insertions on the sclera. Measurements of the

various anatomical parameters (the mean distance from limbus to midpoint and at each end of insertion of four recti muscles, length of each rectus muscle insertion [width], distance between each rectus muscle insertion and ultrasonic measurement of axial length of the eye ball) were recorded (figure nos 2-4). Tools utilized were Castroviejo's caliper, ultrasonic A-scan biometer (Appaswamy Associates, Chennai, India, fig no 5) and operating microscope (Carl-Zeiss, Germany). The identification number, age, sex, cause of death was noted from eye bank record book. Scheduled parameters as per stated objectives were collected by a single observer in the investigation proforma.

**Statistical Analysis:** Data collected was entered in Microsoft Office Excel 2007 and analysed by using statistical software SPSS 10. The frequency was calculated in percentages. Criteria for significance used in the study was at  $p < 0.05$ .

## RESULTS

The study included 20 female and 44 male enucleated eyeballs and the mean age of the samples was 71 years with a range of 26-86 years. Statistically significant difference ( $p < 0.05$ ) was found between male and female eyes regarding distance of limbus to midpoint point of only medial rectus muscles insertion (table no 1). Values for length of muscle insertion was greater for all rectus muscles in male except superior rectus (statistically not significant, Fig no 1). The mean distance from limbus to midpoint, superior, inferior, medial and lateral border of insertion had been depicted in table no 2.

The mean distance between medial rectus to inferior rectus was  $10.34 \pm 1.53$  mm (range 7-11 mm) and between inferior rectus to lateral rectus was  $10.73 \pm 2.11$  mm (range 7-19 mm). The mean distance between lateral rectus and superior rectus was  $10.39 \pm$

$1.34$  mm (range 9-16 mm) and between superior rectus and medial rectus was  $9.56 \pm 0.98$  mm (range 7-11 mm). The mean axial length of the sampled eye balls ( $n=64$ ) was  $22.35 \pm 1.73$  mm (range 20.25-24.88 mm). No statistically significant (Pearson's statistical significance, 2-tailed test) correlation was found between axial length and the insertional parameters of rectus muscles (limbus-insertional distance, width of insertion and interinsertional distance).

There was significant statistical correlation between distances of limbus to midpoint of medial rectus insertion with that of the distances of limbus to midpoint of superior rectus insertion. There was significant statistical correlation between distances of limbus to midpoint of inferior rectus insertion with that of the distances of limbus to midpoints of lateral rectus insertion and superior rectus insertion.

Significant statistical correlation exists between the widths of the four recti muscles (Pearson 2-tailed correlation, significant at 0.01 level).

The distance between medial rectus to inferior rectus was negatively correlated with distance between superior rectus to medial rectus. This correlation was

statistically significant (Pearson 2-tailed level of correlation at -0.406). It was also noticed that the distance between lateral rectus to superior rectus was significantly correlated with distance between medial rectus to inferior rectus and also to distance between inferior rectus to lateral rectus and there was positive correlation.

Table 1: Comparison between male and female cadaveric eyes regarding the distance from the limbus to mid-point of four-recti muscles insertion (n=64).

Distance between limbus to mid-point of rectus muscles insertion	Male Eyes (n=44) Mean $\pm$ SD	Female Eyes (n=20) Mean $\pm$ SD	Remark
Medial Rectus**	5.04 $\pm$ 0.79	5.5 $\pm$ 0.76	P=0.004
Inferior Rectus	6.23 $\pm$ 0.92	6.2 $\pm$ 0.73	P=0.554
Lateral Rectus	7.04 $\pm$ 0.82	6.85 $\pm$ 0.79	P=0.78
Superior Rectus	8.04 $\pm$ 1.19	7.9 $\pm$ 1.12	P=0.43

Table 2: Distance from limbus to rectus Muscle Insertions (n= 64)

Name of the muscle		Mean $\pm$ SD (mm)	Range (mm)
Medial Rectus Insertion	Limbus to midpoint of insertion	5.44 $\pm$ 0.75	4-7
	Limbus to superior border of insertion	5.78 $\pm$ 1.08	4-9
	Limbus to inferior border of insertion	5.99 $\pm$ 0.99	4-9
Inferior Rectus Insertion	Limbus to midpoint of insertion	6.44 $\pm$ 0.52	6-8
	Limbus to medial border of insertion	6.46 $\pm$ 0.84	5-8
	Limbus to lateral border of insertion	7.73 $\pm$ 0.9	6-10
Lateral Rectus Insertion	Limbus to midpoint of insertion	6.94 $\pm$ 0.67	6-9
	Limbus to superior border of insertion	7.4 $\pm$ 1.09	4-9
	Posterior limbus to inferior border of insertion	7.51 $\pm$ 1.17	6-11
Superior Rectus Insertion	Limbus to midpoint of insertion	7.72 $\pm$ 1.2	6-11
	Limbus to medial border of insertion	7.08 $\pm$ 1.45	5-11
	Limbus to lateral border of insertion	8.97 $\pm$ 1.16	7-11

Table no 3: Comparison of distance from the limbus to the midpoint of rectus muscles insertion among various studies

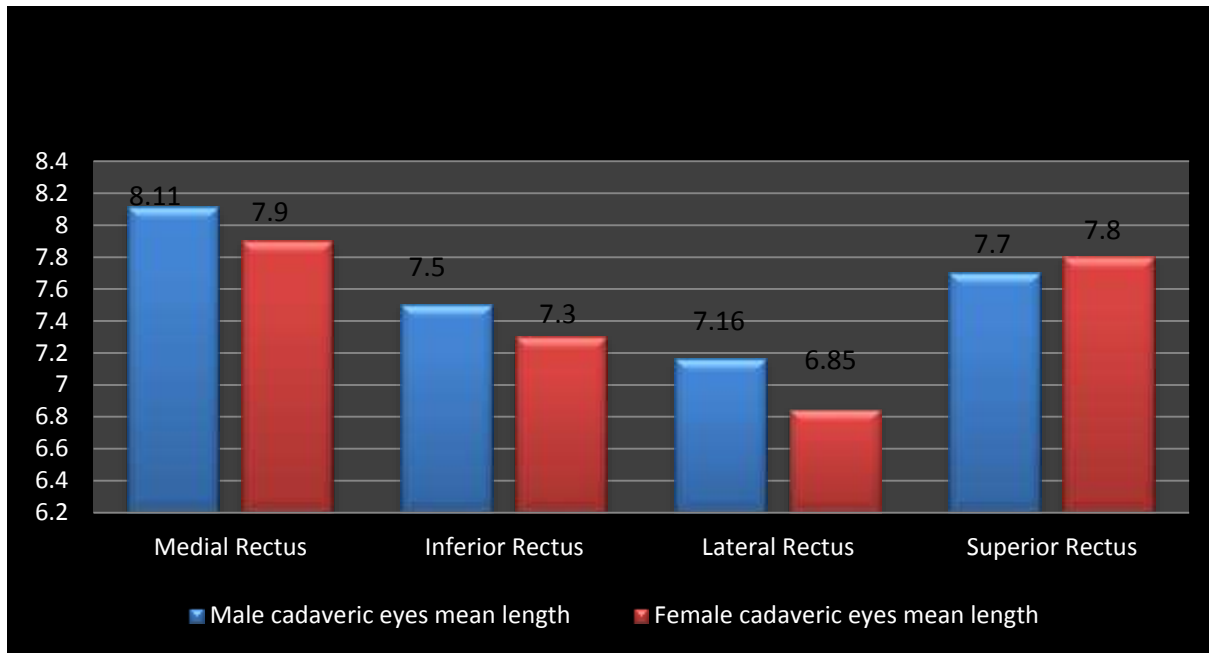
	Fuchs (1884)	Weiss (1897)	Howe (1902)	Gat (1902)	Apt (1980)	Present study
Number of eyes	31	5	21	80	100	64
Medial rectus, mm	5.5	5.05	5.7	5.4	5.3	5.44
Inferior rectus, mm	6.5	6.85	6.7	6.4	6.8	6.44
Lateral rectus, mm	6.9	6.75	7.4	6.6	6.9	6.94
superior rectus, mm	7.7	8.01	7.6	7.1	7.9	7.72

Table no 4: Comparison of length of line (width) of rectus muscle insertions among various studies

	Fuchs(1884)	Weiss(1897)	Fink(1962)	Apt(1980)	Present study
Number of eyes	31	5	100	100	64
Medial rectus, mm	10.3	10.76	--	11.3	8.03
Inferior rectus , mm	9.8	10.35	9.8	10.5	7.45
Lateral rectus, mm	9.2	9.67	--	10.1	6.59
Superior rectus, mm	10.6	10.75	10.2	11.5	8.27

Table no 5: Comparison of distances between rectus muscle insertions among various studies

	Duke-Elder(1961)	Reynard et al.(1965)	Apt(1980)	Present study
Medial rectus to Inferior rectus, mm	5.5	--	5.9	10.34
Inferior rectus to Lateral rectus, mm	7	9	8	10.73
Lateral rectus to Superior rectus, mm	6.5	8	7.1	10.39
Superior rectus to Medial rectus	7	8	7.5	9.56



**Figure 1: Eyeball muscle length in both gender**

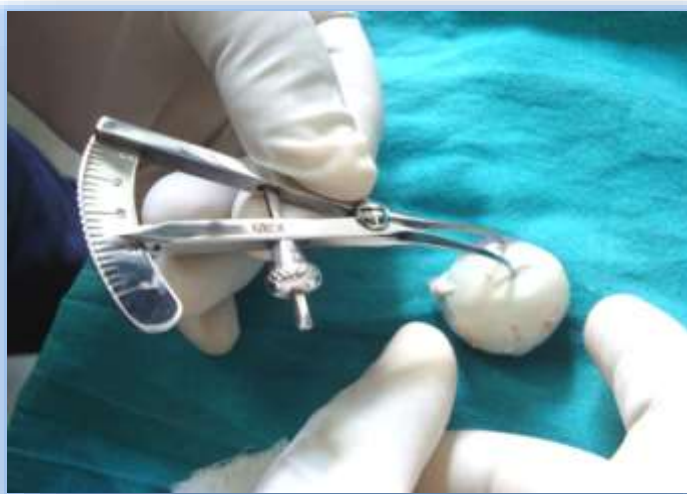

Figure no 2: Measurement of distance between limbus to midpoint of rectus muscle insertion

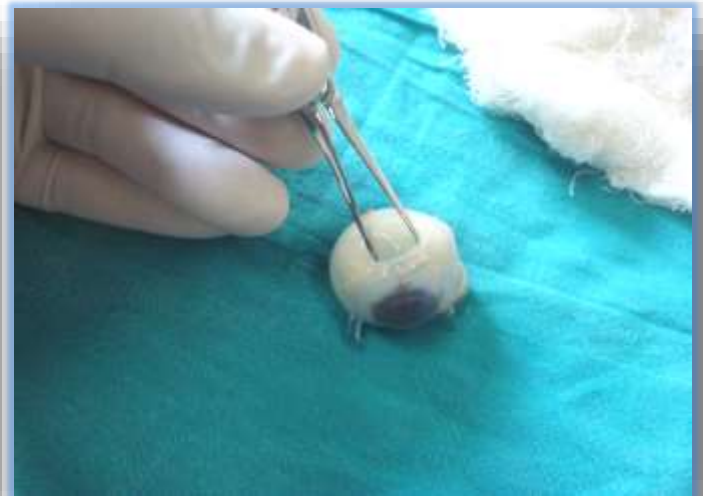

Figure no 3: Measurement of length of line ("width") of rectus muscle insertion.

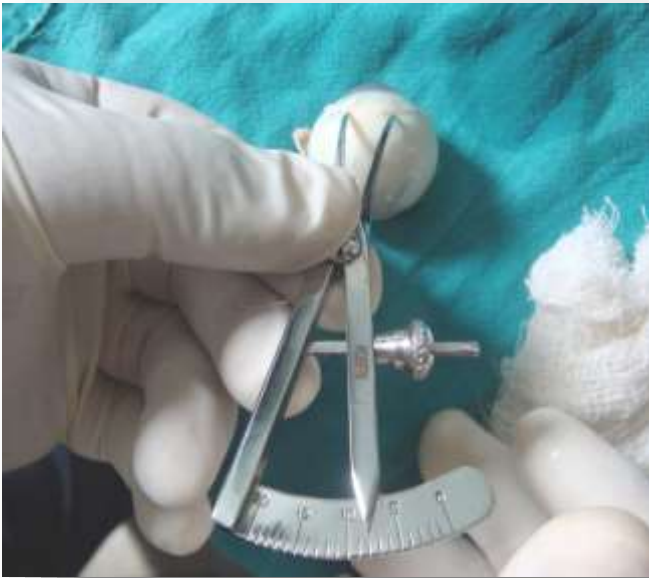

Figure no 4: Measurement of distance between rectus muscles insertions

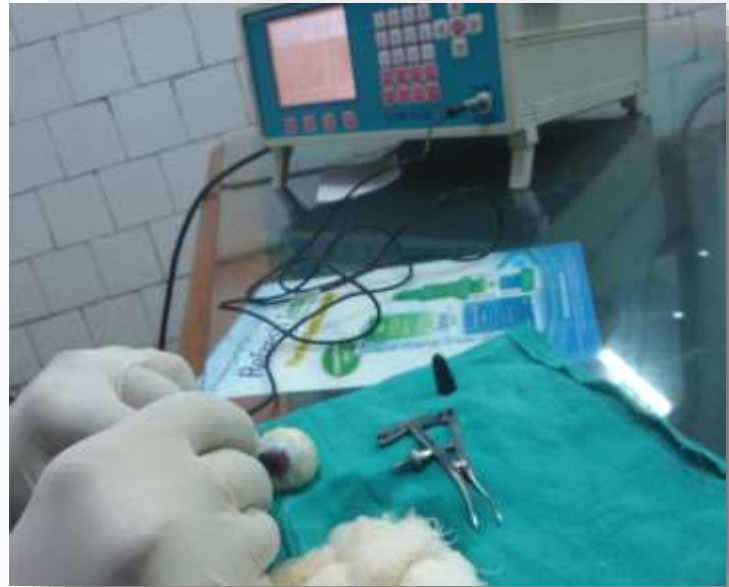

Figure no 5: Axial Length measurement by Ultrasonic A Scan

## DISCUSSION

Measurements of distances from the limbus to insertion of horizontal rectus muscles in living persons were recorded in two studies. However both these studies involved strabismus patients rather than normal subjects (Goldstein, 1969; Helveston et al., 1978). Anatomical evaluation of extra ocular muscles, macula and optic nerve in enucleated eyes of living subjects and to compare the results with a previous autopsy study was carried out by Kim et al. (2008) The study concluded that most of the measurements were different from those of autopsy studies, and so to consider the effects of preservation and fixation solution on autopsy eyes, race, and the differences among measurements techniques.

Apt (1980) quoted a study by Sappey in 1855 reported that the globes and corneal diameters were larger in males than in females. However in Apt's study itself, no such difference was noticed. In the present study statistically significant

difference in the measurements of rectus muscles insertions were not found except in the distance of limbus to insertion of medial rectus which was more in case of females. Since the sample size of females was less than 30 this difference might not be applied to general population.

Fuchs (1884) measured 31 autopsy and surgically enucleated eyes that were emmetropic by axial length measurement (antero-posterior diameter 23-25 mm). Other autopsy studies were done subsequently by Weiss (1897) and Howe (1902). However it was Apt (1980) who first pointed out that the limbus as well as site of muscle insertion has finite thickness. Distance from the limbus to the midpoint of rectus muscles insertion present in different studies was compared with the present study in table no 3. It is evident that the measurements obtained in the present study did not differ much from those obtained by others and were

much close to the values obtained by Fuchs (1884).

The lines of insertion were generally not straight, but more or less curved. Some previous investigators had measured the length of line of rectus muscle insertions. Results of these studies were compared in the table no 4. Measurements in Apt's study (1980) were larger than those of the previous three studies. It might be due to dissecting microscope used by Apt in his study. Under high magnification (7 xs) one can see the insertion line extending slightly farther along the sclera than when little or no magnification was used. It could be easily seen that the values of the width of rectus muscle insertion in the present study was significantly lower than that of Apt's study. This might be because the present study was carried out on Indian subjects whose physique differs from western population and accordingly the muscle dimensions might differ. The discrepancy could also be attributed to the differences in methodology.

The values of inter-insertional distances obtained by Apt (1980) were higher than those given by Duke- Elder et al (1961), but lower than those presented by Renard and co-workers (1965). In the present study, however, the distances between the rectus muscles were significantly higher (table no 5).

The value of the axial length of the eyeball, measured by ultrasonic A scan,

obtained in the study was 22.35mm with a range of 20.25mm - 24.88mm which was not much different from the normal values (John,1984) . An ultrasonic measurement of extra ocular muscles' thickness and axial length in normal Indian population was carried out by Arora et al.(1990) There was no significant correlation between the thickness of four rectus muscles and the age, sex, weight and stature in healthy persons. In our study as well, no correlation was found between the axial length of the eyeball and insertional characteristics of rectus muscles.

Major limitation of our study is small sample size. Mean age (71 years, range 26-86 years) of sampled eyeballs points towards older age group participating in our study. Parameters measured in-situ before enucleation on greater number of eyeballs from younger cohort could have been better. However, we believe that our small study might help in reevaluation of spiral of Tilluax based on regional data. This may cause betterment of results of strabismus surgeries.

**Acknowledgement:** Staff and administration of the Department of Eye bank and Cornea, Regional Institute of Ophthalmology (RIO), 88 College Street, Kolkata-700073, West Bengal, India.

**Conflict of interest and financial disclosure:** None

## REFERENCES

1. Sevel P.1986.The origins and insertions of the extraocular muscles: Development, histologic features, and clinical significance. *Trans Am Ophthalmol Soc* 84:488.
2. Goldstein JH.1969. Strabismus and insertion of horizontal rectus muscles. *Am J Ophthalmol* 68(4):695-698.
3. Helveston EM, Ellis FD, Patterson JH, Weber J.1978. Augmented recession of the medial recti. *Ophthalmology* 85(5):507-511.
4. Kim JL, Lee SG, Yang JW.2008. Anatomical Evaluation of Extraocular Muscles and Relationships Among Macula and Optic Nerve in Enucleated Eye. *J Korean Ophthalmol Soc* 49(7):1159-1164.

5. Apt L.1980.An anatomical revaluation of rectus muscle insertions. Trans Am Ophthalmol Soc 78:365–375.
6. Fuchs E.1884.Beiträge zur normalen Anatomie des Augapfels. Albrecht von Graefes Arch Klin Exp Ophthalmol 30:1–21.
7. Weiss L.1987. Über das Wachstum des Menschlichen Auges und über die Veränderung der Muskelinsertionen am wachsenden Auge. Anatomische Hefte 8:193–248.
8. Howe L.1902. On the primary insertions of the ocular muscles. Trans Am Ophthalmol Soc 9:668–678.
9. Gat L.1947. Ein Beitrag zur Topographie des Ansatzes der vier geraden Augenmuskeln.Ophthalmologica 114:43-51.
10. Fink WH .1962.Surgery of the Vertical Muscles of the Eye, Ed 2. Springfield, Illinois, CC Thomas, pp 90, 128.
11. Elder Duke S, Wybar K.1961.System of Ophthalmology.St. Louis: CV Mosby Co; vol 2, pp. 81-90.
12. Renard G, Lemasson C, Saraux H.1965.Anatomie de L'oeil et de ses annexes. Paris, Masson, p 62.
13. John Shammas H.1984. Atlas of Ophthalmic ultrasonography and biometry: CV Mosby Co., 132-3.
14. Arora R, Verma L, Kumar A.1990. Ultrasonic measurements of extra ocular muscles thickness in normal Indian population. Indian J ophthalmol 38(4):164-165.