



ASN-PH-020919
ISSN: 2315-537X

International Journal of Herbs and Pharmacological Research

IJHPR, 2012, 1(2):55 - 61

www.antrescentpub.com

RESEARCH PAPER

SUB ACUTE AND CHRONIC EFFECTS OF CARICA PAPAYA ON THE KIDNEY OF RATS

¹Dikibo E., ¹Onokhua V., ²Oyadonghan G.P., ³Okpe A.C., ⁴Okoro C.J. ¹Anyanwu R.A.,

¹Department of Medical Laboratory Science, Ambrose Alli University, Ekpoma, Edo State, Nigeria. ²Department of Anatomy, Abia State University, Uturu, Abia State. ³Department of Pharmacology, University of Nigeria, Enugu campus, Enugu State, Nigeria. ⁴Department of Medical Microbiology, University of Nigeria Teaching Hospital, Ituku Ozalla, Enugu, Enugu State.

Corresponding author: dikibolix@yahoo.com

Received: 2nd May, 2012

Accepted: 17th July, 2012

Published: 31st July, 2012

ABSTRACT

This study investigates the sub-acute and chronic effects of *Carica papaya* on the kidney of growing Sprague Dawley rats. A total 40 growing rats (95.0 ± 10.0 grams) within the ages of 7 ± 1 weeks were involved in the study. They were divided into eight groups of 5 rats each: A (control; n = 5), B (n = 10), C (n = 10) and D (n = 10). Group A1 and A2 served as the acute and chronic control respectively. Group B1, C1 and D1 served as the subacute test while group B2, C2 and D2 served as the chronic test. The rats received varied doses of powdered *Carica papaya* seed (6, 8, 10grams). Group A1, B1, C1 and D1 were fed for 3 weeks while Group A2, B2, C2 and D2 were fed for 6 weeks. At the end of each stage, animals were sacrificed and the kidneys were harvested for histological study. The results showed histological distortions in the liver parenchymal architecture in a dose and duration dependent manner. Our findings suggest therefore, that *Carica papaya* seeds have nephrotoxic potentials and as such, the need for further studies cannot be overemphasized.

Key words: *Carica papaya* seed, Herb, Sub-acute, Chronic, Nephrotoxic.

INTRODUCTION

Traditional medicines and complementary and alternative medicines (CAM) are attracting more and more attention within the context of health care provision and health sector reforms. WHO is promoting its inclusion in health policies because of its positive features, which include diversity and flexibility; accessibility and affordability in many parts of the world; broad acceptance among many populations in developing countries; comparatively low cost and growing economic importance (Kumar, 2006).

Of interest is *carica papaya* locally known as *Ibepe*, *Gwanda* and *Okwere* in Yoruba, Hausa and Igbo languages respectively. Various pharmacological actions and medicinal uses of different parts of papaya are well reported in the ancient literature (Kirtikar and Basu, 1998). They include; anti-fertility (Lohiya *et al.*, 1994), the extracts have exhibited inhibitory effects on gram-positive bacteria and gram-negative bacteria. These organisms include: *Bacillus subtilis*, *Escherichia coli*, *Salmonella typhi*, *Staphylococcus aureus*, *Enterobacter cloacae* and *Proteus vulgaris* (Emeruwa, 1982). The petroleum ether extract of the rind of raw *papaya* fruit exhibits significant antimalarial activity (Bhat and Namita, 2001). The purified chemopapain from commercially available dried latex of the fruits has shown immunological properties (Buttle and Barret, 1984). *Papaya* fruits are used as topical ulcer dressings (Hewitt *et al.*, 2002).

This study will therefore establish the subacute and chronic effects of pawpaw (*Carica papaya*) seeds on the histology of the kidney.

MATERIALS AND METHODS

Experimental animals: Forty (40) Sprague Dawley rats of 7 ± 1 week old and weights ranging from 95.0 to 105.0g and comparable sizes were procured from the animal house of the College of Medicine, Ambrose Alli University, Ekpoma, Nigeria. They were moved to the site of the experiment at No. 23 St. Mary Street, Ekpoma where they allowed 2 weeks of acclimatization.

Substance of study: Unripe *Carica papaya* was collected from the premises of the animal house, College of Medicine, Ambrose Alli University, Ekpoma and authenticated by a botanist in the Department of Botany, Faculty of Natural Sciences, Ambrose Alli University, Ekpoma.

Substance preparation: The outer peel of *Carica papaya* was removed and the seeds obtained and sun dried. The dried seeds were then crushed into fine powder using electric blender. The fine powder was measured using Electric Balance (Denver Company, USA, 200398. IREV.CXP-3000) and packaged in small plastic envelopes and then stored pending usage.

For the purpose of this study, pellets were prepared by adding measured quantity of *Carica papaya* powder to feed (grower mesh) to add up to 50grams as described by Nwaopara *et al.* (2011).

Animal grouping: The experiment involved two stages; stage one (1) which lasted a period of 3 weeks (acute test) and stage (2) which lasted a period of 6 weeks (chronic test). The animals were assigned into eight groups of 4 rats each: Group A1 and A2 served as the acute and chronic control respectively. Group B1, C1 and D1 served as the acute test while group B2, C2 and D2 served as the chronic test.

Experimental design: The animals were weighed on the first day of the acclimatization period and fed 50grams of feed with water giving *ad libitum*. They were housed in well ventilated labelled wooden cages at the site of the experiment. The cages were designed to secure the animals properly especially from wild animals/insects and cleaned daily.

Substance administration: The preliminary studies, animal acclimatization, ingredients procurement (*Carica papaya* preparation and production), actual animal experiment and evaluation of results, lasted from October, 2011 to February, 2012. However, the actual administration of *Carica Papaya* to the test animals lasted for 6 weeks (acute: 3 weeks; chronic: 6 weeks).

Stage 1 administration: Group A1 (control group) received 50.0g of feed and distilled water alone. Test Groups B1 to D1 received as follows; 44.0g feed, distilled water plus 6g of CP; 42.0g feed, distilled water plus 8g of CP; 40.0g feed, distilled water plus 10g of CP respectively.

Stage 2 administrations: All the groups in stage two received as stated for stage 1; the difference is that the feeding period lasted for six weeks unlike stage 1 which lasted for 3 weeks.

Sample collection: The Kidney of each rats were obtained at the end of each stage under chloroform anesthesia and fixed in 10% formalin for histological processing.

Processing schedule: The tissues were processed using automatic tissue processor according to the processing schedule used in Obafemi Awolowo University Teaching Hospital Complex (OAUTHC), Ile-ife, Osun State, Nigeria. The fixed plastic cassette tissues in 10% formalin were automatically processed by passing them through different grades of alcohol as follows: 70% alcohol (2hrs), 80% alcohol (2hrs), 90% alcohol (2hrs), 90% alcohol (2hrs), 95% alcohol (2hrs), Absolute (2hrs), Xylene 1 (2hrs), Xylene II (2hrs), Molten paraffin wax 1 (2hrs) and Molten paraffin Wax II (2hrs).

After the last timing, the tissues were removed from their plastic cassettes and placed at the centre of the metallic tissue mould and then filled with molten paraffin wax. They were also left to solidify after which they were now placed in the refrigerator at 5°C for 15 minutes. After the blocks were cool in the refrigerator for the time stated

above (15 minutes), the blocks were then removed from the metallic case using a knife and after which the paraffin wax at the side of the blocks were removed.

The blocks were then trimmed and cut serially at 3nm on a rotary microtome. The sections were floated in water bath at 55°C and picked up by the use of a clean frosted end slides. The frosted end slides were now placed on the hot plate for 40 minutes for adequate attachment of the sections on the slides after which the sections were dewaxed, hydrated, air dried and stored in a slide box ready for staining process.

Staining procedure: Sections for general tissue structure were stained by Haematoxylin and Eosin technique. The sections were dewaxed in 3 changes of xylene (5 minutes), the sections were hydrated through descending grades of alcohol (absolute, 95%, 80% and 70%), the sections were stained in Harris haematoxylin (5 minutes), the sections were rinsed in running tap-water to remove excess stain, The sections were differentiated in 1% acid alcohol (3 seconds), the sections were blued in running tap water (10 minutes), the sections were counterstained with 1% eosin (1 minute), sections were finally rinsed in water, dehydrated in ascending grades of alcohol (70%, 80, 95% and absolute), and the sections were cleared in xylene, air-dried and mounted with dibutylphthalate propylene xylene (DPX). The slides were examined under a light microscope and photomicrographs were taken.

RESULTS

Following the histological observation of this study, kidney tissue damages expressed in several forms were presented with ingestion of graded doses of *Carica papaya* seeds for three weeks (acute) as well as for six weeks (chronic).

Specifically, mild to severe glomerular degeneration, tubular wall disruptions, vacuolation, glomerular shrinkage, tubular congestion, exudation, parenchymal erosion, pykrosis, inflammatory cell infiltration, infarction with palour, and edema were presented.

In addition, these renal damages were observed to be dependent on dose and duration of the ingested *Carica papaya*.

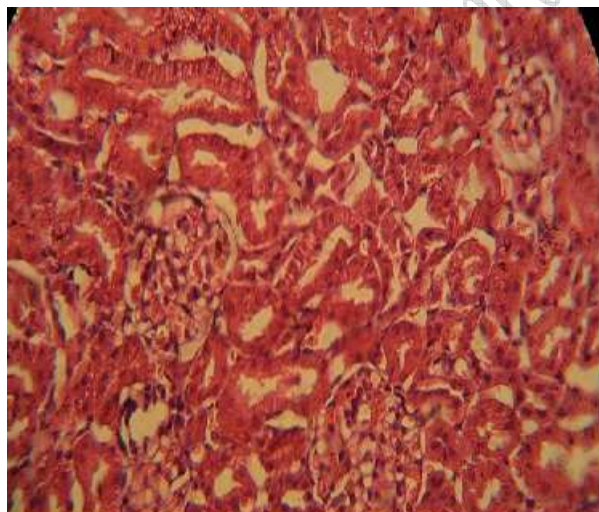


Figure 4.1. Control group A (A sectional representation of normal rat kidney at X 4 magnification showing normal glomerulus and nephrons)

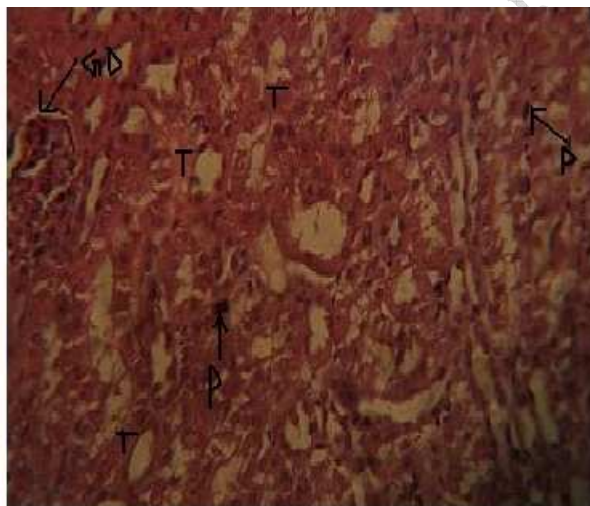


Figure 4.2 . Test group B1: A representative section of rat kidney fed 6 grams/kg/day for 3 weeks (Showing tubular wall disruptions (T), mild glomerular degeneration with vacuolation (GD) and pykrosis (P))

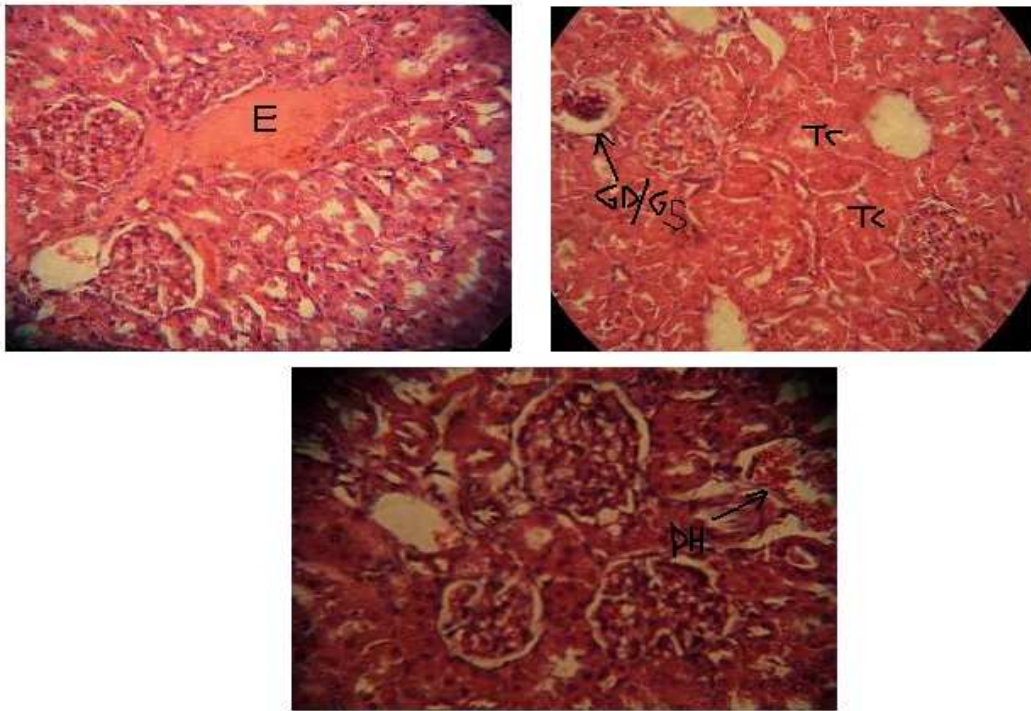


Figure 4.3. Test group B2: A representative section of rat kidney fed 6 grams/kg/day for 6 weeks (Showing Exudations (E), severe glomerular degeneration and glomerular shrinkage (GD/GS), tubular congestion (TC), parenchymal haemorrhage (PH))

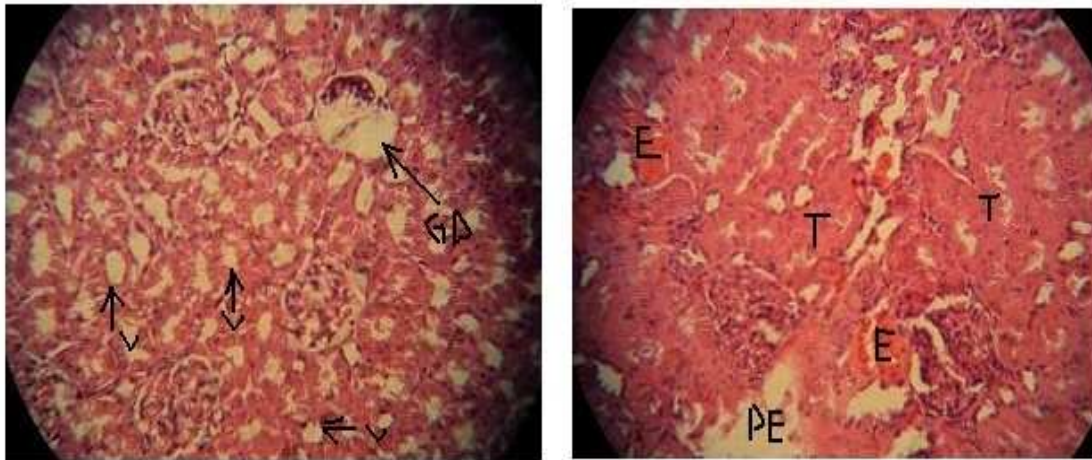


Figure 4.4. Test group C1: A representative section of rat kidney fed 8 grams/kg/day for 3 weeks (Showing glomerular degeneration (GD), severe vacuolation (V), tubular congestion (T), exudation (E) and parenchymal erosion (PE))

DISCUSSION

Irrespective of the variations, it is clear that ingestion of *Carica papaya* seeds have the potential to induce renal damages. Hence, the findings of this study does not support it herbal usage in the management of poison related renal diseases as early reported (Olagunju *et al.*, 2009). In addition, this study's findings are not in line with the report by Thomas and Ajani (1987), who reported that daily intake of 15 ml of aqueous extract of unripe *C. papaya* at 5 ml three times daily for seven days, in seven-year old sickle cell children, had no adverse effect on the functions of the liver and kidney. Similarly, the results of this study are not in line with the study of Oduola *et al.*, (2007) who reported that its extract is not nephrotoxic.

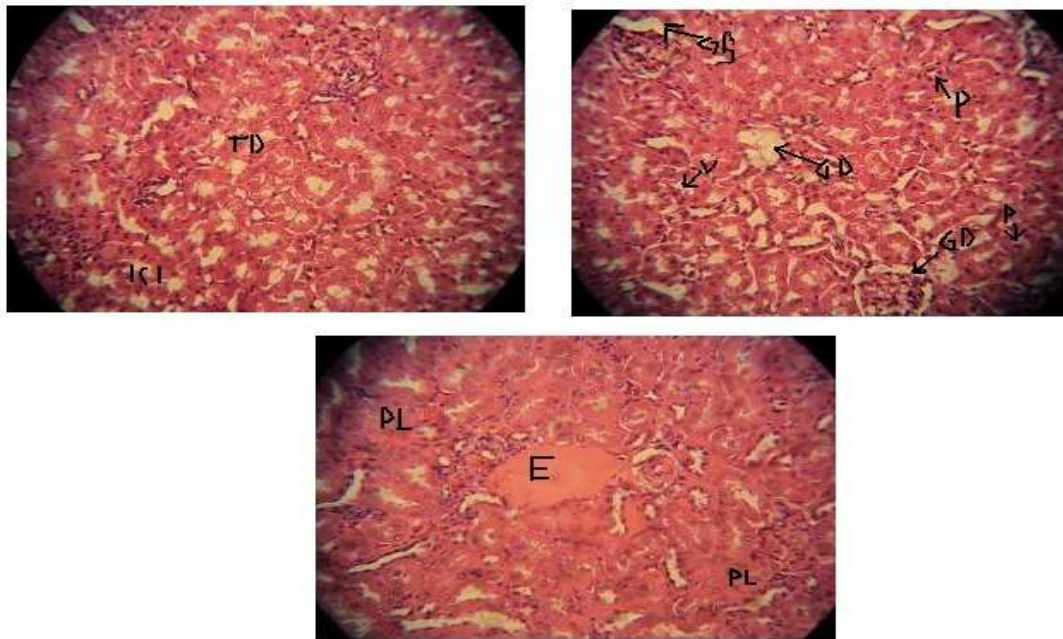


Figure 4.5. Test group C2: A representative section of rat kidney fed 8 grams/kg/day for 6 weeks (Showing severe tubular wall disruptions (TD), inflammatory cell infiltration (ICI), glomerular degeneration with vacuolation (GD) and shrinkage (GS), pykrosis (P), exudation (E) with palour(PL)

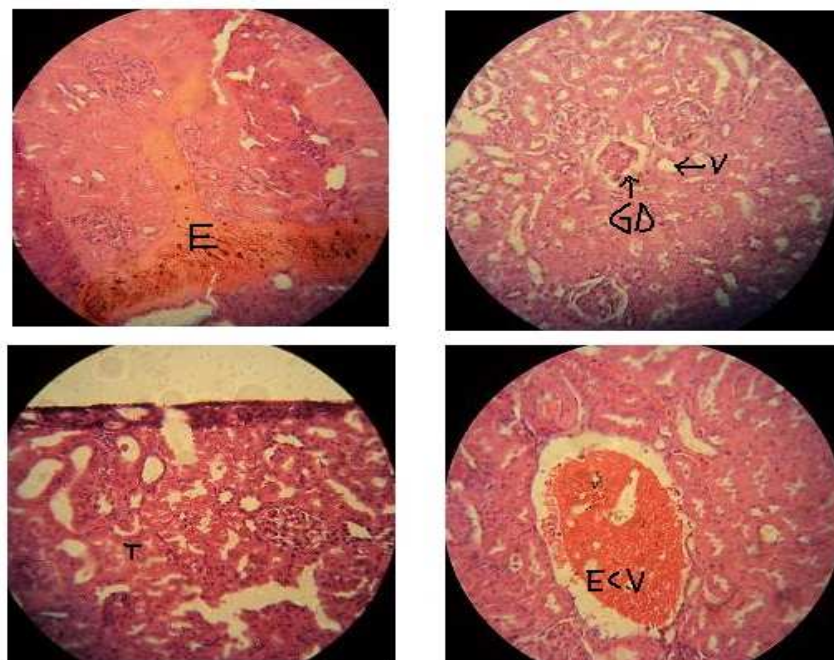


Figure 4.6. Test group D1: A representative section of rat kidney fed 10 grams/kg/day for 3 weeks (Showing exudation (E), severe tubular degeneration, shrinkage and disruption with vacuolation (GD and V), tubular dilation and parenchymal erosion (T), and enlarged congested vessel (ECV)

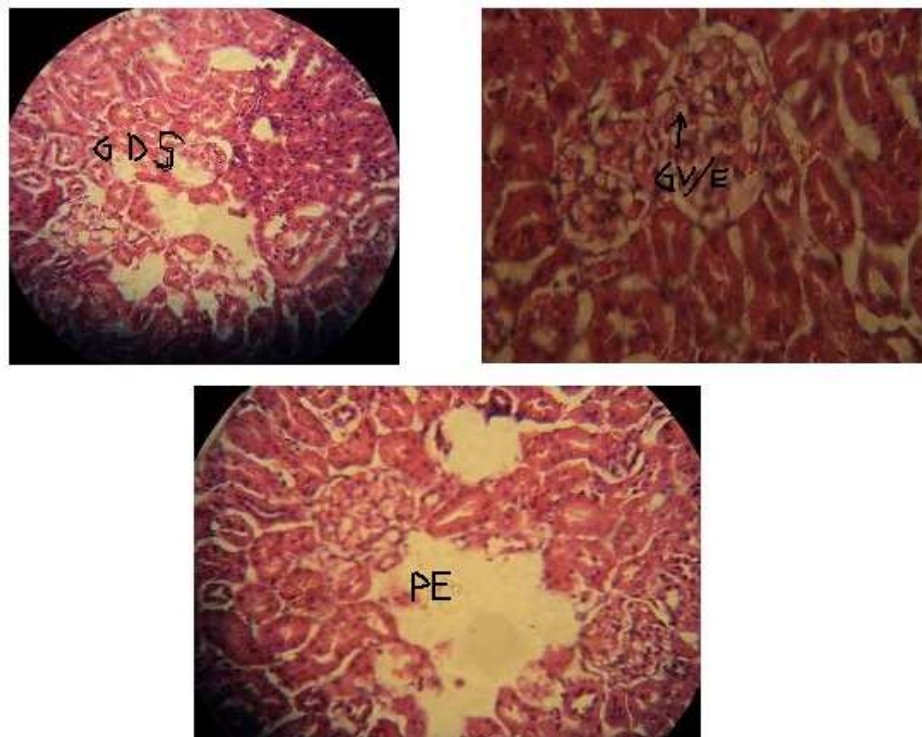


Figure 4.7. Test group D2: A representative section of rat kidney fed 10 grams/kg/day for 6 weeks (Showing severe glomerular degeneration and shrinkage (GDS), glomerular vacuolation/ edema (GV/E) and severe parenchymal erosion (PE))

On the contrary, the present results agree with the finding of Ayotunde and Ofem (2008) who reported shrinkages of cell and complete degeneration of cell and tissue in fish treated with *Carica papaya*. He also observed that the tissue damage became severe with increasing concentration of *C. papaya* and duration of exposure. Similarly, Udoh and Udoh, (2005) has reported *Carica papaya* seeds induced elevation of serum acid phosphatase, alkaline phosphatase and aspartate amino transferase (Udoh and Udoh, 2005) which are agents of oxidative stress. By implication, the reported nephrotoxic potentials of *C. papaya* as shown in this study are in agreement with Udoh and Udoh (2005). Moreover, crude extracts from the seeds of *C. papaya* has been shown to induce variable responses depending on the dose, duration, and route of administration in laboratory animals (Kamal *et al.*, 2003; Verma and Chinoy, 2006). Hence the fruit is widely classified as harmful in pregnancy, for fear of its teratogenic and abortifacient effects (Adebivi *et al.*, 2002).

Conclusively, based on our previous findings on weight; that *Carica papaya* may increase feed intake and feed conversion ratio, but this does not translate into enhanced growth rate and weight gain (Bankole *et al.*, 2012). This study demonstrated that unripe seed of *Carica papaya* may be a good weight management diet; however, it may also induced growth retardation for growing state. Furthermore, the nephrotoxic activities observed in this study by ingestion of *Carica papaya* suggest its renal damage potentials.

ACKNOWLEDGEMENT

We acknowledge the assistance provided by the research staff at the Animal Farm/Research Laboratory of Anthonio Research Center, Ekpoma-Nigeria, and those of the Department of Morbid Anatomy/Forensic Medicine, Obafemi Awolowo University, Ife-Nigeria, towards the success of this study.

REFERENCES

Adebivi, A., Adaikan, P.G. and Prasad, R.N. (2002): *Papaya (carica papaya)* consumption is unsafe in pregnancy, fact or fable? Scientific evaluation of a common belief in some parts of Asia using a rat model. *Br J Nuti*; 88(2), 199-203.

Ayotunde, E.O. and Ofem, B.O. (2008): Acute and Chronic Toxicity of Pawpaw (*Carica papaya*) Seed Powder to adult Nile Tilapia (*Oreochromis niloticus* linne 1757); *Afri. J. Biotech*; 7 (13): 2265 – 2274.

Bankole JK., Dikibo E., Onokhua V., Eidangbe AP., Aremu AO., Uhumwangho EJ (2012). Weight changes and growth performance in Sprague Dawley rats fed diet containing graded doses of *Carica papaya* seeds. *IJHPR*; 1(1):24-29

Bhat, P.G. and Namita, N. (2001): in vitro Antimalarial activity of extracts of three plants used in the traditional medicine of India. *Am. J. Trop. Med. Hyg*; 65(4): 304 - 308.

Buttle, D.J. and Barret, A.J. (1984): Chymopapains chromatographic purification and immunological characterization. *Biochem. J*; 223 (1): 81-88.

Emeruwa, A.C. (1982): Antibacterial substance from *Carica papaya* fruit extract. *J. Nat. Prod*; 45(2): 123-127.

Hewitt, H., Whittle, S., Lopez, S., Bailey, E. and Weaver, S. (2002): Topical use of papaya in chronic skin ulcer therapy in Jamaica. *West Indian Med. J*; 49(1): 32-33.

Kirtikar, R. and Basu, B.D. (1998): Indian Medicinal plants. 2nd Edn. International book distributors. Dehra Dun. Vol. II. Pp. 1097-1099.

Kamal R., Gupta RS. and Lohiya NK. (2003). Plants for male fertility regulation. *Phytother Res*; 17: 579 – 590.

Kumar, J.K. (2006): Fuzzy logic and modern analytical tool coupling in comprehensive evaluation of traditional and complementary medicine. *Pharmacognosy Magazine*; 2 (8):202 – 203.

Lohiya, N.K., Goyal, R.B., Jayaprakash, D., Ansari, A.S. and Sharma, S. (1994): Antifertility effects of the aqueous extracts of *Carica papaya* seeds in male rats. *Plant Med*. 60(5): 400-404.

Nwaopara A.O., Akpamu, U., Izunya A.M., Oaikhena, G.A., Okhiai, O., Anyanwu, L.C., Idonije, B.O. and Oyadonghon, G.P. (2011): The effect of *Yaji*-meat-sauce consumption on cerebellar neurons of white albino rats. *Current Research Journal of Biological Sciences*; 3 (4): 308 - 312.

Oduola, T., Adeniyi, F.A.A., Ogunyemi, E.O. Idowu, T.O. and Bello, I.S. (2007): Evaluation of the effect of intake of extract of unripe pawpaw (*Carica papaya*) on Liver function in sickle cell patients. *World Journal of Medical Sciences*; 2(1): 28-32.

Olagunju, J.A., Adeneye, A.A., Fagbohunka, B.S., Bisuga, N.A., Ketikus, A.O., Benebo, A.S., Olufowobi, O.M., Adeoye, A.G., Alimi M.A. and Adeleke, A.G. (2009): Nephroprotective activities of the aqueous extract of *Carica papaya* Linn. In carbontetrachloride induced renal injured wistar rats: a dose and time dependent study. *Biol. and Med*; 1: 11-19.

Thomas KD. and Ajani B. (1987). Antisickling agent in an extract of unripe pawpaw (*Carica papaya*). *Transaction of the Royal Society of Tropical Medicine and Hygiene*; 81: 510 -511.

Udoh, F. and Udoh, P. (2005): Hepatotoxicity of the methanol extract of *carica papaya* seeds in Wistar rats. *Pharm. Biol*; 43: 349-352.

Verma, R.J., Nambiar, D. and Chinoy, N.J. (2006): Toxicological effects of *Carica papaya* seed extract on spermatozoa of mice. *J Appl Toxicol*; 26(6):533-535.

AUTHOR'S CONTRIBUTION

All authors contributed to the preparation and presentation of this manuscript.