

# Holoprosencephaly In A Nigerian Female: A Case Report

Type of Article: Case Report

Chukuemaka .E. Agi , Cecil Abere

Department of Radiology, University of Port-Harcourt teaching hospital, Port-Harcourt, Nigeria.

## ABSTRACT

**BACKGROUND:** Holoprosencephaly is a complex intracranial abnormality with 3 ranges of severity: Lobar, semi-lobar and alobar. The clinical presentation with typical facial anomalies is unique. Imaging with USS, CT and MRI are useful diagnostic tools. We here report the first case of holoprosencephaly in the University of Port Harcourt Teaching Hospital and highlight the clinical and radiological diagnosis of this condition.

## METHODOLOGY

The medical records of the patient who presented with Holoprosencephaly (HPE) and literature review of the subject using available journals and medline search were utilised. The reviewed radiologic investigation modality establishing the diagnosis was contrast enhanced computed Tomography in which axial noncontrast/postcontrast 10mm sections were taken and the axial images and reconstructions( coronal/ sagittal ) were reviewed.

The Computed Tomography machine used is a Helical 8 slices General Electric Machine and contrast medium administered was Iopamidol in standard dose for weight

**RESULT** A 1 day old female infant delivered in a peripheral hospital with absent nasal opening and neonatal asphyxia. Cranial computed tomography showed rudimentary nasal septum, hypotelorism and nasal aperture stenosis with absent interhemispheric fissure and falx cerebri, solitary widened monovertricle and fused thalami .

**CONCLUSION** Holoprosencephaly is a rare congenital structural anomaly of the prosencephalon that results in incomplete development of the brain. In its severe form it is incompatible with life. Its etiology is not fully established

**KEY WORDS:** holoprosencephaly; facial anomalies; Radiologic diagnosis; Nigeria.

**Correspondence:** C.E. Agi

this scheme, congenital brain malformations can be classified according to their stage of development as anomalies of neural tube closure e.g spinal dysraphisms, anomalies of structure and neural migration such as holoprosencephaly<sup>2</sup>

Holoprosencephaly is a complex intracranial abnormality characterized by absent or incomplete cleavage of the prosencephalon (forebrain)<sup>3,4,5</sup> It is a spectrum of congenital structural forebrain malformation characterized by midline hemisphere fusion where the most medial aspects of the hemispheres fail to form

Three ranges of severity are described by DeMeyer; lobar, semilobar and alobar in order of increasing severity of anomaly<sup>5,6</sup>. Another milder subtype called middle interhemispheric variant (MIH) or syntelencephaly has also been described and reported by Barkovich in 1993<sup>7,8</sup>

Holoprosencephaly (HPE) occurs in 1:16,000/18,000 live births and 1:250 conceptuses<sup>8,9,10</sup>. The female to male ratio at birth is 2:1.

The pathogenesis of holoprosencephaly (HPE) is thought to be due to disruption of the normal induction and patterning of the rostral neural tube during early embryogenesis with possible teratogenic and genetic causes including trisomy 13, trisomy 18 and maternal diabetes<sup>11</sup>

Distinctive midline facial malformations occurs in most cases which correlates with the degree of holoprosencephaly(HPE) and have prognostic significance<sup>7,11</sup>.

We report here a case of holoprosencephaly (HPE) seen in the University of Port-Harcourt Teaching Hospital and highlight the role of modern neuro-imaging in the diagnosis.

## CASE REPORT

Baby M.A, a 1 day old female infant was referred 2 hours after delivery from a peripheral hospital on account of absence of nasal openings of birth. She had mild to moderate birth asphyxia and was intubated with an oro-tracheal tube in the peripheral hospital prior to referral.

The Mother was a 35 year old Para 4 woman who was not diabetic. She took only routine ANC drugs throughout the pregnancy. There was no history of Herbal Drug Intake, alternate medical therapy, febrile illness or skin rash in the course of pregnancy.

## INTRODUCTION

Most developmental anomalies of the brain are idiopathic, although such anomalies have been associated with use of drugs, alcohol, and medication during pregnancy as well as genetic transmission.<sup>1</sup>

A unifying factor for classification of developmental anomalies of the brain is the time at which the change to the developing brain occurred during gestation. According to

Obstetric ultrasonography done 1 day prior to elective caesarean section for transverse lie and post ultrasonic /last menstrual period expected date of delivery showed polyhydraminium. AFI = 36. The sonologist did not report on the intracranial structures.

Physical examination revealed a neonate that was dyspnoic and cyanotic. Examination of the Ear, Nose and Throat showed absent external nasal openings (nostrils) bilaterally. They were sealed with skin. She was tachypneic but without any significant respiratory findings. The cardiovascular and gastrointestinal systems were normal. Craniofacial computed tomography showed normal cranial vault but indistinct hypophyseal fossa on scanogram. No calcification was seen. The soft tissues of the nose were seen with an orotracheal tube insitu. Axial pre/post contrast sections showed a rather rudimentary nasal septum with narrowing of the transverse diameter of the nasal bone making the inter-orbital diameter small 10mm (hypotelorism ). The posterior opening of the nasal cavity appeared absent. Evaluation of the intracranial structures showed absence of the interhemispheric fissure and falx cerebri. A solitary widened lateral ventricle (monovertricle) was seen with associated cortical thinning which is typically described as "pancake of anterior cerebral tissue". The brain stem and cerebellum were all normal. The thalami were fused. The petrous and sphenoid ridges were preserved.

A diagnosis of holoprosencephaly (HPE) was made based on the above findings.

A few hours after the CT examination, the parents of the

IMAGE 1

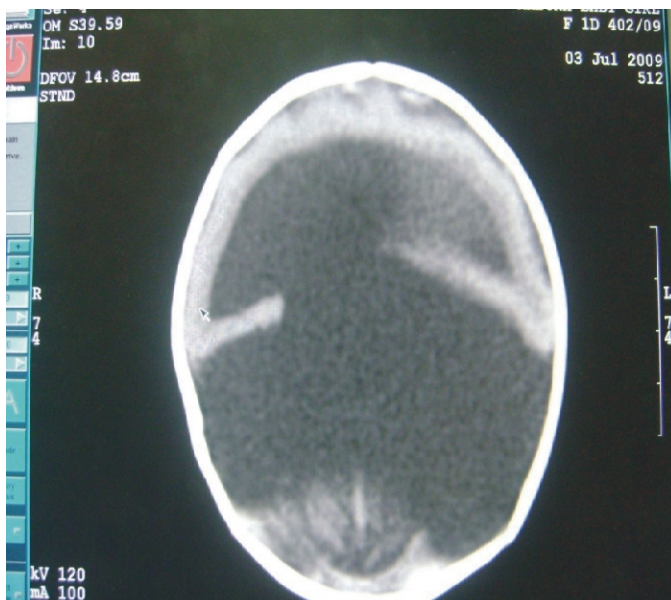


IMAGE 1 SHOWING THE AMADAEUS SILHOUETTE OF VENTRICULAR MORPHOLOGY IN ALOBAR HOLOPROSENCEPHALY-Black arrow shows contiguous gyrus crossing the midline and the white arrow shows the Monovertricle.

IMAGE 2

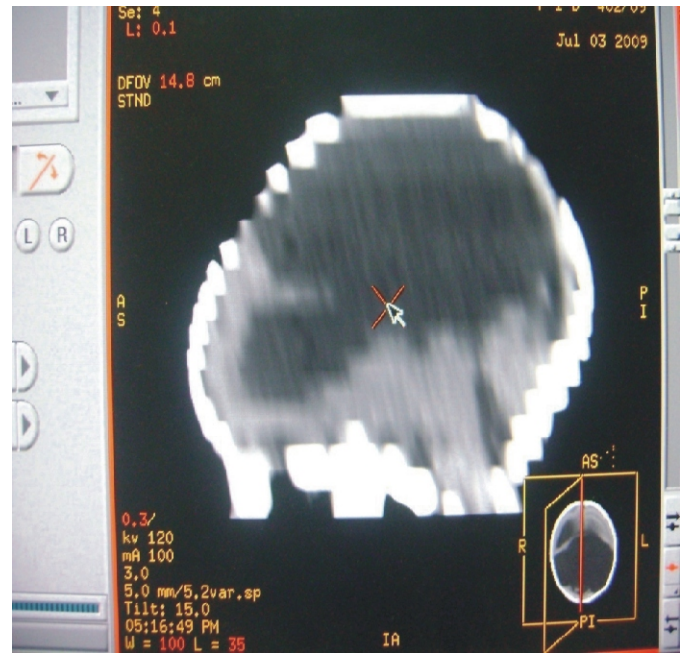

IMAGE 2-SAGITTAL RECONSTRUCTION SHOWING ANTERIOR DISPLACEMENT OF THE HEMISPHERIC TABLE (BLACK ARROW) AND FLATTENING OF THE

patient signed against medical advice and took the patient away from the hospital.

#### DISCUSSION

While the exact cause of holoprosencephaly (HPE) is yet to be determined<sup>10</sup>, active research into its pathophysiology has revealed multiple teratogenic and genetic causes (both chromosomal and single gene)<sup>11</sup>. The most common genetic abnormality associated with holoprosencephaly is trisomy 13, chromosomal deletions, duplications and translocations<sup>7</sup>. Other trisomies implicated are trisomy 18, 9, 3, 11,

Numerous possible risk factors have been identified including gestational diabetes, (1%) trans-placental infections (the TORCH complex), first trimester bleeding and a history of miscarriage<sup>10</sup>. Our patient did not have gestational diabetes and her pregnancy was uneventful.

There is evidence of correlation between holoprosencephaly and the use of various drugs classified as being potentially unsafe for pregnancy and lactating mothers. These include aspirin, lithium, thiorazine, retinoic acid and anticonvulsants<sup>11</sup>. There is also a correlation between alcohol consumption, nicotine, cigarette smoking and holoprosencephaly<sup>12,13</sup>. Although the mother of the patient in our report took only routine antenatal drugs such as folic Acid and Ferrous sulphate, it should be noted that the use of over the counter drugs which may not be considered significant is not uncommon amongst pregnant women in our community.

At birth, the ratio of females to males with holoprosencephaly (HPE) is 2:1, with the ratio increasing as

the degree of severity increase. The cause of this sex discrepancy remains unknown<sup>11</sup>. It is important to note that the gender of the patient in this case is female. No correlation has been found between holoprosencephaly and maternal age. Our patient's mother was aged 35 years.

Holoprosencephaly is associated with typical facial anomalies which include cyclopia in which a single midline fused eye exists in a single orbit below a proboscis with ocular hypotelorism and midline clefting<sup>11,14</sup>. Other subtle facial dysmorphic features include flat nasal bridge, single midline upper incisors, absent nasal bones and nasal septum and congenital nasal aperture stenosis. The closer the pair facial structures the greater the degree of severity of the internal (brain) malformations. It is instructive to note that our patient had a rudimentary nasal septum, hypotelorism and nasal aperture stenosis that necessitated orotracheal intubation.

Holoprosencephaly is usually associated with microcephaly, although macrocephaly or microcephaly may be seen<sup>11,15</sup>. Our patient neither had microcephaly or macrocephaly, her cranial vault being intact and within normal clinical and radiological limits (normocephaly).

The imaging study of choice for the diagnosis and classification of holoprosencephaly is cranial MRI<sup>14</sup>. The next best are USS and cranial CT<sup>11,16</sup>.

De Meyer has classified Holoprosencephaly into 3 categories based on the facial clinically observable features and their imaging findings. The appearance of the face predicts the brain anomalies. From the mild to the most severe these are Lobar Holoprosencephaly, Semi-lobar Holoprosencephaly and Alobar Holoprosencephaly.

Reliable prenatal sonographic diagnosis is possible in cases of alobar and semilobar, but not usually lobar holoprosencephaly<sup>14</sup>. Gray scale ultrasound shows the absence of the midline fissure and the cortical fusion. Also Color Doppler demonstrate the absence of the superior sagittal sinus and a variable absence of the deep and midline venous structures. Prenatal MRI can be done in cases in which the foetal head is not easily accessible<sup>11</sup>.

Both Computed Tomography (CT) and Magnetic Resonance Imaging (MRI) are useful for the complete evaluation of Holoprosencephaly. Axial CT with three dimensional reconstructions provide information regarding the skull and facial anatomy while MRI defines the cranial contents better than any other modality.

On CT and MRI images, alobar holoprosencephaly results in a horseshoe shaped monoventricle, an absent interhemispheric tissue, fused thalami, an absent falx, agenesis of the corpus callosum, an absent septum pellucidum and absent olfactory bulbs. Axial nonenhanced CT shows the characteristic "Amadeus" silhouette of the ventricular morphology. The sagittal view shows inferior flattening of tentorium and anterior displacement of the hemispheric tissue by the large monoventricle.

Semilobar holoprosencephaly is characterized by partial ventricular differentiation but with a single ventricular cavity,

a partial interhemispheric fissure and falx, partial and incomplete formation of the corpus callosum and a variable degree of thalamic fusion. The abnormality tends to be more severe anteriorly with partial cleavage and lateral differentiation occurring posteriorly. Lobar holoprosencephaly occurs with partial fusion of the frontal lobe with an otherwise normally formed interhemispheric fissure, lateral ventricular formation, variable and incomplete absence of the anterior corpus callosum and /or septum pellucidum and separate thalami. The middle interhemispheric fusion variant appears as incomplete cleavage of the posterior frontal and parietal lobes and often incomplete cleavage of the basal ganglia and thalami. The body of the corpus callosum is absent in the area where cleavage has failed to appear<sup>11</sup>.

Our patient showed absent interhemispheric fissure and falx, a solitary widened monoventricle and fused thalami. (see Images) and therefore falls into the severest (Alobar) of the 3 classifications by De Meyer<sup>5,6</sup>.

Recent advances in sonographic 3D imaging is making the diagnosis of holoprosencephaly easier and is rendering the concepts of the anomaly vivid<sup>17</sup>.

Clinical features of infants with Holoprosencephaly are those of seizures and mental retardation as well as endocrine challenges. Presentation is usually in infancy. The anomaly is over-represented in fetal demise and stillbirths indicating a poor prognosis which is worse with the Alobar variety.

## CONCLUSION

Holoprosencephaly is rare congenital brain and facial anomaly with incidence of 1:16,000/18,000 live births and 1:250 conceptuses<sup>7,9,10</sup>. The female to male ratio at birth is 2:1.

Prenatal diagnosis is usually established commonly by ultrasonography or occasionally by MRI in the 2<sup>nd</sup> trimester. Postnatal diagnosis can be made by ultrasound, CT or MRI or a combination of the imaging modalities.

We thus recommend detailed fetal anomaly sonographic evaluation of all pregnant women with significant risk factors such as Diabetes Mellitus, inappropriate drug use, polyhydramnios between the 18<sup>th</sup>-24<sup>th</sup> weeks of gestation for prenatal diagnosis.

Also proper antenatal care and drug education of potential mothers/couple will also reduce the incidence from prescription/nonprescription drugs.

## REFERENCES

1. Warkany J, Passarge E, Smith LB. Congenital Malformations in autosomal trisomy syndromes. *Am J Dis Child* 112:502-517, 1966.
2. Van der Knaap MS, Valk J. Classification of congenital abnormalities of the CNS. *AJNR* 9:315-326, 1988.
3. Macahan PJ, Nyberg AD, Mac AC. Sonography of facial features of alobar and semi-lobar holoprosencephaly. *American Journal of Radiology*

- (AJR) 1990; 154;143-148.
4. Susan DJ. Pediatric imaging. In *Fundamentals of Diagnostic Radiology*: 3<sup>rd</sup> Ed. New York; Lippincott Williams & Wilkins 2007:225-226.
  5. De Meyer W. Holoprosencephaly. In Myrianthopoulos N (ed) : *Malformations*. New York ;Elsevier;1987: 225-244.
  6. De Meyer W, Zeman W. Alobar Holoprosencephaly ( Arhinencephaly ) with median cleft and palate: Clinical electroencephalo graphic and nosologic considerations. *Confin Neurol* 1963;23: 1-36.
  7. Bendavid C, Dupe V. Holoprosencephaly: An update on cytogenetic abnormalities. *American Journal of Medical Genetics* 2010;( 154C):86-92.
  8. Demeyer W, Zeman W, Palmer CG. The face predicts the brain: Diagnostic significance of median facial anomalies for holoprosencephaly (arhinencephaly). *Paediatrics* 1964; 34: 256-63.
  9. Barness EG. Prosencephaly Growth Failure. In *A Review of Potter's Pathology of Foetus and infant and child* 2<sup>nd</sup> Edition. Vol. 2 Missouri; Mosby 1997: 1056-59.
  10. Simon EM, Hevner R, Pinter JD, Clegg NJ, Delgado M, Kinsman S, et al. The dorsal cyst in holoprosencephaly and the role of the thalami in its formation. *Neuroradiology*, 2001, 43:787-791.
  11. Cohen MM. Holoprosencephaly: clinical, anatomic, and molecular dimensions. *Birth Defects Res A Clin Mol Teratol* 2006 , **76**:658-673.
  12. Croen LA, Shaw GM, Lammer EJ. Risk factors for cytogenetically normal Holoprosencephaly in California: A population based cause control study: *American Journal of Medical Genetics* 90, 320-325:2000.
  13. Hayashi M. Neuropathological evaluation of the diencephalon, basal ganglia and upperbrainstem in Alobar holoprosencephaly. *Acta Neuropathol* 2004 107(3):190-6.
  14. Sutton D, Stevens J, Katherine M. *Intracranial lesions Textbook of radiology and imaging: Vol 2; 7th edition*, New York; Elsevier 2002:1767-1818.
  15. Anuj KT, Deepak A, Gopal S. Hydrocephalic holoprosencephaly: An oxymoron? Insights into etiology and management. *Journal of Paediatric Neurosciences* 2009;4(1):41-43.
  16. Barkovich AJ, Maroldo TV. Magnetic resonance imaging of normal and abnormal brain development;