

Marjolin's Ulcers: A Review

Type of Article: **Review**

*Kingsley O. Opara, **I.C. Otene

Plastic Surgery Division,*Department of Surgery, Imo State University Teaching Hospital, Orlu, Imo State, Nigeria and **Department of Surgery, Delta State University Teaching Hospital, Oghara, Delta State Nigeria.

ABSTRACT

Background: Marjolin's ulcers though thought to be rare have been reported to have a higher incidence in sub-Saharan Africa. These tumours typically run an aggressive course with a poor prognosis. Late presentation has been reported to be typical of these cancers and some of the reasons adduced for this, are difficulties in both clinical and pathological diagnosis.

This review therefore aims at enlightening the medical community on Marjolin's ulcers with a view to improving early recognition, treatment and outcome.

Method: Literatures on marjolin's ulcers were sourced from available journals and internet based searches using Pubmed, Medline and Google search.

Results: The incidence of Marjolin's ulcers appears higher in developing countries. First recognized in the first century AD, a lot is yet to be understood about the evolution of these cancers. Late presentation still remains a feature of this pathology even in recent times. Prognosis improves drastically with early recognition and treatment.

Conclusion: The key to improving outcome in Marjolin's ulcers is early recognition and adequate treatment.

Key Words: Marjolin's Ulcers; Review; Literature

Correspondence- Dr K.O. Opara

HISTORICAL PERSPECTIVE

It was Celcius who first observed malignant transformation in burn scars in AD 100.¹ About 1,700 years later, precisely in 1828, Jean Nicholas Marjolin, a French surgeon, published an article in the French Dictionnaire de Medicine on a series of simple leg ulcers which showed warty changes.² Described as 'Ulcer canchroides', he did not at the time recognize the malignant nature of these transformations. A more comprehensive description of these lesions was to be made a couple of years later by Dupuytren.³ Later reports of these transformations by Byron and Smith in 1844 and 1850 respectively were to confirm these conditions as carcinomas.⁴ They described cancers arising in burn scars, scars from flogging as well as other forms of trauma.

The term 'Marjolin's ulcer' was first used by Da Costa in 1903,⁵ in describing tumours arising from simple leg ulcers. This was however restrictive in nature considering there were then numerous reports of these carcinomas arising from other lesions besides chronic leg ulcers. Other authors suggested broader terms like cicatricial and scar cancers.⁴

In modern parlance, the term "marjolin ulcer" refers to carcinomas arising from chronically inflamed, or scarred skin⁶

EPIDEMIOLOGY

The true incidence of marjolin ulcers is largely unknown. It is however thought to be rare. Earlier reports of incidences of 1.2 to 2 percent of skin cancers were restricted to carcinomas arising from burn scars.^{1,7} The incidence however shows regional differences due to sociocultural and economic influences. Incidences of up to 6.8% have been reported amongst the kashmiri Indians, where the cultural practice of wearing the "Kangri," an earthen oven underneath a flowing gown predisposes to repeated burn injuries and subsequent development of marjolin ulcers popularly called "Kangri ulcers."⁸ Similar ulcers are also reported in some parts of Japan where the practice of wearing tin ovens around the abdominal region underneath the garment results in the "Kairo burn cancer" In North-western China, malignant ulcers on the buttocks known as the Kang Ulcer similarly result from the practice of warming the bed with external heat. "Erythema ab Igne," a chronic thermal dermatitis commonly seen in stockers and those who regularly warm themselves by open fires also occasionally undergoes malignant change.^{9,10}

In sub-Saharan Africa, the incidence of these ulcers is also reported to be higher than the generally reported incidence.¹¹ Up to 63% of squamous cell carcinomas in some series arose from chronically irritated or scarred skin.¹² The relative high prevalence of preceding conditions for the development of marjolin's ulcers such as chronic leg ulcers and poorly managed burns; amongst Sub-Saharan communities, may be responsible.

Marjolin ulcers have been reported in every age group, but occur predominantly in middle age, with a reported average age of onset of 53 to 59 years^{9,13} The age of onset is however thought to be lower in less developed societies. Sisrat and Shrikhande⁸ reported an age of onset of 44years in India in the late 1960s. Asuquo et al reported 44.1 years as the average age of their patients presenting with marjolin's ulcers in south eastern Nigeria. Nthumba¹¹ recently reported an average age of onset of between 36 and 42 years in Sub Saharan Africa. These averages may not however be truly representative, as a number of variables such as aetiologic agent, and age at time of onset of the predisposing condition, are known to influence the age of onset of these cancers: The latent period, that is the time

from onset of the predisposing condition, to the development of cancer, has been shown to be inversely proportional to the age of onset of the predisposing chronic condition.^{11,14,16} The average ages reported will therefore depend largely on the make up of the study population.

Most reports show a male preponderance, with ratios of 2 to 3:1 reported.^{8,9,13,14,17} Reasons for this may range from genetic differences, to a simple male bias for the predisposing conditions.

Marjolin ulcers show no racial predilection. Cultural and socioeconomic factors as earlier highlighted however influence the distribution of the disease.

PATHOGENESIS

Ewing formulated a set of criteria to establish the relationship between trauma and the development of cancer.⁹ These were equally adapted to the development of cancers in burn scars by Treves and Pack.¹ These criteria are relevant even in modern times, as a relationship of cancer to preceding trauma or a pre-existing chronic condition must be established to make a diagnosis of Marjolin's ulcer. These criteria are as follows:-

The cancer must arise within the boundaries of the scar or wound.

Incontrovertible evidence of trauma or the pre-existing ulcer as evidenced by the wound or scar.

The absence of any precursory or similar neoplasm on the site of the trauma/wound prior to the development of the cancer

The histologic variety of the cancer must be compatible with the tissues found in the site of the trauma or scar/wound

The interval time between the trauma/ulcer and the onset of the cancer must be appropriate. A period of one month has been proposed as the minimum acceptable time between the trauma/ulcer and the onset of the cancer.¹⁸

Numerous causative agents in the development of marjolin ulcers have been reported. These include Burn and non-burn traumas, osteomyelitis sinuses, pressure sores, urinary fistulas, pilonidal sinuses, gumata, radiation scars, and scars from flogging, etc.⁴. The process of evolution of this scarred or chronically irritated skin into a malignant tumour is not clearly understood. Several theories have been propounded, but none fully explains all aspects of this evolution. Some of these theories include:-

Virchows theory of chronic irritation. This theory explains that with chronic irritation and repeated tissue injury, attempts at healing become increasingly difficult and the regenerated epithelium less stable. This less stable epithelium under persistent stimulus for regeneration, eventually loses contact inhibition, and undergoes malignant change.⁹

Friedwald and Rouse proposed the co-carcinogenic theory which proposes an initiator phase and a promoter phase in the development of marjolin ulcers. An area previously exposed to a carcinogenic stimulus known as the "initiator", develops dormant neoplastic cells which when acted upon by a co-carcinogen or "promoter" are activated, and evolve into a cancer.¹⁹ Either of these acting alone may not be sufficient in itself to bring about the development of a cancer. By this theory,

a burn may act as an "initiator," while actinic radiation or some other carcinogenic stimulus acting on the burn scar acts as the "promoter." Saffioti and Shubik showed the potentiating effect of cotton oil on the development of carcinoma in burn sites on mice.⁹ Arons experimentally showed changes ranging from acanthosis to epidermoid carcinoma in tissues of rats exposed to repeated trauma;^{9,19} thus implicating trauma as a carcinogenic agent. These give support to the co-carcinogenic theory.

Treves and Pack¹ proposed the toxin theory. They suggest that as a result of tissue damage, toxins are released which result in a nutritional deficiency at the cellular level. This compromises the ability of the cells to effect tissue repairs following carcinogenic insults with attendant accumulation of mutated DNA and subsequent malignant change.

Ribet's theory of epithelial element implantation, suggests that epithelial elements implanted into the dermis following trauma, undergo a disordered regenerative process leading to carcinomatous change.¹¹

A number of researchers, support the immunologically privileged site theory. Castillo and Goldsmith suggested that the poor lymphatic flow in scar tissue, impairs immunosurveillance, making it difficult for the body to mount an effective antigen-antibody response to proto-oncogens or tumour within the scar. " Futrell and Myers later suggested that this apparent shielding allowed the tumour to "escape" early recognition by the normal host.²⁰

The hereditary theories were proposed after p53 and Fas gene mutations were found in patients with Marjolin's ulcers^{21,22}.

The environmental and genetic interaction theory seeks to explain the evolution of acute Marjolin's ulcers,²³ suggesting that genetic differences make the individual more susceptible to the environmental insult, resulting in a short latent period.

Studies have also shown patients with Marjolin ulcers have a decreased T-cell count, suggesting that immunosuppression is a contributory factor.²⁰

None of the theories so far proposed in itself fully explains the evolution of Marjolin's ulcers. At best they only explain aspects of the process of malignant transformation leading some authors to propose the multifactorial theory which proposes that a combination of the above theories will best explain the process of evolution of Marjolin's ulcers.²⁴

CLINICAL FEATURES

Characteristically, there is a time lag, or latent period between the primary pathology and the development of carcinoma. This time lag is variable, ranging from a few weeks to several years. A time lag of up to 70years has been reported in some series⁴ The shortest reported time lag has been 4 weeks, by Mcleod and Stauffer.^{25,26} The challenge in these cases with ultra short latent periods, is to prove the absence of cancer in the tissues prior to development of the observed malignant transformation. Indeed some have argued that these Marjolin ulcers with ultra short latent periods may actually have arisen from skin which previously had premalignant changes¹⁷. In any case, two distinct types of marjolin ulcers are described; Acute

marjolin ulcers with a lag phase of less than one year, and chronic marjolin ulcers with a lag phase longer than a year. The former which is quite rare is seen more often following burn injuries in the older age groups.¹ This as pointed out by Nancarrow⁴ may suggest that the skin is less able to withstand trauma and indeed carcinogenic insults, as it ages.

In general the average latent period for marjolin's ulcer has been reported to be between 20 and 40 years.⁹ Shorter averages are however reported in sub-Saharan Africa.^{11,12}

The commonest region of the body involved are the lower limbs. Average figures of 40% for the lower extremities, 30% for the head and neck region, 20% for the upper extremities, and 10% for the trunk are generally accepted.^{20,28} The predominance of lower limb involvement in cicatricial cancers as opposed to the overwhelming head and neck predominance in spontaneous epidermoid carcinomas suggests the less significant role of actinic radiation in the aetiopathogenesis of marjolin's ulcers as opposed to spontaneous epidermoid carcinomas. Marjolin ulcers are also commoner in scars over flexion creases and junctions of mobile and non mobile areas. These scars are exposed to recurrent trauma and therefore more likely to be unstable. Also, thick, firm, hypopigmented scars, as well as scars from deep burns allowed to heal slowly without skin grafting, show less stability and therefore have a greater tendency towards malignant change.^{1,8,29,30}

Treves and pack¹ describe two clinical types of marjolin ulcers

The flat indurated, infiltrative, ulcerative marjolin ulcer.

The less frequent exophytic papillary form.

The former is commoner, with a poorer prognosis. Malignant changes in scars/ chronic ulcers are often insidious and heralded by pain. There may also be a change in the nature of discharge which often becomes offensive and sometimes hemorrhagic. The extension of the ulcer is often slow in the early stages⁹

The malignant change often begins at the edge which may show some warty change with elevation. Occasionally there is the appearance of a mass within the scar or ulcer. The base of the ulcer becomes increasingly indurated with a granular, often necrotic floor with blood clots. Healing may occur in some areas where sloughing has occurred thus presenting a deceptively innocuous appearance.^{9,20,31} It is also important to note that all the signs of malignant transformation must not necessarily be present to draw a suspicion of Marjolin's ulcer. Nthumba in presenting his series on Marjolin's ulcer developing from pressure sores, noted that these ulcers commonly had a benign appearance of both the ulcer edges and the bases, and except for a foul smell, showed none of the classical signs of malignant transformation.³² This occasionally makes clinical diagnosis difficult. The occasional difficulty in making a clinical diagnosis, as well as confounding histopathological features are some of the reasons cited by Vanessa et al³⁷ as being responsible for the observed late presentation commonly seen in patients with Marjolin's ulcers.³³⁻³⁸

With time these tumours invade the deeper tissues such as muscle, bone and other deeper structures. Fig. 1. Patients occasionally present with pathological fractures.

Marjolin ulcers in the early stages spread mainly by direct tissue invasion with metastasis occurring relatively late. Lymphatic spread occurs in the late stages especially when the

tumour has gone beyond the margin of the scar. This may be explained by the poor lymphatic flow in scar tissue, a feature which also confers some protection from immunological recognition on the early stages of Marjolin's ulcers as suggested by castilo and goldsmith.⁷ The presence of regional lymph node metastasis is considered the most important prognostic factor.⁹ Distant metastases are uncommon.

DIAGNOSIS

The main stay of diagnosis is histological. Tissue biopsy should be taken from the suspicious areas of the edge as well as the central area.¹ Malignant transformation usually starts at a margin with gradual progression.⁹ The clinician must therefore recognize areas of suspicious change, to reduce the chances of a false negative biopsy results. Considering the multifocal nature of marjolin ulcers, some authors have suggested an excision biopsy of the entire scar/ulcer where possible, to reduce the chances of a false negative.³⁹ Indeed cases where multiple focal biopsies turned out negative but complete excision revealed presence of carcinomatous change have been reported.⁴⁰

The commonest histological variety seen in marjolin's ulcer is squamous cell carcinoma.^{4,9,11} Other histological varieties like basal cell carcinomas, malignant melanomas, fibrosarcomas, liposarcomas, have been reported.^{4,5,14,37} Occasionally, more than one histologic variant may be seen within the same scar. Presence of a mix of basal and squamous cell cancer often described as basosquamous, have been reported. Novick et al⁹ also reported a combination of squamous cell carcinoma, and melanoma within the same scar. This probably implies a common aetiopathogenesis for the variety of histological types of cancers seen in marjolin's ulcers.

A common confounding histological finding is pseudoepitheliomatous hyperplasia commonly seen in chronic ulcers. This shows irregular invasion of the dermis, but unlike in squamous cell carcinoma, the squamous cells are usually well differentiated with leukocytic invasion of the proliferating epithelium which is usually limited by a definite basement membrane. It is however important to note that malignant change may occur in a field of pseudoepitheliomatous hyperplasia hence the need for Multiple biopsies from different sites.^{9,41}

Radiological imaging techniques such as CT scan, MRI and plain radiographs are useful in assessing involvement of deeper tissues. The typical imaging features of Marjolin's ulcer as highlighted by Smith J et al are bone destruction, soft tissue mass and periosteal reaction⁶. CT is however more sensitive than plain radiographs in detecting skeletal involvement, while MRI better delineates soft tissue involvement.

TREATMENT

Surgery remains the main stay of treatment for Marjolin's ulcer. Wide surgical excision with margins of up to 2 to 4 cm have been suggested by various authors^{12,20,42}

A surgical margin of 2 cm is however generally recommended.^{9,23} Some authors have recommended a wider margin of 2.5cm for recurrent tumours.⁴³ In view of the multifocal nature of marjolin's ulcers however, the suggestion by Nancarrow of excising the entire scar tissue where possible and not just the area of malignant degeneration appears logical. Cases of multiple tumours arising within the same scar have

been reported.^{39,40} This is supported by the field of change theory of carcinogenesis by Willis, where the scar tissue may be considered as that field of change. The fact that local recurrences often occur within the residual scar supports this line of management.

Defects following resection should be skin grafted except where the bed may not be suitable for a skin graft, then a flap may be used. Novick et al⁹ suggests that a minimum of a 12 month interval be given between tumour extirpation, and definitive reconstruction to avoid obscuring local recurrences. This is indeed advisable considering the high recurrence rates associated with marjolin's ulcers.

Amputation is indicated when deep invasion makes local excision impossible, when there is bone or joint involvement, or when excision would severely impair function and encumber treatment.^{9,44}

Regional metastases occur in 2 to 6% of cases,⁴⁵ therefore the regional nodes should be thoroughly assessed in a patient presenting with marjolin's ulcers.

Lymph node dissection is generally advised in the presence of clinically palpable nodes and not as a prophylactic measure as shown in numerous studies.^{12,46-48}

Some investigators however suggest prophylactic node dissection (PND), based on the low salvage rate for regional node metastases.^{9,47} Late presentation may be a reason for this low salvage rate. In difficult terrains, where access to medical care is greatly limited, PND will probably do more good than harm.

Marjolin ulcers show poor response to radiotherapy as a result of their relative poor vascularity, due to extensive fibrosis.⁴² Radiotherapy has however found some use in palliation of inoperable primary or recurrent tumours⁵⁵

The relative poor vascularity of these cancers may also explain their poor response to systemic chemotherapy. Intra-arterial perfusion with methotrexate was reported by Novick et al as a useful adjunct to surgery.⁹

PREVENTION

Unstable scars and scars arising from burn wounds allowed to heal slowly have been shown to run a higher risk of malignant change.^{1,4,9,14} Deep burn wounds should be primarily grafted where possible, and unstable scars excised and grafted. Poor scars with a high risk of instability such as thick, hypopigmented inelastic scars across joints or mobile areas should be excised and replaced with supple tissue. It is important that such scar excisions should be adequate in depth as it is thought that dermal induction does occur.⁴

Scars on the scalp should be excised where possible, or protected from actinic injury. Moreso in regions with significant sunshine, people with significant scarring on their scalp should be advised to use wigs or protective clothing over their scalp when out in the open during periods of peak sunshine. Repeated exposure to corrosive chemicals used in perming the hair may not be advisable in such patients.

PROGNOSIS

Marjolin's ulcers are generally thought to have a poor prognosis.^{4,9,50-52} Squamous cell carcinomas arising from scars are 10 times more likely to metastasise than those arising from

actinic damage.^{15,16} Determinants of poor prognosis include short latency period, lower limb involvement as opposed to involvement of the upper limb, trunk and head and neck, as well as tumour size. Tumours less than 2cm in diameter are thought to have a better prognosis than those greater than 2cm in diameter. The less well differentiated tumours also carry a poorer prognosis. Deeper penetrating tumours as measured by depth of dermal invasion and vertical tumour thickness carry a worse prognosis. Recurrent tumours, and tumours with scanty peritumoural T lymphocyte infiltration also run a more aggressive course. The scanty peritumoural T lymphocyte infiltration signifies a poor host immune response. The primary lesion undergoing malignant change also influences prognosis; Tumours arising from pressure sores run a more aggressive course than those arising from post burn scars or

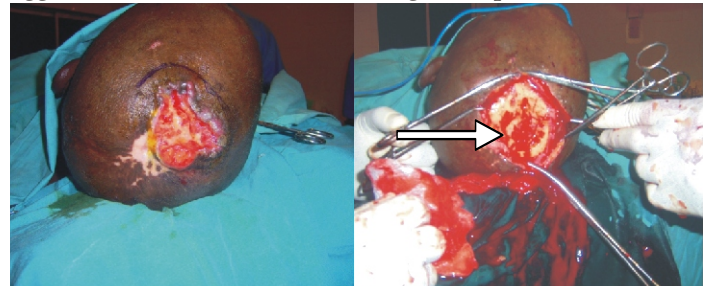


Fig. 1: Advanced Marjolin's ulcer of the scalp showing invasion of the skull.

chronic ulcers.^{9,43,53,54} The most important prognostic factor however is the presence of lymph node metastasis and this has been shown to correlate with outcome.^{9,45}

REFERENCES

1. Treves N, Pack GT: The development of cancer in burn scars. *Surg Gynecol Obstet* 1930, 51:749-782.
2. Marjolin JN. Ulcers. *Dictionnaire de Medicine*. Vol.21, 1st ed. Paris: Bechet Jeune, 1828: 46
3. Applebaum J, Burrows WM, Greenway HJ. Acute Marjolin's ulcer. *J Assoc Mil Dermatol* 1985;11: 57-61
4. Nancarrow JD. Cicatricial cancer in South-West England: a regional regional plastic surgery unit's experience over a 20 year period. *Br J Surg*. 1983;70:205-208
5. Cruickshank AH, Connel EM, Miller DG. Malignancy in scars, chronic ulcers and sinuses. *J Clin Pathol* 1963;16:573-80
6. Smith J, Mello LF, Nogueira Neto NC, et al. Malignancy in chronic ulcers and scars of the leg (Marjolin's ulcer): a study of 21 patients. *Skeletal Radiol* 2001;30(6):331-7.
7. Castillo J, Goldsmith HS. Burn scar carcinoma. *Cancer J. Clin*. 1968;18:140-142
8. Sisrat MV, Shrikhande SS. Histochemical studies on squamous cell carcinomas of the skin arising in burn scars with special reference to histogenesis. *Indian J. Cancer*. 1967;3:157-169
9. Novick M, Gard DA, Hardy SB, Spira M. Burn scar carcinoma: A review and analysis of 46 cases. *The Journal of Trauma*. 1977;10:809-817.
10. Engler HS: Cancer arising in scars of old burns. *J Med Assoc Ga* 1968; 57:145
11. Nthumba PM. Marjolin's ulcers in sub Saharan Africa. *World J Surg*. 2010;34:
12. Asuquo ME Ikpeme IA, Bassey EE, Ebughe G. Squamous Cell Carcinoma in South-Eastern Equatorial Rain Forest in Calabar, Nigeria. *Eplasty*. 2009; 9: e53

13. Callam MJ, Harper DR, Dale JJ, et al. Chronic ulcer of the leg: clinical history. *Br Med J (Clin Res Ed)* 1987;294(6584):1389-91.
14. Lawrence REA. Carcinomas arising in burn scars. *Surg Gynaecol. Obstet.* 1952; 95:579-588
15. Duncan KO, Leffell DJ. Epithelial precancerous lesions. In: Freedberg IM, Eisen AZ, Wolff K. Fitzpatrick's dermatology in general medicine. 6 ed. New York: Mc Graw-Hill; 2003. P.719-36.
16. Dupree MT, Boyer JD, Cobb MW: Marjolin's ulcer arising in a burn scar. *Cutis* 1998, 62:49-51.
17. Horton CE, Crawford HH, Love HG, Leffler RA. The malignant potential of Burn scar. *Plast Reconstr Surg* 1958;22:348-53.
18. Tenopyr J, Silverman I. The relation of chronic varicose ulcer to epithelioma. *Ann Surg* 1932;95:7548
19. Arons MS, Rodin AE, Lynch JB, Lewis SR, Blocker TG Jr: Scar tissue carcinoma. Part II: an experimental study with special reference to burn scar carcinoma. *Ann Surg* 1966, 163:445-460.
20. Malheiro E., Pinto A., Choupina M., Barroso L., Reis J., Amarante J. Marjolin's ulcer of the scalp: A case report and literature review. *Ann of Burn and fire disaster.* 2001;14:
21. Lee SH, Shin MS, Kim HS: Somatic mutations of Fas (Apo-1/CD95) gene in cutaneous cell carcinomas arising from a burn scar. *J Invest Dermatol* 1999, 114:122-126
22. Harland DL, Robinson WA, Franklin WA: Deletion of the p53 gene in a patient with aggressive burn scar carcinoma. *J Trauma* 1997, 42:104-107.
23. Kowal-Vern A, Criswell BK: Burn scar neoplasms: A literature review and statistical analysis. *Burns* 2005, 31:403-413.
24. Nthumba PM. Marjolin's ulcers: theories, prognostic factors and their peculiarities in spina bifida patients. *World Journal of Surgical Oncology* 2010, 8:108
25. McLeod JM: Burns and their treatment. London, Oxford Univ Press, 1918, p 15
26. Stauffer H: *Zeitschr Krebsforsch.* 1929;28:418
27. Simons MA, Edwards JM, Nigam A. Marjolin's ulcer presenting in the neck. *J Laryngol Otol* 2000;114:980-2.
28. Mohamed SI, Abdullah BJJ, Singh DA, Heng KS. CT appearances of Marjolin's ulcer in the left gluteal region of a young man. *Biomed Imaging Interv J* 2006; 2:e26
29. Nelzen O, Bergqvist D, Lindhagen A. Venous and non-venous leg ulcers: clinical history and appearance in a population study. *Br J Surg* 1994;81(2):182-7
30. Bowers RF, Young JM: Carcinoma arising in scars, osteomyelitis and fistulae. *Arch Surg.* 1960;80:564.
31. Esther RJ, Lamps L, Schwartz HS: Marjolin ulcers: secondary carcinomas in chronic wounds. *J South Orthop Assoc* 1999, 8:181-187.
32. Nthumba PM. Marjolin's ulcers: theories, prognostic factors and their peculiarities in spina bifida patients. *World Journal of Surgical Oncology* 2010, 8:108
33. Baldursson BT, Hedblad MA, Beitner H, Lindelöf B. Squamous cell carcinoma complicating chronic venous leg ulceration: a study of the histopathology, course and survival in 25 patients. *Br J Dermatol.* 1999;140:1148-52.
34. Kontochristopoulos G, Kyriakis K, Symeonidou S, Katsiboulas V, Aroni K, Panteleos D, et al. Squamous cell carcinoma in chronic trophic ulcers of leprosy patients. *J Eur Acad Dermatol Venerol.* 2000;14:222-36
35. Baldursson B, Sigurgeirsson B, Lindelöf B. Venous leg ulcers and squamous cell carcinoma: a large-scale epidemiological study. *Br J Dermatol.* 1995;133:571-4.
36. Bosch RJ, Gallardo MA, Ruiz Del Portal G, Sanchez P, Arce MF, Herrera E. Squamous cell carcinoma secondary to recessive dystrophic epidermolysis bullosa: report of eight tumours in four patients. *J Eur Acad Dermatol Venerol.* 1999;13:198-204.
37. Vanessa O. Zagne Bauk^I; Aline Mesquita Assunção^{II}; Renata Ferreira Domingues^{III}; Nurimar C. Fernandes^{III}; Tullia Cuzzi Maya^{IV}; Juan Piñeiro Maceira^{IV} Marjolin's ulcer: a twelve-case report *Anais Brasileiros de DermatologiaAn. Bras. Dermatol.* 2006. 81
38. Celikoz B, Demiriz M, Selmanpakoglu N. A shorter lag period of mesenchymal malignancy on Marjolin's ulcer. *Burns* 1997;23:72-4
39. Das S, Roy AK, Maiti A. Marjolin ulcer with multifocal origin. *Indian J Dermatol* 2009;54:14-5
40. Phillips TJ, Salman SM, Bhawan J, Rogers GS: Burn scar carcinoma. Diagnosis and management. *Dermatol Surg* 1998, 24:561-565
41. Kirkham N. Tumours and cysts of the epidermis. In: Lever WF, Lever GS. *Lever's histopathology of the skin.* 8 ed. Philadelphia: Lippincott-Raven; 1997. p. 685-746.
42. Ames FC, Hicky RC. Squamous cell carcinoma of the skin of the extremities. *Int Adv Surg Oncol.* 1980;3:17999.
43. Abdolazim Ghalambor. Marjolin ulcer: How much of safety margin needs resection along marjolin ulcer squamous cell carcinoma in recurrence cases. *Pak J Med Sci* May - June 2007 Vol. 23 No. 3 394-397
44. Fleming M.D., Hunt J.L., Purdue G.F. et al.: Marjolin's ulcer: A review and re-evaluation of a difficult problem. *J. Burn Care Rehabil.*, 11: 460-9, 1990.
45. Gross ND, Monroe M. Skin cancer: squamous cell carcinoma. 2009 Available at: <http://emedicine.medscape.com/article/870430-overview>. Accessed April 15, 2011
46. Barr LH, Menard JW. Marjolin's ulcer: the LSU experience. *Cancer* 1983;52:173-5.
47. Hill bb, Sloan DA, Lee EY, McGrath PC, Kennady DE. Marjolin's ulcer of the foot caused by non-burn trauma. *South Med J* 1996;89:707-10
48. Arons MS, Rodin AE, Lynch JB, Lewis SR, Blocker TG Jr: Scar tissue carcinoma. Part I: A clinical study with special reference to burn scar carcinoma. *Ann Surg* 1965, 161:170-188.
49. Bostwick J, Pendergrast WJ, Vasconez LO: Marjolin's ulcer: an immunologically privileged tumor? *Plast Reconstr Surg* 1975, 57:66-69
50. Moller R, Reymann F, Hou-Jensen K. Metastases in dermatological patients with squamous cell carcinoma. *Arch Dermatol* 1979;115:703-5
51. Konigova R, Rychterova V. Marjolin's ulcer. *Acta Chir Plast* 2000;42:91-4
52. Alcolado JC, Ray K, Baxter M, Edwards CW, Dodson PM. Malignant change in dermatitis artefacta. *Postgrad Med J.* 1993;69:648-50
53. Friedman HI, Cooper PH, Wanebo HJ: Prognostic and therapeutic use of microstaging of cutaneous squamous cell carcinoma of the trunk and extremities. *Cancer* 1985, 56:1099-1105
54. Ozek C, Cankayali R, Bilkay U, Guner U, Gundogan H, Songur E, Akin Y, Cagdas A: Marjolin's ulcers arising in