



Mini-craniotomy under local anaesthesia and sedation as a less invasive procedure for spontaneous intracerebral haemorrhage in a developing country

Amos O. Adeleye

Division of Neurological Surgery, Department of Surgery, College of Medicine, University of Ibadan and University College Hospital, Ibadan, Nigeria

Correspondence: femdoy@yahoo.com

<https://dx.doi.org/10.4314/ecajs.v22i2.1>

Abstract

Background: Minimally invasive surgery (MINS) is being viewed as the more practical alternative to the traditional craniotomy for the evacuation of spontaneous intracerebral haemorrhage (sICH). Most such sICH arises as complications of systemic hypertension. The techniques of MINS described are not currently affordable in most developing countries.

Methods: An annotated technique of mini-craniotomy under local anaesthesia (LA) is here described as a stop-gap solution to this problem. An outcome study of this surgical technique in a prospective consecutive patient population is also presented.

Results: Twenty-one patients, 13 males, mean age 41.1 years, underwent this surgical procedure. Clinical presentation of the sICH was generally severe: 48% in coma, 81% critically ill, and many of these cases were complicated with high fever, meningism, and chest morbidity. The Glasgow Coma Scale score was 3/15 to 8/15 and 9/15 to 12/15, respectively, in 9 of 21 cases (42.9%) each. The ICH showed evidence of significant mass effect on brain computed tomography (CT) scan in 95% and was associated with intraventricular haemorrhage in 43%. The bleed was deep-seated in the white matter and basal ganglia in 16 of 21 cases, and superficial-cortical in the rest. The midline shift was at least 5 mm in all of these. The surgical procedure was successfully completed in all cases. The in-hospital results were: mortality of 62% and postoperative survival of 38%, which is well within the range of global outcome statistics related to sICH.

Conclusions: In well-selected patient groups mini-craniotomy under LA appears effectual in the surgical evacuation of sICH. It has a particular attraction as a low-cost treatment option for developing countries.

Keywords: spontaneous ICH, surgical evacuation, minimally invasive surgery, surgical technique, mini-craniotomy, local anaesthesia, low-cost procedure, developing country

Introduction

Craniotomy under general anaesthesia remains the traditional surgical method for evacuating primary, or spontaneous, intracerebral haemorrhage (sICH).¹⁻³ The outcome of this invasive surgical dissection on this high-risk patient group however remains less than encouraging in many cases.⁴⁻⁶ In randomised trials, surgically treated patients had outcomes as poor as non-surgically treated ones who received only intensive medical therapy.^{2,3} One putative explanation for this counterintuitive outcome of surgical evacuation of sICH has been the added stress of the surgical exposure on the patients who usually are in critical clinical state to start with.

For this reason, minimally invasive surgery (MINS) is now being seen as a more appropriate way to address the problem.^{6,7} Several techniques to this end have been described.^{6,8,9} They however involve the use of expensive, cutting-edge technologies that are economically beyond the reach of an average developing country's health system. What is more, patients with sICH in our practice



usually present in too poor of a clinical state to be safe candidates for extensive craniotomy under general anaesthesia.¹⁰

We have since discovered a pragmatic way around this problem. In well-selected cases, we now perform surgical evacuation of sICH under local anaesthesia with light short-acting sedative in our practice. The aim of this article is to present an annotated illustration of this surgical technique. An outcome analysis in a consecutive prospective patient cohort is also reported.

Methods

Many patients with primary ICH, especially the hypertension-related ones, present in a poor clinical state for care in our practice.¹⁰ They are usually in coma, with a Glasgow Coma Scale score (GCS) < 9/15, and have associated disease complications, such as aspiration pneumonitis, which usually make our understaffed anaesthetic team not to be too favourably disposed to administering general anaesthesia with endotracheal intubation. We usually resort to the procedure being presented in this report when faced with these difficult situations in potentially surgically salvageable patients.

Surgical technique

Before being transferred to the operating room (OR) and appropriately positioned for surgery, the patient's clinical condition is maximised as much as is practically feasible. In the OR, a wide scalp field around the proposed surgical incision is prepped; then the incision line and the scalp circumference are infiltrated with a plain local anaesthetic (LA) agent, such as 1% xylocaine, and an isolation draping of the incision site is done (Figure 1a). The scalp incision is carried into the galea and appropriately sized subgaleal scalp flaps are raised and maintained with retractors. Next, the ipsilateral myofascial soft tissue is further infiltrated generously with the same LA (Figure 1b) to facilitate a pain-free elevation of a pedicled mini-craniotomy bone flap (Figures 1c and 1d). The dural opening is made in a cruciate manner and then a limited 1 cm corticectomy, centred over the haematoma cavity, is used to access and evacuate the bleed (Figure 1e). Next, haemostasis of the haematoma bed is assured and the dural opening closed as needed (Figure 1f). The bone flap is returned, and the scalp is closed in layers over a subgaleal wound drain, out via a separate surgical stab wound (Figures 1g and 1h).

Clinical materials

A prospective consecutive database of all the patients who underwent this procedure in the author's practice had been kept over a 5-year period ending in December 2014. For this descriptive outcome study, age and gender distribution were included in the analysis, as were time to presentation for neurosurgical care; and pattern of clinical presentation of the sICH, including associated complications, and the cranial computed tomography (CT) scan pattern of the intracranial bleed. The primary outcome was success or failure of completing the surgical procedure under the limited anaesthesia. The secondary outcome was the in-hospital survival of the patients. The data were analysed using SPSS version 21. They are presented in descriptive statistics.

Results

We performed this procedure on 21 patients over this study period. The surgery was successfully completed in all cases. Figure 2 shows the pre- and postoperative cranial CT images of an illustrative case. Another clinical example is illustrated in Figure 3. The patients' ages ranged from 28 to 83 years (mean age 41.1 years; standard deviation [SD] 27.2), and about one-fifth were in their seventh decade and beyond. Thirteen patients (61.9%) were male. Premorbid history of hypertension was established in 17 cases (81%), with 88.2% (15 of 17) being noncompliant with their antihypertensive drug treatment. Admission blood pressure (BP) was not only uncontrolled in 19 patients (90.5%), it exhibited malignant derangement ($> 210/115$ mmHg) in 52.4%, with systolic BP being as high as 300 mmHg and diastolic as high as 240 mmHg.

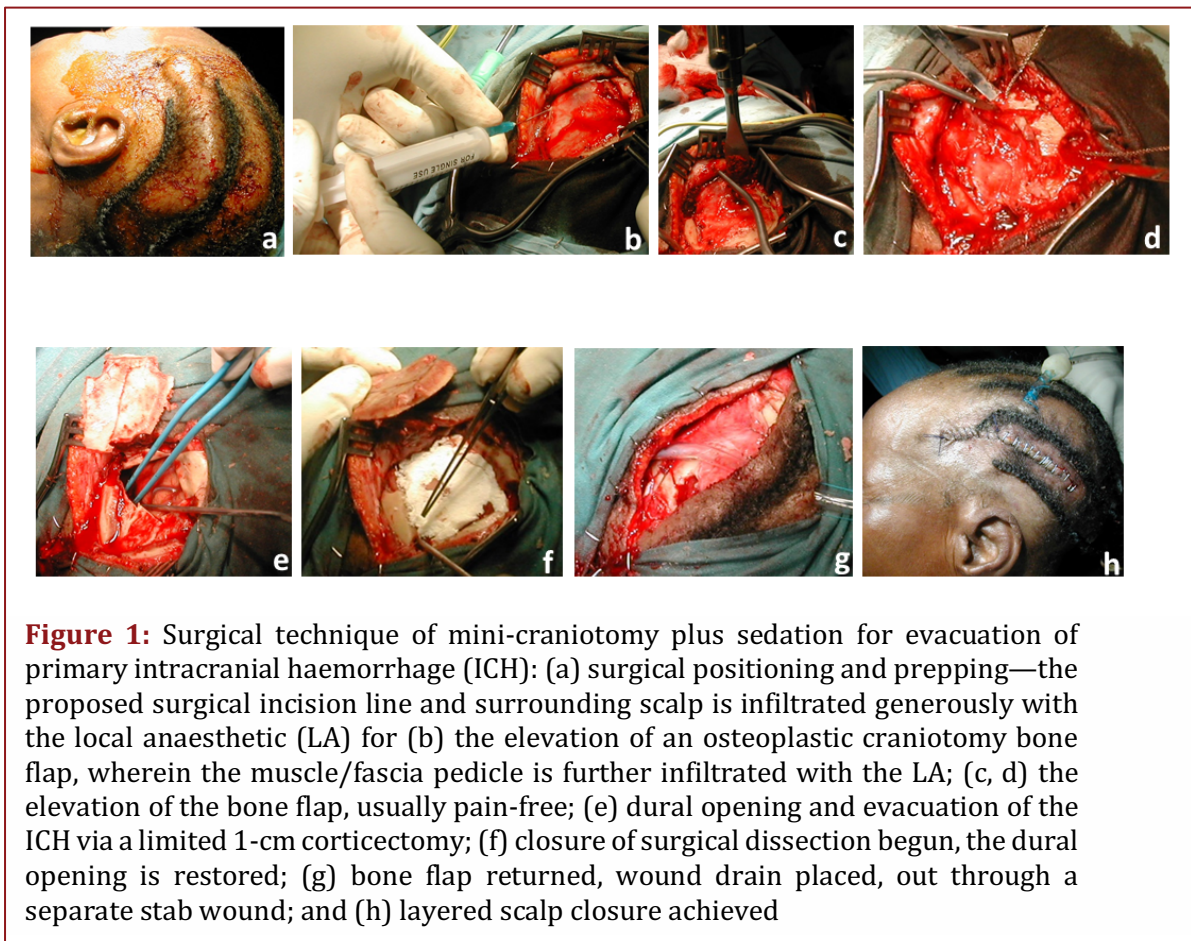


Table 1 shows some more details of the severe nature of the clinical presentations in this patient cohort. About 43% presented in coma (GCS < 9) and significant proportions were complicated with high fever (temperature > 38.5°C), chest infection or aspiration, and meningism. Nine patients (42.9%) had a GCS in the range of 3/15 to 8/15; the same number had a GCS between 9/15 and 12/15. The other 3 patients had a presenting GCS of 14/15 or 15/15. The median duration of ictus to neurosurgical presentation was 42 hours (range 6-144 hours). Cranial CT patterns (Table 2, Figure 2, Figure 3) revealed severe forms of sICH: significant mass effect (effacement of ventricles and midline shift of at least 5 mm) was present in 95.2% and there was associated intraventricular extension of the haemorrhage in 42.9%. The sICH was mainly in the cortical or deep white matter substance of the brain in 60% of the cases; 13 (61.9%) were right-sided and the rest were left-sided. The median ICH volume using the ABC/2 rule was 49 mL (range 20-70 mL).^{11,12}

Table 1: Clinical characteristics of the cases of spontaneous intracerebral haemorrhage for which mini-craniotomy was performed (N = 21)	
Variable	n (%)
Level of consciousness	
Altered sensorium	12 (57.1)
Coma (Glasgow Coma Score ≤ 8)	9 (42.9)
Clinical condition on examination	
Acutely ill	4 (19.0)
Critically ill	17 (81.0)
Fever (temperature > 38.5°C)	
Present	10 (47.6)
Absent	11 (52.4)
Breathing pattern	
Normal	8 (38.1)
Dyspnoea	7 (33.3)
Aspiration pneumonitis	6 (28.6)
Meningism	
Present	6 (28.6)
Absent	15(71.4)

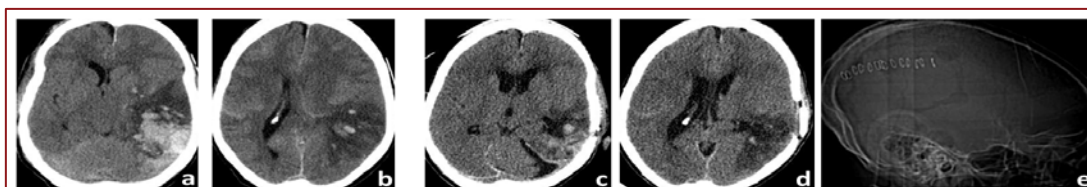


Figure 2: (a, b) cranial computed tomography (CT) scan showing the large left temporal sICH evacuated in the above patient. There is evidence of significant brain swelling: effacement of the left cerebral hemispheric gray-white differentiation and the ipsilateral lateral ventricle, as well as midline shift; (c, d) postoperative cranial CT showing complete evacuation of the haematoma and restoration of the brain anatomy; (e) the scanogram of the CT showing the outline of the mini-craniotomy.

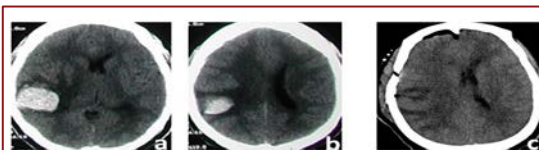


Figure 3: Another case of ICH operated with the same technique (a, b) cranial CT showing a right temporo-parietal ICH. There is significant ipsilateral brain swelling and effacement of the lateral ventricle (c) postoperative CT showing complete evacuation of the haematoma and lessening of the brain swelling

Table 2: Computed tomography (CT) scan findings of spontaneous intracerebral haemorrhage (sICH) in this patient population

Variable	n (%)
Laterality	
Right	13 (61.9)
Left	8 (38.1)
Intracerebral distribution*	
Superficial cortical	4 (20.0)
Deep cortical/white matter	4 (20.0)
Ganglionic	8 (40.0)
Mass effect	
Present	20 (95.2)
Absent	1 (4.8)
Intraventricular haemorrhage	
Present	9 (42.9)
Absent	12 (57.1)

*information not available for 1 case

Discussion

The cohort of patients in this study presented with clinically and radiologically severe forms of sICH: coma, chest morbidity, fever, ICH with mass effect, and associated with intraventricular haemorrhage (IVH). These are poor prognostic indices in a disease that to date remains the most devastating form of stroke¹³⁻¹⁸: at least 50% of sICH patients die within 30 days despite cutting-edge medical care in dedicated critical care units,⁷ and the mortality rises up to 5-times higher when sICH is associated with IVH.¹⁶

Therefore, the survival rate (more than 30%) in this patient population suggests that the surgical technique described is not doing more harm to them. The prognosis for sICH remains very poor



globally, whatever form of in-hospital care—surgical or non-surgical—is employed.^{2,6,14} In the STICH I trial, currently the most-acclaimed randomised controlled trial of the treatment options for sICH, only 26% of the surgical and 24% of the medical arms had favourable outcomes.² The follow-up report to this study, another randomised trial, even in better-selected patient cohorts, still showed 59% poor outcomes in the surgical group and 62% in the medical group.³

The surgical treatment of sICH has traditionally been craniotomy and evacuation of the haematoma under general anaesthesia with endotracheal intubation.¹ The results have been mixed. Some studies suggest benefits to this line of surgical treatment.^{19,20} Others report no benefits, or even worse outcomes.^{2,4,5} It has been suggested that the added trauma of the highly invasive traditional craniotomy (under general anaesthesia) may place extra demands on the body's homeostasis that it offsets whatever gains the surgical evacuation of the haematoma might have availed.

It is in this light that MINS to decompress sICH has now emerged as the new appropriate means to the same goal of evacuating the toxic products of these brain bleeds.⁹ Several techniques of MINS have been described. Some are neuroendoscopically accomplished, others with flat detector CT-based puncture, and many involve placement of external ventricular drainage devices and introduction of clot-lysing recombinant tissue plasminogen activator into the haematoma or the associated IVH.^{6-9,17,19} All of these techniques involve cutting-edge technology and are necessarily expensive. They are virtually beyond the reach of the health systems of developing countries for now.

The technique described in this paper may be viewed as a midway solution to the same clinical goal of a more homeostatic surgical evacuation of sICH.^{7,8} It is less invasive for the patients as shown. It avoids the added risks of general anaesthesia in this high-risk patient population. Finally, it costs much less than the traditional craniotomy under general anaesthesia to execute in our low-resource practice.

References

1. Mckissock W, Richardson A, Taylor J. Primary intracerebral haemorrhage: a controlled trial of surgical and conservative treatment in 180 unselected cases. *The Lancet*. 1961;278(7196):221-6.
2. Mendelow AD, Gregson BA, Fernandes HM, Murray GD, Teasdale GM, Hope DT, et al. Early surgery versus initial conservative treatment in patients with spontaneous supratentorial intracerebral haematomas in the International Surgical Trial in Intracerebral Haemorrhage (STICH): a randomised trial. *Lancet*. 2005;365(9457):387-97.
3. Mendelow AD, Gregson BA, Rowan EN, Murray GD, Gholkar A, Mitchell PM. Early surgery versus initial conservative treatment in patients with spontaneous supratentorial lobar intracerebral haematomas (STICH II): a randomised trial. *Lancet*. 2013;382(9890):397-408.
4. Prasad K, Mendelow AD, Gregson B. Surgery for primary supratentorial intracerebral haemorrhage. *Cochrane Database Syst Rev*. 2008(4):CD000200.
5. Prasad K, Shrivastava A. Surgery for primary supratentorial intracerebral haemorrhage. *Cochrane Database Syst Rev*. 2000(2):CD000200.



6. Provencio JJ, Da Silva IR, Manno EM. Intracerebral hemorrhage: new challenges and steps forward. *Neurosurgery clinics of North America*. 2013;24(3):349-59.
7. Barnes B, Hanley DF, Carhuapoma JR. Minimally invasive surgery for intracerebral haemorrhage. *Current opinion in critical care*. 2014;20(2):148-52.
8. Ramanan M, Shankar A. Minimally invasive surgery for primary supratentorial intracerebral haemorrhage. *J Clin Neurosci*. 2013;20(12):1650-8.
9. Yang Z, Hong B, Jia Z, Chen J, Ge J, Han J, et al. Treatment of supratentorial spontaneous intracerebral hemorrhage using image-guided minimally invasive surgery: Initial experiences of a flat detector CT-based puncture planning and navigation system in the angiographic suite. *AJNR Am J Neuroradiol*. 2014;35(11):2170-5.
10. Adeleye AO, Osazuwa UA, Ogbale GI. The clinical epidemiology of spontaneous ICH in a sub-Saharan African country in the CT scan era: a neurosurgical in-hospital cross-sectional survey. *Frontiers in Neurology*. 2015;6:169.
11. Broderick JP, Brott TG, Duldner JE, Tomsick T, Huster G. Volume of intracerebral hemorrhage. A powerful and easy-to-use predictor of 30-day mortality. *Stroke*. 1993;24(7):987-93.
12. Broderick JP, Brott TG, Grotta JC. Intracerebral hemorrhage volume measurement. *Stroke*. 1994;25(5):1081.
13. Pantazis G, Tsitsopoulos P, Mihas C, Katsiva V, Stavrianos V, Zymaris S. Early surgical treatment vs conservative management for spontaneous supratentorial intracerebral hematomas: A prospective randomized study. *Surg Neurol*. 2006;66(5):492-501; discussion -2.
14. Rincon F, Mayer SA. The epidemiology of intracerebral hemorrhage in the United States from 1979 to 2008. *Neurocrit Care*. 2013;19(1):95-102.
15. Schwarz S, Hafner K, Aschoff A, Schwab S. Incidence and prognostic significance of fever following intracerebral hemorrhage. *Neurology*. 2000;54(2):354-61.
16. Tuhim S, Horowitz DR, Sacher M, Godbold JH. Volume of ventricular blood is an important determinant of outcome in supratentorial intracerebral hemorrhage. *Crit Care Med*. 1999;27(3):617-21.
17. Zhou X, Chen J, Li Q, Ren G, Yao G, Liu M, et al. Minimally invasive surgery for spontaneous supratentorial intracerebral hemorrhage: a meta-analysis of randomized controlled trials. *Stroke*. 2012;43(11):2923-30.
18. Adeleye AO, Oyemolade TA. Determinants of the in-hospital Outcome of Spontaneous ICH in a Developing Country in the CT Era: a Neurosurgical Prospective Analytical Study. *Journal of Neurological Sciences (Turkish)*. 2016;33(2):315-24.
19. Auer LM, Deinsberger W, Niederkorn K, Gell G, Kleinert R, Schneider G, et al. Endoscopic surgery versus medical treatment for spontaneous intracerebral hematoma: a randomized study. *J Neurosurg*. 1989;70(4):530-5.
20. Ohwaki K, Yano E, Nagashima H, Hirata M, Nakagomi T, Tamura A. Surgery for patients with severe supratentorial intracerebral hemorrhage. *Neurocrit Care*. 2006;5(1):15-20.