



## Colorectal Polyposis in a 15 Year Old Boy in Uganda - Case Report

N Kakembo<sup>1</sup>, P Kisa<sup>1</sup>, J Sekabira<sup>1</sup>, D Ogdzediz<sup>2</sup>

<sup>1</sup>Department of Surgery College of Health Sciences Makerere University

<sup>2</sup>Yale university, Department of Surgery, New Haven, CT, USA

**Correspondence to:** Nasser Kakembo Email: [kakembon@ymail.com](mailto:kakembon@ymail.com)

*Colorectal polyps usually present as rectal bleeding and are associated with increased risk of colorectal carcinoma. This is a 15 year old boy who presented with painless rectal bleeding for 9 years and mass protruding from the anus for 2 years after passing stool. He had history of 3 nephews with similar symptoms. On clinical assessment an impression of Adematous familial colorectal polyposis was made and biopsy was taken from the mass that revealed inflammatory polyps. He subsequently had a total colectomy and ileall pouch anal anastomosis with good outcome. In absence of endoscopic surveillance and diagnostic services diagnosis of colorectal polyposis syndromes is a challenge because clinicians rely on digital rectal assessment and examination under anesthesia.*

**Key words:** polyposis, polyps, Uganda

**DOI:** <http://dx.doi.org/10.4314/ecajs.v21i3.16>

### Introduction

Colorectal polyps commonly present with rectal bleeding in children, adolescents and adults. Multiple juvenile polyps account for significant risk of intestinal cancer if there are more than 5 in number<sup>1</sup>. Commonly children have juvenile polyps that are solitary usually 1-5, but some children inherit genes that lead them to develop polypoosis syndromes namely adenomatous polyposis and harmatomatous polyps. The presence of multiple adenomatous polyps in the large bowel confers a high lifetime risk of colorectal cancer and should undergo surveillance for colorectal neoplasia<sup>8,9</sup>. Although the presence of multiple adenomatous polyposis (>100 polyps) can be accounted for by mutations in the adenomatous ployposis coli (APC) gene, a large group of patients remain with multiple (5-100) adenomas and in whom there is no detectable APC mutation<sup>3,8</sup>.

The hereditary polyposis syndromes include adenomatous poyposis syndromes (FAP, Gardner syndrome) and the harmatomatous polyposis syndromes (Putze-Jeghers syndrome, Juvenile polyposis, and Cowden's disease)<sup>2</sup>. The adenomatous polyposis syndromes are characterized by numerous adenomatous polyps throughout the entire colon and a spectrum of extra colonic manifestations. They invariably progress to colorectal cancer without appropriate intervention<sup>2,8</sup>. Diagnosis of symptomatic polyposis is by colonoscopy, and here we present a teenager with colorectal polyposis from a resource limited setting where there were no pediatric colonoscopy services pausing a diagnostic challenge.

### Case Report

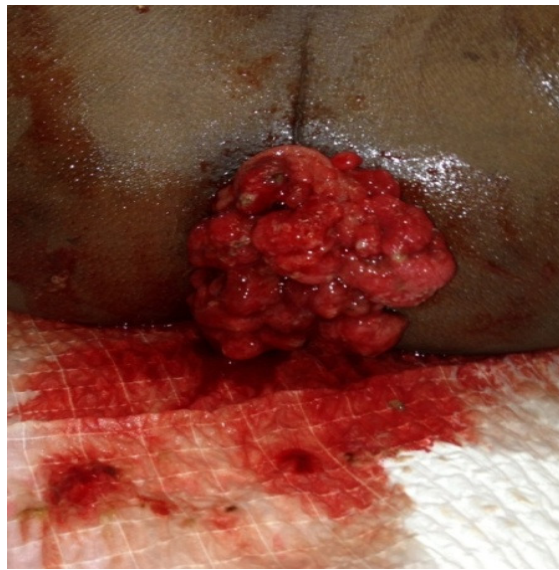
#### Case 1.

A 15 year old boy presented with 9 years of rectal bleeding and 2 years of a red mass protruding from the anus after passing stool. It was noted by the mother that this boy was staining the family pit latrine with fresh blood whenever he would pass stool and he had been treated with herbs with no improvement. Two years prior to admission he noticed a grape like red mass protruding through the anus associated with pain and fresh bleeding on defecation. Initially the mass would spontaneously get reduced but later on it would remain out. He would sometimes become so pale with generalized body weakness until when the boy was brought to pediatric surgical outreach camp where multiple rectal polyps were diagnosed. He had been treated with herbs, no medication, and no history of surgery or blood transfusion prior to this. He was from a peasant family with no first degree relatives with a similar problem but he reported to have three nephews who had occasional rectal bleeding .The boy was reported to be stunted compared to other siblings and children in the same community. Clinical examination revealed a boy who was moderately pale with no jaundice and no edema. He was generally of short stature weighing 35kg with general body weakness. Digital rectal examination revealed: a normal peri anal area and sphincter tone. There were boggy fungating masses in the rectum about 8 cm proximal to anal verge, they were red friable and

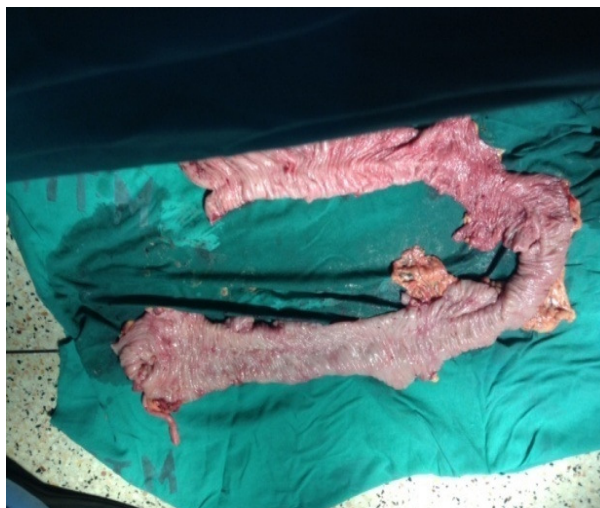circumferential easily prolapsed out of the anal canal with significant bleeding (Figure 1). The clinical impression of *Adematous familial colorectal poplyposis* was made and biopsy was taken from the mass that revealed inflammatory polyps.

The Patient was transferred to a tertiary hospital and counseled for an exploratory laparotomy due to lack of pediatric colonoscopy services in the country. At laparotomy the peritoneal cavity was clean and liver appeared normal with no tumor seeding. He had multiple enlarged lymph nodes at the ileocaecal junction. The entire colon was inspected and palpated for polyps from caecum to rectum and multiple boggy masses were felt in the caecum and sigmoid colon. Total colectomy was done excluding proctectomy. The specimen was cleaned and opened up lengthwise and found multiple polyps (over 8 polyps) in the caecal area and descending colon (Figures 2 and 3). It was subjected to histology that showed inflammatory polyps with no evidence of malignancy.

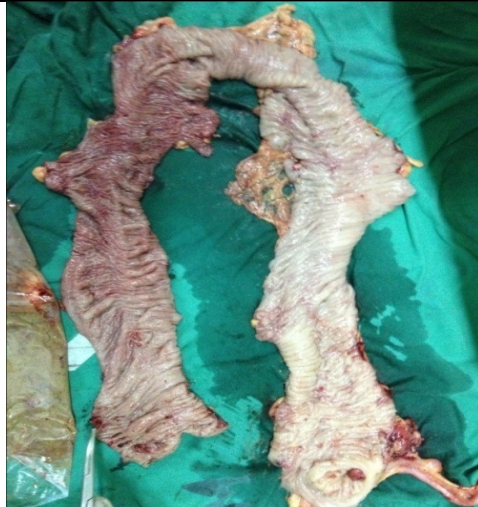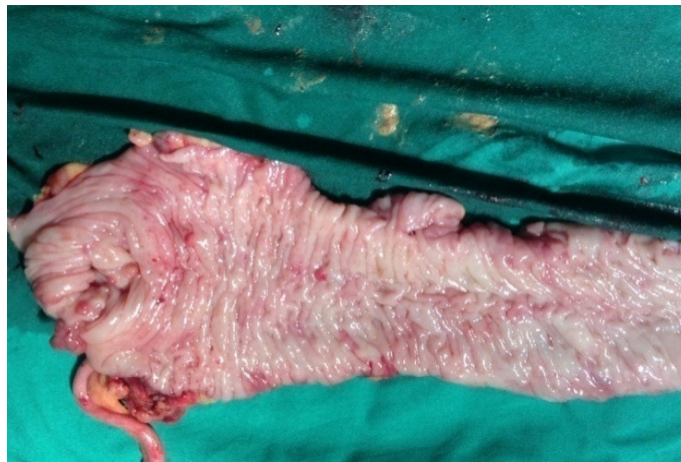Patient had a relaparotomy 2 months later with proctectomy and ileal J-pouch anastomosed to the anus with a proximal ileostomy in situ. He recovered from this surgery un eventfully and the ileostomy was closed a month later. He is currently fine with no rectal bleeding and has good bowl control



**Figure 1.**



**Figure 2**

**Figure 3****Figure 4**

### Discussion

Colonic polyps usually present with, rectal bleeding, a mass per rectum, abdominal pain, mucopurulent discharge, diarrhea, vomiting and sometimes it can be asymptomatic<sup>4</sup>. Other forms of presentation include intussusceptions and auto amputation of the polyps<sup>7</sup>. This particular boy presented with excessive bleeding after stooling with a mass protruding through the rectum.

The World Health Organization criteria for diagnosis of juvenile polyposis syndrome are one of either; more than five polyps in the colon or rectum, juvenile polyps throughout the gastrointestinal tract, any number of juvenile polyps in a person with a family history of juvenile polyposis<sup>8,10</sup>. The patient under discussion fulfilled all the criteria. Patients at risk or with high suspicion of juvenile polyposis should have endoscopic screening of the colon and upper gastrointestinal tract at 15 years or time of first symptoms<sup>8</sup>.

The surgical choices for symptomatic juvenile polyposis syndrome patients are subtotal colectomy with ileorectal anastomosis, or total proctocolectomy with a pouch<sup>5, 8</sup>. In view of risk of rectal cancer or intractable proctitis ileal pouch anal anastomosis is more acceptable to patients in spite of poorer bowel function otherwise patients who undergo subtotal colectomy require routine endoscopic surveillance of the remaining rectum every 6 months for recurrent polyps or carcinoma<sup>6,11</sup>.

The role of chemoprevention in the treatment of colorectal and duodenal adenomas is still under study. It involves use of sulindac which has shown reduction of established colorectal adenomas in adults by 50%

and celecoxib a selective cyclooxygenase -2 inhibitor that has shown some promise in reducing the number colorectal adenomas as well as duodenal adenomas <sup>11</sup>.

### Conclusion

Routine digital rectal examination and examination under anesthesia are key methods of diagnosing colonic pathology in children in absence of colonoscopy.

### References

1. Carol A Durno, Colonic polyps in children and adolescents. *Can J Gastroenterol*. Apr 2007; 21(4):233-239
2. Luk GD .Diagnosis and therapy of hereditary polyposis syndromes. *Gastroenterologist* .1995 Jun; 3(2):153-67
3. Lipton L, Tomlinson I. The genetics of FAP and FAP –like syndromes. *Fam Cancer*.2006; 5(3):221-6
4. Pillai RB, ToliaV. Colonic polyps in children; frequently multiple and recurrent. *Clin Pediatr (Phila)*. 1998 Apr; 37(4):253-7
5. Oncel M, Church JM, Remzi FH, Fazio VW. Colonic surgery in patients with juvenile polyposis syndrome: a case series. *Dis Colon Rectum*. 2005 Jan; 48(1):49-55; discussion 55-6
6. Soravia C, O'Connor Bl, BerkT, Mcloed RS, &Cohen Z. Functional outcome of conversion of ileorectal anastomosis to ileal pouch anal anastomosis in patients with familial adenomatous polyposis and ulcerative colitis . *Dis Colon Rectum*. 1999 Jul; 42(7):903-8
7. Nagasaki A, Yamanaka K, Toyohara T, Ohgami H, &Sueishi K. Management of colorectal polyps in children . *Acta Paediatr Jpn*. 1993 Feb; 35(1):32-5
8. Lodewijk AABrosens, Danielle Langeveld, & et al .Juvenile polyposis syndrome . *World J Gastroenterol* 2011 November 28;17(44):4839-4844
9. Giardiello FM,Hamilton SR,& et al. Colorectal neoplasia in juvenile polyposis or juvenile polyps. *Arch Dis Child*. 1991 Aug;66(8):971-5
10. Jass JR, Williams CB, Bussey HJ, Morson BC . Juvenile polyposis – a precancerous condition .*Histopathology* 1988Dec;13(6):619-30
11. Aikhouri, Naim, & et al .Familial adenomatous Polyposis in Childrenand Adolescents. *J ournal of Paediatric Gastroenterology &nutrition*.December 2010-Volume 51-issue 6-p727-732