

Surgical Aspects of Genitourinary Bilharzia

G. A. Maranya, Y.A. Al-Ammary, P. R. Oduor,

Consultant Surgeons, Coast Province General Hospital, P.O. Box 91066-80103, Mombasa, Kenya

Correspondence to: Dr. G.A. Maranya, Email: maranya@wananchi.com

The blood fluke *Schistosoma haematobium* mainly affects the lower genitourinary tract, where the pathological effects are a result of the reaction to the schistosome ova. The chronic effects cause damage to the musculature of the urinary tract resulting in scarring and fibrosis. The ureters dilate and or stricture. Contracture of the bladder and or detrusor failure may occur. Secondary calculi in the upper tracts and bladder are common. There is strong association with bladder cancer development of the squamous cell type. Emphasis is on the prevention of the infestation.

Introduction

Infestation with the blood fluke *Schistosoma haematobium* is endemic in Eastern, Central and West Africa, Egypt and the Indian Ocean islands off the Eastern Coast of Africa. It is transmitted through contact with contaminated water¹. The causal agent of genitourinary schistosomiasis was described in 1851 by Theodor Bilharz when he found a blood fluke in a mesenteric vein during a postmortem examination in Cairo, Egypt¹.

The schistosomulae (larvae) of the *Schistosoma haematobium* develop in the portal vein of the infected human host. At maturity the coupled adult worms migrate to the veins of the vesical and pelvic plexuses where they mate and the female lays eggs. Involvement of the various urogenital organs varies and appears to correlate with the extent of their venous circulation. The urinary bladder, lower ends of the ureters and seminal vesicles are most commonly affected by the disease in view of their rich venous supply².

Pathology

The pathological effects of *Schistosoma haematobium* infestation in man are mainly the result of an intense host reaction to the eggs. The main target organs are the bladder, distal ureters, the prostate, seminal vesicles and the spermatic cords³. Initially granulomatous lesions form in the lamina propria. The extent of the lesions, their healing, progression, or complication depends on the tissue egg load, the frequency of re-infestation, the efficiency of treatment and the onset of secondary infection. There was a significant correlation between egg burden and the histological severity of tissue reaction².

The Upper Urinary Tracts

The endopelvic part of the ureters is principally involved. The eggs may be found in all layers of the ureter. The end result is healing with a variable degree of mural fibrosis with loss of muscle and development of peri-ureteral adhesions. The sum of these changes is an obstructive uropathy caused by stricture formation and or atony and dilatation of the involved segment (Figure 1). Tissue egg loads are greater in cases with obstructive uropathy than in those without⁴. Vesicoureteric reflux has also been reported. Eventually, urinary stasis invites secondary bacterial infection and stone formation (Figures 1, 2, 3). Anuria⁵ results from bilateral total ureteric obstruction mainly by stricturing which may be aggravated by secondary calculi (Figure 2).

Management

Endourology may be useful for early short segment strictures. This entails endoscopic dilatation and visual internal urethrotomy⁶. In anuria this mode of intervention may be tried first. If it fails, nephrostomy is performed followed by further evaluation and appropriate surgery.

Open surgery is indicated for more established lesions.

- Resection and anastomosis is undertaken for a well localised short segment stricture².

- Ureteroneocystostomy; re-implantation of the ureter into the bladder, is the procedure of choice for strictures of the lower ends of the ureters. This is done flush, as tunnelling may result in restricting⁷.
- Psoas hitch ureteric re-implantation into the bladder is used for moderate length strictures of the distal ureter. The bladder is opened transversely, closed longitudinally after ureteric re-implantation and anchoring of the bladder to the ipsilateral psoas fascia above the iliac vessels.
- Boari flap is sometimes required for longer or multiple lower segment strictures². This utilises a wide flap of bladder which is tubularised to bridge a long ureteral defect, provided the bladder is not contracted.
- Replacement by ileum⁸ may be required for a long segment or multiple strictures (Figure 3). A length of ileum is used in an isoperistaltic orientation.
- Nephrectomy is indicated for advanced cases with loss of renal function

Urinary Bladder

Acute schistosomal effects

Atrophic changes result from heavy submucous ova deposition with subsequent reduction of the blood supply to the overlying epithelium. Secondary infection may play an aggravating role, resulting in erosion of the surface epithelium, thus forming bilharzial ulcers². Other effects are: haemorrhagic cystitis, acute erosions, granulomatous polyps, and pseudotubercles. Endoscopic examination is critical in evaluating these bladder lesions.

Adequate therapy with anti-schistosomal medication results in favourable healing with reversal of granulomatous lesions, small amount of mucosal fibrosis and dystrophic calcification⁹.

Chronic effects.

These are mainly the result of fibrosis and reduced vascularity of the bladder wall³. They include sand patch lesions, chronic ulcer, cystitis cystica and glandularis, leucoplakia, bladder neck stenosis, bladder contracture, bladder hypotonia and bladder carcinoma³. Most of these lesions can be ascertained by endoscopic evaluation.

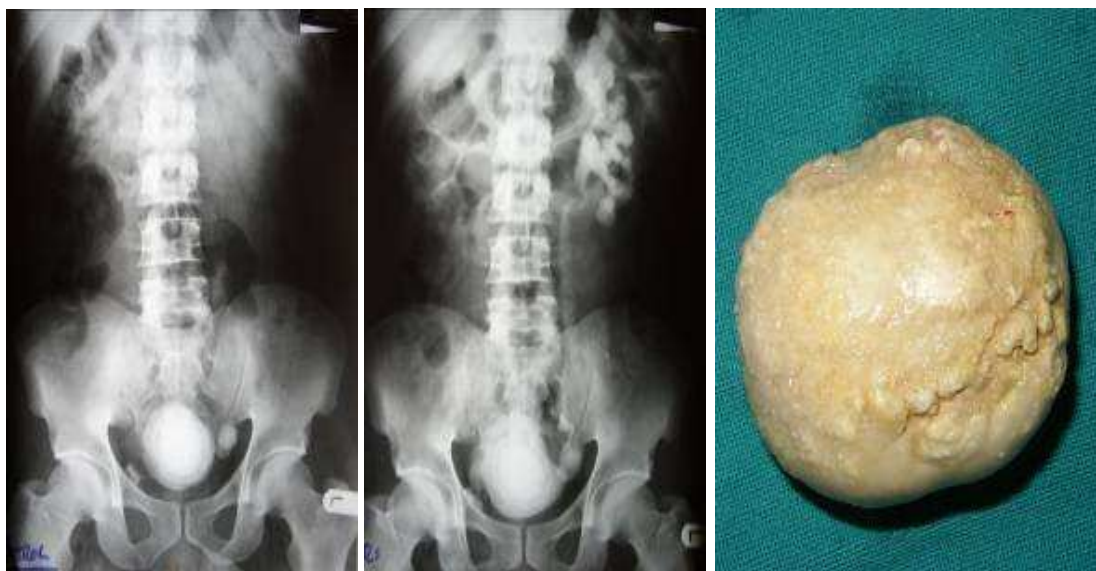


Fig. 1a

Fig. 1b

Fig. 1c

Figure 1. A 45 year old male with urinary schistosomiasis with bilateral ureterohydronephrosis on ultrasound.

- Plain abdominal X-rays showing bladder wall calcification, large bladder and left ureteric calculi.
- Urogram showing left ureterohydronephrosis with stricture at the vesicoureteric junction and a non-opacified right kidney.
- The bladder calculus after vesicolithotomy.

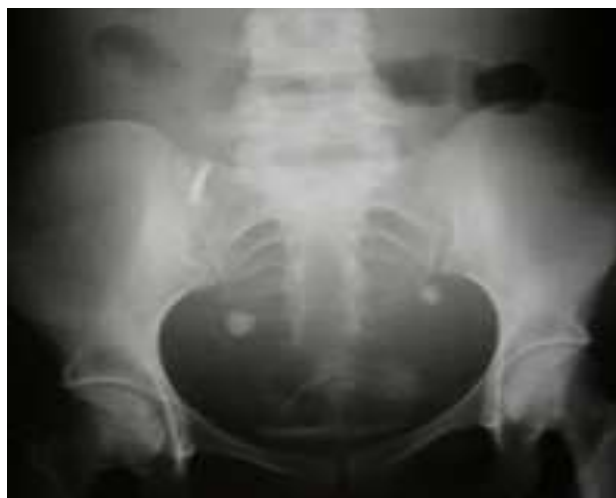

Figure 2. Plain pelvic X-ray film of a 23 year old female with anuria. Secondary bilateral ureteric calculi due to total distal ureteric obstruction confirmed at cystoscopy.

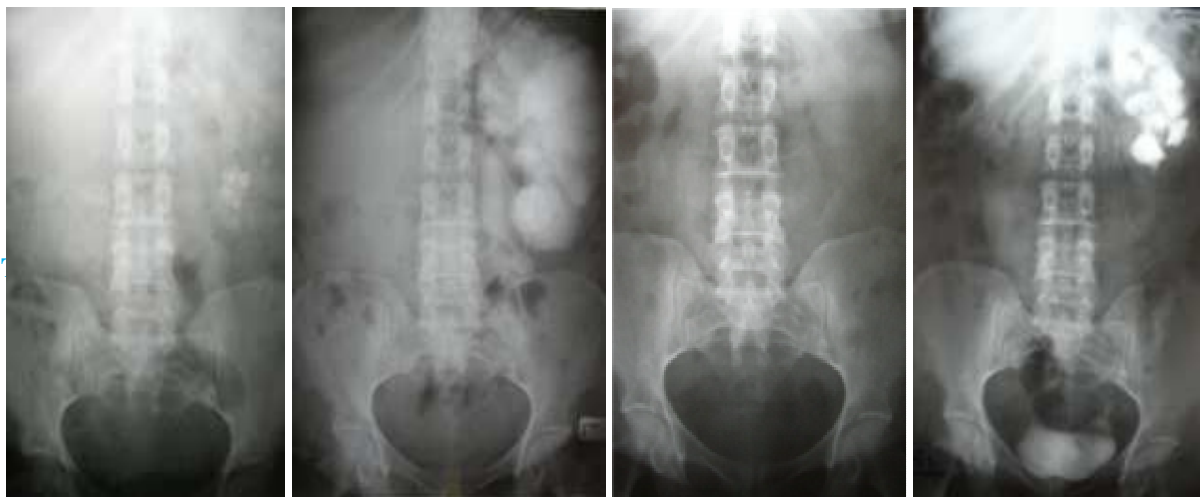

Fig. 3a

Fig. 3b

Fig. 3c

Fig. 3d

Figure 3. A 55 year old female with advanced bilharzial changes. Gross bilateral ureterohydronephrosis on ultrasound.

- a) Plain abdominal x-ray showing multiple secondary calculi in the upper left ureter and kidney.
- b) A 34 hour urogram film showing gross left ureterohydronephrosis and a very long ureteric stricture. Non-opacified right kidney.
- c) Plain film 1 year after right ureteric re-implantation and left ureteric replacement with ileum. All the calculi have been eliminated.
- d) A 5 hour urogram film outlining the left kidney and ileal ureter. The right kidney remains non-functional.

A plain X-ray may show bladder wall calcification (Figure 1a), but this per se does not affect bladder function.

- **Bladder neck stenosis** is a result of muscle destruction, fibrosis of the trigone and infestation of the proximal urethra¹⁰. If it occurs, it is treated by endoscopic incision of the bladder neck.
- **The contracted bilharzial bladder** is the outcome of severe and prolonged infection¹¹. Cystoscopic evaluation under a general anaesthetic will show the reduced bladder capacity. Surgery is indicated when the bladder capacity is less than 100 millilitres; the procedure of choice being augmentation cystoplasty with ileum.
- **Detrusor failure** with atony or hypotonia may occur as a result of bladder muscle destruction and replacement with fibrosis¹⁰. In some cases, notably women, varying degrees of urine retention occur. Treatment is with suprapubic pressure at voiding, urethral catheterization for a while then trial voiding without a catheter, and clean intermittent self-catheterization for persistent retention.

Bladder Calculi.

Since secondary bacterial infection is common in bladder schistosomiasis, stones can develop as a result of infection by specific organisms that secrete the enzyme urease¹². The consequent hydrolysis of urinary urea produces ammonia. The presence of ammonium ions and high pH induce the production of stones containing calcium, magnesium, and ammonium sulphate. Stones produced by urea-splitting organisms are often very large (Figure 1). There is usually no associated bladder outflow obstruction. Treatment is by endoscopic cystolitholapaxy or open vesicolithotomy.

Carcinoma of the bilharzial bladder.

Bladder carcinogenesis is probably related to bacterial and viral infections, commonly associated with bilharzial infestation, rather than

the parasite itself¹³. Urinary bacteria have a double action, namely (i) secretion of β -glucuronidase enzyme which may clear conjugated carcinogens, yielding free carcinogenic products, (ii) the production of carcinogenic nitrosamines from their precursors in urine, such as nitrates and secondary amines¹⁴. Local mechanical irritation by *Schistosoma* eggs appears to be an important promoting factor¹³. Two thirds of the cancers show squamous cell differentiation^{15, 16}. This tumour is of high grade, invasive and more aggressive than transitional cell carcinoma.

Most patients present for treatment at an advanced stage. The explanation for the late presentation may be the overlapping of symptoms of simple bilharzial cystitis with early malignant cystitis¹³.

The diagnosis depends on cystoscopy, biopsy and careful bimanual examination under anaesthesia¹³.

Treatment

- **Endoscopic resection.** In view of the bulk and advanced stage of these tumours, transurethral resection is not feasible for definitive treatment. Endoscopic resection is currently limited to obtaining biopsy material for histopathological diagnosis and evaluation².
- **Segmental resection.** Local resection is only feasible if the tumour is solitary, does not involve the trigone, its size allows excision with adequate safety margin, and the rest of the bladder is free of any associated precancerous lesion. Few patients with carcinoma satisfy these criteria².
- **Radical cystectomy.** In view of the pathology and natural history of the disease, radical cystectomy and some form of urinary diversion provides the logical surgical approach to most cases with resectable tumours¹⁶. The extent of the excision includes the bladder with its perivesical fat, peritoneal covering, prostate, the seminal vesicles, together with the distal common iliac, internal iliac and external iliac lymph nodes. In the female, bladder resection includes the urethra, uterus and the upper two thirds of

the vagina, with pelvic cellular tissue and the aforementioned lymph nodes².

- **Radiation therapy.** Experience with external beam radiation therapy showed disappointing results. Preoperative radiotherapy before radical cystectomy did not make any difference compared to radical cystectomy alone².
- **Chemotherapy.** Adjuvant chemotherapy where the drug is given after radical cystectomy to reduce local or systemic recurrence has been tried with epirubicin. Neoadjuvant chemotherapy where the drug is given first before radical cystectomy in an attempt to reduce the tumour size to allow safer resection has been tried with the same agent. Both have produced inconclusive results¹³. Induction chemotherapy, where this mode of treatment is used alone for advanced disease, produced poor results.

The Urethra and Genital Tracts

Occasionally bilharzia affects the bulbous urethra and may result in peri-urethral abscesses, fistulae or stricture formation². Bilharzial seminal vesiculitis may result in haemospermia, painful ejaculation and low back pain, just as may bilharzial prostatitis. Plain x-ray may show calcification in the seminal vesicles with a honeycomb appearance. Infestation of these organs has no effect on fertility².

Schistosoma haematobium has been found in the cervix, vagina and vulva. There is an increased incidence of infertility in this group¹.

Prevention and Control

Prevention of *Schistosoma haematobium* infestation¹ can be achieved by:

- (i) Reduction in the number of eggs excreted from infected people reaching water, which harbours the intermediate snail hosts. It depends on health education, provision and use of adequate sanitary facilities, and specific antischistosomal chemotherapy for infected individuals and communities.
- (ii) Reduction of miracidial-snail contact, by reduction in snail numbers using chemical

molluscicides or use of suitable biological control methods.

- (iii) Reduction in the longevity of the adult worms in the host; a function of antischistosomal chemotherapy.

Conclusion

Bilharzia can be controlled by simple measures, which with determination, can be effected by the community and the Government. It is the hope of the authors that this will be achieved and even result in the eradication of this parasite in our continent of Africa and thus consign this publication to the archives of surgery.

Acknowledgement

We are sincerely grateful to Jason Mwawana for the computer work.

References

1. Davis A. Schistosomiasis. In: *Manson's Tropical Diseases*. Cook G. (Ed) 20th Edn. W.B. Saunders .1996: 1413 –1456.
2. Ghoneim M.A. Bilharziasis of the genitourinary tract. *B.J.U. International*. 2002; 89(Suppl.1):22-30.
3. Husain I. Schistosomiasis of the urinary tract. In: *Oxford Textbook of Surgery*. Morris P.J., Malt R.A. (Eds). Oxford University Press .1994:2523-2528.
4. Smith J.H., Kamel I.A., Elwi A., von Lichtenberg F. A quantitative postmortem analysis of urinary schistosomiasis in Egypt. *Am. J. Trop. Med. Hyg.*1974; 23:1054 – 1071.
5. Ghoneim M.A., Ashamalla A., Abdel-Khalik M. Bilharzial strictures of the ureter presenting with anuria. *Br. J. Urol*. 1971; 43: 439 – 443.
6. Ghoneim M.A., Nabeeh A., El – Kappany A. Endourologic treatment of ureteral strictures. *J. Endourol*. 1988; 2: 267 – 270.
7. Eshleman J.L. Helminthic infections of the urinary tract; Schistosomiasis. In: *A Textbook of Urology and Nephrology in*

-
- Africa*. Eshleman JL (Ed). Eshleman J.L. (Publisher). 1999: 163 – 172.
8. Shokeir A.A., Gaballah M.A., Ashamalla A.A., Ghoneim M.A. Optimisation of replacement of the ureter by ileum. *J. Urol*. 1991; 146: 306 – 310.
 9. Farid Z, Miner W.F., Higashi G.I., Hassan A. Reversibility of lesions in schistosomiasis: a brief review. *J. Trop. Med. Hygiene*. 1976; 79:161-166.
 10. Koraitim M. A new concept of bilharzial bladder neck obstruction: the triple mechanism. *J. Urol* .1973; 109: 393 – 396.
 11. Sayesh E.S., Dimmette R.M. The fibrotic contracted urinary bladder associated with schistosomiasis and chronic ulceration. *J. Urol*. 1956; 75:671-679.
 12. Bishop M.C. Urinary tract infection and prostatitis. *Surgery International*. 2002; 59:264-267.
 13. Shokeir A.A. Squamous cell carcinoma of the bladder: pathology, diagnosis and treatment. *B.J.U. International*. 2004; 93:216-220.
 14. Hicks R.M., Ismael M.M., Walters C.L., Beecham P.T., Rabie M.F., El Alamy M.A. Association of bacteriuria and urinary nitrosamine formation with *Schistosoma haematobium* infection in the Qalyub area of Egypt. *Trans. R. Soc. Trop.Med. Hyg.*1982; 76:519 –528.
 15. Lucas S.B. Squamous cell carcinoma of the bladder and schistosomiasis. *East Africa Med. J.* 1982; 59: 345 – 351.
 16. El-Bolkainy N.M., Ghoneim M.A., Mansoura M.A. Carcinoma of the bilharzial bladder in Egypt. Clinical and pathological features. *Br. J. Urol*. 1972; 44:561 – 570.