

<http://www.bioline.org.br/js>

Cystic Medulloblastoma in a child

A. Agrawal¹, A. Agrawal², D.N. Balpande³, C.S. Pathak³

¹Associate Professor in Neurosurgery, ²Associate Professor in Pathology, ³Professor in Pediatrics, Datta Meghe Institute of Medical Sciences, Sawangi (Meghe), Wardha (India)

Correspondence to: Dr Amit Agrawal, Fax: +91-7152-2231902. Email: <dramitagrawal@gmail.com>

Introduction

Medulloblastoma is a commonly encountered, highly malignant posterior fossa midline cerebellar tumour of children, with a tendency to early recurrence and dissemination through the cerebrospinal fluid¹⁻⁸. On computed tomography, majority of the medulloblastomas have a typical appearance, consisting of a mass of uniformly increased density that enhances homogeneously after contrast enhancement with sharp demarcation of the neoplasm and there may be associated hydrocephalus²⁻⁸.

Case Report

This 14 year male child presented with headache, vomiting and swaying while walking to either side of 1 month duration and loss of vision of 15 days duration. On examination, the child was conscious and well oriented. He had bilateral papilloedema. There was no perception of light or projection of rays in both the eyes. Eye movements were normal and he had bilateral cerebellar signs. There were no other neurological deficits. CT scan (Figure-1) showed a mass in the midline of the posterior fossa, comprising a solid isodense component on the right and a cystic hypodense component on the left, having a density slightly higher than cerebrospinal fluid. There was diffuse enhancement of the solid component. The fourth ventricle was compressed and displaced anteriorly and to the right with associated hydrocephalus.

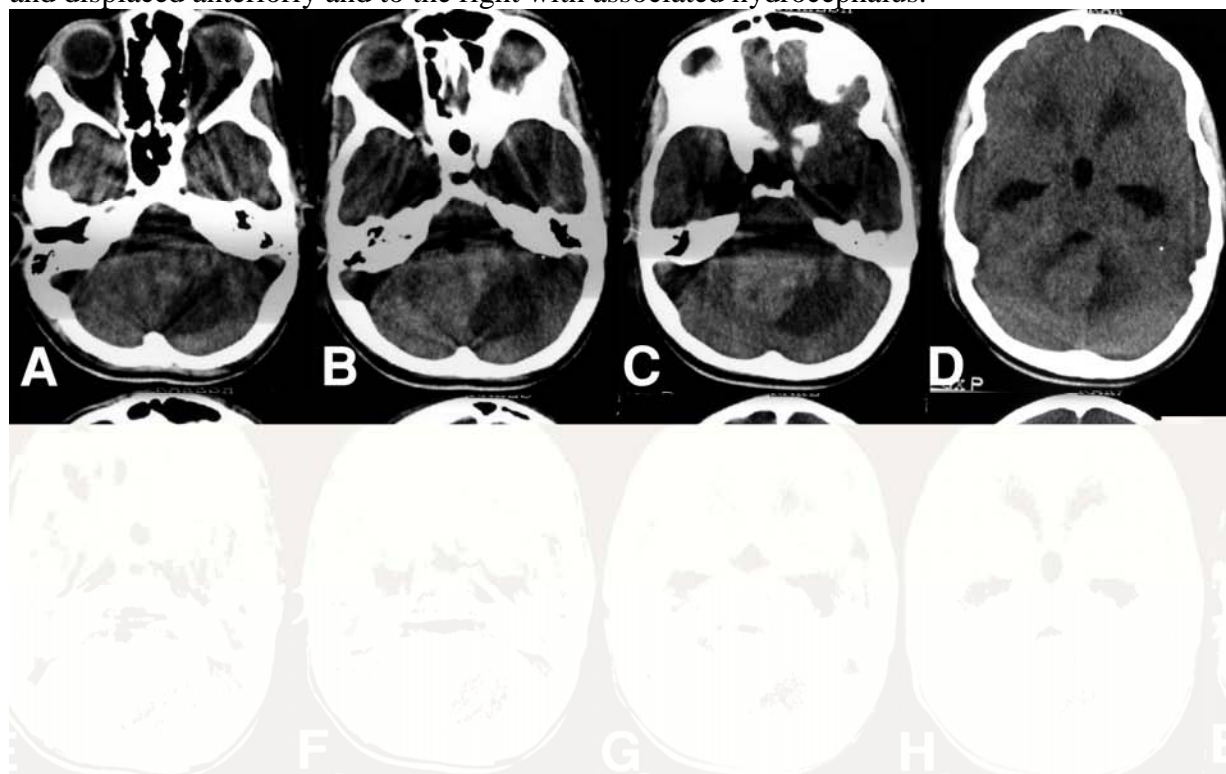


Figure 1. Plain CT scan showing a midline posterior fossa mass with a high-density area on the left and a low-density area on the right (A-D), the solid component showed marked homogeneous enhancement after contrast administration (E-H)

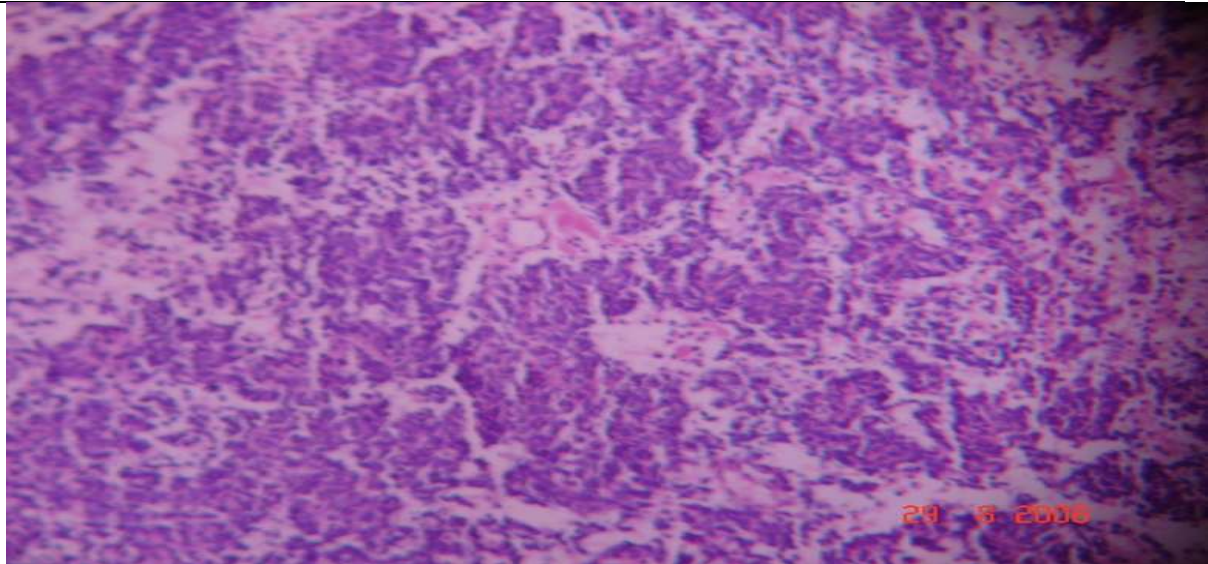


Figure 2. Histopathological examination showed highly undifferentiated areas composed of cells with small hyperchromatic nuclei and inconspicuous cytoplasm (H & E 40x)

The child underwent midline suboccipital craniectomy, vermis was split, there was a big cyst containing xanthochromic fluid that was evacuated and the bulk of the grayish, soft friable, highly vascular tumor was resected. Histopathological examination showed the tumor cells with poor cytoplasm, oval nuclei and formed Homer Wright rosettes (Figure-2). A diagnosis of cerebellar medulloblastoma was made. Following surgery he improved in his headache, vomiting and cerebellar signs but there was no improvement in his vision. He was subjected to cranio spinal irradiation and is on regular follow up with no fresh symptoms.

Discussion

Up to 47% patients of medulloblastoma can have atypical features on CT scan⁵ and these include cystic or necrotic component, calcification, hemorrhage, lack of contrast enhancement, eccentric location, rarely direct transtentorial extension^{5,9}. Cystic or necrotic component is less common in children than in adults^{5,10-12}. Presence of these atypical features on CT scan can make it difficult to differentiate a medulloblastoma from other posterior fossa tumors i.e. ependymoma and astrocytoma in children⁵. In a child is who have a central well-marginated tumor which exhibits uniformly increased density on pre-contrast scans and homogeneous contrast enhancement there is 85-90% likelihood it to be a medulloblastoma,⁵ however the presence of atypical features on CT scan in the first decade of life should not be considered against the diagnosis of medulloblastoma.^{5,9}

References

1. Giordana MT, Schiffer P, Schiffer D. Prognostic factors in medulloblastoma. *Childs Nerv Syst.* 1998;14(6):256-62.
2. Naidich TP, Lin JP, Leeds NE, Pudlowski RM, Naidich JB. Primary tumors and other masses of the cerebellum and fourth ventricle: differential diagnosis by computed tomography. *Neuroradiology* 1977; 14: 153- 174.
3. Zimmerman RA, Bilaniuk LT, Pahlajani H. Spectrum of medulloblastomas demonstrated by computed tomography. *Radiology* 1978; 126:137-141.
4. Probst FP, Liliequist B. Assessment of posterior fossa tumors in infants and children by means of computed tomography. *Neuroradiology* 1979; 18:9-18.
5. Zee CS, Segall HD, Miller C et al Less common CT features of medulloblastoma. *Radiology* 1982; 144 : 97-102.

6. Maleci A, Cervoni L, Delfini R. Medulloblastoma in children and in adults: a comparative study. *Acta Neurochir* 1992; 119:62-67.
7. Haie-Meder C, Song PY. Medulloblastoma: differences in adults and children: regarding Frost et al., *IJROBP* 32:951-957; 1995 and Prados et al., *IJROBP* 32:1145-1152; 1995. *Int J Radiation Oncology Biol Phys* 1995;32:1255-1257.
8. Tortori-Donati P, Fondelli MP, Rossi A, et al. Medulloblastoma in children: CT and MRI findings. *Neuroradiology* 1996;38:352-359
9. Hubbard JL, Scheithauer BW, Kispert DB, et al. Adult cerebellar medulloblastomas: the pathological, radiographic, and clinical disease spectrum. *J Neurosurg* 1989;70:536-544.
10. Kingsley DPE, Kendall BE. The CT scanner in posterior fossa tumors of childhood. *Br J Radiol* 1979; 52:769-776.
11. Mahapatra AK, Paul HK, Sarkar C. Cystic medulloblastoma. *Neuroradiology*. 1989;31(4):369-70.
28. Bourgouin PM, Tampieri D, Grahovac SZ et al : CT and MRI imaging findings in adults with cerebellar medulloblastoma : Comparison with findings in children. *Am Jr Roentgen* 1992; 159: 609-612.