

Carpal Tunnel Syndrome in Patient on long Term Hemodialysis - a Case Report

S. A. Salati¹, N.F. Aldajani¹, B. Al Aithan², S.M. Rabah¹.

¹King Fahad Medical City, Riyadh, Saudi Arabia

²Military Hospital, Riyadh, Saudi Arabia

Correspondence: Dr Sajad Ahmad Salati, Email: docsajad@yahoo.co.in, docsajad@gmail.com

Pain in hands is a common complaint in patients of end-stage renal disease on long term hemodialysis. This pain can arise from various different etiological factors. We present one such case of 56 years old lady who suffered from pain in the hand due to carpal tunnel syndrome on the side with angioaccess. Carpal tunnel was released by open surgical technique resulting in symptomatic relief of the patient.

Introduction

Complaints related to hand are not uncommon in patients of end stage renal disease on long term hemodialysis¹ and need proper work and evaluation so that relief can be provided to these otherwise chronically ailing patients. These symptoms may represent complications of angioaccess² or may be related to other common diseases. Carpal tunnel syndrome is the commonest compression neuropathy leading to painful hands³ and need early detection and management to bring about symptomatic relief and prevent disabilities.

Case presentation

A 56 years old female reported with pain and abnormal sensations (numbness/tingling) in her left hand of three years duration. The patient was a known case of diabetes, hypertension and end-stage renal disease on regular hemodialysis and had functioning Cimino-Brescia fistula (for angioaccess) on the affected side since 17 years. The patient used to experience increase in pain and paresthesias after dialysis or routine work and after sleeping for a few hours. The patient had been receiving analgesics and was using a volar splint to immobilize the wrist but without satisfactory relief. One examination, the patient had features suggestive of carpal tunnel syndrome with positive Tinel's, Dercum's and Phalen's tests. Two-point discrimination was 16-17mm but there was no motor deficit. There was no atrophy of hand muscles and color and capillary return was within normal limits and comparable to opposite hand. There was no other neurodeficits on general physical examination.

Electrophysiological studies were conducted in both upper extremities (Figure 1). The left median sensory potentials were not obtained on stimulation proximal to the wrist. The left median motor distal latency was significantly prolonged (6.75 ms at left wrist as compared to 4.5ms over right wrist). In addition, the left median motor compound muscle action potential (CMAP), left median motor and sensory conduction velocities were decreased (sensory peak amplitude of 1.7uV over left palm as compared to 58.5 uV on right side and motor peak amplitude of 2.1mV over left wrist as compared to 4.3 mV on right side). These electrophysiological studies were interpreted as evidence for a severe degree of left Median Neuropathy at the wrist.

The patient was operated upon under local anesthesia and open release of carpal tunnel was done. One day prior to operation, the patient was had session of hemodialysis. Per-operatively the transverse carpal ligament was found to be compressing the median nerve along the whole extent of carpal tunnel. No other pathological lesion was found. The patient had an uneventful postoperative phase. At six months follow-up, the patient was pain free but still had paresthesias although of lesser intensity.

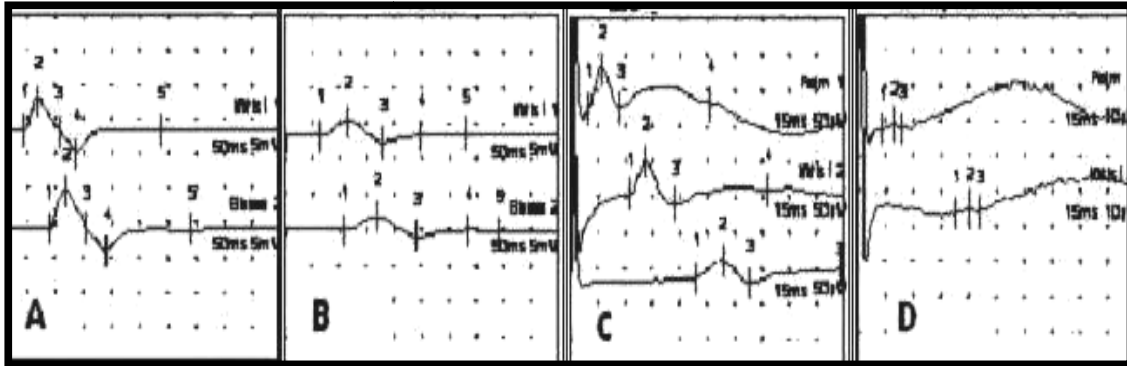


Figure 1. Nerve Conduction Studies - (A) Motor NCS of right median nerve over right abductor pollicis brevis (B) Motor NCS of left median nerve over left abductor pollicis brevis (C) Sensory NCS of right median nerve over right index finger (D) Sensory NCS of left median nerve over left index finger

Discussion

Symptoms related to hand are common in cases of end-stage renal disease on maintenance hemodialysis¹. These symptoms can arise from complications of angioaccess² which include steal syndrome and ischemic monomelic neuropathy or else the patient may be suffering from other usual diseases prevalent in general population, the carpal tunnel syndrome (CTS) being one such condition when either one or both of the hands could be symptomatic. Our case suffered from carpal tunnel syndrome on the side with Cimino-Brescia fistula.

Warren and Oriento³ in 1975 were the first to report the development of carpal tunnel syndrome in patients on chronic dialysis and since then, multiple studies have been published on this subject. The incidence of carpal tunnel syndrome in patients having dialysis is difficult to assess, and depends on the criteria for diagnosis, be it by EMG or by clinical assessment⁴. Scardapane et al reported in 1979 that the incidence of EMG evidence of nerve entrapment rises with an increase of time on dialysis and 50% of their patients who had been on dialysis for over five years had EMG evidence of carpal tunnel syndrome⁴. Al-Homrany et al also found statistically significant positive correlation ($P = 0.039$) between the finding of abnormal EMG suggesting CTS and the duration on dialysis, with increasing prevalence observed in patients treated for more than 5 years⁵.

Carpal tunnel syndrome (CTS) is the most common peripheral entrapment disorder, and results from compression of the median nerve at the wrist where it courses deep to transverse carpal ligament. This condition was initially described by James Jackson Putnam in 1880 and later on medical luminaries like Paget, Marie, Ramsay Hunt, Phalen and Osler contributed to our understanding of the syndrome⁶. The usual symptoms include numbness, paresthesias, and pain in the median nerve distribution, with nocturnal exacerbation. These symptoms may or may not be accompanied by objective changes in sensation and strength of median-innervated muscles in the hand. Some patients can report with features secondary to autonomic nerve fiber involvement (the median nerve carries most autonomic fibers to the whole hand) including sensitivity to changes in temperature (particularly cold), a difference in skin color or changes in sweating pattern of affected hand. Our patient had pain and paresthesias as presenting features.

As far as pathophysiology is concerned, it is now known that the median nerve is damaged within the rigid confines of the carpal tunnel, initially undergoing demyelization followed by axonal degeneration. Sensory fibers often are affected first, followed by motor and/or autonomic fibers. Though the precise cause of the damage to nerve is still uncertain; however, it seems likely that abnormally high carpal tunnel pressures in patients with CTS causes obstruction to venous outflow, back pressure, edema formation, and ultimately, ischemia in the nerve and subsequent manifestations.

Most cases are idiopathic, although the risk of development of CTS appears partly to be associated with a number of different epidemiologic factors, including genetic, medical, social, vocational and demographic⁷. In the patients on chronic hemodialysis (like the one we are presenting), the etiology is multifactorial, though multiple reports are found in literature which tend to establish the relation between CTS and long-term hemodialysis due to chronic renal failure^{8,9}. Amyloidosis due to beta 2-microglobulin deposition is recognized with increasing frequency in patients undergoing long-term hemodialysis and deposition of amyloid in carpal tunnel leading to median nerve compression is being projected as a possible cause of CTS in this subset of population. This amyloid deposition has been confirmed in studies by biopsy of transverse carpal ligament and median nerve^{9,10}. However since no material was retrieved by us during operation for histopathological analysis, we could not study this aspect in our case. Uremia leads to extracellular fluid retention which may cause raised pressure in the carpal tunnel. Besides peripheral neuropathy is common in chronic renal failure with its associated uremia which can present as painful hands. Both these effects of uremia can get worsened by the arteriovenous fistula used for dialysis. During dialysis both the venous pressure and the volume of the hand are increased distal to the fistula because of the venous engorgement and the patient can become symptomatic as was true of our patient who would feel significant increase in pain and paresthesias in her affected hand during her dialysis sessions⁴. Lesser common related factors for carpal tunnel syndrome in chronic renal failure include extensive uremic tumoral calcinosis that affecting the wrist¹¹ and acute thrombosis occurring in a persistent median artery¹².

Diagnosis of CTS is based on meticulous history, physical examination and electrophysiological studies. A constellation of bedside tests are mentioned in literature as aids to diagnosis¹³; the prominent ones include (a) Hoffmann-Tinel sign-gentle tapping over the median nerve in the carpal tunnel region elicits tingling in the nerve's distribution, (b) Phalen sign-tingling in the median nerve distribution is induced by full flexion (or full extension for reverse Phalen) of the wrists for up to 60 seconds, (c) Carpal compression test - this test involves applying firm pressure directly over the carpal tunnel, usually with the thumbs, for up to 30 seconds to reproduce symptoms (d) A positive flick sign - having to shake the hand for relief. Electro physiologic studies include electromyography (EMG) and nerve conduction studies (NCS) and are the first-line investigations in diagnosis of carpal tunnel syndrome (CTS). In addition, other neurologic diagnoses (like neuropathies due to uraemia, diabetes etc) can be excluded besides providing an accurate assessment of severity of damage to the nerve, thereby directing management and providing objective criteria for the determination of prognosis¹⁴. Carpal Tunnel Syndrome is usually divided into mild, moderate, and severe; patients with mild CTS have sensory abnormalities alone on electrophysiologic testing, and patients with sensory plus motor abnormalities have moderate CTS. Patients with any evidence of axonal loss (e.g., decreased or absent sensory or motor responses distal to the carpal tunnel or neuropathic abnormalities on needle EMG) are classified as severe CTS. Radiologic imaging methods are infrequently used, particularly in cases with features of predominantly unilateral median nerve compression to rule out any space occupying lesion in the carpal tunnel. MRI has consistently shown the greatest sensitivity and specificity in the regard though in the hands of experienced operators, high frequency ultrasound may be equally useful.

Management in mild to moderate cases is conservative and comprises of use of nocturnal wrist-hand orthosis (splints) maintaining the wrist joint in neutral position. Non steroidal anti inflammatory drugs (NSAIDS) and steroids may be of benefit. Patients of severe carpal tunnel syndrome or the ones not responding to conservative therapy over 3-4 weeks are treated by surgical release of carpal tunnel. However before undertaking surgery, the patient needs to be fully informed about complications which include failure of recovery of neurodeficits, scar tenderness, pillar pain, and neuroma formation¹⁵. Our patient had persistent paresthesias even at six months follow-up but did not develop any other complication and was satisfied with the outcome of carpal tunnel release.

Conclusion

It is stressed that carpal tunnel syndrome be ruled out early in every case of end stage renal disease presenting with complaints related to hand to prevent serious neurodeficits and disabilities.

Furthermore it is emphasized that neurophysiological studies are utilized for detection of early cases of carpal tunnel syndrome.

References

1. Carroll LL, Tzamaloukas AH, Seremin AE, Ecsenberg B. Hand symptoms in patients on chronic dialysis. *Int J Artif Organs* 1993; 16:694-9
2. Haimov M, Schanzer H, Skladani M. Pathogenesis and management of upper-extremity ischemia following angioaccess surgery. *Blood Purif* 1996; 14(5):350-4
3. Warren DJ, Otieno IS. Carpal tunnel syndrome in patients on intermittent haemodialysis. *Postgrad Med J* 1975; 51:450-2.
4. Bradish C F. Carpal tunnel syndrome in patients on haemodialysis. *J Bone Joint Surg* 1985; 67B (1):130-132
5. Al-Homrany MA, Khan MH, Adzaku F, Harding MG. Carpal tunnel syndrome in haemodialysis patients: early detection by electroneurophysiological studies. *Nephrology* 2001; 6 (6): 259-262
6. Sternbach G. The carpal tunnel syndrome. *J Emerg Med* 1999; 17(3):519-23
7. de Krom MC, Kester AD, Knipschild PG, *et al.* Risk factors for carpal tunnel syndrome. *Am J Epidemiol* 1990; 132(6):1102-10
8. Jose L. Zamora, James E. Rose, Vidal Rosario *et al.* Hemodialysis associated carpal tunnel syndrome -A clinical review. *Nephron* 1985; 41:70-74
9. Kimura I, Sekino H, Ayyar D. Carpal tunnel syndrome in patients on long-term hemodialysis. *Tohoku J Exp Med* 1986; 148(3):257-66
10. Chung YJ, Choi KC, Ha JH, *et al.* A case of carpal tunnel syndrome due to dialysis-related amyloidosis in a patient undergoing long-term hemodialysis. *Korean J Intern Med* 1997; 12(1):75-9
11. Cofan F, Garcia S, Combalia A, Segur JM, Oppenheimer F. Carpal tunnel syndrome secondary to uraemic tumoral calcinosis. *Rheumatology* 2002; 41:701-703
12. Rose RE .Acute carpal tunnel syndrome secondary to thrombosis of a persistent median artery. *West Indian Med J* 1995; 44(1):32-3
13. D'Arcy CA, McGee S. The rational clinical examination. Does this patient have carpal tunnel syndrome? *JAMA* 2000; 283(23):3110-7
14. Robinson LR. Electro diagnosis of carpal tunnel syndrome. *Phys Med Rehabil Clin N Am* 2007; 18(4):733-46
15. Boya H, Ozcan O, Oztekin HH. Long-term complications of open carpal tunnel release. *Muscle Nerve* 2008; 38(5):1443-6