

Intranasal Endoscopic Repair of Bilateral Choanal Atresia in a Male Newborn with Crouzon's Syndrome

A.D. Dunmade¹, I.O. Ajayi¹, B.S. Alabi¹, O.A. Mokuolu², B.O. Bolaji³, O.I. Oyinloye⁴

¹Department of Otorhinolaryngology, University of Ilorin Teaching Hospital, Ilorin, Nigeria.

²Department of Paediatrics, College of Health Sciences, University of Ilorin,

³Department of Anaesthesia, College of Health Sciences, University of Ilorin, Ilorin, Nigeria.

⁴Department of Radiology, College of Health Sciences, University of Ilorin, Ilorin, Nigeria.

Corresponding to: Ajayi IO, Email: drlanreajayi@gmail.com

Bilateral choanal atresia is a rare developmental problem in which there is narrowing of the posterior nasal aperture. Commoner in female newborns, it is usually associated with respiratory distress and cyanosis. We present a 30hr old male child with respiratory distress and intermittent cyanosis at birth. On examination patency was not demonstrable in both nasal cavities on insertion of nasal catheter. Low-dose CT scan demonstrated bilateral choanal atresia. Patient had intranasal endoscopic repair of atresia and nasal stenting. Child was discharged after 4weeks and was followed up for 5months.

Introduction

Congenital bilateral choanal atresia, a rare neonatal emergency, is a developmental abnormality in which there is narrowing of posterior nasal aperture occurring in 1 in 7000 to 10000 births^{1,2}. Commoner in female newborns than their male counterparts, it is frequently unilateral and more often affects right side than left side³. It can be bony or membranous or mixed. Frequently associated anomaly is CHARGE Syndrome (Coloboma, Heart disease, choanal Atresia, mental and growth Retardation, Genital hypoplasia, Ear deformities). Other associated anomalies include Treacher Collins Syndrome, Down's syndrome and Crouzon's syndrome among others⁴. Patients often present with respiratory distress, cyanosis and difficulty with feeding. If emergency measure is not taken urgently, it may result in death⁵.

We present a male neonate with bilateral choanal atresia, who had transnasal repair using an endoscope, powered microdebrider and nasal stenting within 72hrs of life.

Case presentation

This was a 2.6 kg full term male neonate with Apgar scores of 7/1 and 9/5 was delivered by emergency caesarean section on account of eclampsia in his primiparous mother. He presented with respiratory difficulty and occasional cyanosis that improved with cry immediately after delivery. Attempt at suctioning mucous secretion from the nasal cavities met with resistance that necessitated transferring child to Neonatal Intensive Care Unit (NICU) with SPO₂ of 84%.

On examination, the child was in respiratory distress evidenced by tachypnoea (55 breaths/min), intercostal and sternal recessions, and occasional cyanosis. He had

microcephaly, hypertelorism, bilateral proptosis, low set ears, micrognathia, microglossia and flat face. Body temperature was 36.7° Celsius.

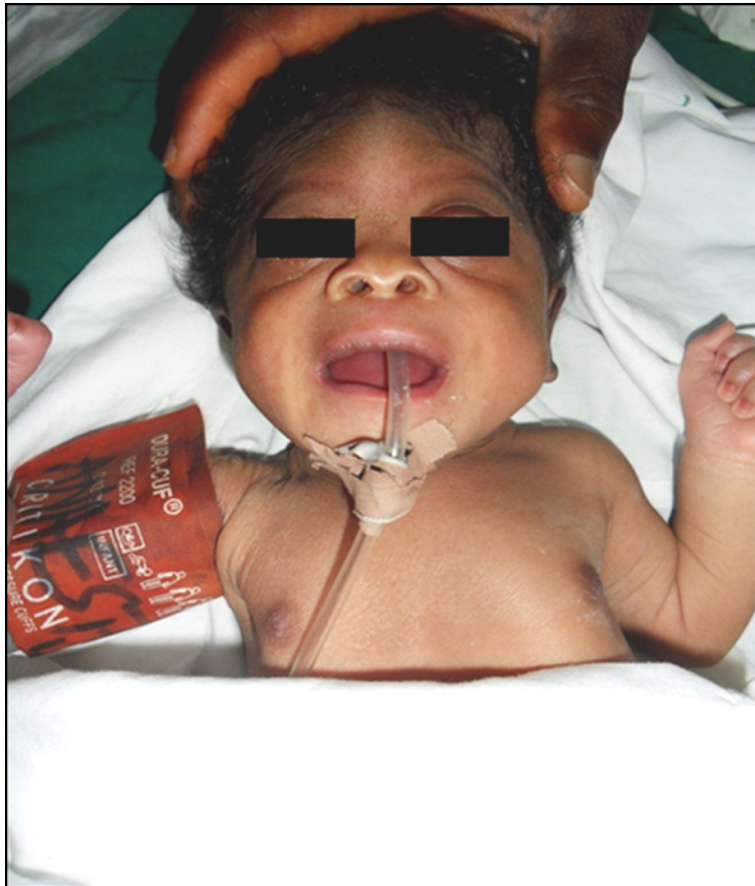

Figure 1. Photograph of the baby showing orogastric tube in-situ to keep the oropharynx patent for airway

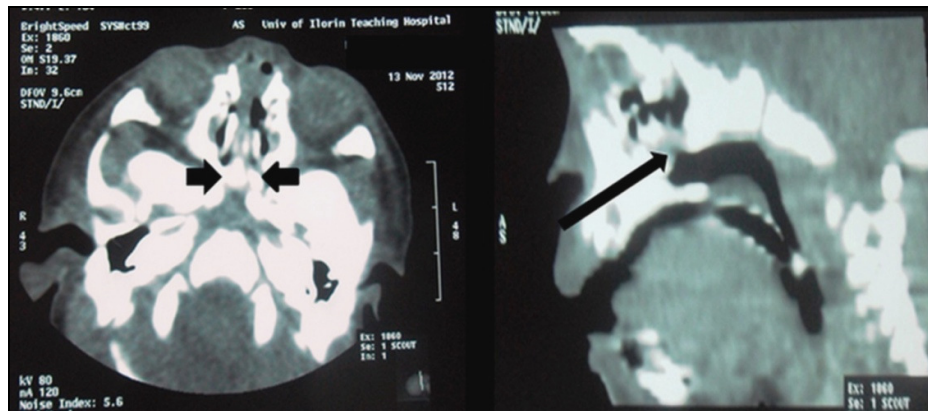


Figure 2. CT scan demonstrating bilateral choanal atresia (short arrowed) and left mixed type (long arrowed)

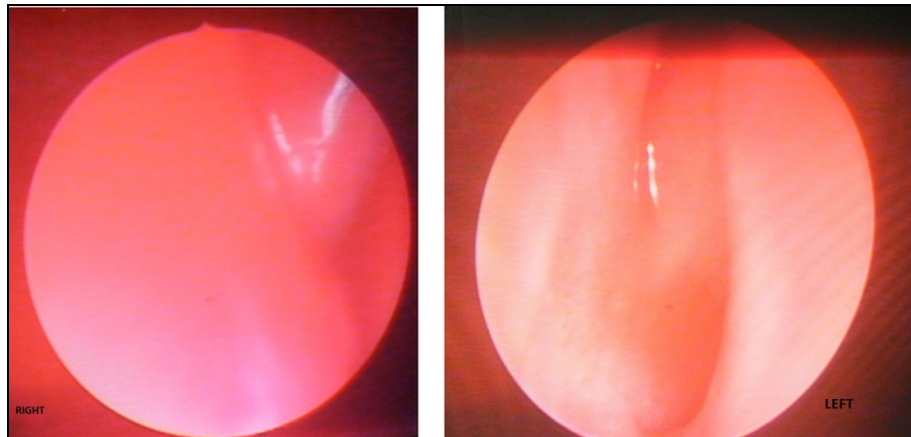


Figure 3. Nasoendoscopic view of right and left posterior choanae atresia

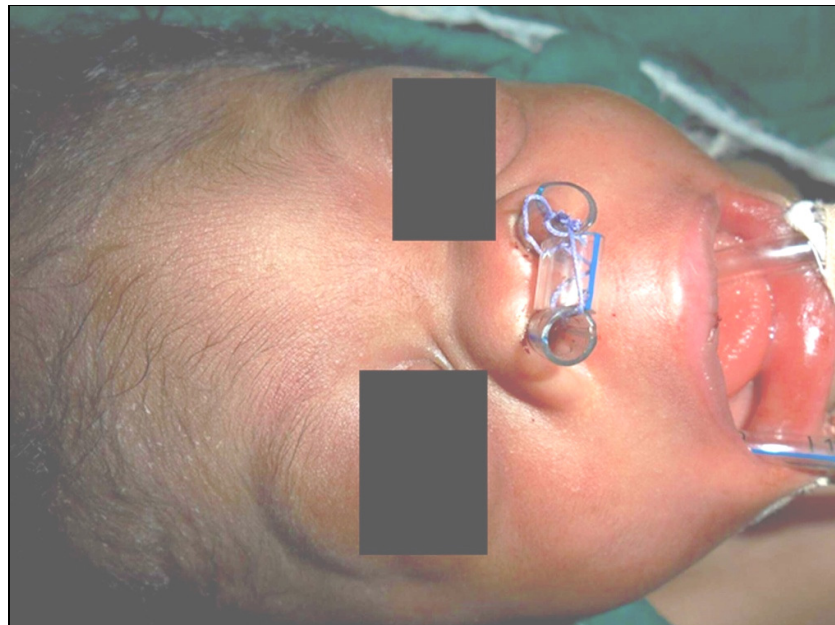

Figure4. Photograph showing nasal stent in-situ after repair

Nasal examination revealed flat nasal bridge. No patency was demonstrable bilaterally. Using nasal catheter FR 6, patency test revealed obstruction to passage at 2cm on the right and at 2.7cm on the left from the nares, thereby making suspicion of bilateral choanal atresia (BCA) very high. Nasal endoscopic examination was however deferred till the baby was relaxed under general anaesthesia. The heart sounds were normal with no murmurs and the heart rate was 120/min. Other systemic examinations revealed hypoplastic penis but essentially normal abdominal findings.

Immediate measure taken at presentation was inserting an oro-gastric tube to keep the child breathing through the mouth and for feeding (Figure 1). Supplemental oxygen via facemask, prophylactic antibiotics and intravenous fluid were also given. At 48 hours into admission the child had confirmatory low-dose radiation CT scan of the nose and paranasal sinuses using a low dose technique of 50ma, the child abdomen, genitals and

limbs were also wrapped in protective lead apron. The CT demonstrated thickening of the bony vomer causing complete obstruction of the right nasal cavity and bony narrowing of the left nasal cavity with membranous central portion (Figure 2). Echocardiography revealed normal study. Other ancillary investigations were essentially normal.

At 68 hours of admission, patient was scheduled for intranasal endoscopic surgical correction of the bilateral choanal atresia under endotracheal general anaesthesia. Intra-operative endoscopic findings using Hopkins' rod (0 and 30 degrees, 2.7mm by Karl Storz, GmbH, Germany) included complete bony right choanal atresia and mixed (bony and membranous) left choanal atresia (Figure 3). Using powered microdebrider, a gentle transnasal puncture of the atretic plate was performed. In addition to using the angulated debrider tip, at each step of puncturing the atretic plate, care was taken to maintain surgical principle by keeping the use of angled microdebrider tip to the nasal floor plane in order not to accidentally enter the sphenoid. The nasopharynx was constantly visualized with 30 degree telescope to ensure safe puncture of the atretic plate at each step. After puncturing the plate with debrider tip, Watson-William rasp size 2 was then used to widen and smoothen the raw edges of the posterior choanae. A 3.0mm cut-to-size endotracheal tube was thereafter inserted bilaterally to stent the repaired choanae. The anterior ends of the stents were sutured to a tube brace and columella using vicryl size 3/0 suture (Figure 4). The patient was continued on antibiotics and oro-gastric tube for feeding throughout the time the stent was in situ. The intranasal stent was removed after 4 weeks.

The patient was subsequently discharged thereafter in stable clinical condition without nasal obstruction or mouth-breathing. No complication was recorded in our patient. There was no symptomatic or clinical evidence of restenosis throughout the period child was followed up at our out-patient clinic. Plan was made to repeat nasendoscopy at 6 month post-operative. He was however lost to follow up after 5 months due to undisclosed reasons from the parents when contacted on phone despite giving their informed consent to this report.

Differential diagnosis

Congenital nasal piriform aperture stenosis (CNPAS) may mimic BCA⁶. But as the name implies, CNPAS is a problem with stenosis and not atresia. Distinction is made on CT scan finding. Other differentials include congenital bilateral dacrocystocoele, deviated nasal septum, encephalocele, and nasal dermoid⁷.

Discussion

Bilateral choanal atresia is a rare developmental problem in which there is failure of complete canalization of the nasal cavities due to persistent buconasal (or nasobuccal) membrane of Hochstetter⁸. During the fourth week of intra-uterine life, the nasal placodes deepen to lie between the medial and lateral nasal processes. The medial processes also fuse to form the frontonasal process which compressed to form the nasal septum as the lateral nasal processes approach each other. The nasal septum then grows posteriorly to divide the two nasal cavities. Each nasal cavity is closed posteriorly

by bucconasal membrane (a thinned out posterior wall of the nasal sac). This is expected to break down sixth week in utero. Its persistence is thought to be the cause of choanal atresia. Bilateral choanal atresia constitutes 40-45% of congenital choanal atresia which is commoner in females with male to female ratio ranging from 1:2 to 1:5⁹. Clinical symptoms are present at birth and could be a cause undiagnosed neonatal death. Those with delayed diagnosis later in life have been reported in literatures^{10,11}. BCA is classified into bony (90%), membranous (6%) or mixed (4%) types⁴.

Our patient was a male with bilateral mixed type. Choanal atresia is often associated with other anomalies like CHARGE, but our patient presented with suspected Crouzon syndrome evidenced by craniosynostosis and hypoplastic face. No cardiac anomalies or musculoskeletal lesion were however seen in our patient. Choanal atresia presentation (especially when bilateral) often includes difficulty with breathing, cyclical cyanosis and difficulty with feeding which were the cardinal symptoms in this reported case¹². Because neonates are obligate nasal breathers, they tend to develop respiratory distress that may result in even death. High index of suspicion is needed to make prompt diagnosis. In this reported case, diagnosis was made within 30 minutes of birth. An attempt to suction the patient's nose at birth which met with resistance made the attending resident doctor to suspect choanal atresia. If child had been delivered outside the hospital setting, higher chances are there to lose this patient to neonatal death due to missed diagnosis. Misting of metallic spatula and cotton wool wick can also be used to demonstrate nasal patency at birth. Computed tomographic scan would differentiate the bony from the membranous types, estimate the thickness and identify other bony anomalies like congenital ethmoidal osteoma¹².

Our reported case had low-dose radiation CT scan to minimize exposure to ionizing irradiation. Low dose (50 ma) scans of the paranasal sinuses in thin axial cuts using the multislice technique with reconstruction in sagittal plane demonstrated the choanal atresia in this reported case. The low-dose technique does not affect the measurement accuracy of choanal atresia¹³. Various surgical techniques have been used to correct choanal atresia. These include the trans-palatal approach, the trans-septal approach, the endoscopic transnasal approach, advanced drill technology and use of LASER. From review of literatures, intranasal approach has been adjudged the route of choice⁹. We explored endoscopic intranasal approach for the patient similar to advanced drill technology reported by Vickery and Gross using powered microdebrider¹⁴. Direct visualization of the atretic plate adds value to surgical technique and ultimately its outcome thereby minimizing complications and less bleeding. Various factors have been identified as indices to successful repair and low restenosis incidences⁹. The combination of drilling with curettage, use of a rigid instead of a soft stent, and use of antibiotics throughout the period stent was in situ added to the success recorded in our reported case.

Conclusion

Bilateral congenital atresia in a male with crouzon's syndrome is uncommon. A high index of suspicion is needed to diagnose this neonatal emergency early in order to prevent death. Endoscopic intranasal puncture of atretic plate with powered microdebrider and stenting within 72 hours of life offers a good surgical outcome with less complication.

References

1. Gujrathi CS, Daniel SJ, James AL, et al. Management of bilateral choanal atresia in the neonate: an institutional review. *Int J Pediatr Otorhinolaryngol* 2004; 68(4):399-407.
2. Theogaraj SD, Hoehn JG, Hagan KF. Practical management of congenital choanal atresia. *Plast Reconstr Surg* 1983; 72: 634-42.
3. Samadi DS, Shah UK, Handler SD. Choanal atresia: a twenty-year review of medical comorbidities and surgical outcomes. *Laryngoscope* 2003;113(2):254-258.
4. Bergstrom L, Owens O. Posterior choanal atresia: a syndromal disorder. *Laryngoscope* 1984; 94:1273-6.
5. Saleem AF, Ariff S, Aslam N, et al. Congenital bilateral choanal atresia. *J Pak Med Assoc* 2010; 60(10):869-72.
5. Saleem AF, Ariff S, Aslam N, et al. Congenital bilateral choanal atresia. *J Pak Med Assoc* 2010; 60(10):869-72.
6. John EN, Mbam TT, Nimkur LT, et al. Synchronous congenital nasal piriform aperture stenosis and atresia: a rare accompaniment of mid-facial dystosis and cause of neonatal upper airway obstruction: a case report. *Jos Journal of Medicine* 2012; 6(3):37-41.
7. Brachlow A, Schwartz RH, Bahadori. Intranasal mucocele of the nasolacrimal duct: an important cause of neonatal nasal obstruction. *Clinical Pediatrics*. 2004, 43:479-81.
8. Mossey PA, Little J, Munger RG, et al. Cleft lip and palate. *Lancet* 2009;374(9703):1773-1785.
9. Singh B. Bilateral choanal atresia: key to success with the transnasal approach. *J Laryngol Otol*. 1990 Jun;104(6):482-4.
10. Ismail A, Abdulkadir AY. Bilateral Choanal atresia in a 7-year-old boy: A Case Study. *Niger Postgrad Med J*. 2013 Dec; 20(4):352-5.
11. Tatar EÇ, Ozdek A, Akcan F, Korkmaz H. Bilateral congenital choanal atresia encountered in late adulthood. *J Laryngol Otol*. 2012 Sep; 126(9):949-51.
12. Xue-zhong Li, Xiao-lan Cai, Lei Zhang, et al. Bilateral congenital choanal atresia and osteoma of ethmoid sinus with supernumerary nostril: a case report and review of the literature. *J Med Case Reports* 2011; 5:583.
13. Al-Noury K., Lotfy A. Role of Multislice Computed Tomography and Local Contrast in the Diagnosis and Characterization of Choanal Atresia. *Int J Pediatr* 2011; 2011: 280763.
14. Vickery CL, Gross CW. Advanced drill technology in treatment of congenital choanal atresia. *Otolaryngol Clin North Am*. Jun 1997;30(3):457-65.