

## Minimally Invasive Incision Debridement in Combination with Continuous Closed Negative Pressure Drainage for Morel - Lavallée Lesion.

Li Canzhang<sup>1,2</sup>, A.K. Kiribata<sup>1</sup>, E.K. Naddumba<sup>1</sup>

<sup>1</sup>Orthopaedic unit, China – Uganda Friendship hospital, Naguru Kampala ,Uganda

<sup>2</sup>Trauma Centre of Yunnan, The second People`s Hospital of Yunnan province, China

**Correspondence to:** Dr. Kiribata Konde abdulhamid, Email: hk1642@yahoo.com

**Background:** *The objective of this review was to explore the effectiveness of minimally invasive incision debridement in combination with continuous closed negative pressure drainage for Morel - Lavallée lesion.*

**Methods:** *The Department treated 16 cases of Morel-Lavallée lesion with minimally invasive incision debridement in combination with continuous closed negative pressure drainage technic from Aug 2013 to Aug 2014. All the cases were followed up for 4 to 6 months.*

**Results:** *Fourteen of the cases were managed successfully. Skin necrosis in 2 cases, were skin grafting was then performed. The cure rate was 87.5%.*

**Conclusion:** *Minimally invasive incision debridement in combination with continuous closed negative pressure drainage is a good technic for the treatment of Morel-Lavallée lesion.*

**Key words:** Morel-Lavallée, minimally invasive incision, closed negative pressure drainage

### Introduction

Morel-Lavallée lesions were first reported by French physician Maurice Morel-Lavallée in 1853. It is posttraumatic soft tissue closed degloving injuries in which the skin and subcutaneous tissues are separated from the fascia superficial to the underlying musculature<sup>1</sup>. This injury typically occurs following high-speed trauma. The shear injury disrupts perforating vessels and lymphatics and creates a potential space that fills with blood, serosanguinous fluid, and necrotic fat<sup>2</sup>. Lesions may be missed at initial evaluation and present weeks to months after the inciting event<sup>2</sup>. We share our experience with management of 16 cases of Morel-Lavallée lesion were admitted over a 1 – year period between August 2013 and August 2014.

### Methods

Diagnosis of Morel-Lavallée lesion was based on clinical symptoms, ultrasound scan, Computer Tomography and percutaneous aspiration. Morel-Lavallée lesion cases without fracture were treated with minimally invasive incision debridement in combination with continuous closed negative pressure drainage. For the patients associated with pelvic and acetabula fractures there are two different ways according to the classification of pelvic fracture. ① Managed the lesion early with minimally invasive incision debridement in combination with continuous closed negative pressure drainage for stable fracture cases. Then open reduction and internal fixation (ORIF) for the fracture is performed as vascular supply to the skin is attained and infection controlled. ② For unstable fracture cases we used external fixation to fix the pelvic emergency. After the patient condition has improved, Morel-Lavallée lesions are treated with minimally invasive incision debridement in combination with continuous closed negative pressure drainage as soon as possible. All cases were followed-up to 6 months (range, 4 – 8 months).

### Result

During the study period, a total of 16 patients were diagnosed with Morel-Lavallée lesion. Their ages ranged between 24 -55 years with an average, of 32 years. Males accounted for 11 of the cases and 5 were females. All the 16 cases were were involved in road traffic crashes. All lesions

were localized in thigh and hip region. Twelve of the cases were associated with pelvic and acetabular fractures. The initial full recovery rate was 87.5%. Fourteen of the cases were successfully managed. Only 2 cases developed skin necrosis that required a second debridement operation and skin grafting.

## Discussion

Morel-Lavallée lesion can appear in the trunk and lumbar zone; but most commonly, lesions occur within the proximal thigh and trochanteric region. These lesions can be open or closed and can lead to:

1. **Skin necrosis:** Cormack and Lamberty proved that the flow of blood to the skin and the dermis is made through the muscle fascia and subcutaneous tissue of the blood vessels<sup>3</sup>. If an internal degloving injury took place, structural damage of blood vessels disrupts blood supply to the skin tissue causing necrosis<sup>3</sup>. Sometimes the skin necrosis appears larger than the lesions area<sup>3</sup>.
2. **Infection:** Many Scholars agree, though there might be no open wound, haematogenous spread of bacteria into the cavity can lead to infection or local abscess formation<sup>4</sup>. In Hak's report, the average time was 13.1 days after the injury to the debridement. The bacterial culture before debridement showed 46% positive of that group<sup>4</sup>.

The key to early diagnosis of Morel-Lavallée lesion is based on clinical manifestations. Lesion site appears blue, ecchymosis, bruises, hematoma formation, and local hypesthesia or loss of feeling. Palpation often reveals an obvious fluctuation as in Figures 1 and 2.

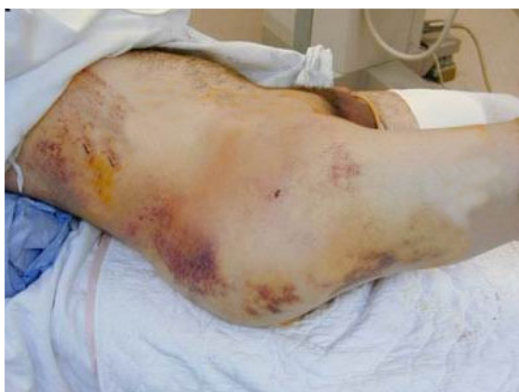

Figure 1

**Figure 1.** A patient with Morel-Lavallee lesion three days after injury.

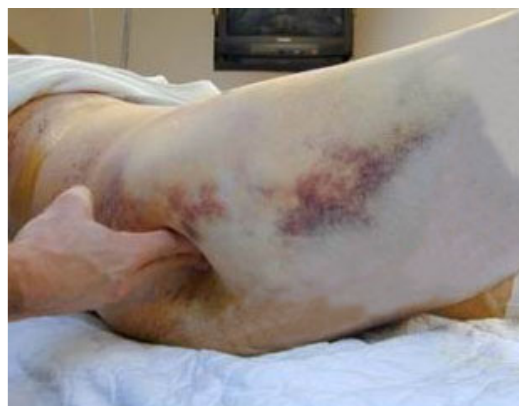

Figure 2

**Figure 2.** A large fluctuant area is demonstrated by palpation

A positive ultrasound Scan could reach 100% sensitivity for Morel-Lavallée lesion patients. At times bloody fluid can be extracted percutaneously under ultrasound guidance. Magnetic resonance imaging is the preferred imaging modality in the evaluation of Morel Lovellee lesions<sup>2</sup>.

Most authors have agreed that, once the injury is identified, the haematoma must be evacuated and any necrotic tissue must be removed as neglected lesions can become infected, complicating management<sup>4,5,6,7,8</sup>. However, the method by which this is performed is controversial. ZHU Yueliang and XU Yongqing et al<sup>9</sup> used repeated debridement, external fixation of fractures, vacuum sealing drainage, skin grafting, reconstruction of genitalia, and anoplasty to treat Morel-Lavallée lesion and got satisfactory outcomes. Tseng and Tornetta<sup>10</sup> reported early percutaneous drainage with debridement, irrigation, and suction drainage for the treatment of Morel-Lavallee lesions appears to be safe and effective. In their study 19 patients with a Morel-Lavallee lesion were managed with percutaneous drainage and debridement of the lesion within three days after the injury. Drainage was usually completed through two 2-cm incisions<sup>10</sup>. A plastic brush was used to debride the injured fatty tissue, which was washed from the wound with pulsed lavage. A medium Hemovac drain was placed within the lesion and was removed when drainage was <30 mL over twenty-four hours. Antibiotics were administered intravenously during closed drainage. ORIF of pelvis and acetabulum fractures were done when the wound was healing<sup>10</sup>.

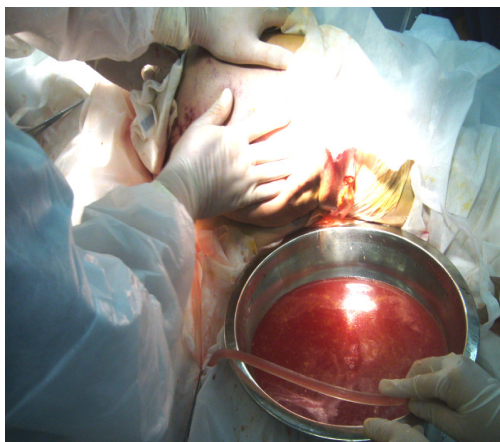


Figure 3

Figure 3. A 3 cm Incision Under Ultrasound Scan Localization on the Lesion Area was made and drain the fluid.

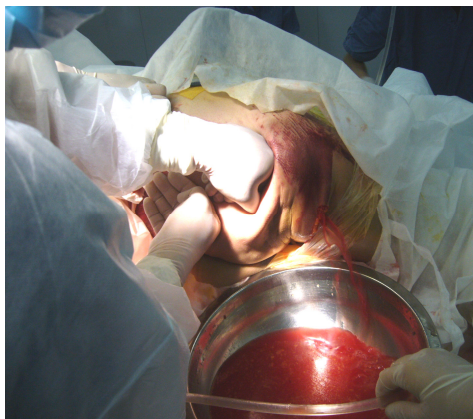
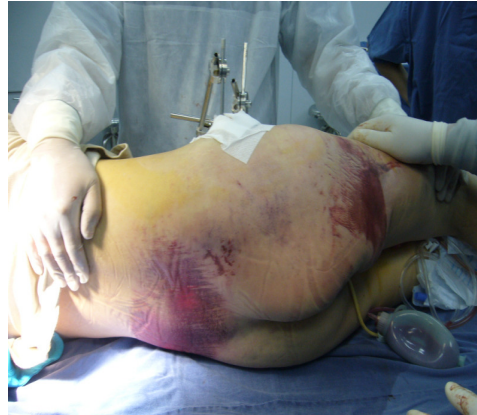
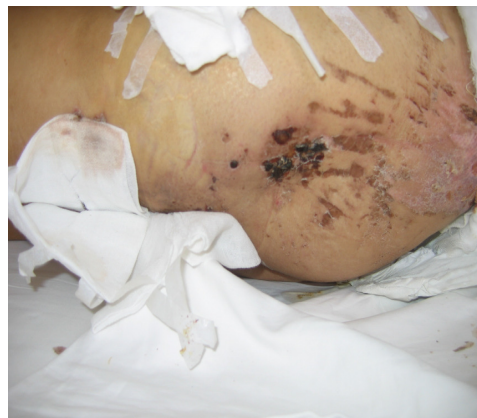Figure 4

Figure 4. Removed fluid and all necrotic tissue through incision irrigating the cavity with normal saline



**Figure 5**

Figure 5. Kept the drainage tube at the lowest point of the cavity and connected continuous closed negative pressure machine or negative pressure absorbing ball



**Figure 6**

Figure 6. The skin flap survived after continuous closed negative pressure drainage for 7days.

Through a 3cm incision, thorough removal of fluid and necrotic tissue was done under ultrasound guided localization of the lesion. Irrigation of the cavity with more than 3000ml normal saline until the solution was clean and no more necrotic tissue. A drainage tube was kept at lowest point of the cavity after debridement. Continuous closed negative pressure machine or negative pressure absorbing ball was connected with the tube. Sutured the wound and covered lesion area with compressive bandage. As for the late occurrence skin necrosis, debridement of lesion site extensively and make split thickness skin graft or skin flap transplantation (Figures 3 – 6).

Continuous closed negative pressure drainage is preferably used on patients with stable vital signs. There's need to keep observing change in nature and amount of fluid drained. If there is a continuous increase in the nature and amount of fluid drained, open surgical debridement should be performed as soon as possible.

Treatment timeline for Morel-Lavallée lesion associated with pelvic and acetabular fractures can be difficult to predict. Patient vital signs must be stabilized and life-threatening concurrent injuries treated immediately. Individualization of treatment for different patients is necessary as survival of the skin flap alone has a very narrow time limit and needs a stable pelvis. A well vascularized skin is necessary for ORIF of pelvic and acetabular fractures. Minimally invasive

incision debridement in combination with continuous closed negative pressure drainage is less traumatic, simple operation and effective treatment for Morel-Lavallée lesion. It provides opportunities for the early treatment of the associated fracture.

## References

1. Morel-Lavallée. Decollements traumatiques de la peau et des couches sous-jacentes. Arch Gen Med . 1863;1:20-38,172-200,300-332.
2. Falgun H. Chokshi, MD, Jean Jose, DO, and Paul D. Clifford, MD. Morel-Lavallée Lesion. The American Journal of Orthopedics 2010;39(5):252-253.
3. Cormack GC, Lamberty BG. The blood supply of thigh skin. Plast Reconstr Surg. 1985 Mar;75(3):342-54.
4. Hak DJ, Olson SA, Matta JM. Diagnosis and management of closed internal degloving injuries associated with pelvic and acetabular fractures: the Morel-Lavallée lesion. Trauma. 1997 Jun;42(6):1046-51.
5. Letournel E, Judet R. Fractures of the acetabulum. 2nd ed. Elson RA, translator, editor. Berlin: Springer; 1993. p 337, 363-97.
6. Kottmeier SA, Wilson SC, Born CT, Hanks GA, Iannaccone WM, DeLong WG. Surgical management of soft tissue lesions associated with pelvic ring injury. Clin Orthop Relat Res. 1996;329: 46-53.
7. Routt ML Jr, Simonian PT, Ballmer F. A rational approach to pelvic trauma. Resuscitation and early definitive stabilization. Clin Orthop Relat Res. 1995;318: 61-74.
8. Helfet DL, Schmeling GJ. Complications. In: Tile M, editor. Fractures of the pelvis and acetabulum. 2nd ed. Baltimore: Williams and Wilkins; 1995. p 451-67.
9. Zhu Y, Xu Y, Li J, Dai Y, Yang X, Zhao H. Surgical treatment of Morel-Lavallée lesion with perineal lacerations. Zhongguo Xiu Fu Chong Jian Wai Ke Za Zhi. 2010 Jun; 24(6):726-9.
10. Tseng S, Tornetta P 3rd. Percutaneous management of Morel-Lavallée lesions. J Bone Joint Surg Am. 2006 Jan;88(1):92-6.