



A Uterine Stone: A Case Report

T. Negussie, P. Kidane

Department of Surgery, School of Medicine, CHS, Addis Ababa University

Correspondence to: Philipos Kidane, E-mail: philiposkidane@gmail.com

Human uterine stone formation is an exceedingly rare condition and to our knowledge only two previous case reports has been published on uterine stones. Uterine calcification occurs in many animal species related to the formation of a protective shell for the developing embryo¹ and human endometrial calcification has been rarely associated with some benign and malignant conditions in the form of Psammoma bodies. We present here a rare case of uterine stone in an 8 year old female child.

Case report

An 8 year old female child was admitted to our hospital for colostomy closure. The child initially presented at the age of 2 years with perianal region necrotizing fasciitis (following intramuscular antibiotic injection for diarrheal illness) with sphincter damage and debridement of wound and sigmoid loop colostomy was done and at the age of 4 years anal sphincter reconstruction and colostomy closure attempted but the faecal incontinence persisted along with urinary incontinence and currently admitted with significantly improve anal sphincter tone and mild stress incontinence for colostomy reversal.

The physical examination showed a patent anal canal with good anal tone but tight or frozen pelvis. Plain abdominal x-ray and Barium enema through colostomy showed patent and good calibre distal bowel with radiopaque shadow in the pelvis (Figure 1 A and B). She was explored and the finding was a big hard mass inside the uterus (Figure 2) which was opened over the fundus and an 8 x 5 cm stone identified in the endometrial cavity which was crashed in pieces and removed (Figure 3). The endometrial cavity was found to be normal, with no fistula to the bladder and the vaginal cavity was also normal as was the other pelvic viscera. The child was subsequently discharged on her 8th post-operative day improved. The stone removed was sent for chemical analysis which revealed a composition of calcium and carbonate (calcite).

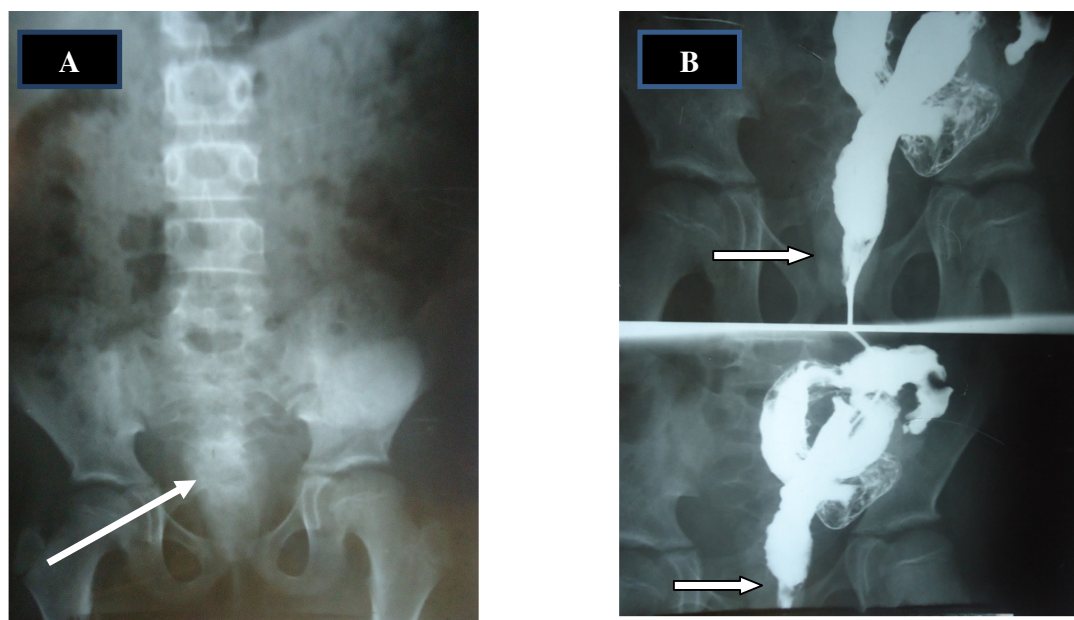


Figure 1. Plain abdominal x-ray(A) and distal colostogram(B) showing radio-opaque shadow in the pelvis(arrow)

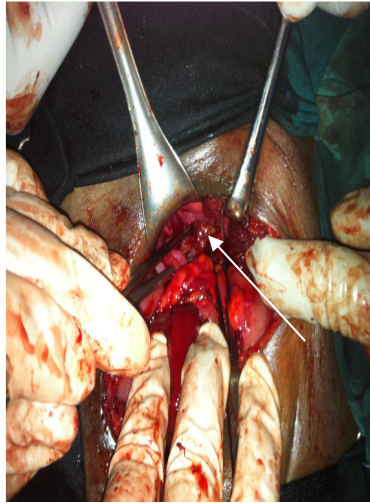


Figure 2. Stone (arrow) inside the open uterus

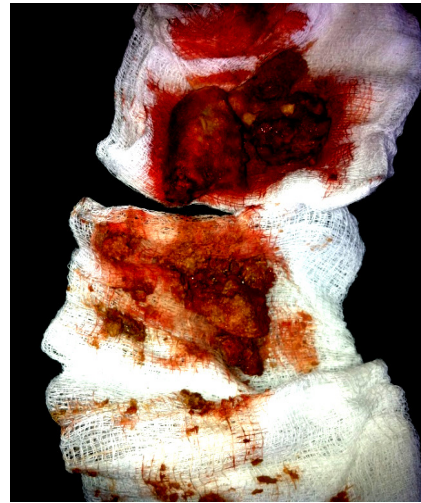

Figure 3. The removed Crashed Stone

Discussion

Calcification and hence stone formation in the human endometrium is an extremely rare phenomenon except when it occurs in the developing embryo and foetus. After extensive literature search using pubmed and the Ptolemy library, there have been only two cases of uterine stones reported in a 73 and 46 year old women^{2,3}. Calcium deposition has also been found to occur in intrauterine contraceptive devices. Calcification has been reported in Asherman`s syndrome⁴, in papillary adenocarcinoma^{5,6} and in degenerated leiomyomata. Two old gynaecology text books mentioned uterine stones consisting of phosphate and carbonate with the explanation of pedunculated fibroids rarely getting twisted, strangulated, necrosed, calcified and fall into the endometrial cavity^{7,8}. In animal species, such as hens, calcification occurs in the formation of a protective egg shell that will permit ongoing respiration for the developing offspring. Human urinary tract stones are mainly composed of calcium oxalate and phosphate and also magnesium ammonium phosphate and sometimes urate, cystine and xanthine but stones composed of calcium carbonate or calcite are unheard of in humans but do occur in herbivores.

In summary, we have presented a very rare case of uterine stone composed of calcium carbonate, rarely found in human urinary tract, but common in other animals.

References

1. Taylor TG. How an eggshell is made. *Sci Am* 1970; 222:89-95
2. *Am J SurgPathol.* 1990; 14 (11):1071-5. Uterine Lithiasis. Alpert LC, Haufrect EJ, Schawrtz MR.
3. Hadda FS. Uterine Calculi (womb Stones). *Annu Rep Orient Hosp* 1963;16:1205-7.
4. Untawale VG, Gabriel JB, Chauhan PM, Calcific endometritis. *Am J ObstetGynecol* 1982; 144:482-3.
5. Factor SM. Papillary adenocarcinoma of the endometrium with psammoma bodies. *Arch Pathol* 1974; 98; 201-5.
6. Hameed K, Morgan DA. Papillary adenocarcinoma of endometrium with psammoma bodies. *Cancer* 1972; 29:1326-35.
7. Hirst BC. *A text-book of diseases of women.* Philadelphia: WB Saunders, 1903:330.
8. Lynch FW. Chapter 12. In: Davis CH, ed. *Gynecology and obstetrics*, vol 2, Hagerstown: WF Prior, 1939:11.