

Tuberculous Hip Infection Leading to Life Threatening Complications: A Case Report

T. Beyeza, P. Mulepo

Department of Orthopaedics, Makerere University College of Health Sciences – Kampala, Uganda.

Correspondence to: T. Beyeza, Email: beyeza1959@yahoo.com

Introduction

Tuberculosis remains a major cause of morbidity and mortality worldwide. An orthopaedic surgeon working in a developing nation is most likely to encounter musculoskeletal tuberculosis. The infection runs a chronic course with destruction of the affected part. The diagnosis usually requires high level of suspicion followed by biopsy to confirm and they usually respond well to chemotherapy with surgery only being adjuvant for specific indication. The natural cause of tuberculous arthritis evolves over several years from a synovitis to complete joint destruction and the prognosis depends on the stage of the disease at presentation.

Case report

A 26 year old male whose occupation is selling roasted meat was referred from a rural district hospital to Mulago national referral and teaching hospital with history of passing urine per anus and passing faecal matter per urethra for one year. He was well until he reached the age of 10 years when he started to feel right hip pain associated with a low grade fever which limited his daily activities. He was treated from nearby health facilities without much relief.

He later developed a perineal abscess for which he was treated locally by a traditional healer who drained his abscess using a hot iron rod. As a result, he developed a sinus that took two years to heal. When the perineal sinus closed, he developed another abscess that pointed at the right inguinal region and was drained from the district hospital. He had no history of cough or evening fevers but had moderate weight loss. He had no contact with known tuberculosis patient. He later developed progressive difficulty in passing urine and stool; he always strained to pass urine and stool. This was associated with frequency and urgency. He then started to pass urine per-anus while straining and also observed faecal matter per urethra. He thereafter developed intestinal obstruction for which he had a colostomy done at Mulago Hospital.

On examination, he had moderate wasting, mild pallor of mucus membranes, wasting of right gluteal muscles, marked prominence of the right greater trochanter with a fixed flexion deformity of the right hip joint.

Laboratory investigations included Full Blood Count (CBC) which gave a WBC = and 7.1×10^3 and ESR = 60mm/hr. Renal Function Tests(RFTS) and Liver Function Tests (LFTS) were within normal ranges. Urinalysis

- (a) Dipstick: (i) protein.....+
(ii) Glucose.....Nil
(b) Microscopy: (i) Pus cells.....+++
(ii) Epithelial cells.....++

Cystoscopy done revealed a massive calcified mass elevating the rectovesical and compressing the bladder against the pubic symphysis.

Examination under Anaesthesia (EUA) and Proctoscopy revealed a calcified mass in the rectum fused to the right pelvis and right hip joint.

Radiological investigation

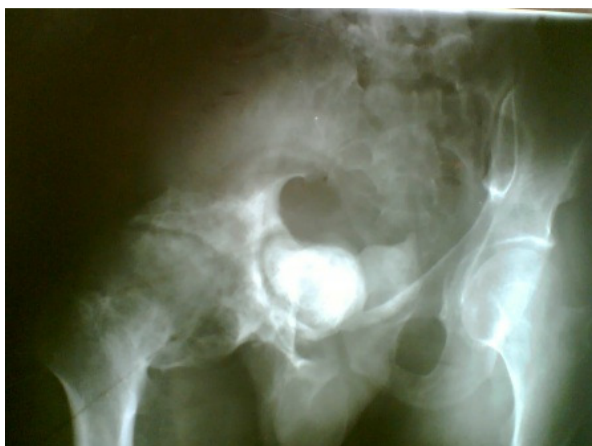

Figure 1 AP Pelvic Radiograph

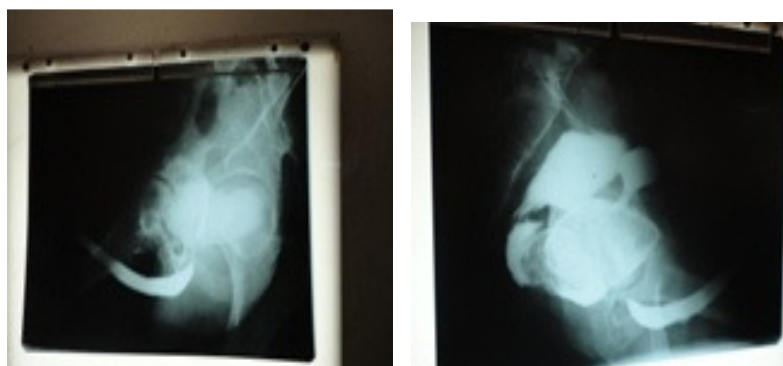
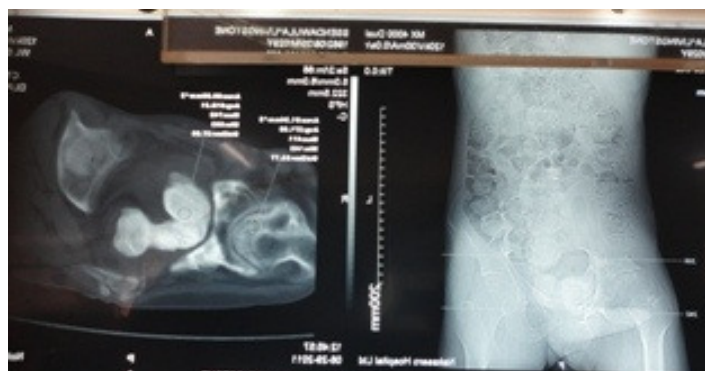
Figure 2 Cystourethrogram.

Abdominal u/s revealed mild bilateral hydronephrosis the other abdominal organs were normal. Pelvic X-ray fig.1 showed a calcific pelvic mass and a destructive lesion of the right hip joint. Cystourethrogram fig.2 revealed a Rectovesical fistula a result of erosion of the bladder, and associated chronic bladder outlet obstruction.

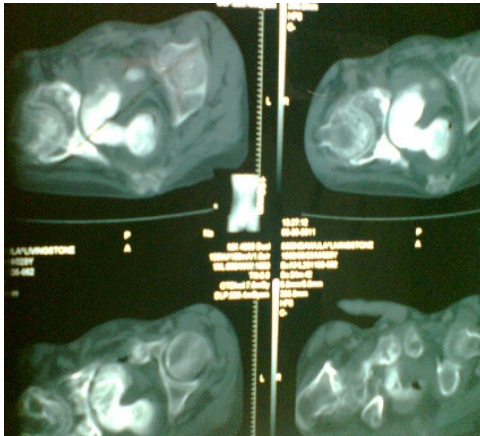


Figure 3 CT Scans of the pelvis

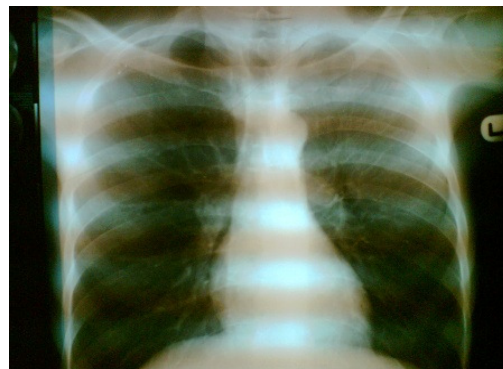

Figure 4 Chest x-ray.

Incisional biopsy was done and the specimen taken for Z-N stain and histology. Z-N stain revealed acid fast bacilli (*Mycobacterium tuberculosis*) and histology revealed Langerhan's giant cells with area of caseations. The patient was initiated on antituberculous medication for 12 months.

Discussion

Tuberculosis is an infectious disease caused by acid fast bacilli *Mycobacterium tuberculosis*. Tuberculosis is one of the six leading cause of death due to infectious diseases worldwide, it was responsible for an estimated 1.8 million deaths in 2008 according to the Global tuberculosis report 2011¹. Tuberculosis remains a major Global health problem causing significant morbidity and mortality. In 1993, the WHO declared tuberculosis a Global public health emergency at the time when an estimated 8.5 – 9.5 Million new cases and 1.2 – 1.5 million deaths was reported². In 2010, there were 8.8 million (Range 8.5 – 9.2 million) incident cases of Tuberculosis, 1.1 million (Range 0.9 – 1.2 million) deaths from tuberculosis among HIV negative people and an additional 0.35 million (Range 0.32 – 0.39) deaths from HIV associated Tuberculosis according to the Global tuberculosis report 2011.

Uganda ranks 19th Of the 22 high burden tuberculosis countries, in 2010, incident rate was 209 cases per 100,000 populations. Musculoskeletal tuberculosis accounts for around 10 – 15% of all tuberculosis notifications in the non – industrialised world⁴. However, in the western world, musculoskeletal tuberculosis tends to be uncommon and accounts for around 1 -2 % of all cases of tuberculosis and about 10 – 15% of extrapulmonary tuberculosis. The spine is the most common site for osseous involvement accounting for around 50% of cases, followed by the pelvis 12%, hip and femur 10%, knee and tibia 10%, ribs 7% and multiple sites 3%. The musculoskeletal is the second

most affected system after the pulmonary system. Tuberculosis Spread to the musculoskeletal system is by haematogenous route³. Mycobacterium infections of the joints are chronic, slowly progressive as in our case and usually monoarticular with weight bearing joints most affected. Granulomatous inflammation with caseation destroys bone. Overcrowding, immune suppression, malnutrition and contact with known patient of tuberculosis are main risk factors to acquiring tuberculosis. The diagnosis of extra pulmonary tuberculosis is often challenging and can be delayed. A positive chest radiograph, or positive skin tuberculin test, will support the diagnosis though it is not excluded by negative results in our case, the predisposing factor could not be established because of the long history of the illness and the absence of old medical record.

Regarding this patient who initially was attended to from rural district hospital misdiagnosis could have been a result of lack of specialist surgeons. Concomitant pulmonary tuberculosis has been reported to be present in less than 30% of extra pulmonary tuberculosis cases⁶. The treatment for extra pulmonary tuberculosis usually take 8 – 12 months of antituberculous drug therapy using a four drug combination in the initial two month intensive phase and a two drug combination in the continuation phase. This treatment needs to be supervised.

Conclusion

Musculoskeletal tuberculosis contributes to a significant morbidity and mortality, and remains a diagnostic challenge to clinicians which requires a high index of suspicion. Prompt diagnosis and treatment of skeletal tuberculosis are important to prevent serious bone and joint destruction. In the developing countries the problem is compounded by the small numbers of specialised surgeons.

References

1. Global Tuberculosis control: *WHO Report 2011*.
2. Salman Al-Saleh, Hassan Naddaf, Abdurahman Al-Arfaj, et al: Tuberculous Arthritis; A review of 27 cases: *Annals of Saudi Medicine, Vol. 18 No4, 1998*.
3. JC Talbot, Q. Bismil, D. Saralaya et,al ; Musculoskeletal Tuberculosis in Bradford – A six year review: *Annals of the Royal College of Surgeons of England 2007 May, 89(4):405-9*.
4. Dariel A. Spigel, Girish K. Singh, Ashak K. Banskola: Tuberculosis of the Musculoskeletal System. *Techniques in orthopaedics; 20(2):167-178, 2005 Lippincott Williams and Wilkins, Inc, Philadelphia*.
5. Mohammed J. Al-Sayyad and Lutf A. Abumunaeer : Tuberculous Arthritis revisited as a forgotten cause of monoarticular arthritis. *Annals of Saudi Medicine; 2011 Jul – Aug 31(4): 398 – 401*.
6. Guedes Ramos, Marcelle D. Alves, Rodrigo Dos Santos et al: Chronic slowly progressive Monoarthritis tuberculosis of the hip without systemic symptoms mimicking osteoarthritis: A case Report. *Case Journals 2009; 2: 6457*.