



## Sokoto Journal of Veterinary Sciences

(P-ISSN 1595-093X/ E-ISSN 2315-6201)

Eyarefe & Oguntoye /*Sokoto Journal of Veterinary Sciences* (2016) 14(3): 8 – 17.

<http://dx.doi.org/10.4314/sokjvs.v14i3.2>

### RESEARCH ARTICLE

# Honey, an unexplored topical wound dressing agent in Nigerian veterinary practice

OD Eyarefe & CO Oguntoye\*

*Department of Veterinary Surgery and Reproduction, University of Ibadan*

\*Correspondence: Tel.: +2348055063671; E-mail: wumcel06@gmail.com

#### Abstract

This paper presents an overview of honey as a wound dressing agent, its mechanism of action, selected cases of wounds managed with honey and a survey of veterinarians' perception and usage of honey for wound management in Nigeria. Structured questionnaires were administered to veterinary practitioners predominantly in Southwest Nigeria to evaluate their awareness, usage and concerns about honey as a wound dressing agent. Case reports of animal patients' wounds managed with honey are presented in a logical fashion to showcase honey efficacy in wound management. There was remarkable healing with honey in the cases managed. Many of the respondents did not consider honey as first choice in wound management and availability of pure honey is a major concern expressed with honey use. More veterinarians in Nigeria should use honey for its high efficacy and cost effectiveness in the management of animal wounds.

*Keywords:* Awareness, Dressing agents, Efficacy, Honey, Wound

Received: 02-07- 2016

Accepted: 30-07-2016

#### Introduction

Incidence of wounds remains the highest amongst conditions presented to veterinary clinics and hospitals in Nigeria and some other West African countries (Eyarefe *et al.*, 2011; Eyarefe & Dei, 2014). The veterinarian is therefore faced with the challenge of managing wounds of varying types, severity and degrees of contamination-cum-infection and chronicity with a goal of enhancing rapid wound healing. Wound management often requires topical antimicrobial agents (antiseptics or antibiotics) incorporated into wound dressings to enhance wound sterilisation, debridement and repair process (Lipsky & Hoey, 2009; Eyarefe *et al.*, 2014). Various topical antiseptics such as chlorhexidine, hexachlorophene, iodine compounds (iodine tincture, povidone iodine, cadexomer iodine), alcohol, sodium hypochlorite, quaternary ammonium compounds, acetic acid, hydrogen peroxide, and silver nitrate have been used to enhance wound healing with varying results (Liptak, 1997; Lipsky & Hoey, 2009). Topical preparations of

cephazolin, bacitracin-polymyxin and B-neomycin, silver-sulphadiazine, gentamicin, neomycin sulphate, and nitrofurazone antibiotics have been used for wound management (Liptak, 1997; Atiyeh *et al.*, 2007; Lipsky & Hoey, 2009). An ideal topical antimicrobial agent should have antimicrobial spectrum for the targeted type of infected wound, rapid bactericidal activity, allow infrequent dosing, local skin penetration and residual activity without systemic absorption, including being active in the presence of body fluids and proteins in wound exudate (Kramer *et al.*, 2004; Lipsky & Hoey, 2009). It should have no associated host tissue allergic reaction; neither produce toxic, carcinogenic and teratogenic effects nor have likelihood of inducing bacteria resistance (Kramer *et al.*, 2004). More importantly, it should be readily available at low cost and produce acceptable cosmetic and aesthetic skin qualities (Zumla & Lulat, 1989; Lipsky & Hoey, 2009; Eyarefe *et al.*, 2014; Eyarefe & Fabiyi, 2016). In recent times, some new topical agents such as:

Cadexomer iodine, silver compounds, super oxidized water, antimicrobial peptides and honey have evolved for wound management (Molan 2001; Ulvatne, 2003; Reddy *et al.*, 2004; Gonzalez-Espinosa *et al.*, 2007; Fonder *et al.*, 2008; Lipsky & Hoey, 2009). Of these agents, honey has been prized for its universal availability, cost effectiveness, especially in management of large surface wounds and ease of accessibility in poor resource settings of African and Asian countries.

Bee honey is a natural age-long medicinal agent (De Rooster *et al.*, 2008; Lee *et al.*, 2011), whose efficacy in wound management has received a renewed interest in recent times, especially, with the challenge of microbial resistance to antibiotics (Molan, 2011; Molan, 2006; Lee *et al.*, 2011). In laboratory studies, it has been shown to have inhibitory effects against a wide range of gram-positive and gram-negative aerobic and anaerobic bacteria (70 species) including methicillin resistant *Staphylococcus aureus* (MRSA) (Dunford *et al.*, 2000; Molan, 2001; Cooper *et al.*, 2002; Krisztina *et al.*, 2007). It also has antifungal actions against *Aspergillus*, *Penicillium* and dermatophytes species (Boukraa & Bouchergane, 2007; Israili, 2014). Its immune-boosting, antioxidant (Tonk *et al.*, 2003; Molan & Rhodes, 2015) and tissue regenerating properties (Molan, 2011; Eyarefe *et al.*, 2014) have also been emphasized in literatures. Pure, unpasteurized, honey is composed of approximately 40% glucose; 40% fructose; 20% water; and trace amounts of amino acids, vitamins (i.e., biotin, nicotinic acid, folic acid, pantothenic acid, pyridoxine, and thiamine), enzymes (i.e., diastase, invertase, glucose oxidase, and catalase), and minerals (i.e., potassium, iron, magnesium, phosphorus, copper, and calcium), flavonoids and phytochemicals (Mathew & Binnington, 2002). Royal jelly protein 1(MRJP/1) and arabinogalactan are recent components found in honey to which honey's immunostimulatory activity in wound healing has been attributed by researchers (Gannabathula *et al.*, 2012; Majtan, 2014).

Honey is prized for its antibacterial, anti-inflammatory, tissue regeneration, angiogenesis, and epithelialisation properties (Simon *et al.*, 2009; Eyarefe *et al.*, 2014; Molan & Rhodes, 2015). In a recent study, its immunostimulatory activity was also elucidated. Honey effect on leucocytes cause the production of cytokines which lead to the stimulation and growth of cells. Honey at a concentration of 1% stimulated the release of tumour necrotic factors alpha (TNF- $\alpha$ ) by monocytes

and suppressed the production of reactive oxygen intermediate formed during respiratory burst (Tonks *et al.*, 2001). In a similar in vivo study honey stimulated the release of cytokines known to play key roles in tissue repairs (TNF- $\alpha$ , interleukin-1 beta (IL-1 $\beta$ ), and IL-6) (Tonks *et al.*, 2003). In another study honey upregulated the gene for matrix metalloproteinase 9 (MMP-9) - a protease that detaches keratinocytes from the basement membrane. This honey influenced molecular episode also aid wound re epithelialization through keratinization by inducing the production of keratinocytes growth factor and fibroblast growth factor 7 (Majtan *et al.*, 2010).

Honey is currently used worldwide to treat human patients with infected wounds, burns, ulcers, fournier gangrene, and pyoderma gangrenosum (Mathews & Binnington, 2002; Lee *et al.*, 2011). Some veterinarians have also attempted honey in clinical wound management myiasis and pododermatitis) with exciting results (Krisztina *et al.*, 2007; De-Rooster & Declercq, 2008). Honey is currently branded as Medi honey, surgi-honey, Activion tube and Manuka honey (Simon *et al.*, 2009; Molan & Rhodes, 2015). Despite honey's wound healing efficacy as expressed in literature, many veterinarians have been slow to accept honey for management of animal wounds (Mathews & Binnington, 2002). The aim of this study therefore is to assess the level of veterinarians' awareness and usage of honey for animal wound management in Nigeria with the objective of encouraging veterinary practitioners in Nigeria to consider honey as a topical treatment option in wound management. Some wound cases managed with honey are also reported and discussed.

## Materials and Methods

### *Survey instrument design*

A structured questionnaire was developed to explore the perception and experience of veterinary practitioners (small and large animals) in Nigeria with topical wound dressings especially honey. A draft version of the questionnaire was validated through experienced veterinarians and their comments used to modify the final version of the instrument. Additional validity and reliability (internal consistency) of instrument sample data was high with alpha coefficient = 0.73. The final version consisted of 6 sections which include: clinician's demography consisting of gender, practice location and type of practice (large or small animal practice). Clinician's case types (medical, surgical or mixed

practice), common wound dressing agents utilised for topical wound management, perception and experience with wound dressing agents, and observation / challenge with honey. The Likert's scale was adopted as respondent indicator for the study.

*Instrument administration*

Questionnaires were administered to practitioners at their practice locations and at local veterinary conferences.

Enrolment Criteria: General practitioners in small and large animal practices were enrolled. One questionnaire was served to each practice even when more than one clinician works in the same clinic or hospital. Incompletely filled questionnaires were not used in the analysis.

*Data analysis*

The responses (Practitioners' bio-data and questions) were coded and entered into Microsoft windows excel spread sheet. Data generated within each section were presented in percentages with the standard error of means.

**Results**

*Survey of practitioners on honey use for wound dressing*

Distribution of respondents clinics/hospital, practice types and location: Eighty-four (84) veterinary practices distributed across 10 states of Nigeria completed the questionnaires. Their practice representatives consisted of 61(72.6%) males and 19

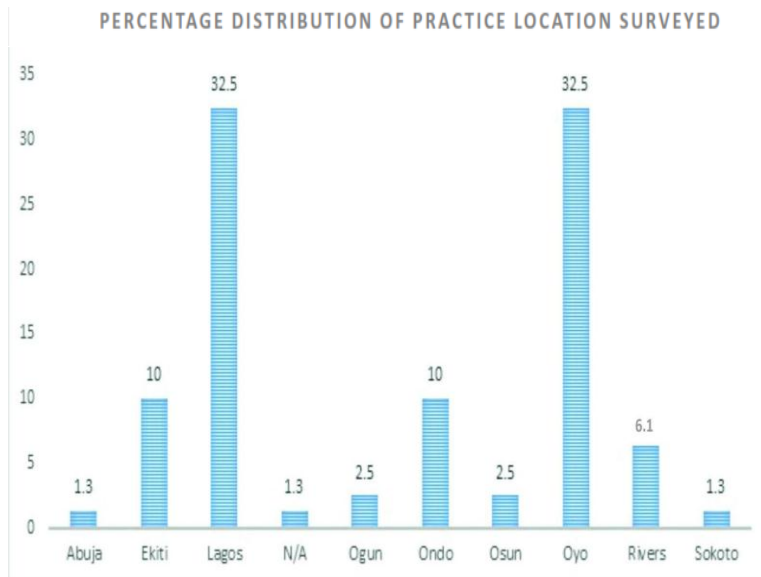
(22.6 %) females. Four (4.8%) practice representatives did not disclose their sex. Lagos (32.5%) and Oyo (32.5%) states had the highest number of practices, followed by Ondo (10%), Ekiti (10%), Rivers (6.1%), Ogun (2.5%) and Osun (2.5%) and the least in Sokoto state (1.3%) and Abuja (1.3%) (Federal Capital Territory (FCT) (Figure 1). Fifty-six percent (56%) of them operated mixed practice (large and small animals), 34% operated small animal practice only and 10% operated only large animal practice.

Predominant cases managed at practice (medical or surgical): Most veterinary establishments surveyed (88.8%,  $p=0.001$ ) handle both medical and surgical cases. A significant number (85.1%,  $p= 0.006$ ) handle more medical than surgical cases (Table 1).

Wound prevalence in Veterinary practice surveyed: Wound cases constituted more than half of the caseload of 47.5% of respondents' practice and wound cases constituted less than half of the total case load of 51.3% respondent practice (Table 1).

Common wound Dressing agents' used by practitioners in Nigeria: Majority of the practitioners (90.1%,  $p=0.04$ ) use topical wound dressing agents (Table 1). Many practitioners (25.4%) use oxytetracycline spray as wound dressing agent, 20% use penicillin preparation, 17.92% use iodine, 13.3% use honey, 11.6% uses amikacin preparation and 11.6% other unspecified wound healing agents (Figure 2).

Practitioners perception of honey and usage a wound dressing agent: Many practitioners surveyed (66.6 %,  $p= 0.008$ ) strongly agreed that in selecting wound dressing agent honey was not a priority. Most practitioners (95.1%,  $p=0.002$ ) use other wound dressing agents rather than honey. Only 53.8 % of practitioners surveyed have attempted to use honey for wound dressing at one time or the other. Those who have used honey (57.5%,  $p=0.032$ ) attested that honey produce faster and better healing qualities when compared with other topical wound dressing agents. The concern of 72.6 % ( $p=0.05$ ) of practitioners was the availability of unadulterated honey for wound dressing. Most practitioners that have used honey disagreed with its likelihood to cause wound hypergranulation (Table 1).



**Figure 1:** Showing percentage distribution of practice location surveyed

**Table 1:** Percentage responses of practitioners to topical wound dressing agents and honey usage for wound management queries

	Strongly agree	Agree	Disagree	Strongly disagree	No response	Standard error of mean	P value	Sig. ( $\leq 0.05$ )
Handle Medical and Surgical cases	45.0	43.8	6.3	3.8	1.3	$\pm .094$	.001	<b>S</b>
Handle Medical cases mostly	43.8	41.3	10.0	2.5	2.5	$\pm .102$	.006	<b>S</b>
Wounds comprise 50% or more of caseload	12.5	35.0	38.8	7.5	6.3	$\pm .133$	.489	<b>NS</b>
Wounds comprise less than 50% of caseload	16.3	35.0	35.0	12.5	1.3	$\pm .107$	.454	<b>NS</b>
Often use wound dressing agents	48.8	41.3	3.8	3.8	2.5	$\pm .101$	.004	<b>S</b>
Wound dressing agents delay healing	5.0	7.5	57.5	26.3	3.8	$\pm .091$	.075	<b>NS</b>
Honey produces faster and better healing compared with other wound dressing agents	32.5	25.0	12.5	5.0	25.0	$\pm .177$	.032	<b>S</b>
Honey is expensive	20.0	26.3	23.8	13.8	16.3	$\pm .151$	.269	<b>NS</b>
Challenge of getting unadulterated honey	46.3	26.3	11.3	2.5	13.8	$\pm .155$	.057	<b>NS</b>
Honey causes hyper-granulation	6.3	21.3	42.5	5.0	25.0	$\pm .336$	.823	<b>NS</b>
Honey's healing potentials is satisfactory	23.8	28.8	10.0	5.0	32.5	$\pm .180$	.034	<b>S</b>

	Yes	No	No response	Standard Error of Mean	p	.sig ( $\leq 0.05$ )
You have used honey in wound dressing	53.8	41.3	5.0	$\pm .065$	.679	<b>NS</b>
You use other wound dressing agents rather than honey	81.3	13.8	5.0	$\pm .048$	.002	<b>S</b>
In selecting wound dressing agents, honey not priority	66.3	16.3	17.5	$\pm .066$	.008	<b>S</b>

**Key:**

p: p value/significance

S: Significant

NS: Not significant

*Reports of wound cases managed with honey at the surgery clinic of the Veterinary Teaching Hospital, University of Ibadan, Ibadan, Nigeria*

Case Number 1: A two year old boerboel bitch was presented with an extensive swelling at the back (cervico-thoracic portion) that developed four days after levamisole hydrochloride administration at the site 8 days prior to presentation. Temperature was 39.9°C. All other vital parameters were within reference values. A fine needle aspirate of the swelling yielded abundant inflammatory cells mainly

neutrophils (70%), with numerous bacteria and necrotic cells (Plate I). A diagnosis of post injection septic necrotizing myositis was made and the patient placed on antibiotics (500mg amoxicillin; North China Pharmaceutical Co, Ltd, China; intravenously twice daily for five days). The abscess was drained flushed with physiologic saline and bandaged. The wound later presented with central necrotic area of devitalised tissues with oedematous and hyperaemic wound edges (Plate II). Further honey dressing enhanced mechanical debridement which enabled

appreciation of wound extent (Plate III). The open wound was managed with honey dressings daily and later at alternate days and further infrequently until adequate healing for surgical reconstruction was achieved (plate IV).

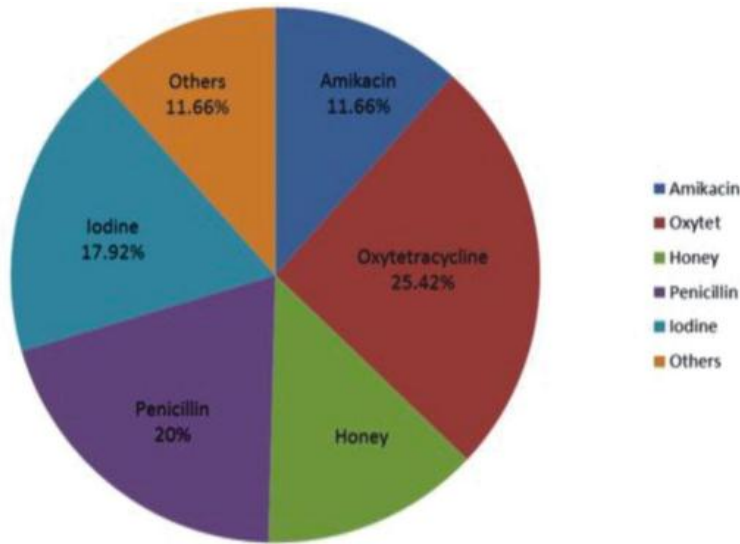
Case Number 2: A one year, ten month - old Rottweiler dog was presented with a 14cm fluctuant swelling associated with a post injection of ivermectin two weeks previously at the cranial dorsum, around the shoulder region (Plate V). The swelling had a small weak skin surface which opened into a cavity resulting into spillage of its contents following shaving. A surgical debridement and extension of the surface wound aided the drainage of its serosanguinous fluid content (Plate VI). The wound was cleansed with physiologic saline following which honey was incorporated into the cavity and bandage applied. Honey dressing was done daily and later at alternate days and less frequently till wound completely healed (Plates VII-IX).

Case Number 3: A two year old Rottweiler bitch (26kg) was presented with an extensive third degree chemical burn wound following a tick bath and application of an oily preparation also meant to

ward off ticks on the back by a care giver (Plates X and XI). Temperature was 40°C. Patient was placed on antibiotics (cephalexin (Sporidex®, Ranbaxy, India) 500mg capsule twice daily for seven days at a dose of 20mg/kg body weight). Wound was cleansed daily with physiologic saline and dressed with honey incorporated bandages. Debridement, repair, contraction and epithelialization were rapid (Plates XII – XVII).

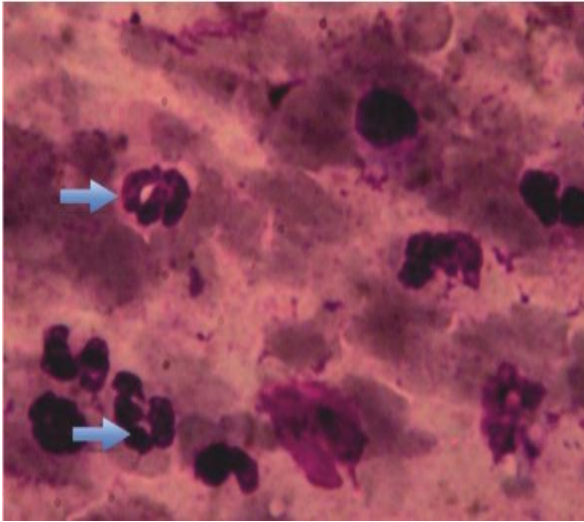
**Discussion**

The result of the study showed that honey is still unpopular for wound management among veterinary practitioners in Nigeria. Lagos and Oyo states had the highest number of practices as shown by the result of the survey (Figure 1). The predominance of more practice in Lagos and Oyo states may have been influenced by the prevalence of small animal practice in this part of the country which often requires practice location for patient management (personal observation). Most of the veterinary practice surveyed handle more medical cases than surgical (Table 1). This result reflects a general trend in clinical practice all over the world. Most veterinary practice have higher medical than

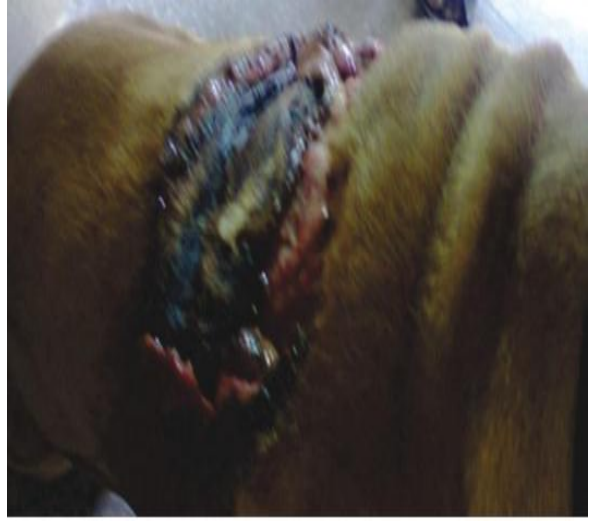

**Figure 2:** Showing percentage distribution of topical wound healing agents used by respondents' practice in Nigeria

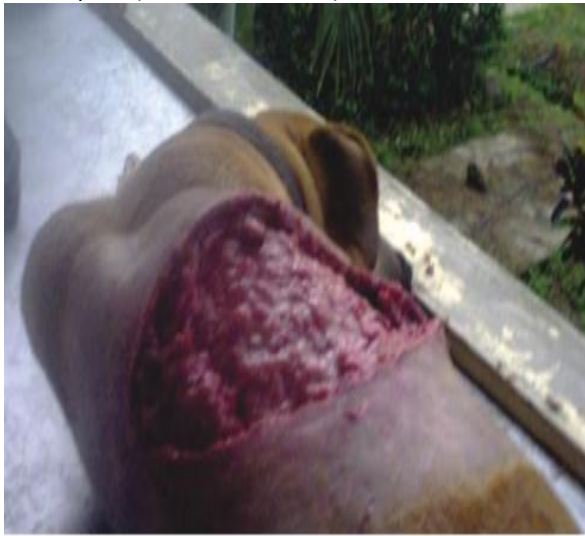surgical case load as a result of more medical cases than surgical among the population and the fact that surgery is an active skill and equipment based specialty that lay heavy demand on equipment and personnel proficiency for patient management (Eyarefe & Dei, 2014). The higher prevalence of wound cases as expressed in this study is consistent with observation in previous studies (Liptak, 1997; Eyarefe & Dei, 2014). The cases managed with honey also revealed the efficacy of honey dressing in wound healing. It is worthy of note that the honey used in the management of these cases was unprocessed honey obtained from local bee hives in Nigeria.



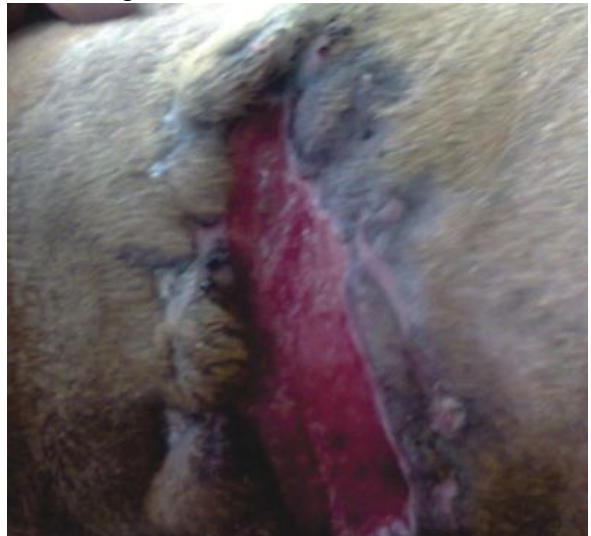**Plate I:** Showing predominantly neutrophils, hyper segmented neutrophils (Upper blue arrow), swollen neutrophils (Lower blue arrow)



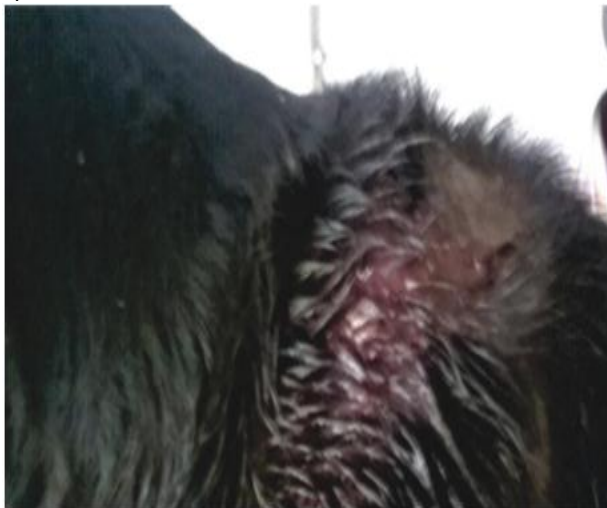**Plate II:** Showing the dog having open wound with central necrotic area and oedematous /hyperaemic wound edges



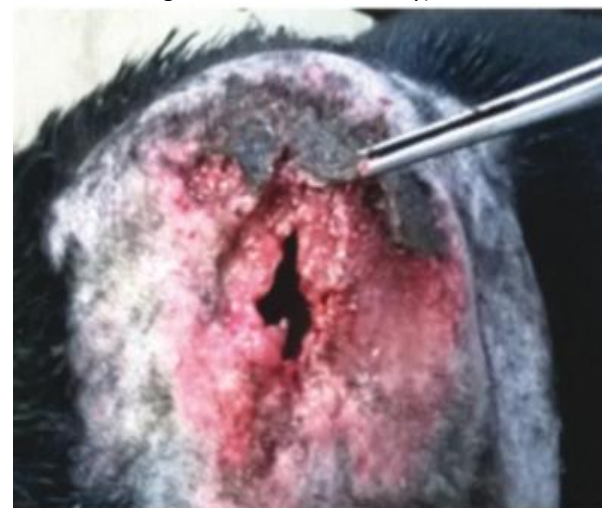**Plate III:** Showing the dog with extensive wound following slough off necrotic area on the third day of presentation



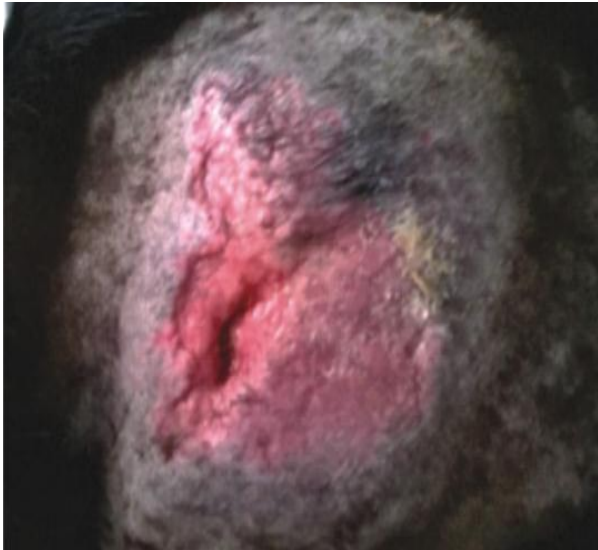
**Plate IV:** Showing contracting and epithelializing wound on day 32 of honey wound dressing (Picture taken with dog on lateral recumbency)



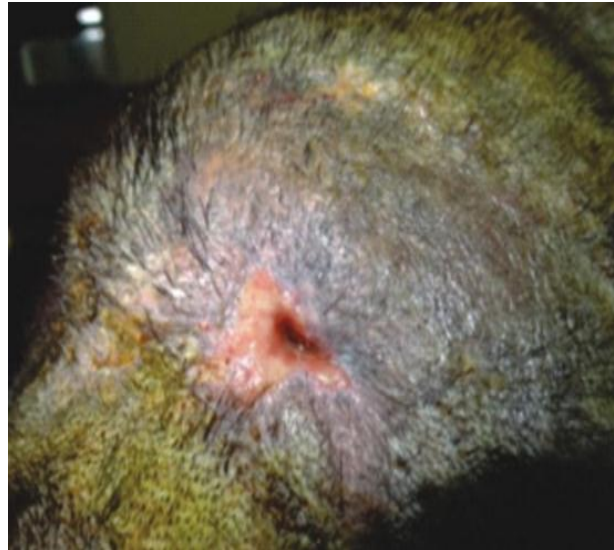
**Plate V:** Showing dog with swollen shoulder with matted coat due to exudation from fluid filled cavity



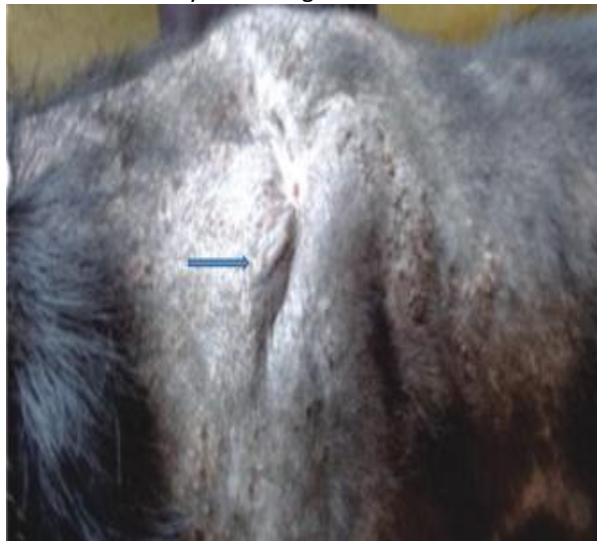**Plate VI:** Showing wound state after shaving and surgical debridement on day 1



**Plate VII:** Showing wound state day 5 following continuous honey dressing



**Plate VIII:** Showing wound state on day 12



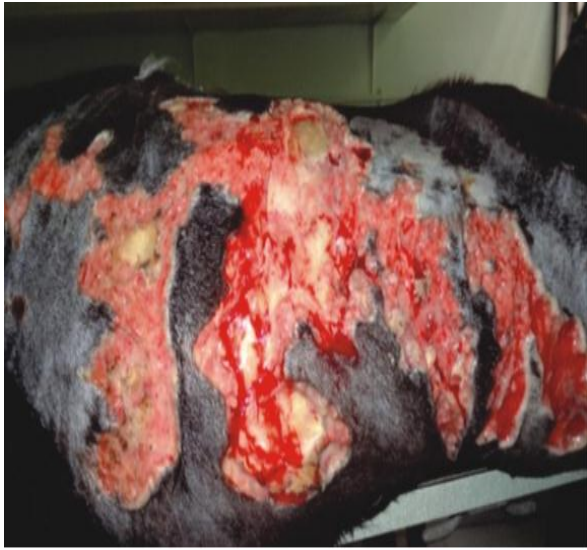**Plate IX:** Showing completely healed wound state on day 18 (Blue arrow)



**Plate X:** Showing extensive 3<sup>rd</sup> degree chemical burn wound with scabs on first day of presentation

Natural unprocessed honey has been in use for medical purpose since ancient times by the Greeks and Egyptians and the same tradition is upheld in the treatment of a broad spectrum of wounds all over the world (Al- Waili, 2003; Al- Waili, 2004a; Al- Waili, 2004b; Al- Waili, 2005; Simon *et al.*, 2009; Molan, 2011). Irradiation of honey because of *Clostridium botulinum* is only precautionary as no case of *Clostridium botulinum* infection associated with honey treatment has been reported (Bell, 2007; Simon *et al.*, 2009). The result that honey was not a priority in the selection of topical wound agent by 66.6% (Table 1) of practitioners surveyed further confirms a previous report that veterinarians are slow to accept and exploit the well-publicised wound healing potentials of bee honey (Mathews &

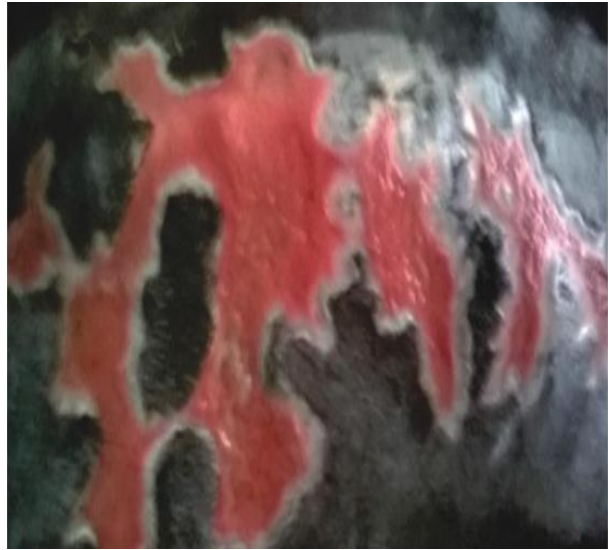Binnington, 2002). Literature has shown that most clinicians resort to use of honey after facing frustration from the inefficacy of other topical agents in management of wound types of varying chronicity (Molan, 2002; Simon *et al.*, 2006; Visavadia *et al.*, 2008; Blaser *et al.*, 2007; Simon *et al.*, 2009). That 72.6% of practitioners surveyed (Table 1) expressed concern about availability of unadulterated honey further strengthens the need for honey branding for medical and surgical use in Nigeria. Such branding has been done in some developed countries (Medi honey, surgi-honey, Activion tube and Manuka honey) (Simon *et al.*, 2009; Lee *et al.*, 2011; Molan & Rhodes, 2015) and has helped to strengthen clinicians' confidence in their efficacy as their sources are well expressed and



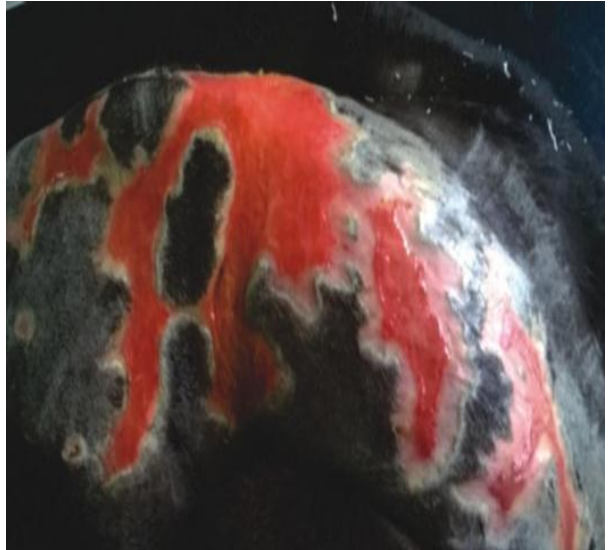**Plate XI:** Showing dog's extensive wound on day 3 of presentation with evidence of honey bandage dressing assisted mechanical debridement

when necessary these sources could be accessed. Nigeria is endowed with rich diversity of ecoflora that could enhance production of honey for medical use. Honey potentials in wound healing has been associated with its multiple bioactive components that help to expedite healing process (Molan & Rhodes, 2015). Honey antibacterial property has been well elucidated in literature (Molan, 2009; Molan, 2011). Its pH is acidic (3.2-4.5) which makes it less favourable to protease activity. Honey's high osmolality is also beneficial to wound healing. Honey's hygroscopic properties make it draw moisture from wound environment and dehydrate bacteria in the process leading to bacterial cell death (Simon *et al.*, 2009; Molan & Rhodes, 2015). In a study where honey was compared with silver sulphadiazine in management of burn wounds, honey showed decreased level for markers of inflammation and malondialdehyde (Subrahmanyam *et al.*, 2001) and reduced number of inflammatory cells.

In case number 1 the efficacy of honey dressing in enhancing mechanical debridement, wound sterilization and tissue regeneration was fully expressed. Honey has been reported to aid wound debridement and tissue regeneration through its immunostimulatory activity on leukocytes leading to rapid phagocytosis and production of cytokines which enhance stimulation and growth of new cells. This immunostimulatory activity of honey has been attributed to various components such as major royal jelly protein-1 (mrjp-1), arabinogalactan, endotoxin contaminant in honey and a substance of molecular weight 5.8 kDa (Majtan, 2014). The same characteristic of honey was expressed in case 2. In



**Plate XII:** Showing impressive progressive state of wound with type 1 collagen, contraction and epithelization on day 16 of honey bandage dressing



**Plate XIII:** Showing futher healing improvement on day 21 of honey bandage dressing

case 3 however, an impressive reduction in wound size and decreased scarring were expressed as the effect of honey; a characteristic previously reported (Subrahmanyam *et al.*, 2001). Honey is a unique natural biologic agent for wound healing. Its impressive outcome in wound management should encourage its embracement by veterinarians in management of animal wounds. Honey has been found to be cheaper and more cost effective for large wounds compared to other conventional dressing agents, (Ingle *et al.*, 2006; Bogdanov *et al.*, 2008). This honey's cost effectiveness should also encourage more veterinarians in Nigeria to embrace its use for their patients' wound management.



## References

- Al-Waili NS (2003). Topical application of natural honey, beeswax and olive oil mixture for atopic dermatitis or psoriasis: partially controlled, single-blinded study. *Complementary Therapies in Medicine*, **11**(4): 226–234.
- Al-Waili NS (2004a). Investigating the antimicrobial activity of natural honey and its effects on the pathogenic bacterial infections of surgical wounds and conjunctiva. *Journal of Medicinal Food*, **7**(2): 210–222.
- Al-Waili NS (2004b). Topical honey application vs. acyclovir for the treatment of recurrent herpes simplex lesions. *Medical Science Monitor*, **1** (8): 94–98.
- Al-Waili NS (2005). Clinical and mycological benefits of topical application of honey, olive oil and beeswax in diaper dermatitis. *Clinical Microbiology and Infection*, **11**(2): 160–163.
- Atiyeh BS, Costagliola M, Hayek SN & Dibo SA (2007). Effect of silver on burn wound infection control and healing: Review of the literature. *Burns*, **33**(2):139–148.
- Bell SG (2007). The therapeutic use of honey. *Neonatal Network*, **26** (4): 247–251.
- Blaser G, Santos K, Bode U, Vetter H & Simon A (2007). Treatment of MRSA-colonized or infected wounds with Medihoney antibacterial honey products. *Journal of Wound Care*, **16** (8): 325–328.
- Bogdanov S, Jurendic T, Sieber R & Gallmann P (2008). Honey for nutrition and health: a review. *Journal American of College of Nutrition*, **27**(6): 677–689.
- Boukraa L & Bouchehrane S (2007). Additive action of honey and starch against *Candida albicans* and *Aspergillus niger*. *Revista Iberoamericana de Micologia*, **24** (4): 309-311.
- Cooper RA, Molan PC & Harding KG (2002). The sensitivity to honey of gram positive cocci of clinical significance isolated from wounds. *Journal of Applied Microbiology*, **93** (5): 857-863.
- De Rooster H & Declercq J (2008). Honey for wound care: myth or science? Part 2: clinical cases with dogs. *Flemish Veterinary Magazine*, **78**:75-80.
- De Rooster H, Declercq J & Van den Bogaert M (2008). Honey for wound care: myth or science? Part 1: literature overview. *Flemish Veterinary Magazine*, **78**: 68-74.
- Dunford C, Cooper R & Molan P (2000). Using honey as a dressing for infected skin lesions. *Nursing Times*, **96** (14): 7-9.
- Eyarefe OD, Alonge TO & Fayemi EO (2011). The incidence of intestinal obstructive diseases in selected veterinary clinics and hospitals in South Western Nigeria. *Nigeria Veterinary Journal*, **32**(1): 36-39.
- Eyarefe OD & Dei D (2014). Retrospective study of prevalence and pattern of surgical conditions presented at the Ashanti Regional Veterinary Clinic, Kumasi, Ghana. *Global Veterinaria*, **13** (3): 408-413.
- Eyarefe OD & Fabiyi BO (2016). Wound healing potentials of aqueous pineapple (*Ananas comosus*) extract- a preliminary report. *Global Journal of Pharmacology*, **10**(1): 23-30.
- Eyarefe OD, Ologunagba FN & Emikpe BO (2014). Wound healing potential of natural honey in diabetic and non-diabetic wistar rats. *African Journal of Biomedical Research*, **17**(1): 15-21.
- Fonder MA, Lazarus GS, Cowan DA, Aronson-Cook B, Kohli AR & Mamelak AJ (2008). Treating the chronic wound: a practical approach to the care of non-healing wounds and wound care dressings. *Journal American Academy of Dermatology*, **58**:185–206.
- Gannabathula S, Skinner MA, Rosendale D, Greenwood JM, Mutukumira AN, Steinhorn G, Stephens J, Krissansen GW & Schlothauer RC (2012). Arabinogalactan proteins contribute to the immunostimulatory properties of New Zealand honeys. *Immunopharmacology and Immunotoxicology*, **34**(4):598-607.
- Gonzalez-Espinosa D, Perez-Romano L, Guzman-Soriano B, Arias E, Bongiovanni CM & Gutierrez AA (2007). Effects of pH-neutral, super-oxidised solution on human dermal fibroblasts in vitro. *International Wound Journal*, **4**(3): 241–250.
- Kramer A, Daeschlein G, Kammerlander G, Andriessen A, Aspöck C, Bergemann R, Eberlein T, Gerngross, Görtz G, Heeg P, Jünger M, Koch S, König B, Laun R, Peter R.U, Roth B, Ruef Ch, Sellmer W, Wewalka G & Eisenbei W (2004). An assessment

- of the evidence on antiseptics: a consensus paper on their use in wound care. *Journal of Wound Care*, **13** (4):1-7.
- Krisztina RI, Niculae M & Bolf P (2007). Honey treatment in veterinary medicine, where to? *Bulletin of University of Agricultural Sciences and Veterinary Medicine Cluj-Napoca. Veterinary Medicine*, **64** (1-2): 521-523.
- Ingle R, Levin J & Polinder K (2006). Wound healing with honey--a randomised controlled trial. *South African Medical Journal*, **96**(9): 831-835.
- Israili ZH (2014). Antimicrobial properties of honey. *American Journal of Therapeutics*, **21**(4): 304-323.
- Lee DS, Sinno S & Khachemoune A (2011). Honey and wound healing: an overview. *American Journal of Clinical Dermatology*, **12**(3):181-190.
- Lipsky BA & Hoey C (2009). Topical antimicrobial therapy for treating chronic wounds. *Clinical Infectious Diseases*. **49**(10): 1541-1549.
- Liptak JM (1997). An overview of the topical management of wounds. *Australian Veterinary Journal*, **75** (6): 408-413.
- Majtan J (2014). Honey: An immunomodulator in wound healing. *Wound Repair and Regeneration*, **22**(2):187-192.
- Majtan J, Kumar P, Majtan T, Walls AF & Klaudivy J (2010). Effect of honey and its major royal jelly protein 1 on cytokine and MMP-9 mRNA transcripts in human keratinocytes. *Experimental Dermatology*, **19** (8): 73-79.
- Mathews KA & Binnington AG (2002). Wound management using honey. *Compendium of Continuing Education for Veterinarians*, **24** (1): 53-60.
- Molan PC (2002). Re-introducing honey in the management of wounds and ulcers - theory and practice. *Ostomy Wound Management*, **48** (11): 28-40.
- Molan PC (2006). The evidence supporting the use of honey as a wound dressing. *International Journal of Lower Extremity Wounds*, **5**(1): 40-54.
- Molan PC (2009). Honey: Antimicrobial actions and role in disease management. In: *New Strategies for Combating Bacterial Infections*. (Ahmad I & Aqil F, editors). Wiley-VCH Verlag GmbH & Co. KGaA, Germany. Pp 229-253.
- Molan PC (2011). The evidence and the rationale for the use of honey as a wound dressing. *Wound Practice and Research*, **19**(4): 204-220.
- Molan P & Rhodes T (2015). Honey- A biologic wound dressing. *Wounds*, **27**(6): 141-151.
- Reddy KV, Yedery RD & Aranha C (2004). Antimicrobial peptides: premises and promises. *International Journal of Antimicrobial Agents*, **24** (6):536-547.
- Simon A, Sofka K, Wiszniewsky G, Blaser G, Bode U & Fleischhack G (2006). Wound care with antibacterial honey (Medihoney) in pediatric hematology-oncology. *Supportive Care in Cancer*, **14** (1): 91-97.
- Simon A, Traynor K, Santos K, Blaser G, Bode U & Molan, P (2009). Medical honey for wound care—still the ‘latest resort’?. *Evidence-Based Complementary and Alternative Medicine*, **6** (2): 165-173.
- Subrahmanyam M, Sahapure AG, Nagane NS, Bhagwat VR & Ganu JV (2001). Effects of topical application of honey on burn wound healing. *Annals of Burns and Fire Disasters*, **14**(3): 143-145.
- Tonks A, Cooper RA, Price AJ, Molan PC & Jones KP (2001). Stimulation of TNF-alpha release in monocytes by honey. *Cytokine*, **14** (4): 240-242.
- Tonks AJ, Cooper RA, Jones KP, Blair S, Parton J, Tonks A (2003). Honey stimulates inflammatory cytokine production from monocytes. *Cytokine*, **21**(5): 242-247.
- Ulvatne H (2003). Antimicrobial peptides: potential use in skin infections. *American Journal of Clinical Dermatology*, **4** (9): 591-595.
- Visavadia BG, Honeysett J & Danford MH (2008). Manuka honey dressing: An effective treatment for chronic wound infections. *British Journal of Oral Maxillofacial Surgery*, **46**(1): 55-56.
- Zumla A & Lulat A (1989). Honey: a remedy rediscovered. *Journal of Royal Society of Medicine*, **82**(7): 384-385.