

Original Article

Modified Laminoplasty for Degenerative Cervical Spondylosis: The Technique of Floating Laminoplasty

Samuel C Ohaegbulam, Wilfred C Mezue, Chika Anele Ndubuisi, Mark O Chikani, Ndubuisi D Achebe, Uwadiogwu A Erechukwu

Department of Neurosurgery,
Memfys Hospital for
Neurosurgery, Enugu, Nigeria

ABSTRACT

Background: Laminoplasty is an established alternative to laminectomy for posterior cervical decompression in spondylotic myelopathy. However, standard laminoplasty requires internal fixation, which is often not obtainable in developing countries. We present our experience with a technique of noninstrumented (floating) laminoplasty developed to avoid the need to anchor the laminoplasty to the anterior elements. **Methods:** We have used floating laminoplasty (FL) for posterior cervical decompression in patients with cervical spondylosis since 2004 and report the technique and our experience with it between 2009 and 2014 when C-arm and magnetic resonance imaging became available in our unit. Patients who had classical laminectomy and hemilaminectomies were excluded. The operation involved bilateral approach to the laminae through a midline incision with generous sparing of the supraspinous, interspinous and interlaminar ligaments. During closure the laminoplasty was hitched to the ligamentum nuchae. Nurick grading was used for clinical evaluation. Patients were followed for at least 1 year. **Results:** There were 36 patients with age range between 32 and 72 years (mean: 56.5 years). Male to female ratio was 3:1. Most patients presented with advanced disease, with 25%, 36%, and 30% at Nurick Grade 3, 4, and 5, respectively. Postoperatively, all (100%) patients with Nurick Grade 2 and 3 improved to Grade 1 or 0, while 9 (69%) of the 13 at Grade 4 improved to Grade 2 or better. Only 1 (9.1%) of 11 operated at Grade 5 did not improve while 3 (27%) improved to Grade 2 or better. No postoperative instability was identified on follow-up. **Conclusion:** FL is a safe and simple procedure that preserves spine stability and minimizes postoperative spinal deformity.

KEYWORDS: Cervical spondylosis, laminoplasty, ligamentous suspension

INTRODUCTION

Laminectomy has long been used for posterior decompression of the spine. The major problem with this is the complication of kyphotic instability and restenosis from formation of a postlaminectomy membrane.^[1] The technique of laminoplasty was first reported in 1973,^[2] and various modifications have since been introduced.^[3-6] The major types include the original Z-plasty, the open door, and the French door (T-saw) laminoplasties.^[7] In its conception, laminoplasty has been argued to require fixation of the lamina-spine complex to maintain decompression, and

this has been achieved by the use of different methods of fixation from suturing with ligature or wires,^[5] to mini plating.^[6] To maintain decompression, it was often necessary to insert spacing with either bone or synthetic ceramics.^[6,8] These various laminoplasty techniques have been shown to be effective over a 5–10 years follow-up period.^[9-12]

Address for correspondence: Dr. Chika Anele Ndubuisi,
Department of Neurosurgery, Memfys Hospital for
Neurosurgery, PO Box 2292, Enugu, Nigeria.
E-mail: chikandu@yahoo.com

This is an open access journal, and articles are distributed under the terms of the Creative Commons Attribution-NonCommercial-ShareAlike 4.0 License, which allows others to remix, tweak, and build upon the work non-commercially, as long as appropriate credit is given and the new creations are licensed under the identical terms.

For reprints contact: reprints@medknow.com

How to cite this article: Ohaegbulam SC, Mezue WC, Ndubuisi CA, Chikani MO, Achebe ND, Erechukwu UA. Modified laminoplasty for degenerative cervical spondylosis: The technique of floating laminoplasty. *Niger J Surg* 2018;24:1-5.

| Access this article online | |
|--|--|
| Quick Response Code:  | Website: www.nigerianjsurg.com |
| | DOI: 10.4103/njs.NJS_12_17 |

Unfortunately, spacing and miniplate application are not easily available in the poorer economies. It is however in these settings that the cost of management of instability is prohibitive. We adopted a technique of fixing the laminoplasty to posterior structures with sutures. This modification can easily be used in circumstances where facilities such as high-speed drill and miniplates are not readily available.

We report our experience and follow-up results with this technique of noninstrumented floating laminoplasty (FL) that achieves decompression of the cord without destabilization of the spine.

METHODS

Consecutive cases of degenerative cervical spondylosis treated with FL between 2009 and 2014. Patients who had classical laminectomy and those who had hemilaminectomies were excluded. Also excluded were cases done before 2009 when magnetic resonance imaging (MRI) and C-arm became available in our center. The operation involved a modification of classical laminoplasty aimed at avoiding instrumentation. The laminae were approached bilaterally through a midline incision with generous sparing of the supraspinous, interspinous and interlaminar ligaments. Nurick grading [Table 1] was used for clinical evaluation. All had MRI and some also had computed tomography (CT) as part of diagnostic workup. Follow-up was over a minimum period of 1 year using both clinical (Nurick grading) and radiological (CT and/or MRI) assessment. Complete clinical assessment at 1 year was obtained in the 36 patients.

The surgical technique

Patients received general anesthesia with endotracheal intubation on a trolley before being positioned prone on a Montreal mattress with the usual precautions. We routinely give perioperative 1 g of ceftriaxone at induction of anesthesia and repeat 12 hourly postoperatively for 72 h. The neck was maintained in neutral or slightly flexed position and the table tilted up to approximately 30° Trendelenburg, bringing the neck to horizontal alignment. The usual protocols of skin preparation and draping are performed before a midline skin incision is made. Dissection is continued strictly in the midline to minimize bleeding. We prefer to use surgical scalpel rather than monopolar diathermy dissection for the approach. A careful subperiosteal dissection of the paraspinal muscles is done with meticulous and generous sparing of the supra- and interspinous ligaments and the ligament flavum.

The muscles are retracted away from the midline to expose the laminae of interest. Exposure is continued laterally to delineate the lateral groove between the lamina and the lateral mass. We then minimally open the ligamentum flavum laterally to gain access and cautiously nibble a wedge of laminae bilaterally using low profile Kerrison punch (2 mm bite). This stage of the operation is more easily and expeditiously performed with the aid of high-speed drill, which we have used since 2010 [Figure 1]. The laminae are carefully freed from the underlying dura using McDonald's dissectors while lifting the laminoplasty segment. Any previously noted foraminal narrowing is now decompressed, care being taken to avoid destabilizing the facet joint. The laminae and spinous segments are lifted upward as a unit supported at the cranial and distal limits by ligamentum flavum. This provides surprising free access because of tenting by the ligamentum flavum especially at both limits of the target levels.

Following satisfactory decompression, a figure of eight suture using size two prolene or nylon is passed through the interspinous ligaments, around the spinous process and through the ligamentum nuchae at the cranial, central and caudal limits of the laminoplasty [Figure 2]. It may be necessary sometimes to pass the suture directly through the spinous process after drilling a hole, or under the lamina. For long segments, additional hitch sutures may be necessary. These hitch sutures are tied only after approximating the muscle. A drain may or may not be placed over the laminae at this time, and the muscles are gently and loosely apposed through the interspinous ligaments with size 2-0 vicryl. The laminoplasty unit is then anchored by tying the figure of eight sutures above the ligamentum nuchae, suspending the laminoplasty away from the canal [Figure 2]. Additional vicryl 2 suture may be used to repair the ligamentum nuchae layer. The wound is closed with 2-0 vicryl to subcutaneous tissue and 2-0 nylon or clips to skin. Intraoperative C-arm is used to assess the achieved degree of decompression. Patients are advised to use hard collar for 1 week.

All patients who could afford it had postoperative CT before discharge to measure the level of decompression. Imaging is repeated at 1 year follow-up.

RESULTS

There were 36 patients with age range between 32 and 72 years (mean: 56.5 years). The male to

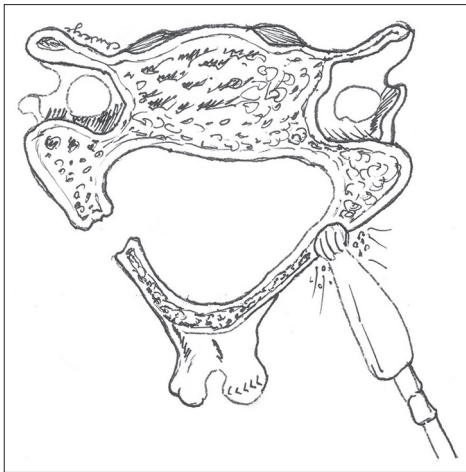


Figure 1: Drill assisted laminectomy along the lamina-facet groove. Laminectomy is already completed on the left side

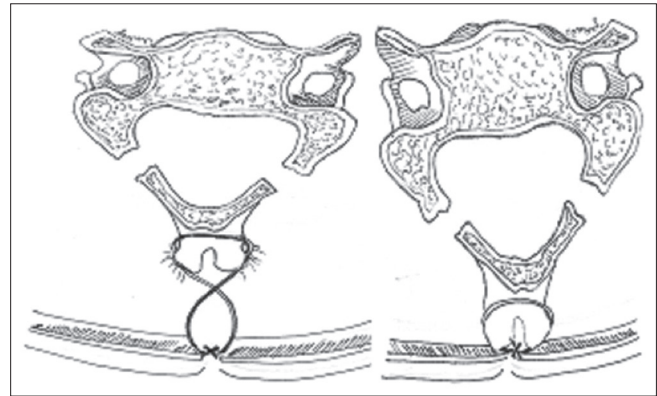


Figure 2: Drawing demonstrating the figure of 8 non-absorbable suture during (left) and at completion (right) of hitching of the laminoplasty unit to the ligamentum nuchae.

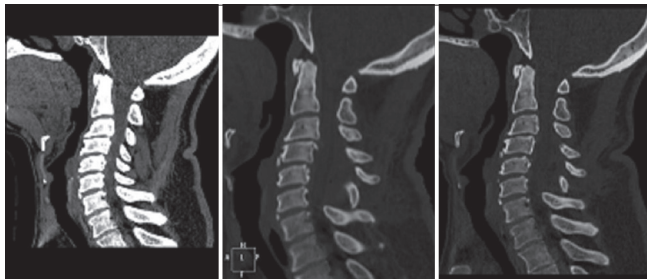


Figure 3: Serial computed tomography scans of a patient preoperative (right), immediate postoperative (center) and at 1 year follow-up (left)

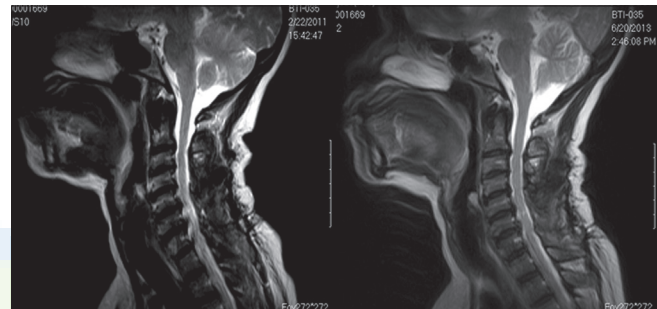


Figure 4: Pre- and post-operative magnetic resonance imaging scan following floating laminoplasty

female ratio was 3:1 [Table 2]. The technique of FL was used in all cases. All patients presented with advanced disease, with 25%, 36%, and 30% at Nurick Grade 3, 4, and 5, respectively [Table 3]. There were no significant perioperative complications. One year postsurgery, all patients with Nurick Grade 2 and 3 improved to Grade 1 or 0, while 9 (69%) of the 13 at Grade 4 improved to Grade 2 or better. Only 1 (9.1%) of 11 operated at Grade 5 did not improve while 3 (27%) improved to Grade 2 or better [Table 3]. This improvement was sustained at 5 years in the 19 patients that were followed for the duration [Table 4]. No postoperative instability was identified on follow-up.

Immediate postoperative CT scan in nine patients showed satisfactory decompression [Figure 3]. Postoperative MRI, in twenty patients who could afford imaging, at 1 year and in 19 patients followed for 5 years showed good decompression without evidence of collapse of the laminoplasty. One patient showed evidence of adjacent level degeneration at the lower level of surgery at 5 years without

| Grade | Description |
|-------|--|
| 0 | Root signs or symptoms. No evidence of spinal cord disease |
| 1 | Signs of spinal cord disease but no walking difficulty |
| 2 | Slight walking difficulty. Able to be employed |
| 3 | Difficulty in walking prevents employment |
| 4 | Able to walk but requiring someone's assistance or a frame |
| 5 | Chair bound or bedridden |

| Age (years) | Number (%) |
|-------------|------------|
| 1-30 | Nil |
| 31-40 | 1 (2.8) |
| 41-50 | 5 (13.9) |
| 51-60 | 16 (44.4) |
| 61-70 | 10 (27.8) |
| 71-80 | 4 (11.1) |
| Total | 36 (100.0) |

Range: 32-72 years, Mean age=56.5 years, Male:female=3:1

clinical deterioration, and one had a persisting kyphotic deformity. There was no evidence of restenosis [Figure 4].

Table 3: Clinical presentation and discharge outcome using Nurick grading

| NG on presentation (n=36) | | One year postdischarge outcome (n=36) | | | | | |
|---------------------------|--------------------|---------------------------------------|---|---|---|---|---|
| | | Number of patients per NG | | | | | |
| Grade | Number of patients | 0 | 1 | 2 | 3 | 4 | 5 |
| 2 | 3 | 2 | 1 | | | | |
| 3 | 9 | 3 | 6 | - | - | - | - |
| 4 | 13 | 2 | 5 | 2 | 4 | - | - |
| 5 | 11 | - | 2 | 1 | 5 | 2 | 1 |

NG: Nurick grade

Table 4: Five-year follow-up outcome in 19 patients

| NG | Preoperative (%) | Postoperative of 5 years (%) |
|---------------|------------------|------------------------------|
| 0 | Nil | 2 (10.5) |
| 1 | Nil | 7 (36.8) |
| 2 | 2 (10.5) | 3 (15.8) |
| 3 | 4 (21.1) | 6 (31.6) |
| 4 | 9 (47.3) | 1 (5.3) |
| 5 | 4 (21.1) | Nil |
| Average score | 3.8 | 1.8 |

NG: Nurick grade

DISCUSSION

The initial clinical outcome in patients who had FL is comparable to that for laminectomy and laminoplasty in the literature.^[13,14] Heller *et al.* in a comparison of clinical and radiological outcomes in matched groups using the Nurick score showed a tendency toward a better outcome in laminoplasty group.^[15] Significantly, they were able to show that complications were more commoner in the laminectomy group. They concluded that laminoplasty was more reliable and safer than laminectomy. Our series revealed that all patients that presented at Grade 3 of the disease improved to Grade 1 or 0 with the procedure and that recovery was least in patients with Nurick Grade 5, confirming that early intervention is necessary to achieve the good clinical outcome. This emphasizes the importance of full clinical and radiological assessment and early referral of patients. Cord atrophy from long-standing pressure or ischemia manifesting as established signal change in MRI also indicates poor outcome^[16] and is present in most patients with Nurick Grade 5.

We did not select patients based on age. Age over 60 years and the extent and duration of neurological deficits before operative intervention are considered important determinants of outcome postoperatively. Some studies, however, did not find any statistical difference between patients over age 70 and a control group of patients under 69 years of age using Japanese Orthopedic Association scores.^[11,12,17] In their study, Kaminsky *et al.* found that only the extent of disease influenced postoperative

outcome in both laminectomy and laminoplasty.^[14]

Progression of myelopathy, development of kyphotic alignment and adjacent segment degeneration are consistently reported with laminectomy for cervical spondylotic myelopathy.^[18] These complications are less common with laminoplasty. It has been shown that following laminoplasty the cord migrates away from the anterior vertebral bodies.^[19,20] We did not note any subsequent narrowing of the canal on further imaging [Figure 4] and late postoperative deterioration was absent in our patients. Although follow-up has not been long enough and all patients did not have MRI, the incidence of adjacent level degeneration was low at 5%. Similar low incidence for adjacent level degeneration has been reported for laminoplasties compared with laminectomies.^[15] This correlates with the lower incidence of spinal instability and may be related to less extensive bone removal.

Compared to the classical laminectomy technique, FL relatively preserves the anatomy of the spine and obviates the need for fusion of the spine segments. Fusion, which may be needed in some cases following classical laminectomy, results in subsequent degenerative cascade at the adjacent nonfused spinal segments.^[21] In our environment and in other developing countries where the cost of implants for fusion may significantly affect the overall cost of surgery, this preservation of the anatomy has a cost reduction implication. It also reduces the risk of iatrogenic neurological injuries associated with the procedure of spine fusion. FL limits the lateral extent of laminectomies and is relatively simple and safe. Although high-speed drill is desirable and facilitates the bone removal, it is not essential. Low profile Kerrison punches are adequate for the procedure.

Compared to other types of laminoplasty FL provides the advantage of avoiding the use of spacers and internal fixation and thus has the potential of reducing operating time and risk of infection. In keeping with the finding that canal expansion is maximal on the open side in hinge type and the midline in bilateral hinge laminoplasties,^[22] FL may combine the advantages of both. The major concern that the suspended laminoplasty will not be maintained in position and could cause cord compression was not sustained. We have attributed this to meticulous anchoring of the laminoplasty to the dense ligamentum nuchae and the paraspinal muscles. There is the possibility that early mobilization without need for long-term collar support produces an outward spring effect on the laminoplasty. Obviously, longer term follow-up and more detailed studies are necessary to fully evaluate the technique. We are currently comparing the results of this technique

with the results of classical laminectomy from the series of the first author, and it is hoped that wider based comparative studies with other techniques will be forthcoming.

The study is limited by its retrospective nature and the relatively short duration and incompleteness of follow-up. In previous studies from the literature, postlaminectomy membranes and subsequent deterioration from further stenosis are a late phenomenon.

CONCLUSION

FL is a safe and simple procedure that preserves the stability of the spine and minimizes postoperative spinal deformity. This technique is especially adapted for cost-effectiveness without sacrificing quality.

Financial support and sponsorship

Nil.

Conflicts of interest

There are no conflicts of interest.

REFERENCES

- Nishizawa K, Mori K, Saruhashi Y, Matsusue Y. Operative outcomes for cervical degenerative disease: A review of the literature. *ISRN Orthop* 2012;2012:165050.
- Oyama M, Hattori S, Moriawski N. A new method of cervical laminectomy. *Chubu Seisei Shi* 1973;16:792-4.
- Edwards CC 2nd, Heller JG, Silcox DH 3rd. T-Saw laminoplasty for the management of cervical spondylotic myelopathy: Clinical and radiographic outcome. *Spine (Phila Pa 1976)* 2000;25:1788-94.
- Hirabayashi K, Watanabe K, Wakano K, Suzuki N, Satomi K, Ishii Y. Expansive open-door laminoplasty for cervical spinal stenotic myelopathy. *Spine (Phila Pa 1976)* 1983;8:693-9.
- Itoh T, Tsuji H. Technical improvements and results of laminoplasty for compressive myelopathy in the cervical spine. *Spine (Phila Pa 1976)* 1985;10:729-36.
- O'Brien MF, Peterson D, Casey AT, Crockard HA. A novel technique for laminoplasty augmentation of spinal canal area using titanium miniplate stabilization. A computerized morphometric analysis. *Spine (Phila Pa 1976)* 1996;21:474-83.
- Patel CK, Cunningham BJ, Herkowitz HN. Techniques in cervical laminoplasty. *Spine J* 2002;2:450-5.
- Hase H, Watanabe T, Hirasawa Y, Hashimoto H, Miyamoto T, Chatani K, *et al.* Bilateral open laminoplasty using ceramic laminas for cervical myelopathy. *Spine (Phila Pa 1976)* 1991;16:1269-76.
- Kawai S, Sunago K, Doi K, Saika M, Taguchi T. Cervical laminoplasty (Hattori's method). Procedure and follow-up results. *Spine (Phila Pa 1976)* 1988;13:1245-50.
- Saruhashi Y, Hukuda S, Katsuura A, Miyahara K, Asajima S, Omura K. A long-term follow-up study of cervical spondylotic myelopathy treated by "French Window" laminoplasty. *J Spinal Disord* 1999;12:99-101.
- Satomi K, Nishu Y, Kohno T, Hirabayashi K. Long-term follow-up studies of open-door expansive laminoplasty for cervical stenotic myelopathy. *Spine (Phila Pa 1976)* 1994;19:507-10.
- Seichi A, Takeshita K, Ohishi I, Kawaguchi H, Akune T, Anamizu Y, *et al.* Long-term results of double-door laminoplasty for cervical stenotic myelopathy. *Spine (Phila Pa 1976)* 2001;26:479-87.
- Hukuda S, Ogata M, Mochizuki T, Shichikawa K. Laminectomy versus laminoplasty for cervical myelopathy: Brief report. *J Bone Joint Surg Br* 1988;70:325-6.
- Kaminsky SB, Clark CR, Traynelis VC. Operative treatment of cervical spondylotic myelopathy and radiculopathy. A comparison of laminectomy and laminoplasty at five year average follow-up. *Iowa Orthop J* 2004;24:95-105.
- Heller JG, Edwards CC 2nd, Murakami H, Rodts GE. Laminoplasty versus laminectomy and fusion for multilevel cervical myelopathy: An independent matched cohort analysis. *Spine (Phila Pa 1976)* 2001;26:1330-6.
- Bohlman HH, Emery SE. The pathophysiology of cervical spondylosis and myelopathy. *Spine (Phila Pa 1976)* 1988;13:843-6.
- Kawaguchi Y, Kanamori M, Ishihara H, Ohmori K, Abe Y, Kimura T. Pathomechanism of myelopathy and surgical results of laminoplasty in elderly patients with cervical spondylosis. *Spine (Phila Pa 1976)* 2003;28:2209-14.
- Hale JJ, Gruson KI, Spivak JM. Laminoplasty: A review of its role in compressive cervical myelopathy. *Spine J* 2006;6 6 Suppl: 289S-98S.
- Aita I, Hayashi K, Wadano Y, Yabuki T. Posterior movement and enlargement of the spinal cord after cervical laminoplasty. *J Bone Joint Surg Br* 1998;80:33-7.
- Sodeyama T, Goto S, Mochizuki M, Takahashi J, Moriya H. Effect of decompression enlargement laminoplasty for posterior shifting of the spinal cord. *Spine (Phila Pa 1976)* 1999;24:1527-31.
- Hilibrand AS, Carlson GD, Palumbo MA, Jones PK, Bohlman HH. Radiculopathy and myelopathy at segments adjacent to the site of a previous anterior cervical arthrodesis. *J Bone Joint Surg Am* 1999;81:519-28.
- Steinmetz MP, Resnick DK. Cervical laminoplasty. *Spine J* 2006;6 6 Suppl: 274S-81S.