

Short communication

A case of miliary tuberculosis in a Holstein Friesian dairy cow, Mekelle, Tigray, Ethiopia

Abreha T. Genzebu, Habtamu T. Menghistu*, and Yohannes H. Weldearegay

Mekelle University, College of veterinary Medicine, P. O. Box 1436, Mekelle, Ethiopia

*Corresponding author email: hbtmtaddele@gmail.com or menghistu.taddele@mu.edu.et

Abstract

We report a case of miliary tuberculosis (TB) found in one of the commercial dairy farms in Mekelle, Tigray, Ethiopia. The case history of the cow indicated weight loss, emaciation and chronic cough. Antibiotic treatment was not successful and there was also repeated death of cows in the farm. Postmortem (PM) examination showed tuberculous lesions in the lung, liver, mediastinal lymphnodes, mesenteric lymphnodes, pleural cavity, reproductive tract, lymphnodes of the head and bone marrow suggesting miliary form of TB. This was confirmed by bacteriological examination and histopathology. The farm where the present case was reported is one of the dairy farms in Mekelle city that supplies milk to the community. As the pasteurization facility is weak in the area, it is suspected that this farm may serve as one of the major transmitters of TB in humans. The lack of control policy in the country worsens the occurrence and spread of TB in animals. In this case, the owner of the Farm was advised to conduct tuberculin skin testing and segregate TB positive cows. Moreover, the owner was advised that it is advantageous to slaughter the reactors under the supervision of the local veterinarian so as to reduce spread of bovine TB in the farm.

Keywords: Bovine tuberculosis; Dairy cattle; Exotic; Mekelle; Miliary TB

Introduction

Ethiopia has one of the largest cattle populations in Africa, with an economy highly dependent on its livestock. To improve nutrition and food security, the Ethiopian government is trying to increase milk production with an intensive breeding programme to increase the number of exotic (Holstein) dairy cattle that produce more milk than indigenous breeds (Shapiro *et al.*, 2015). Evi-

dence indicates that the *Bostaurus* breeds are more susceptible to bovine TB than zebu cattle (Ameni *et al.*, 2003a). Moreover, intensification of the farming system aggravates the spread of the infection (Ameni *et al.*, 2006). Therefore, the programme of increasing milk yield by introducing Holstein breed can be affected by increasing incidence of bovine TB.

Most of the surveys carried out in Ethiopia have been based on tuberculin skin testing and abattoir inspection. Among the recently undertaken studies, the prevalence rate of bovine TB ranges from 3.4% in a small holder production system to 50% in intensive dairy productions in various regions of the country (Ameni and Roger, 1998; Asseged *et al.*, 2000; Ameni *et al.*, 2003a,b). In Ethiopia, due to the growing population which resulted in an increase in milk demand, intensive dairy cattle production systems with exotic breeds are emerging. However, the exotic breeds are more susceptible to diseases like bovine TB than the zebu breed and the presence of bovine TB in a small scale intensive farm has a detrimental effect on the economy and sustainability of the farm. Therefore, the economic loss due to bovine TB in these farms is very high as the exotic breeds are very expensive. In this paper we report a case of miliary tuberculosis found in one of the commercial dairy farms in Mekelle, Tigray, Ethiopia.

Case history

Since one of the missions of Mekelle University, College of Veterinary Medicine, is providing community and consultancy services to the public in the Region, the College has close interaction with the commercial dairy and poultry farmers. On May 25, 2010 the College received a phone call from one of the dairy farms requesting to perform a postmortem examination on one dairy cow. A Holestein Fresian dairy cow aged around 10 years has suffered from a chronic illness. The clinical history of the cow shows chronic coughing, emaciation, decline in appetite and decreased milk production. It has received antibiotic treatment several times but was not successful. Additionally, the clinical history and health management of the herd was assessed. Repeated death of dairy cows after chronic coughing and emaciation was reported by the farmer.

Postmortem findings, acid fast staining and histopathological examination

Postmortem examination of the dairy cow was conducted and showed tuberculous lesions in the lung, liver, mediastinal lymphnodes, mesenteric lymphnodes, pleural cavity, reproductive tract, lymphnodes of the head and bone marrow. Disseminated miliary TB was noted as depicted in Figure 1.



Figure 1. An incised mediastinal lymph node showing tubercle with calcified caseous exudates

Typical tubercle lesion was found in the mediastinal lymphnode. The lung contains multiple coalescing foci of caseous necrosis surrounded by thin pale fibrous tissue capsules (tubercles) (Figure 2).

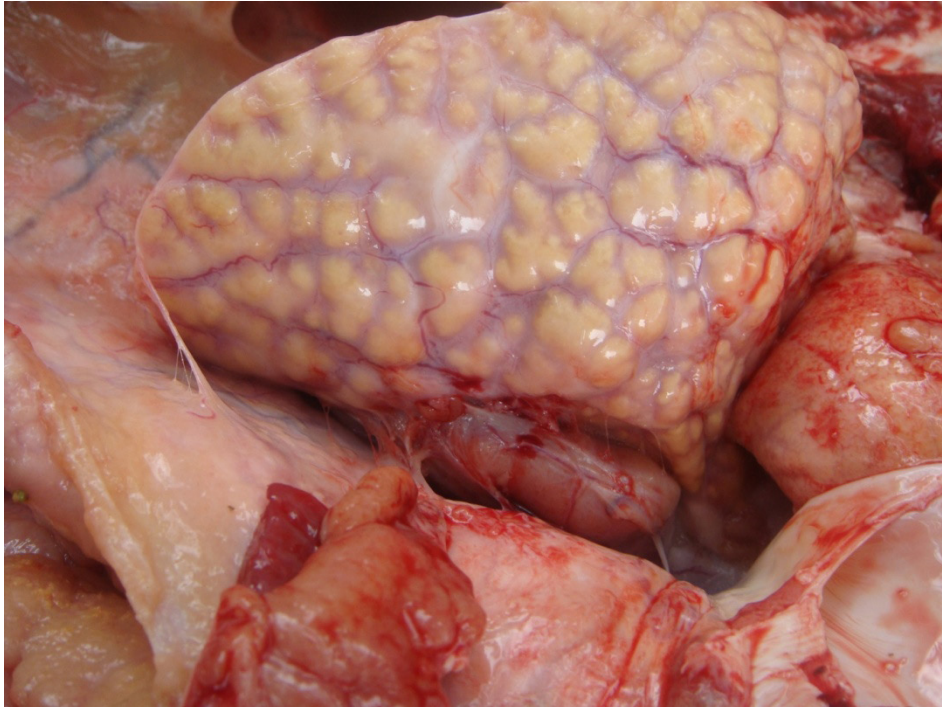

Figure 2. Extensively affected lung tissues with diffuse pus and tubercle lesions as well as adhesion to the pleural cavity due to fibrinous inflammation

When the lung was dissected very thick pus and the tubercles were observed. The pleural cavity was full of pale fibrous tissue capsules (tubercles) (Figure 3). The bone marrow was also found full of pus. In the present case, pulmonary involvement was highly pronounced (that is, the whole lung tissue was affected significantly). In addition, granulomatous lesions were found widely spread in the peritoneum, mesentery, liver, kidneys, intestines and mesenteric lymph nodes.

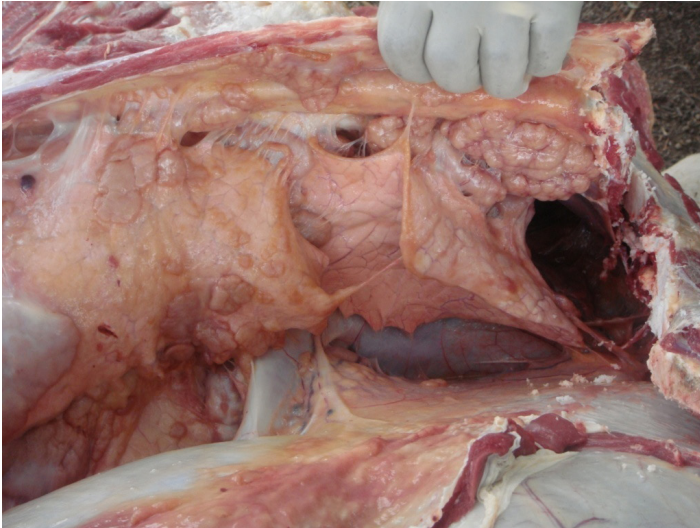


Figure 3. Pleural cavity full of fibrous tissue capsules (tubercles) that led to adhesion with the lung tissue and other associated structures.

Pus from the intestines and smear from the granulomatous lesions were collected and examined for detection of acid fast bacilli. Acid-fast bacteria typical of mycobacteria were detected in the smear samples. Tissue samples from tuberculosis lesions from different tissues were processed, sectioned and stained following standard histological technique (Bancroft *et al.*, 1988). Microscopic examination of hematoxylin and eosin stained slides revealed granulomatous inflammation, with epithelioid cells surrounding the central necrotic area, lymphocyte infiltration, giant (multinucleated) cells at periphery and fibrous encapsulation (Figures 4 and 5).

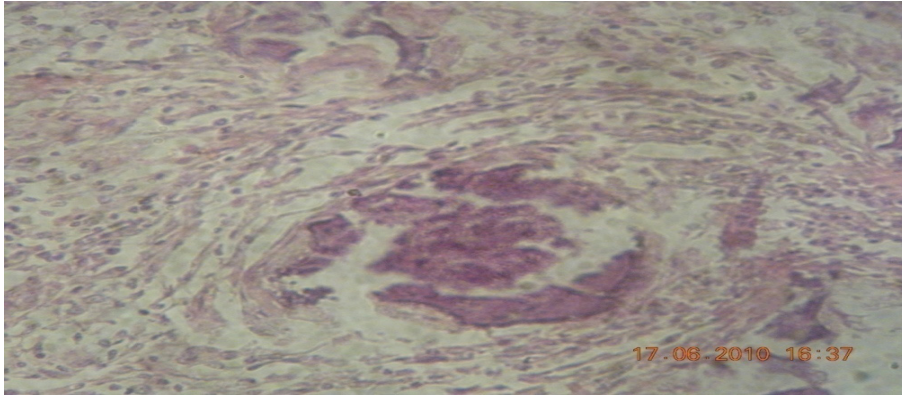


Figure 4. Hematoxylin and Eaosin stain of lung tissue under low magnification (x10) showing necrotic tissue center surrounded by epithelioid cells, an indication of granulomatous inflammation

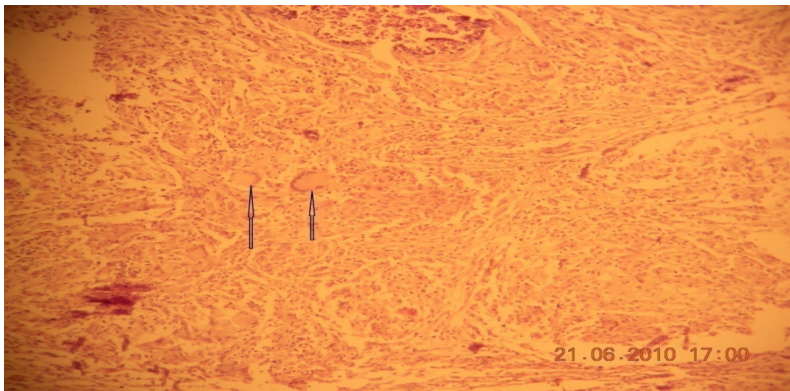


Figure 5. Hematoxylin and eosin stain of lung tissue (x40 magnification) showing giant (multinucleated cells) indicated with arrows.

Discussion

Bovine TB is a chronic infectious disease of animals characterized by the formation of granulomas in tissues and organs, more significantly in the lungs, lymph nodes, intestine and kidney including others. In many countries, TB in

animals, generally due to infection with *M. bovis*, is of significant economic and zoonotic importance (O'Reilly and Daborn, 1995; Cousins and Dawson, 1999).

The predominant clinical sign in the present case was severe emaciation and weight loss. The owner also reported for repeated cases of emaciation, weight loss and coughing in the previous years. This suggests that aerosol transmission of the disease from infected cows to the healthy ones. This is basically facilitated due to confinement of animals and lack of regular testing and isolation of infected animals. As differential diagnosis John's disease and deficiency of trace elements (Selenium/vitamin E) were suspected as ill-thrift and weight loss is a feature of each of this conditions. However, the absence of diarrhea, postmortem findings and laboratory results helped us to exclude John's disease and selenium/vitamin E deficiency (Radostits *et al.*, 2000). Tentative diagnosis of TB on the basis of clinical signs was confirmed using post mortem examination, with confirmatory bacteriology and histopathology tests. The widespread distribution of tubercle bacilli in different organs and tissues like lung, liver, mediastinal lymphnodes, mesenteric lymphnodes, pleural cavity, reproductive tract, lymphnodes of the head and bone marrow confirmed miliary form of TB.

Cases of TB in cattle due to *M. bovis* are more common than any other animal species. The disease is more significant in exotic breed than the zebu breed (Ameni *et al.*, 2006). The repeated death of exotic cows in this farm is an indication for the economic importance of the disease. The zoonotic importance of the disease is also of significant value as there is report of *M. bovis* cases in humans in the country (Kidane *et al.*, 2002). In countries where BTB in cattle is still prevalent and where pasteurization is not widely practiced, usually about 10% to 15% of human TB is considered to be caused by BTB (Ashford *et al.*, 2001).

Conclusion

BTB is an endemic disease that has long been documented in Ethiopia. The incidence of the disease is higher in intensive dairy farms and exotic breeds. The farm where the present case was reported is one of the dairy farms in Mekelle City that supplies milk to the community. As the pasteurization facility is weak in the area, it is suspected that this farm may serve as one of the major transmitters of TB in humans. Thus, the observation of a case of miliary TB in a dairy cow substantiates the previous reports of high prevalence of BTB in

dairy farms in the country and warrants for the attention to seek for an applicable control strategy.

Acknowledgements

The authors acknowledge Mekelle University, College of Veterinary Medicine for provision of material support for the case investigation.

Conflict of interest

The authors declare that there is no conflict of interest.

References

- Shapiro, B.I., Gebru, G., Desta, S., Negassa, A., Nigussie, K., Aboset, G. and Mechal, H., 2015. Ethiopia Livestock Master Plan. ILRI Project Report. International Livestock Research Institute (ILRI), Nairobi, Kenya.
- Ameni, G., Amenu, K. and Tibbo, M., 2003a. Bovine tuberculosis: prevalence and risk factors assessment in cattle and cattle owners in Wuchale-Jida district, Central Ethiopia. *Int. J. Appl. Res. Vet. Med.*, 1, 17–25.
- Ameni, G., Aseffa, A., Engers, H., Young, D., Hewinson, G. and Vordermeier, M., 2006. Cattle husbandry in Ethiopia is a predominant factor for affecting the pathology of bovine tuberculosis and gamma interferon responses to mycobacterial antigens. *Clin. Vaccine Immunol.*, 13, 1030–1036.
- Ameni, G., Bonner, P. and Tibbo, M., 2003b. Across-sectional study of bovine tuberculosis in selected dairy farms in Ethiopia. *Int. J. Appl. Res. Vet. Med.*, 1, 85–97.
- Ameni, G., and Roger, F., 1998. Study on the epidemiology of bovine tuberculosis in dairy farms (Debre-Zeit and Ziway, Ethiopia). In: Proceedings, the 12th Conference of the Ethiopian Veterinary Association (EVA), Addis Ababa, Ethiopia, Pp. 13–19.
- Ashford, D.A., Whitney, E., Raghunathan, P. and Cosivi, O., 2001. Epidemiology of selected mycobacteria that infect humans and other animals. Office International des Epizooties, *Rev. Sci. Tech.*, 20, 325–337.
- Bancroft, J.D., Harry, C.C. and David, R.T., 1988. Manual of Histological Techniques. Churchill Livingstone.
- Bogale, A., Lubke-Beker, A., Lemma, E., Kiros, T. and Britton, S., 2000. Bovine tuberculosis: A cross sectional and epidemiological study in and around Addis Ababa. *Bull. Anim. Health. Prod. Afr.*, 48, 71–80.

- Cousins, D.V. and Dawson,D.J.,1999. Tuberculosis due to *Mycobacterium bovis* in the Australian population: cases recorded during 1970-1994. *Int. J.Tuberc. Lung Dis.*, 3, 715-721.
- Kidane, D., Olobo, J.O.,Habte, A.,Negesse, Y., Aseffa, A.,Abate, G.,Yassin, M.A.,Bereda, K.andHarboe,M.,2002. Identification of the causative organism of tuberculosis lymphadenitis in Ethiopia by PCR. *J. Clin. Microbiol.*, 40, 4230–4234.
- O'Reilly, L.M. and Daborn, C.J.,1995. The epidemiology of *Mycobacterium bovis* infections in animals and man: A review. *Tubercle Lung Dis.*,76(1),1-46.
- Radostits, O.M., Gay, C.C., Blood,D.C. and Hinchelift, K. W., 2000. Disease caused by bacteria *Mycobacterium*. In: *Veterinary Medicine: A Text Book of Disease of Cattle, Sheep, Pig, Goat and Horses*. 9thed, Harcourt Publisher Ltd., London,Pp 909–918