

Securing the mucocutaneous anastomosis in the repair of low-anorectal anomalies

Amr A. AbouZeid

Purpose The aim of this study was to identify the incidence of wound complications after a limited sagittal anorectoplasty for the repair of rectoperineal fistula.

Patients and methods Between January 2011 and December 2014, patients with rectoperineal fistula treated primarily by a limited sagittal anorectoplasty were included. The patients in the study were divided into two groups according to the extent of rectal dissection and mobilization during the operation.

Results Thirty-six consecutive patients with rectoperineal fistula were included (28 girls and eight boys). Their mean age was 10 months (range 3–42 months). The overall incidence of postoperative wound dehiscence was 22.2% (eight patients). In the first group (limited rectal mobilization), there was a high incidence of wound complications (6/15 patients). Five patients were considered to have a major dehiscence and four required a rescue colostomy. In the second group (extended rectal mobilization, 21 patients), two had minor dehiscence that were managed conservatively. The overall incidence of

wound complications was significantly lower in the second group (Mann–Whitney test, $P=0.04$).

Conclusion Among the patients with rectoperineal fistula, extension of the dissection and mobilization of the rectum from the anterior structures (vagina in girls, and bulpospongiosum in boys) decreases wound dehiscence following a limited sagittal anorectoplasty procedure. *Ann Pediatr Surg* 11:185–191 © 2015 Annals of Pediatric Surgery.

Annals of Pediatric Surgery 2015, 11:185–191

Keywords: anterior ectopic anus, imperforate anus, low-anorectal anomalies, rectoperineal fistula, sagittal anorectoplasty

Department of Pediatric Surgery, Faculty of Medicine, Ain Shams University, Cairo, Egypt

Correspondence to Amr A. AbouZeid, MD, Lotefy El-Sayed Street, 9 Ain Shams University Buildings, Abbassia, 11657 Cairo, Egypt
Tel: +20 111 656 0566; fax: +20 224 830 833;
e-mail: amrabdelhamid@hotmail.com

Received 16 February 2015 accepted 17 June 2015

Introduction

Anorectal anomalies are a common pediatric surgical problem with a diverse spectrum and several successive classifications [1]. At one end of the spectrum, low anomalies or the ‘minor forms’ constitute about half of the cases [2]. Recently, ‘rectoperineal’ or ‘rectocutaneous’ fistula has been proposed as one term standing for most of these low anomalies in both sexes [3].

Despite being considered as a minor form of the disease, there is no consensus on the management protocol of rectoperineal fistula. Treatment protocols vary from no treatment to anal dilatation, simple anoplasties (cutback, Y-V plasty), and lastly the more extensive sagittal anorectoplasties [4]. The ‘cutback’ procedure is a simple technique achieving good function (regarding constipation, which is the major problem among these patients) [5]; however, there are many concerns about the poor cosmetic appearance of the perineum and vestibular contamination in girls [6]. Posterior sagittal anorectoplasty, which has been invented by Peña and DeVries [7] for the repair of high anorectal anomalies, has been applied successfully (in a limited form of the procedure) for the repair of rectoperineal fistula with the advantage of repositioning of the neoanus backwards in the center of the muscle complex. However, the latter technique carries the risk of major wound dehiscence that may necessitate temporary fecal diversion (colostomy), which may be considered as a high price for such a minor form of the anomaly [4,8,9].

Most of the reports in the literature are concerned with the repair of the more challenging higher anorectal anomalies [4]. In this report, we aim to address the

incidence of early postoperative wound complications after the repair of rectoperineal fistula in both sexes using a limited sagittal anorectoplasty technique, and the key for securing the mucocutaneous anastomosis in this technique.

Materials and methods

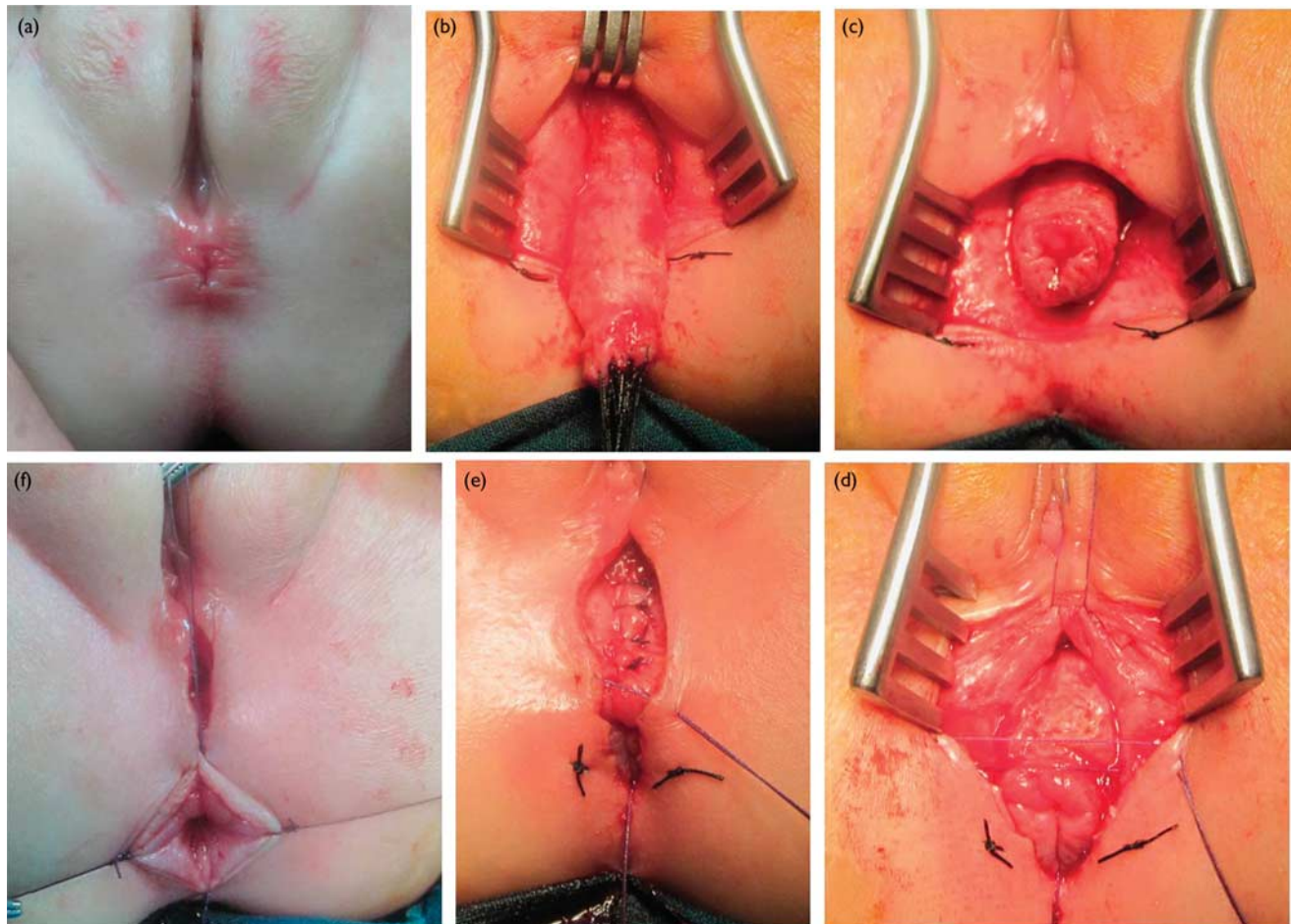
Patients

Between January 2011 and December 2014, patients with low-anorectal anomalies (diagnosed as rectoperineal fistula according to the latest classification) [3] were included in the study. Only patients who were treated primarily by a limited sagittal anorectoplasty were included. Patients who underwent a protective colostomy or other types of anoplasties were excluded. Also, we excluded recurrent cases and cases with a high rectum communicating with the perineum by a long fistulous tract (anorectal stenosis). The study was conducted after approval of the internal review board.

Preoperative preparation

The minimum age for operation was 3 months (to avoid the need for neonatal ICU admission, which is usually busy with other more severe anomalies). Before this age, patients suffering from constipation were managed by daily dilatation of the fistula and by oral laxatives as needed. Screening for possible associated anomalies was performed by clinical examination, plain radiography of sacrum, and renal ultrasound. Patients were hospitalized 2 days before the operation for colonic preparation. This included oral laxatives and enemas thrice daily for 48 h,

Fig. 1



Steps of the limited sagittal anorectoplasty in a 9-month-old girl with rectoperineal fistula. (a) The preoperative position of the rectoperineal fistula. (b) Dissection and mobilization of the anterior rectal wall off the vagina. (c) Checking for the absence of tension after completion of the dissection. (d, e) Reconstruction of the muscles in front of the anorectum in its new position. (f) The four-corner sutures of the mucocutaneous anastomosis.

with oral intake restriction to clear fluids 24 h before the operation.

The surgical technique

All operations were performed by the same pediatric surgeon (A.A.A). Patients were operated in the lithotomy position. Insertion of a urinary catheter was a must in boys. Before starting with the skin incision, the site of the sphincter muscle complex is marked by silk stitches guided by the characteristic shape and color of the anal pit, and confirmed by the muscle stimulator when available. Multiple 4-0 silk stitches are used to distribute the traction tension on the rectoperineal fistula. A racket-shaped incision is made around the fistula and extended backwards, completely splitting the vertical muscle complex open. The incision is deepened down until the posterior rectal wall is seen, which is identified by its characteristic covering fascia. Dissection of this fascia is started on the back and sides of the rectum, as recommended by Levitt and Pena [10], where it is easier to find the proper plain of dissection directly on the rectal wall. Then, the separation of the rectum from the anterior structures is started (vagina in girls and bulbospongiosum in boys; Figs 1 and 2), which is considered by many authors as the most important step

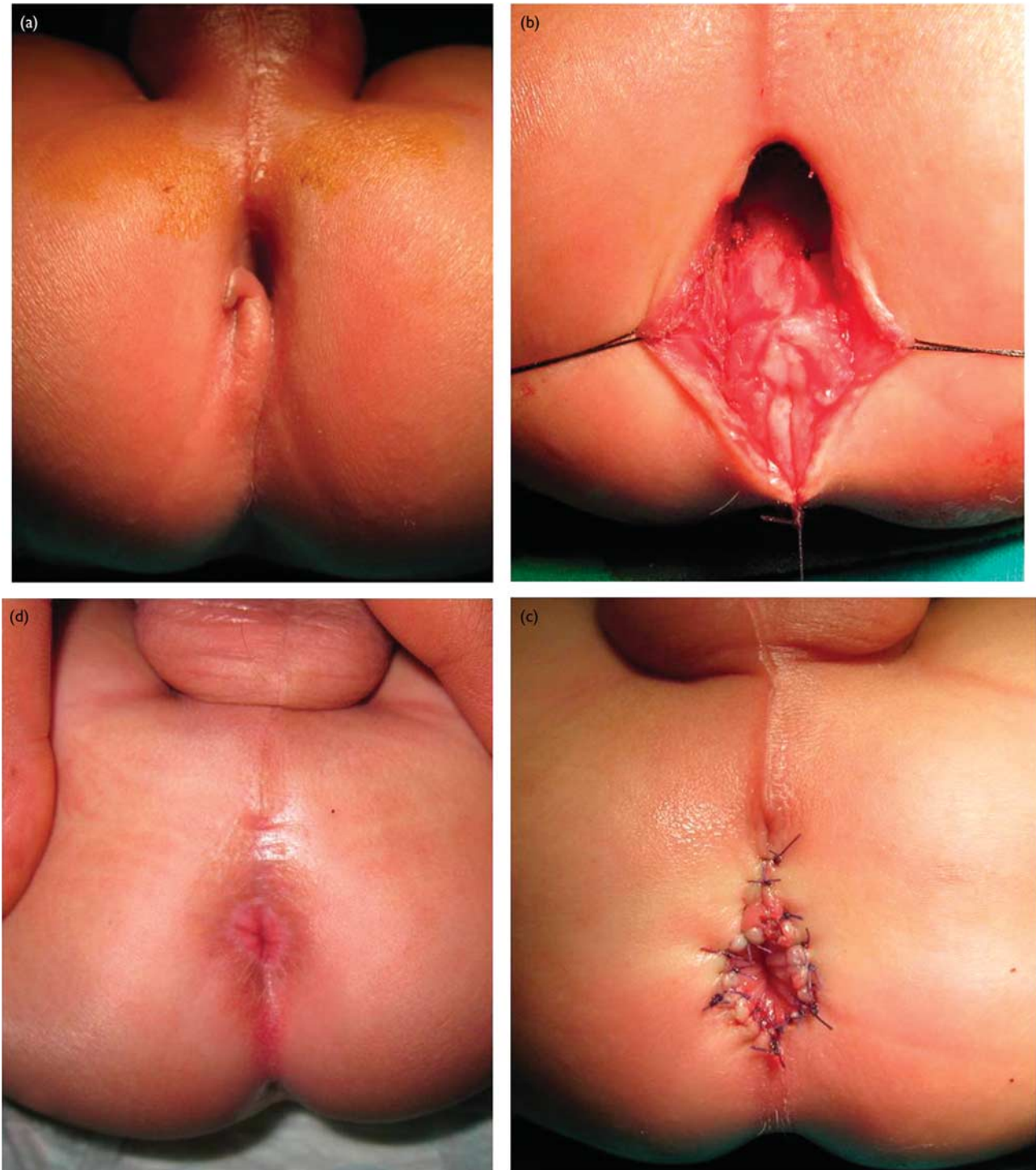
in this operation [9,11–13]. Now, the mobilized anorectum is repositioned backwards within the ‘split-open’ vertical muscle complex. Reconstruction of the perineal muscles in front of the anorectum is followed by the mucocutaneous anastomosis (Figs 1 and 2).

During the first half of this study, we noticed a relatively high incidence of wound complications, which was possibly attributed to the presence of excessive tension on the mucocutaneous anastomosis of the anoplasty in these cases. Therefore, we modified our technique during the second half of the study by performing an over-mobilization of the rectum in all operated cases, to relieve any tension at the mucocutaneous anastomosis (Fig. 3). Care should be taken to fix the anterior wall of the anorectum to the reconstructed perineal muscles to prevent postoperative prolapse (Fig. 1e).

Postoperative care

Postoperative analgesia and antibiotics are continued for 3–5 days. Oral intake is allowed on the fourth postoperative day, on condition that there are no wound complications, and the patient is discharged on the seventh postoperative day. Oral laxatives are added with

Fig. 2



Steps of the limited sagittal anorectoplasty in a 4-month-old boy with rectoperineal fistula. (a) The preoperative position of the rectoperineal fistula. (b) Rectal dissection and mobilization. (c) Completion of the mucocutaneous anastomosis in the new position. (d) Three-month follow-up after the operation.

the progression of feeding for 2–3 weeks (may continue for a longer period if constipation persists).

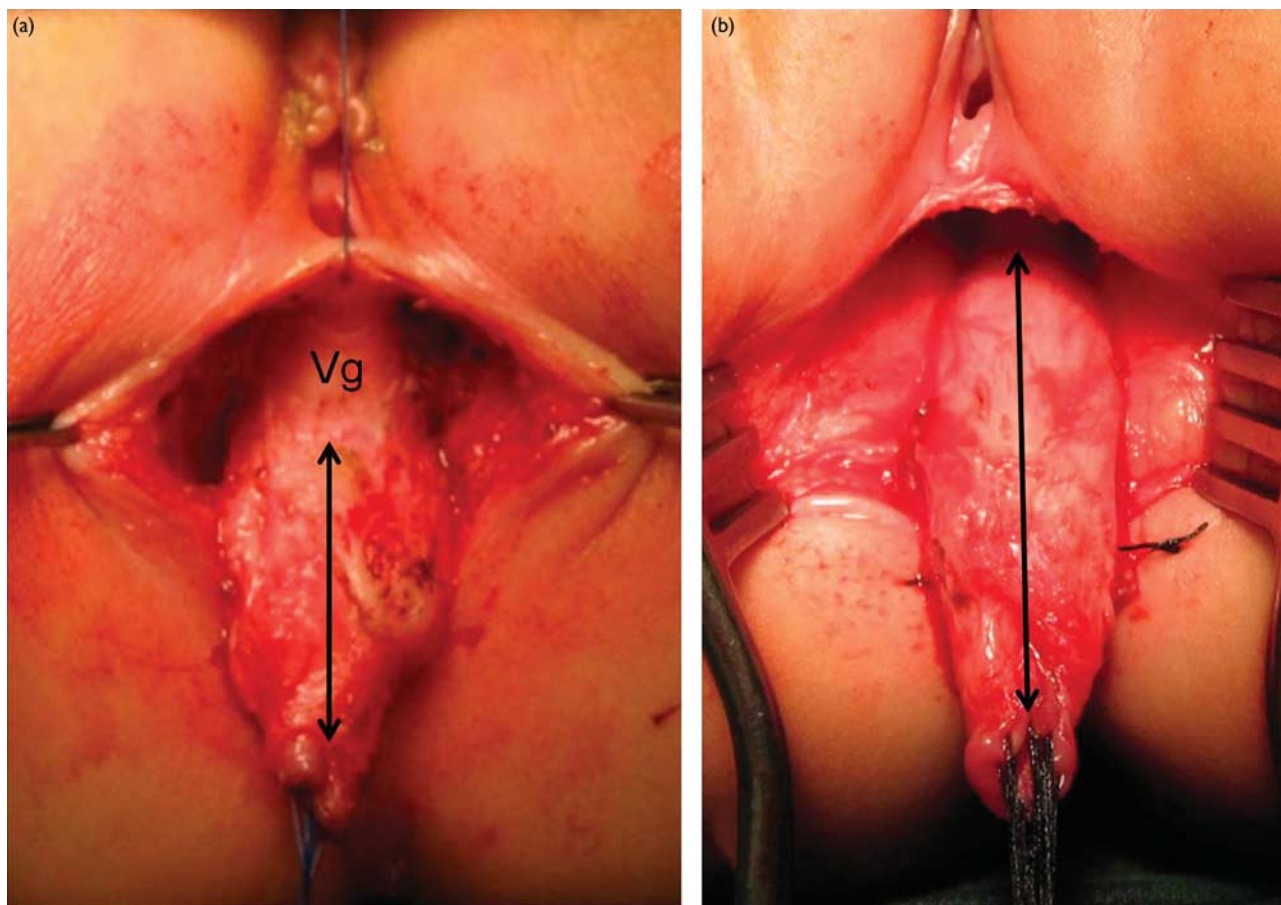
Postoperative wound complications were classified into minor or major dehiscence, with or without the involvement of the mucocutaneous anastomosis. Isolated dehiscence of the midline skin closure is not complicated by anal retraction and can be managed conservatively (Fig. 4). The dehiscence at the mucocutaneous anastomosis is more

important, which may be complicated by anal retraction and stenosis (Fig. 5). Major dehiscence at the mucocutaneous anastomosis usually requires fecal diversion.

Results

During the 4-year period of the study, 36 consecutive patients with rectoperineal fistula were included (28 girls and eight boys). Their age ranged from 3 to 42 months

Fig. 3



Comparison between the dissection of the rectoperineal fistula in the two groups during limited sagittal anorectoplasty. (a) Limited dissection of the rectoperineal fistula in an 8-month-old girl. The double-arrowhead line is pointing toward the length of the dissected rectum up to its attachment with the vagina 'Vg' (about 3 cm). This case was complicated by wound dehiscence that required fecal diversion. (b) Extended dissection of the rectoperineal fistula in a 5-month-old girl. The double-arrowhead line is pointing toward the length of the dissected rectum (about 5 cm) up to its attachment with the vagina that is seen completely retracted away from the rectum.

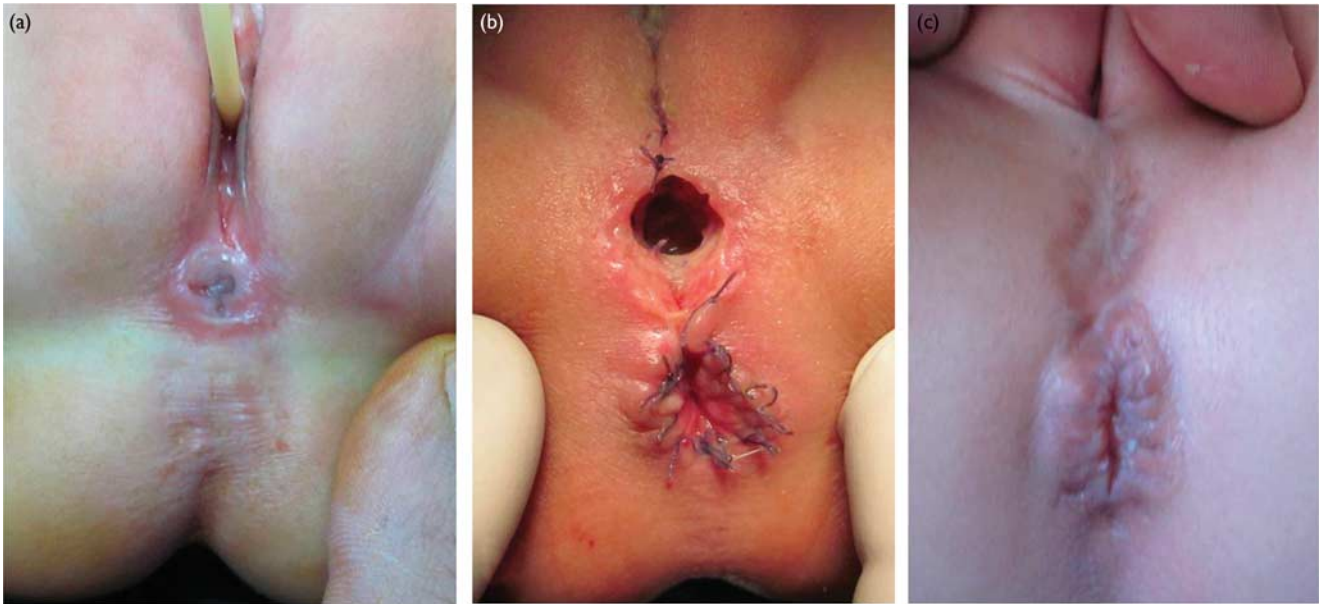
(mean 10.2 ± 9.6 months). Besides the recurrent cases, we excluded another group with different causes: 13 boys (one had a colostomy performed at birth, one had anorectal stenosis, and 11 underwent a cutback or Y-V anoplasty) and nine girls (three underwent cutback anoplasty, three had presacral teratoma 'Currarino syndrome', two had incomplete cloaca 'common urogenital sinus + rectoperineal fistula', and one had caudal duplication syndrome).

In the study group (28 girls and eight boys), we found associated anomalies in three girls (10.7% of the female patients): congenital heart disease in one patient, an absent vagina in another, and vesicoureteric reflux and anterior sacral meningocele in one patient.

All patients in the study (36) underwent limited sagittal anorectoplasty without protecting colostomy. The overall incidence of postoperative wound dehiscence was 22.2% (eight patients), one of which was isolated midline dehiscence without the involvement of the mucocutaneous anastomosis (Fig. 4). The incidence of wound dehiscence was higher in girls (7/28) than in boys (1/8), but it did not reach statistical significance ($P = 0.4$, Mann-Whitney test) (Table 1).

The patients in the study were divided into two groups according to the extent of rectal dissection and mobilization during the operation (Table 1). During the first half of the study (2011–2012), we performed limited dissection and mobilization of the rectum (about 2–3 cm) (Fig. 3a). In this group (15 patients), there was a high incidence of wound complications (six patients, 40%). Five patients were considered to have a major dehiscence (more than half the circumference of the anoplasty) and four required a rescue colostomy. Because of the relatively high incidence of wound complications in the first group, we shifted to more dissection and mobilization of the rectum (about 4–5 cm) in the second half of the study (2013–2014). We called this 'extended anorectal mobilization,' which is more or less similar to the degree of dissection for a rectovestibular fistula (Fig. 3b). In the second group (21 patients), two had postoperative wound complications (9.5%) that were managed conservatively. The first had isolated midline dehiscence (Fig. 4), and the other had minor dehiscence at the mucocutaneous anastomosis of the anoplasty (Fig. 5a). Extension of the rectal dissection and mobilization decreased the overall incidence of wound complications significantly in the second group (Mann-Whitney test, $P = 0.04$).

Fig. 4



Isolated wound dehiscence with sparing of the mucocutaneous anastomosis after limited sagittal anorectoplasty in a 6-month-old girl. (a) The preoperative position of the rectoperineal fistula. (b) Dehiscence of the midline skin closure at 1 week. Note that the dehiscence is taking the shape and the preoperative position of the fistula. Dissection of the fistula leaves a tissue defect that might exert some tension on midline closure. (c) As there was no mucosal retraction, the condition was managed conservatively, and the wound healed by secondary intention.

Discussion

Low-anorectal anomalies comprise different clinical variants in both sexes (anterior ectopic anus, covered anus, bucket-handle deformity, anal stenosis). Recently, a single term, the 'rectoperineal fistula,' has been proposed to cover most of these variants [10]. Basically, it describes a rectum that has passed through the pelvic floor (levator muscle) successfully to end into the perineum anterior to the center of the muscle complex. Therefore, the bowel termination is located within most of the sphincter mechanism, and fecal continence is expected to be excellent in these patients [10]. However, constipation constitutes a major problem among these patients, which is sometimes so intractable as to cause fecal soiling (pseudoincontinence) [4].

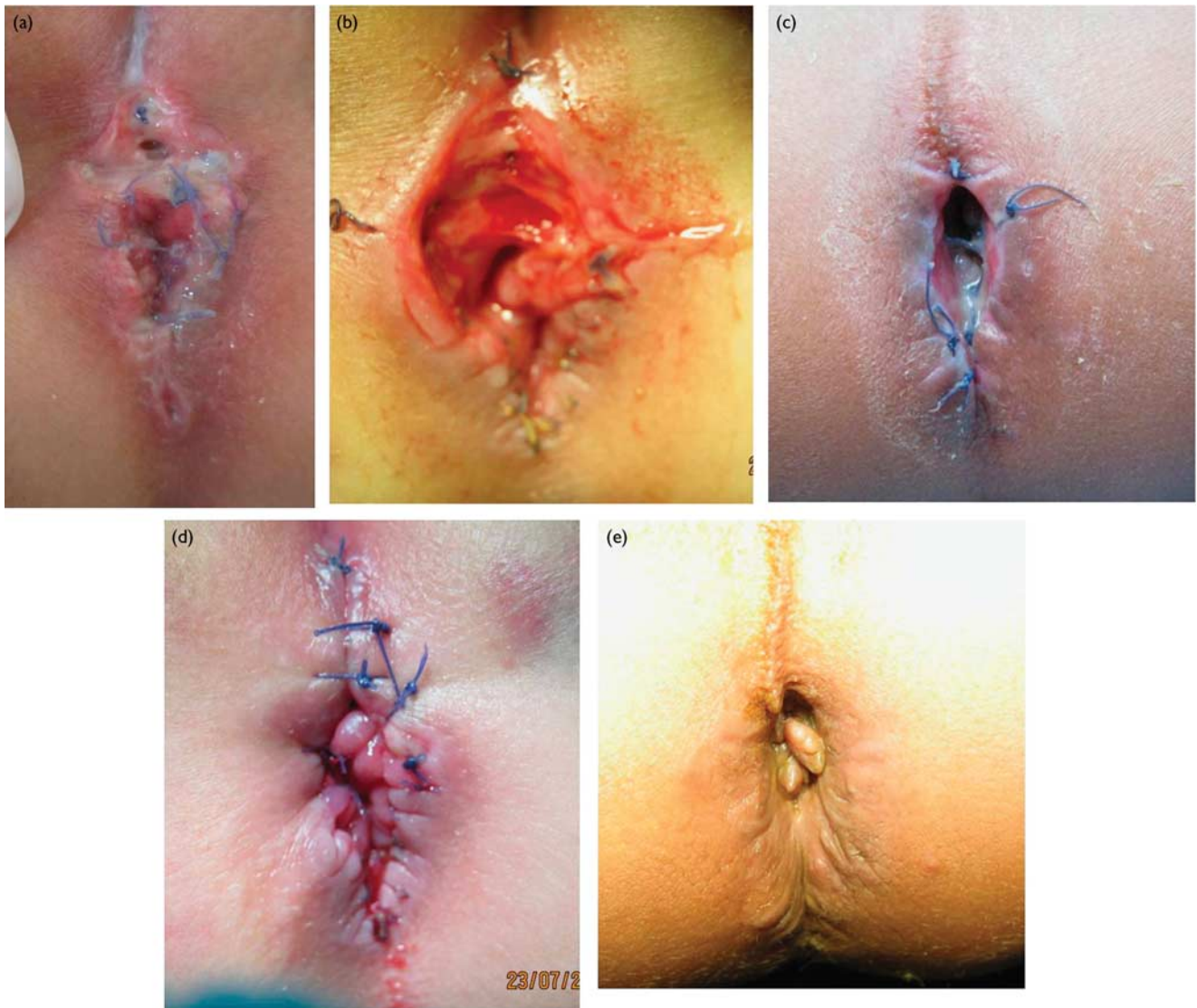
There is no consensus on the best management for rectoperineal fistula. Some scholars would deny any surgical correction, especially when the rectoperineal fistula is sufficiently wide (what they call an 'anteriorly displaced anus') [4]. They build their argument on the reported high incidence of postoperative constipation that would suggest little expected benefit from surgery. Others advocate prolonged regular dilatation for managing a narrow fistula [4]. Simple anoplasty (cutback) is one surgical option that has stood the test of time, with minimal risk of wound complications. However, it is recommended only for selected cases (those with minor anterior displacement); otherwise, it will leave a very short perineum, which may be cosmetically unacceptable, in addition to the persistence of vestibular contamination in girls [4,6]. In contrast, the limited sagittal anorectoplasty offers full correction by mobilization of the anorectum to be repositioned backwards in the center of the muscle

complex. However, there are reports on the increased risk of wound dehiscence, anal retraction, and stenosis. This may affect the continence potential in these patients, in addition to the possible need for fecal diversion (colostomy), which may be considered as a significant morbidity for such a minor form of the disease [4,8,9].

This report is concerned with patients with rectoperineal fistula (both male and female) who underwent a limited sagittal anorectoplasty primarily without a protecting colostomy. We preferred to call our technique a 'sagittal anorectoplasty' as it combines concepts from both the anterior and the posterior sagittal approaches. One reason for this study was that we noticed a relatively higher incidence of wound complications among these patients compared with those with rectovestibular fistula.

We classified wound complications into either isolated midline skin dehiscence or those involving the mucocutaneous anastomosis also. The first type occurred only in one case, which was managed conservatively and healed by secondary intention without complications. It appears that the dissection of the fistula from the perineum (especially when wide) results in a local tissue defect that would exert extra tension on the midline skin closure in patients with rectoperineal fistula (Fig. 4). In contrast, dehiscence involving the mucocutaneous anastomosis was more common (seven patients) and probably more important due to the risk of anal retraction and stenosis. This was further subclassified into minor and major dehiscence according to the degree of circumferential wound dehiscence. Major dehiscence involves more than half the circumference, and is associated with significant mucosal retraction. The latter is more liable to delayed complications (fibrosis and stenosis).

Fig. 5



Different degrees of postoperative dehiscence at the mucocutaneous anastomosis in patients with rectoperineal fistulae. (a) minor anterior dehiscence (less than half of the circumference) in a 3-month-old girl, with no mucosal retraction. This case was successfully managed conservatively without complications. (b) More severe anterior dehiscence (about one-half of the circumference) with mild retraction in an 11-month-old girl. This case required secondary suturing 1 week later (d). (c) Complete dehiscence and retraction at the mucocutaneous anastomosis in a 2-year-old boy. This case was complicated by fibrosis and stenosis (e), and later required reoperation.

Table 1 The distribution of postoperative wound complications among patients with rectoperineal fistula in both groups

	N (%)		
	Boys	Girls	Total
First group (limited mobilization): 15 patients; mean age 11.7 months	Wound complications in one case out of 3 (33.3)	Wound complications in five cases out of 12 (41.7)	Six cases out of 15 (40)
Second group (extended mobilization): 21 patients; mean age 9 months	No wound complications in five cases	Wound complications in two cases out of 16 (12.5)	Two cases out of 21 (9.5)

Many factors have been investigated to decrease wound complications after primary sagittal anorectoplasty: early repair in the neonatal period, protective colostomy, preoperative total bowel irrigation, therapeutic antibiotics, and delaying the postoperative oral intake with or without parenteral nutrition [8,14,15]. However, we

agree with Pena and colleagues, who highlighted the importance of a tension-free mucocutaneous anastomosis [9,11–13]. Effective mobilization of the anorectum through the proper plane of dissection (that maintains the intramural blood supply) is considered as the most important step in the operation that can guard against

wound complications [11]. However, to our knowledge, it is not clear in the literature as to what exactly is considered as an 'effective' mobilization in cases of rectoperineal fistula. Some reports discussed details about the appropriate extent of dissection in girls with rectovestibular fistula: Levitt and Pena [16] recommended the extension of the dissection cephalad until encountering the areolar tissue separating the rectum from the vagina; Okada *et al.* [14] reported the dissection of 4–5 cm of the rectum; others recommended reaching up to the cervix of the uterus [13]. We noticed that there is always a tendency to perform less dissection with the rectoperineal than with the rectovestibular fistula, which appears to be proportionate to the minor degree of the former. However, in our series, this was successful only in 60% of the cases and was associated with wound complications in 40% of the cases. By extending the dissection of the rectoperineal fistula almost similar to a rectovestibular dissection, the incidence of postoperative wound complications decreased significantly to 9.5%.

The study may be criticized for comparing two groups that were not operated synchronously, and that other factors related to the growing experience of the surgeon might have influenced the improvement of the results. However, both groups were comparable (regarding age and sex), and all patients were operated by the same surgeon (with experience in pediatric surgery for 15 years), who performed the same surgical technique, except for the modification related to the extent of rectal mobilization in the second group. Also, the study did not address the delayed and functional outcomes of the procedure, which we thought to be studied and discussed in another separate report.

Conclusion

Among patients with rectoperineal fistula, extension of the dissection and mobilization of the rectum from the anterior structures (vagina in girls and bulbospongiosum in boys) decreases wound dehiscence after a limited sagittal anorectoplasty procedure.

Acknowledgements

Conflicts of interest

There are no conflicts of interest.

References

- Murphy F, Puri P, Hutson JM, Holschneider AM. Incidence and frequency of different types, and classification of anorectal malformations. In: Holschneider AM, Hutson JM, editors. *Anorectal malformations in children*. Berlin, Heidelberg: Springer-Verlag; 2006. pp. 163–182.
- Nixon HH. Review of anorectal anomalies. *J R Soc Med* 1984; **77** (Suppl 3):27–29.
- Holschneider A, Hutson J, Pena A, Beket E, Chatterjee S, *et al.* Preliminary reports on the international conference for the development of standards for the treatment of anorectal malformations. *J Pediatr Surg* 2005; **40**:1521–1526.
- Pakarinen MP, Rintala RJ. Management and outcome of low anorectal malformations. *Pediatr Surg Int* 2010; **26**:1057–1063.
- Hendren WH. Constipation caused by anterior location of the anus and its surgical correction. *J Pediatr Surg* 1978; **13**:505–512.
- Javid PJ, Barnhart DC, Hirschl RB, Coran AG, Harmon CM. Immediate and long-term results of surgical management of low imperforate anus in girls. *J Pediatr Surg* 1998; **33**:198–203.
- Peña A, Devries PA. Posterior sagittal anorectoplasty: important technical considerations and new applications. *J Pediatr Surg* 1982; **17**:796–811.
- Kuijper CF, Aronson DC. Anterior or posterior sagittal anorectoplasty without colostomy for low-type anorectal malformation: how to get a better outcome? *J Pediatr Surg* 2010; **45**:1505–1508.
- Kumar B, Kandpal DK, Sharma SB, Agrawal LD, Jhamariya VN. Single-stage repair of vestibular and perineal fistulae without colostomy. *J Pediatr Surg* 2008; **43**:1848–1852.
- Levitt MA, Pena A. Operative management of anomalies in males. In: Holschneider AM, Hutson JM, editors. *Anorectal malformations in children*. Berlin, Heidelberg: Springer-Verlag; 2006. pp. 295–302.
- Levitt MA, Pena A. Complications after the treatment of anorectal malformations and redo operations. In: Holschneider AM, Hutson JM, editors. *Anorectal malformations in children*. Berlin, Heidelberg: Springer-Verlag; 2006. pp. 319–325.
- Wakhlu A, Kureel SN, Tandon RK, Wakhlu AK. Long-term results of anterior sagittal anorectoplasty for the treatment of vestibular fistula. *J Pediatr Surg* 2009; **44**:1913–1919.
- Kulshrestha S, Kulshrestha M, Singh B, Sarkar B, Chandra M, Gangopadhyay AN. Anterior sagittal anorectoplasty for anovestibular fistula. *Pediatr Surg Int* 2007; **23**:1191–1197.
- Okada A, Kamata S, Imura K, Fukuzawa M, Kubota A, Yagi M, *et al.* Anterior sagittal anorectoplasty for rectovestibular and anovestibular fistula. *J Pediatr Surg* 1992; **27**:85–88.
- Wakhlu A, Pandey A, Prasad A, Kureel SN, Tandon RK, Wakhlu AK. Anterior sagittal anorectoplasty for anorectal malformations and perineal trauma in the female child. *J Pediatr Surg* 1996; **31**:1236–1240.
- Levitt MA, Pena A. Operative management of anomalies in the female. In: Holschneider AM, Hutson JM, editors. *Anorectal malformations in children*. Berlin, Heidelberg: Springer-Verlag; 2006. pp. 303–305.