

# The versatility of the transumbilical approach for laparotomy in infants

Essam A. Elhalaby, Hussam S. Hassan, Mohamed S. Hashish and Amel A. Hashish

**Background/purpose** Although the transumbilical approach became very popular for pyloromyotomy, it has not been widely used in other procedures in children. The aim of this work was to evaluate the safety and the versatility of this approach for laparotomy in infants.

**Patients and methods** All hemodynamically stable neonates and infants with gastrointestinal surgical problems or pelvic or abdominal cystic masses were considered candidates for this approach. The umbilicus was incised nearly circumferentially, and the peritoneum was entered in the midline in a cephalic or caudal direction depending on the site of the lesion. The bowel or the mass was delivered outside the peritoneal cavity, and the procedure was completed in the standard open manner. Patients were evaluated with regard to the feasibility of the surgery and or any difficulty to complete the surgery, any complications related to the approach, and the cosmetic outcome.

**Results** A total of 141 infants underwent transumbilical laparotomy during the period from June 2008 to December 2013. The primary pathology was hypertrophic pyloric stenosis ( $n=65$ ), duodenal, small-intestinal atresia/stricture ( $n=22$ ), colonic atresia ( $n=2$ ), malrotation with/without volvulus ( $n=10$ ), ovarian cysts ( $n=12$ ), intussusception ( $n=9$ ), spontaneous intestinal perforation ( $n=7$ ), remnants of vitellointestinal duct ( $n=4$ ), mesenteric cysts ( $n=3$ ), patent urachus ( $n=3$ ), postoperative

complications of strangulated inguinal hernia ( $n=3$ ), and complications in ventriculoperitoneal shunts ( $n=1$ ). Their age ranged from 1 day to 22 months. The operating time ranged from 30 to 120 min. Three patients required transverse extension of the wound. Two (1.4%) patients developed dehiscence of the wound that required wound closure. Five (3.5%) patients had superficial periumbilical cellulitis and wound infections, and one patient had suture reaction treated conservatively. Late complications (adhesive intestinal obstruction) occurred in three (2%) patients. Parents were very satisfied with the final cosmetic outcome.

**Conclusion** The transumbilical approach is both a feasible and a safe approach for a broad spectrum of surgical procedures in neonates and infants. The cosmetic results are excellent. *Ann Pediatr Surg* 11:1–6 © 2015 Annals of Pediatric Surgery.

*Annals of Pediatric Surgery* 2015, 11:1–6

**Keywords:** abdominal masses, infants, laparotomy, transumbilical approach

Pediatric Surgery Department, Tanta University Hospital, Faculty of Medicine, Tanta University, Tanta, Egypt

Correspondence to Essam A. Elhalaby, MBBCh, MSc Surg, MD, CT, Pediatric Surgery Department, Tanta University Hospital, Faculty of Medicine, Tanta University, Tanta 31111, Egypt  
Tel: +20 100 545 1157, +20 40 333 5695; fax: +00 20 340 7734;  
e-mails: [essam.elhalaby@med.tanta.edu.eg](mailto:essam.elhalaby@med.tanta.edu.eg), [eselhalaby@yahoo.com](mailto:eselhalaby@yahoo.com)

Received 12 October 2014 accepted 19 December 2014

## Introduction

Traditionally, pediatric surgeons used the right upper quadrant incision to access the abdomen for a variety of surgical conditions requiring surgical intervention in newborns and infants. Although this incision is very effective at providing excellent exposure to the abdominal cavity with a low complication rate, the resulting scar grows with the patient and becomes unsightly. Some, particularly adolescents, regard it as a stigma that they do not like to display to their peers, often requesting total removal of the scar by 'plastic surgery' [1].

Recent advances in laparoscopic techniques made it possible for a wide range of these pathologies requiring surgical intervention to be handled by laparoscopy, and this approach proved to be equally effective and cosmetically superior [2–5]. However, the laparoscopic approach is often associated with an increased operative time, higher cost, and a significant learning curve [6,7].

In 1986, Tan and Bianchi [1] reported using a circumumbilical incision as the access for pyloromyotomy in infantile hypertrophic pyloric stenosis. This transumbilical approach has since been adopted by many pediatric

surgeons as a feasible, safe, inexpensive, and virtually scarless approach to hypertrophic pyloric stenosis [8].

Many surgeons modified the original Tan–Bianchi approach for the sake of more access to the abdomen to facilitate the management of surgical pathologies other than pyloric stenosis. The modified incisions included making the incision on the right side of the umbilicus instead of the original position on the upper side [9], or making the incision along the lower side of the umbilicus [10], V-Y plasty [11,12], right-sided lateral wound extension modification [13], and a modified extension with an  $\Omega$ -shaped incision [14].

These modified approaches were used for many other surgical pathologies requiring intervention such as Hirschsprung's disease, ovarian cysts, intestinal atresia, or placing a temporary colostomy as an initial management for high anorectal malformations [10,15–17].

In the interest of improved cosmesis, both laparoscopic and transumbilical approaches are considered as evolving alternative procedures. However, transumbilical laparotomy has several potential advantages over laparoscopy.

This approach does not require any special training for the surgeon or the surgical team, and there is no learning curve or complex or costly instrumentation to acquire and maintain.

In this study, we attempted to ascertain the feasibility and the safety of the transumbilical approach for a wide variety of pediatric abdominal pathologies.

### Patients and methods

This prospective study included 141 patients, who were treated at Tanta University Hospital and affiliated hospitals during the period from June 2008 to December 2013. All infants aged below 2 years with gastrointestinal pathologies or cystic pelvic or abdominal masses requiring surgical intervention were included in the study. Exclusion criteria were a bad general condition, hemodynamic instability, cardiovascular, pulmonary, or renal congenital anomalies, blood dyscrasias, abdominal trauma, failure to establish a preoperative definitive diagnosis, and cases with suspected malignancy.

For all cases, the following data were recorded: patient demography including the age at diagnosis, symptoms at presentation, diagnostic examinations, details of the pathology and the procedures, the operative time, surgical complications, and the length of hospital stay.

An informed consent was obtained from the parents, and the study was approved by the Institutional Review Board.

### The operative technique

Initial assessment and correction of any existing dehydration and acid–base balance were insured. The umbilicus was cleansed thoroughly with providence-iodine or chlorhexidine solution. Then, the abdomen was prepped and draped in the standard manner.

The transumbilical approach begins with a curved incision extending along three quarters of the umbilical circumference. The position of the incision on the umbilicus was planned according to the expected pathology. The wound was extended on one side of its ends or on both sides ( $\Omega$ -shaped incision) when needed. A subcutaneous plane was developed for  $\sim 5$  cm, and the fascia and the peritoneum were opened in the midline, either above or below the umbilicus according to the site of the surgical pathology. The fascial incision was extended to include the site of the umbilicus when needed. The skin was stretched in all directions with vein retractors to provide increased exposure. The bowel or the mass was delivered outside the peritoneal cavity and the procedure was completed in the standard open manner. In case of pelvic or abdominal cystic masses, the site of pathology, localized before the procedure, was compressed gently to force the mass or the cyst to appear through the incision. Large cysts were decompressed to facilitate getting them out of the incision.

At the end of the procedure, the upper and/or the lower angles were secured with interrupted figure-of-8 sutures using polyglactin #2/0. The fascia was closed by interrupted 2/0 or 3/0 polyglactin. The skin incision was

always closed circumferentially by a continuous subcuticular suture with 3-0 polyglactin, leaving a small skin scar and minimal disruption to the abdominal wall. The scar becomes well hidden within the periumbilical skin folds.

### Follow-up

Postoperative antibiotics were given according to the specific pathology. The patients were evaluated 1 month after discharge, and then every 3–6 months for 2 years to detect the following: the final shape of the wound, development of delayed complications as incisional hernia, or adhesive intestinal obstruction.

### Results

The ages of the 141 patients ranged from 1 day to 22 months with a median age of 45 days. Their weight ranged from 2.4 to 5.4 kg with a mean of  $3.7 \pm 0.1.2$  kg. Eighty-four (59.6%) patients were boys. In all the patients, the diagnosis was established preoperatively by clinical examination, plain radiography, contrast studies, and abdominal ultrasonography.

The operating time ranged from 30 to 120 min with a mean of  $75 \pm 15$  min.

A wide range of surgical pathologies were treated successfully using this approach. Twelve ovarian cysts were found: eight of them were simple, not complicated, and larger than 5 cm. Mixed cystic and solid parts were present in one case. In another three cases, the cysts were complicated by torsion (two cases) or by hemorrhage inside the cysts (one case). All cases were successfully delivered outside the abdominal cavity after partial aspiration of the contents (Fig. 1a and b). Three cases with mesenteric cysts were easily treated through this approach (Fig. 2). The surgical pathology requiring intervention is summarized in Table 1 (Figs 3 and 4).

Two cases of intussusceptions (Fig. 5a and b) and one neonate with duodenal atresia required transverse extension of the wound.

The median time to start oral feeds was 24.0 h (range 6.7–48.0 h). Seventy-two patients were discharged within 24 h, and the remainder were discharged within 5 days.

### Early postoperative complications

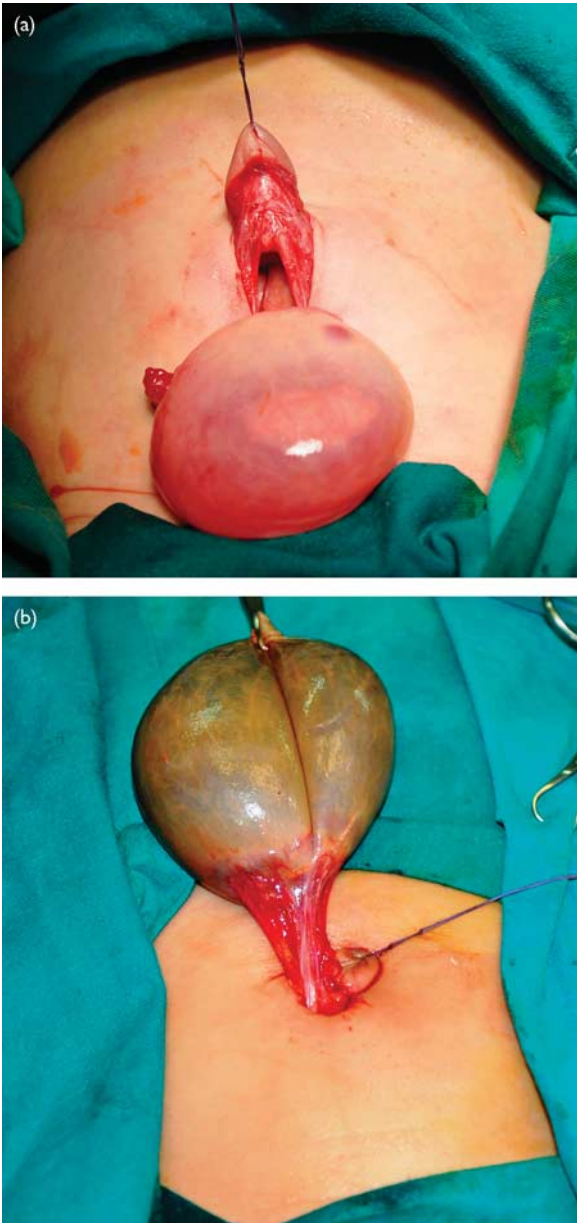
There were 80 early postoperative complications representing a total incidence of 6% (Table 2). Two patients developed dehiscence of the wound that required secondary wound closure (Fig. 6), five had mild to moderate surgical site infections (5%) that required only medical treatment, and one patient had suture reaction (0.7%).

### Follow-up

In all uncomplicated cases, the scars were nearly invisible at the 3- to 6-week follow-up visit, and the results were appreciated by parents (Fig. 7).

Three patients developed postoperative intestinal obstruction that required intervention: two cases in the first follow-up year and one case in the second year. All cases

**Fig. 1**



(a, b) Skin and caudal fascial incisions through which noncomplicated (a) and complicated (b) ovarian cysts were easily delivered.

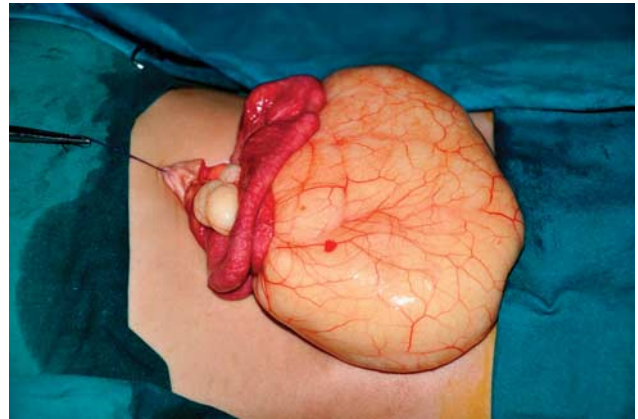
underwent adhesiolysis and had no recurrence. No incisional hernia was noted at late follow-up.

**Discussion**

Since Tan and Bianchi [1] reported using circumumbilical incision as minimal access for pyloromyotomy in infantile hypertrophic pyloric stenosis, there has been a realization of its potential as an access for other surgical pathologies. In 2003, Soutter and Askew [16] reported the use of this novel approach for various abdominal surgical problems, but despite their encouraging results, the approach did not gain the deserved popularity except for pyloromyotomy.

In contrast to traditional open or laparoscopic surgery, the transumbilical approach should not be considered as an

**Fig. 2**

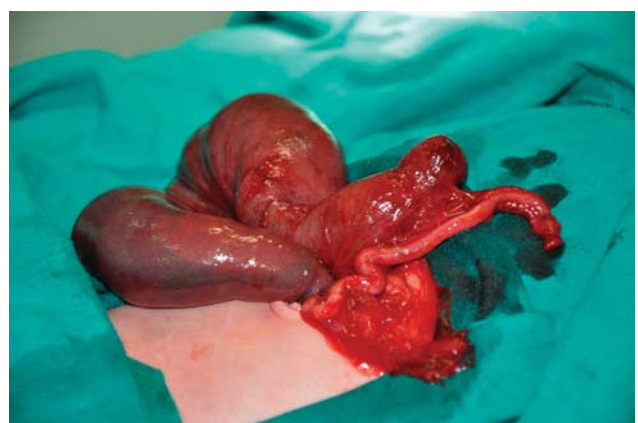

A mesenteric cyst with an attached loop of the small bowel was excised.

**Table 1 Surgical pathologies that required intervention using the transumbilical approach**

Pathology	n (%)
Hypertrophic pyloric stenosis	65 (46.1)
Duodenal, small intestinal atresia/stricture	22 (15.6)
Colonic atresia	2 (1.4)
Malrotation with/without volvulus	10 (7.1)
Ovarian cysts	12 (8.5)
Intussusception	9 (6.4)
Spontaneous intestinal perforation	7 (4.9)
Remnants of vitellointestinal duct	4 (2.8)
Mesenteric cysts	3 (2.1)
Patent urachus	3 (2.1)
Postoperative complications of strangulated inguinal hernia	3 (2.1)
Complications in ventriculoperitoneal shunts	1 (1.4)

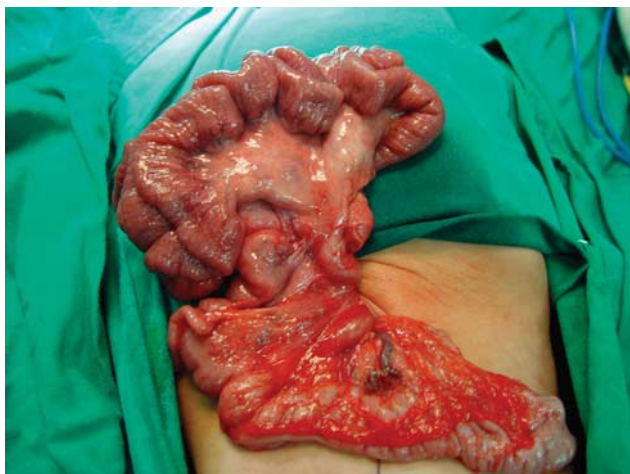**Fig. 3**



Colonic atresia: the right colon was missing. Both the distal unused colon and the proximal end (ileum) were brought out through the same incision (umbilical stoma).

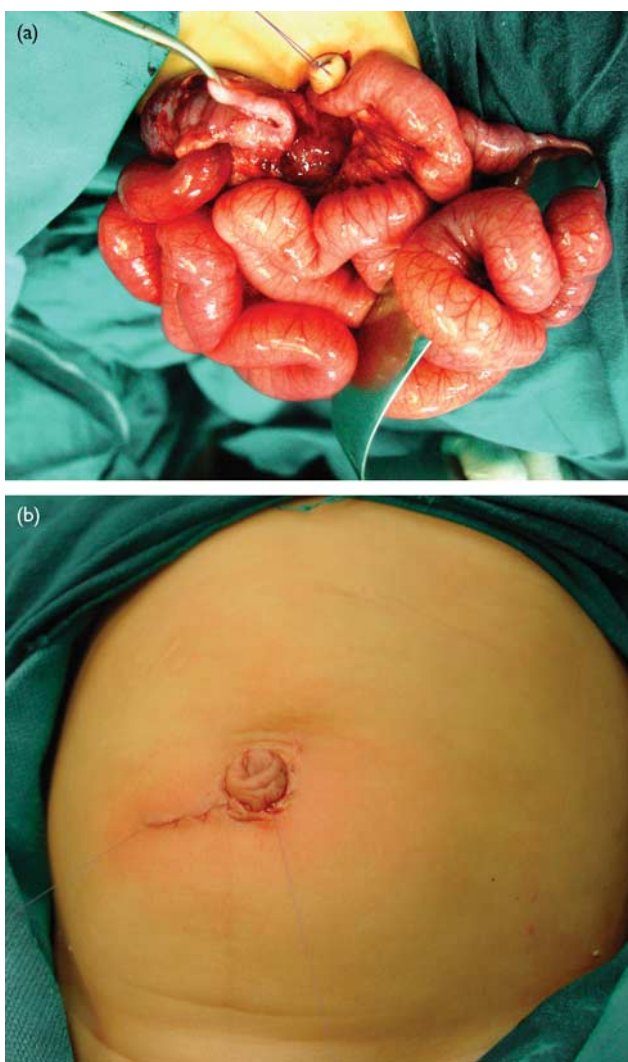
exploratory incision. The diagnosis should be defined preoperatively to ensure the safety and the efficacy of the approach.

Fig. 4



Intestinal malrotation with mid-gut volvulus.

Fig. 5



(a, b) Gangrenous ileocolic intussusception: after failure of pneumatic reduction (a), lateral extension of both the skin and the fascia was needed to deliver the mass (b).

Table 2 Postoperative complications

Complications	n (%)
Wound dehiscence	2 (0.014)
Wound infections	5 (0.035)
Suture reaction	1 (0.007)
Adhesive intestinal obstruction	3 (0.021)

Two main criticisms for this approach are the limited exploration nature of the incision compared with the conventional upper transverse abdominal incision or the laparoscopic approach, and the difficulties in delivering the viscera or masses outside the peritoneal cavity to complete the procedure effectively. Although both the skin and the fascial incision can be extended, we believe that this approach is better avoided if the preoperative diagnosis is not clear.

The size of the patient did not constitute a problem in our series and we have used it in neonates and in infants. The skin curved incision was made along  $\frac{3}{4}$  of the umbilical circumference. The site of the incision was planned according to the surgical pathology requiring intervention. It was a mainly upper circumumbilical incision in cases of infantile pyloric stenosis; a mainly lower incision was made to access pelvic organs as in cases of ovarian cysts. The fascial incision was made to the linea alba above or below the umbilicus and was extended to include the umbilical cicatrix when more exposure was needed. We did not use a circumumbilical fascial incision as described by some investigators [9], as this fascial incision requires a lot of retraction with tension and trauma to the rectus abdominis muscle, which can cause muscle ischemia and hematoma formation, which predispose one to abscess formation, wound infection, and incisional hernia [11].

However, many surgeons do not prefer the fascial incision, as it requires the creation of a subcutaneous pocket that is prone to seroma and infection [17].

After opening the fascia, it was always easy to deliver the site of pathology outside the abdominal cavity. The difficult part of delivering the site of pathology was at the narrow skin incision, which was incised at one or both sides in three cases to facilitate delivery.

In cases of infantile pyloric stenosis, it was always easy to deliver the mass through the umbilical incision. We had two cases of inadvertent duodenal mucosal perforation (1.4%). This incidence is comparable to other reports using the standard approach [18,19].

The current approach is excellent for the management of ovarian cysts regardless of its size. We did not encounter any complications related to this pathological entity using this approach. It is comparable to published results using the laparoscopic approach [20]. Mesenteric cysts can be managed effectively using this approach.

All bowel atresia can be managed effectively through this approach. In cases of colonic atresia, this approach looks even more attractive; the stoma can be fashioned at the

umbilicus, and the abdomen will look almost scarless after stoma takedown.

We have found that intestinal malrotation with or without volvulus is one the best indications for this approach. In the 10 cases of malrotation, it was easy to deliver the cecum and excise Ladd's bands. The entire small intestine can be delivered through this relatively narrow incision to undo the twist, because the root of the mesentery in these cases is a small pedicle.

One case with complicated ventriculoperitoneal shunt complication occurred, where the shunt penetrated and caused a fistula through the umbilicus. It was easily managed through this approach.

One of the difficult cases we encountered using this approach was a case of duodenal atresia, in which it was a real challenge to manage the case through this approach. Lateral extension of the incision was needed. The surgeon should not hesitate to extend the incision either at the skin, the fascia, or at both levels. This should not be considered as a failure of the approach.

Another difficult group of cases handled in this series included some cases of intussusceptions after failure of pneumatic or hydrostatic reduction. Delivering the intussusceptum can be a real challenge. Two cases required later extension of the skin incision, the fascia, and the underlying muscle layers to facilitate the delivery of the mass. Both patients required resection of the nonviable intussuscepted bowel and end-to-end intestinal anastomosis.

Despite the relatively small incision, patients can develop wound dehiscence, as in the two cases that occurred early in this study, when the fascia was closed using a continuous polyglactin suture. Later in the series, we closed the fascia with interrupted polyglactin sutures, and we did not have any wound dehiscence thereafter.

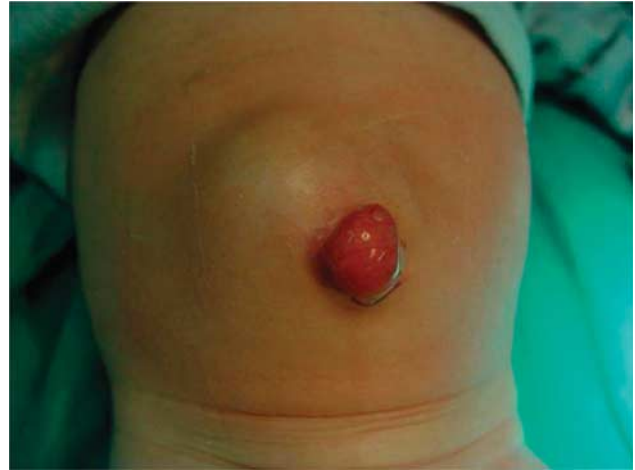We did not have any cases of incisional hernia as reported by others [21]. We believe that incisional hernia is avoidable using this approach by good closure of the abdominal wall with particular attention to ensuring that there is no tension and no strangulation of tissues by the sutures.

A relatively higher incidence of postoperative intestinal obstruction may be expected due to the formation of adhesions. This hypothesis was based on the fact that we had to perform more manipulation on the viscera to force them out of the relatively narrow incision. Actually, the incidence of postoperative adhesions that required surgical intervention in this series (2.12%) was comparable to the incidence reported by others [22,23].

The incidence of postoperative complications in this series was much lesser than that reported by others, perhaps because the majority of our cases dealt with a simple pathology compared with other studies where all their cases were Hirschsprung's disease [16].

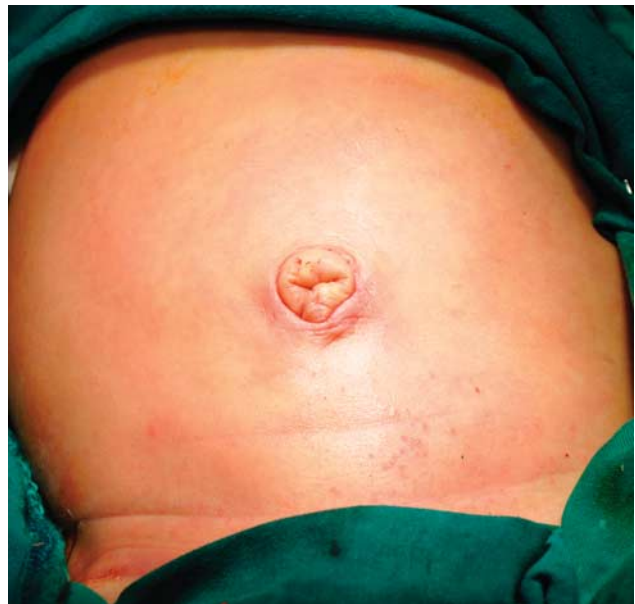Parents' satisfaction with the almost invisible scar was definitely a significant advantage of this approach. Likewise, postoperative complications were comparable

Fig. 6



Wound dehiscence at the sixth postoperative day after pyloromyotomy.

Fig. 7



The periumbilical scar is well hidden in the skin folds.

to conventional and laparoscopic approaches for similar operations [6,24].

We admit that there are certain limitations of the current study, which include the heterogenous primary pathology and the lack of control groups for each pathological entity. Some pathologies were compared with a control group in previously published studies [20,25,26]. Future studies comparing each pathological entity operated through a transumbilical approach with a control group operated through a standard or a laparoscopic approach are recommended.

## Conclusion

The transumbilical open approach is an attractive alternative to laparoscopy, combining safety with minimally

disruptive surgery. It has the advantage of a comparable complication rate and of being an open technique, requiring no additional equipment or particular skills, and it leads to an esthetic scar. Thus, this approach is very appealing in some parts of the developing countries, where acquisition of the necessary equipment and expertise for laparoscopic surgery is far beyond reach.

## Acknowledgements

### Conflicts of interest

There are no conflicts of interest.

## References

- 1 Tan KC, Bianchi A. Circumbilical incision for pyloromyotomy. *Br J Surg* 1986; **73**:399.
- 2 Blakely ML, Lobe TE, Cohen J, Burghen GA, et al. Laparoscopic pancreatectomy for persistent hyperinsulinemic hypoglycemia of infancy. *Surg Endosc* 2001; **15**:897–898.
- 3 Fujimoto T, Segawa O, Lane GJ, Esaki S, Miyano T. Laparoscopic surgery in newborn infants. *Surg Endosc* 1999; **13**:773–777.
- 4 Iwanaka T, Arai M, Ito M, Kawashima H, Imaizumi S. Laparoscopic surgery in neonates and infants weighing less than 5 kg. *Pediatr Int* 2000; **42**:608–612.
- 5 Rothenberg SS. Laparoscopic duodeno-duodenostomy for duodenal obstruction in infants and children. *J Pediatr Surg* 2002; **37**:1088–1089.
- 6 Chen MK, Schropp KP, Lobe TE. Complications of minimal-access surgery in children. *J Pediatr Surg* 1996; **31**:1161–1165.
- 7 Esposito C, Mattioli G, Monguzzi GL, Montinaro L, Riccipiettoni G, Aceti R, et al. Complications and conversions of pediatric videosurgery: the Italian multicentric experience on 1689 procedures. *Surg Endosc* 2002; **16**:795–798.
- 8 Fitzgerald PG, Lau GY, Cameron GS. Use of the umbilical site for temporary ostomy: review of 47 cases. *J Pediatr Surg* 1989; **24**:973.
- 9 Alberti D, Cheli M, Locatelli G. A new technical variant for extramucosal pyloromyotomy: the Tan–Bianchi operation moves to the right. *J Pediatr Surg* 2004; **39**:53–56.
- 10 Sauer CJ, Langer JC, Wales PW. The versatility of the umbilical incision in the management of Hirschsprung's disease. *J Pediatr Surg* 2005; **40**:385–389.
- 11 Besson R, Sfeir R, Salakos C, Debeugny P, et al. Congenital pyloric stenosis: a modified umbilical incision for pyloromyotomy. *Pediatr Surg Int* 1997; **12** (2/3):224–225.
- 12 Poli-Merol ML, Francois S, Lefebvre F, Bouche Pillon-Persyn MA, Lefort G, Daoud S. Interest of umbilical fold incision for pyloromyotomy. *Eur J Pediatr Surg* 1996; **6**:13–14.
- 13 Misra D, Mushtaq I. Surface umbilical pyloromyotomy. *Eur J Pediatr Surg* 1998; **8**:81–82.
- 14 Khan AR, Al-Bassam AR. Circumbilical pyloromyotomy: larger pyloric tumours need an extended incision. *Pediatr Surg Int* 2000; **16** (5–6):338–341.
- 15 Lin JY, Lee ZF, Chang YT. Transumbilical management for neonatal ovarian cysts. *J Pediatr Surg* 2007; **42**:2136–2139.
- 16 Soutter AD, Askew AA. Transumbilical laparotomy in infants: a novel approach for a wide variety of surgical disease. *J Pediatr Surg* 2003; **38**:950–952.
- 17 Alkhatrawi T, Elsherbini R, Ouslimane D. Umbilical site for temporary colostomy in anorectal malformations: is it cosmetically preferable? *Ann Pediatr Surg* 2013; **8**:4.
- 18 Brain AJ, Roberts DS. Who should treat pyloric stenosis: the general or specialist pediatric surgeon? *J Pediatr Surg* 1996; **31**:1535–1537.
- 19 Royal RE, Linz DN, Gruppo DL, Ziegler MM, et al. Repair of mucosal perforation during pyloromyotomy: surgeon's choice. *J Pediatr Surg* 1995; **30**:1430–1432.
- 20 Hashish AA. Minimally invasive surgery for ovarian cysts in children: transumbilical versus laparoscopic approach. *Ann Pediatr Surg* 2011; **7**:117–122.
- 21 Murphy FJ, Mohee A, Khalil B, Lall A, Morabito A, Bianchi A. Versatility of the circumbilical incision in neonatal surgery. *Pediatr Surg Int* 2009; **25**:145–147.
- 22 Menzies D. Peritoneal adhesions. Incidence, cause, and prevention. *Surg Annu* 1992; **24** (Pt 1):27–45.
- 23 Menzies D, Ellis H. Intestinal obstruction from adhesions – how big is the problem? *Ann R Coll Surg Engl* 1990; **72**:60–63.
- 24 Iwanaka T, Uchida H, Kawashima H, Nishi A, Kudou S, Satake R. Complications of laparoscopic surgery in neonates and small infants. *J Pediatr Surg* 2004; **39**:1838–1841.
- 25 Blumer RM, Hessel NS, van Baren R, Kuyper CF, Aronson DC. Comparison between umbilical and transverse right upper abdominal incision for pyloromyotomy. *J Pediatr Surg* 2004; **39**:1091–1093.
- 26 Leclair MD, Plattner V, Mirallie E, Lejus C, Nguyen JM, Podevin G, Heloury Y. Laparoscopic pyloromyotomy for hypertrophic pyloric stenosis: a prospective, randomized controlled trial. *J Pediatr Surg* 2007; **42**:692–698.