

Suboptimal correction of low anorectal anomalies: a possible cause for intractable constipation in children

Amr A. Abouzeid^a, Ahmed B. Radwan^a, Shaimaa A. Mohammad^b, Mohamed Eldebeiky^a and Mosad El-Behery^a

Background Constipation is a common problem among patients following the repair of low anorectal anomalies. We present our experience in managing constipation in a group of these patients with reoperation to correct residual anterior anal misplacement.

Patients and methods The study included pediatric patients presenting with significant constipation following the repair of low anorectal anomalies. Patients with evidence of residual anterior anal misplacement (either clinically, by means of MRI, or using electrical muscle stimulation) were offered a reoperation to bring their ani backward to an orthotopic position.

Results Thirteen patients were included in the study between September 2009 and June 2015. Their ages ranged from 1.5 to 10 years. The primary anomaly was rectoperineal fistula in 10 (seven boys and three girls) and rectovestibular in three girls. Two types of reoperations were performed: a posterior anoplasty with posterior sphincterotomy (five cases), and a limited sagittal anorectoplasty (eight cases). Straining at defecation was

relieved in all patients. Of the 13 patients, nine were relieved from their constipation (69%) and had regular bowel movements without medications. The remaining four (31%) showed partial improvement.

Conclusion Among patients with low anorectal anomalies, suboptimal correction with residual anterior anal misplacement represents one correctable cause for persistence of constipation. *Ann Pediatr Surg* 12:142–149 © 2016 Annals of Pediatric Surgery.

Annals of Pediatric Surgery 2016, 12:142–149

Keywords: constipation, low anorectal anomalies, MRI, perineal fistula, vestibular fistula

Departments of ^aPediatric Surgery and ^bRadiodiagnosis, Faculty of Medicine, Ain-Shams University, Cairo, Egypt

Correspondence to Amr A. Abouzeid, MD, Lotefy El-Sayed Street, 9 Ain-Shams University Buildings, Abbassia, Cairo 11657, Egypt
Tel: +20 111 656 0566; fax: +20 224 830833;
e-mail: amrabdelhamid@hotmail.com

Received 26 January 2016 accepted 8 June 2016

Introduction

In 1978, Hendren [1] and Leape and Ramenofsky [2] first reported the association of constipation with anterior displacement of the anus in children. Patients were reported to have symptoms in the form of straining and severe pain on defecation, dating since birth or time of weaning (which was of greater concern to parents compared with constipation) [2]. These patients were successfully managed with posterior anoplasty. At that time, Hendren made a clear statement: 'I believe that many patients who have been labeled as having refractory 'psychogenic constipation' or 'habit constipation', in fact, have unrecognized slight, or sometimes obvious, anterior displacement of the anus. Operation can relieve many of these patients of the need to continue their cathartic programs' [1].

Similarly, we thought that the reported high incidence of constipation following the repair of low anorectal anomalies [3,4] may be related (in certain situations) to the undercorrection of the anomaly, with residual degree of anterior anal displacement. In the literature, several causes have been investigated to explain persistence of constipation after the repair of anorectal anomalies: narrow neoanus with the need for dilatation [4], hypomotility of a hugely dilated rectosigmoid colon, neurogenic causes, dyssynergic defecation [5], and the possibility of associating aganglionosis [6]. No single factor could totally explain the pathogenesis of constipation in these patients that would suggest a multifactorial etiology. However, to the best of

our knowledge, the effect of residual anterior anorectal misplacement on the process of defecation has not been sufficiently investigated [7].

Precise judging on the anal position as normal or displaced is not an easy job, due to the wide variation between individuals in their perineal topography [1]. This becomes even more difficult after the scarring of previous perineal operations. The use of electrical muscle stimulation under anesthesia to determine the exact location of the anus in relation to the sphincter muscles can be of great help and is considered the gold standard [3,4]. The MRI is another useful tool (with no ionizing radiation) that has been used extensively in our unit over the last years for studying patients with anorectal anomalies.

In this report, we present our experience in managing a group of pediatric patients presenting with constipation following a previous surgery for low anorectal anomalies and the outcome of reoperations for residual anterior anal displacement in these patients.

Patients and methods

The study included pediatric patients presenting with constipation following the repair of low anorectal anomalies (rectoperineal and rectovestibular fistulae). All patients complained of failure to pass stools spontaneously with varying degrees of severity (Table 1). Most parents gave a history for their children suffering from

Table 1 Varying degrees of severity of constipation among operated cases of low anorectal anomalies

Degree of constipation following the repair of low anorectal anomalies	Failure to pass stools spontaneously (usually for more than 5 successive days)
Mild	Requires regular laxatives to evacuate
Moderate	Requires regular enemas to evacuate
Severe	Uncontrolled with medical treatment (laxatives and enemas)

severe straining at defecation; others had fecal soiling (pseudoincontinence) (Tables 2 and 3). Patients with true fecal incontinence were excluded.

Clinical examination was performed to identify the position and caliber of the anus. In some cases, diagnosing anterior anal misplacement was quite evident clinically by the presence of a posterior skin dimple marking for the predestined site of the anus (Fig. 1a). Barium enema (when performed) usually showed isolated dilatation of the rectum and distal sigmoid colon with exaggerated posterior rectal shelving in lateral films.

Multiple pulse sequence MRI was performed to identify the relation of the anal canal to the surrounding soft tissue structures. Sedation with chloral hydrate (occasional general anesthesia) was needed in young uncooperative children. The diagnosis of anterior anal misplacement was confirmed based on our previous experience with studying the MRI anatomy in primary cases with rectoperineal fistula [8]. In the midsagittal plane, the anteriorly misplaced distal anal canal was seen descending in front of the ‘hypointense’ muscle sphincter (Figs 1d, 2a and 3a). In the axial plan, at the level of the distal anal canal, the transversus perineal muscles can represent an important landmark for the normal anterior boundary of the anal canal (Fig. 4).

Other investigations included renal ultrasound to screen for possible associating renal anomalies, plain radiograph of the sacrum, and electrical stimulation of the external anal sphincter under general anesthesia in selected (equivocal) cases.

After approval of the internal review board, patients suffering from significant (moderate to severe) constipation with an evidence of anterior anal misplacement (clinically, radiologically, or by electrical muscle stimulation) were offered a reoperation. The option of reoperation to bring the anus backward was discussed with the parents. This included the type of operation, expected outcome, and possible risk for wound complications (a temporary colostomy may turn to be necessary).

Surgical technique

Before the operation, patients were hospitalized for 48 h for bowel preparation (restriction of oral intake to clear fluids and evacuation enemas). Two types of surgical techniques were performed according to the degree of residual anterior anal misplacement. When the anus was slightly displaced forward with a good-looking perineum, a posterior anoplasty was usually sufficient (Fig. 3). However, with more obvious

Table 2 The outcome of reoperation (posterior anoplasty) in patients presenting with constipation following previous repair of low anorectal anomalies

Age (years)	Sex	Type of anomaly	Initial (primary) operation	Severity of constipation	Type of operation	Degree of symptomatic improvement	Follow-up
1	Male	Rectoperineal	Performed elsewhere, probably Y-V anoplasty (according to the scar)	Severe constipation. Fecal impaction.	Posterior anoplasty	Regular defecation without medications	Lost to follow-up after 1 month
2	Male	Rectoperineal	Limited PSARP, at our pediatric surgery unit	Moderate constipation. Straining at defecation. Frequent soiling (2-3 times/day).	Posterior anoplasty	Regular voluntary defecation without medications. No straining at defecation. Occasional soiling (every other day).	8 months
3	Female	Rectoperineal	Limited PSARP, at another pediatric surgery unit	Severe constipation. Straining at defecation. Fecal soiling.	Posterior anoplasty	Regular voluntary defecation without medications. No straining at defecation. No soiling.	6 months
4	Female	Rectovestibular	Limited PSARP with covering colostomy, at our pediatric surgery unit	Moderate constipation	Posterior anoplasty	Regular voluntary defecation without medications	6 months
5	Male	Rectoperineal (bucket-handle)	Y-V anoplasty, at our pediatric surgery unit	Moderate constipation	Posterior anoplasty	Regular voluntary defecation without medications	2 months

PSARP, posterior sagittal anorectal plasty.

Table 3 The outcome of reoperation (sagittal anorectoplasty) in patients presenting with constipation following previous repair of low anorectal anomalies

	Age	Sex	Type of anomaly	Initial (primary) operation	Severity of constipation	Type of reoperation	Degree of symptomatic improvement	Follow-up
1	8 years	Male	Rectoperineal	Performed elsewhere, no available data	Severe constipation. Straining at defecation. Frequent daily soiling.	Limited PSARP	Regular voluntary defecation without medications. No straining; no soiling.	5 years
2	4 years	Male	Rectoperineal	Performed elsewhere, probably Y-V anoplasty (according to the scar)	Moderate constipation. Straining at defecation.	Limited PSARP	Regular voluntary defecation without medications. No straining; no soiling.	2 years
3	9 years	Male	Rectoperineal	Performed elsewhere, no available data	Severe constipation. Straining at defecation. Frequent daily soiling.	Limited PSARP	Daily laxatives to evacuate (4 × 12 mg senna). Disappearance of straining at defecation. Occasional soiling.	1 year
4	1.5 years	Male	Rectoperineal	Performed elsewhere, no available data	Moderate constipation. Straining at defecation.	Limited PSARP	Daily laxatives to evacuate No straining.	4 months
5	4.5 years	Female	Rectovestibular	ASARP, at our pediatric surgery unit	Severe constipation. Straining at defecation. Fecal soiling.	ASARP	Daily laxatives to evacuate (2 × 12 mg senna). No straining; no soiling.	3 months
6	4 years	Female	Rectoperineal	ASARP with covering colostomy, at our pediatric surgery unit	Severe constipation. Straining at defecation. Fecal soiling.	ASARP	Regular voluntary defecation without medications. No straining; no soiling.	3 months
7	6 years	Female	Rectovestibular	ASARP, at our pediatric surgery unit	Severe constipation. Straining at defecation. Fecal soiling.	ASARP	Daily laxatives to evacuate (2 × 12 mg senna). No straining; no soiling.	2 months
8	15 months	Female	Rectoperineal	ASARP, at another pediatric surgery unit	Moderate constipation. Straining at defecation.	ASARP	Regular defecation without medications. No straining; no soiling.	2 months

ASARP, anterior sagittal anorectoplasty; PSARP, posterior sagittal anorectal plasty.

degrees of anterior anal displacement (associated with a short perineum), complete mobilization of the anorectum through a limited sagittal anorectoplasty was performed (Figs 1 and 2).

The patient is placed either in the prone position (usually for male patients; Fig. 1), or in the supine lithotomy position (usually for female patients; Fig. 2). The distance required to bring the anus backward to an orthotropic position is estimated and marked on the skin by means of silk stitches (Figs 2 and 3). This is performed guided by the special color and shape of the anal skin pit and using the electrical muscle stimulator (when available).

First surgical technique 'posterior anoplasty'

An incomplete circumferential incision (similar to that described by Hendren) [1] is made around the anus posteriorly, starting from the 1 to the 11 o'clock position. Another posterior midline incision is made starting from the anus anteriorly and extending backward to the estimated distance needed to bring the anus backward to an orthotropic position. The midline incision is deepened, completely splitting the sphincteric muscles posterior to the anorectum. From the posterior midline incision, the dissection is extended on both sides of the anorectum (lateral walls) to free it from the surrounding attachments. Dissection continues until the posterior wall of the anorectum is completely mobile that it can be pulled backward (without tension) to take its new orthotropic position within the split open sphincteric

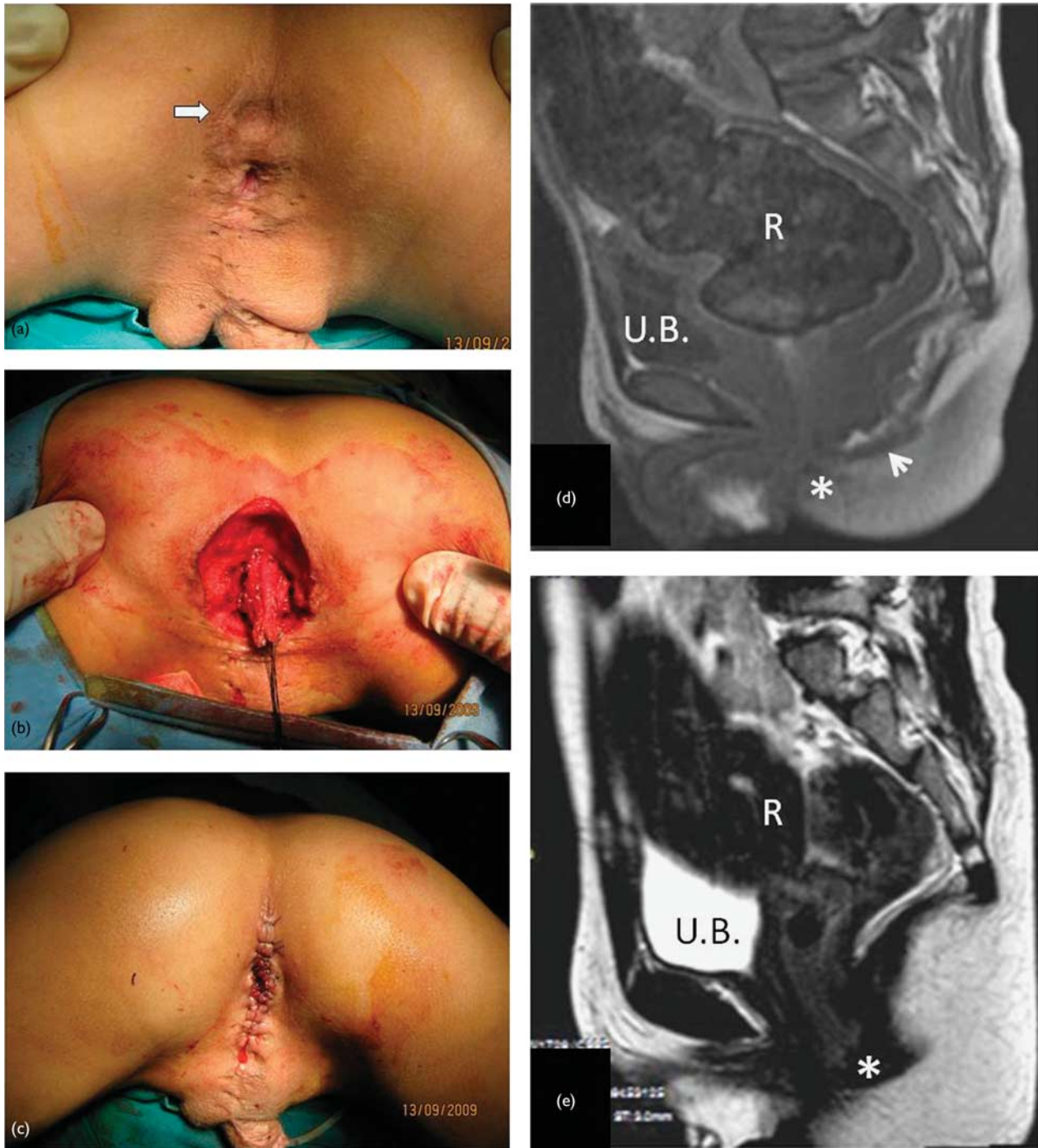
muscles. After trimming of the edges, the anocutaneous anastomosis is completed (Fig. 3).

Second surgical technique 'limited sagittal anorectoplasty'

This technique differs from the former in the circumferential incision around the anus being a complete one, allowing for complete mobilization of the anus backward. A posterior midline incision is deepened splitting the sphincteric muscles open (similar to the first technique). Dissection starts at the back and sides of the rectum, keeping the plane of dissection just outside the rectal wall (as recommended by Dr Peña, to avoid interruption of the rectal submucosal blood supply) [9]. Dissection is then completed all around, separating the anorectum from the anterior structures as well (the vagina in female, and the bulbospongiosum in male patients). In male patients, the presence of a urinary catheter is important for identifying the urethra during the dissection to guard against its injury. The dissection continues to free a sufficient length of the rectum (about 4–5 cm), to secure the anocutaneous anastomosis without tension (which is considered a major risk factor for postoperative wound disruption) [10]. The anocutaneous anastomosis is completed in the new orthotropic position, followed by reconstruction of the perineum (Fig. 1).

Postoperative care: oral intake is allowed on the first and fourth postoperative days for a posterior anoplasty and a formal anorectoplasty, respectively. Oral laxatives are added

Fig. 1



An 8-year-old boy presenting with intractable constipation and fecal soiling (case 1; Table 3). There is a history of anooplasty for a low anorectal anomaly in the neonatal period. (a) Perineal inspection showing a postanal skin dimple marking for the predestined site of the anus (white arrow). (b) Reoperation by a limited PSARP. (c) Repositioning of the anorectum backward in the center of the muscle complex. (d) Preoperative midsagittal MRI showing the anteriorly misplaced anal canal (*) descending in front of the 'hypointense' muscle sphincter (arrow-head). (e) Repeat MRI study 3 years following the reoperation and clinical improvement showing less rectal distension (R) and less compression on urinary bladder (UB). PSARP, posterior sagittal anorectal plasty.

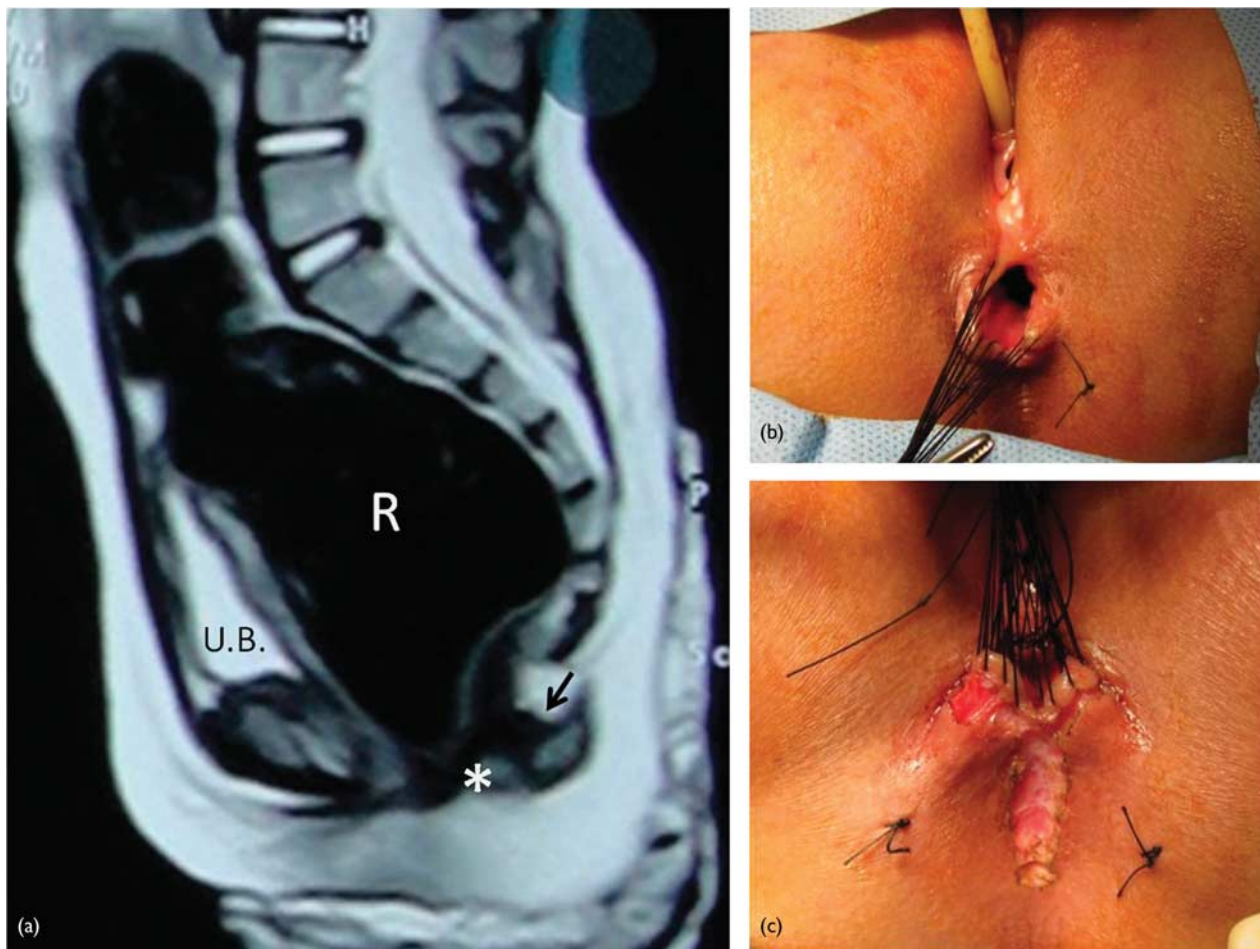
with the progression of feeding for 2–3 weeks (may continue for a longer period if constipation persists).

Results

Between September 2009 and June 2015, 18 patients presented with constipation following the repair of low anorectal anomalies. Two patients with mild constipation and three other patients who preferred to continue with

their conservative bowel management programs were excluded from the study. The remaining 13 patients were included. Their ages ranged from 1.5 to 10 years (median 4 years; mean 4.4 years). The primary anomaly was rectoperineal fistula in 10 children (seven boys and three girls) and rectovestibular fistula in three girls. All patients in the study had good anal caliber (admitting Hegar dilator size 14–16 depending on the age of the patient), with no significant

Fig. 2



A 4-year-old girl presenting with severe constipation following a previous repair (limited PSARP) of rectoperineal fistula (case 6; Table 3). (a) MRI (midsagittal T2WI) showing hugely distended rectum (R) compressing the urinary bladder (UB) anteriorly. The anal canal (*) is seen displaced anteriorly in front of the hypointense muscle complex (black arrow). Note the normal development of the sacrum and the coccyx in this patient. (b,c) Limited sagittal anorectoplasty to correct residual anterior anal misplacement. The posterior limit of the muscle complex is determined by muscle stimulator and marked on the skin by means of two silk stitches. Note the presence of constipation in this patient despite having a very wide and patulous anus (b). PSARP, posterior sagittal anorectal plasty.

sacral abnormalities (Fig. 3a). The diagnosis of anterior anal misplacement was based on clinical examination and was confirmed with MRI. Electrical muscle stimulation of the external anal sphincter under general anesthesia was needed for further confirmation in two cases with equivocal findings.

A posterior anoplasty with posterior sphincterotomy was performed in five cases (first group; Table 2), whereas complete mobilization and repositioning of the anorectum (limited sagittal anorectoplasty) was performed in eight (second group; Table 3). Partial wound dehiscence occurred in one case from the second group on the sixth postoperative day, which was managed conservatively without delayed sequelae.

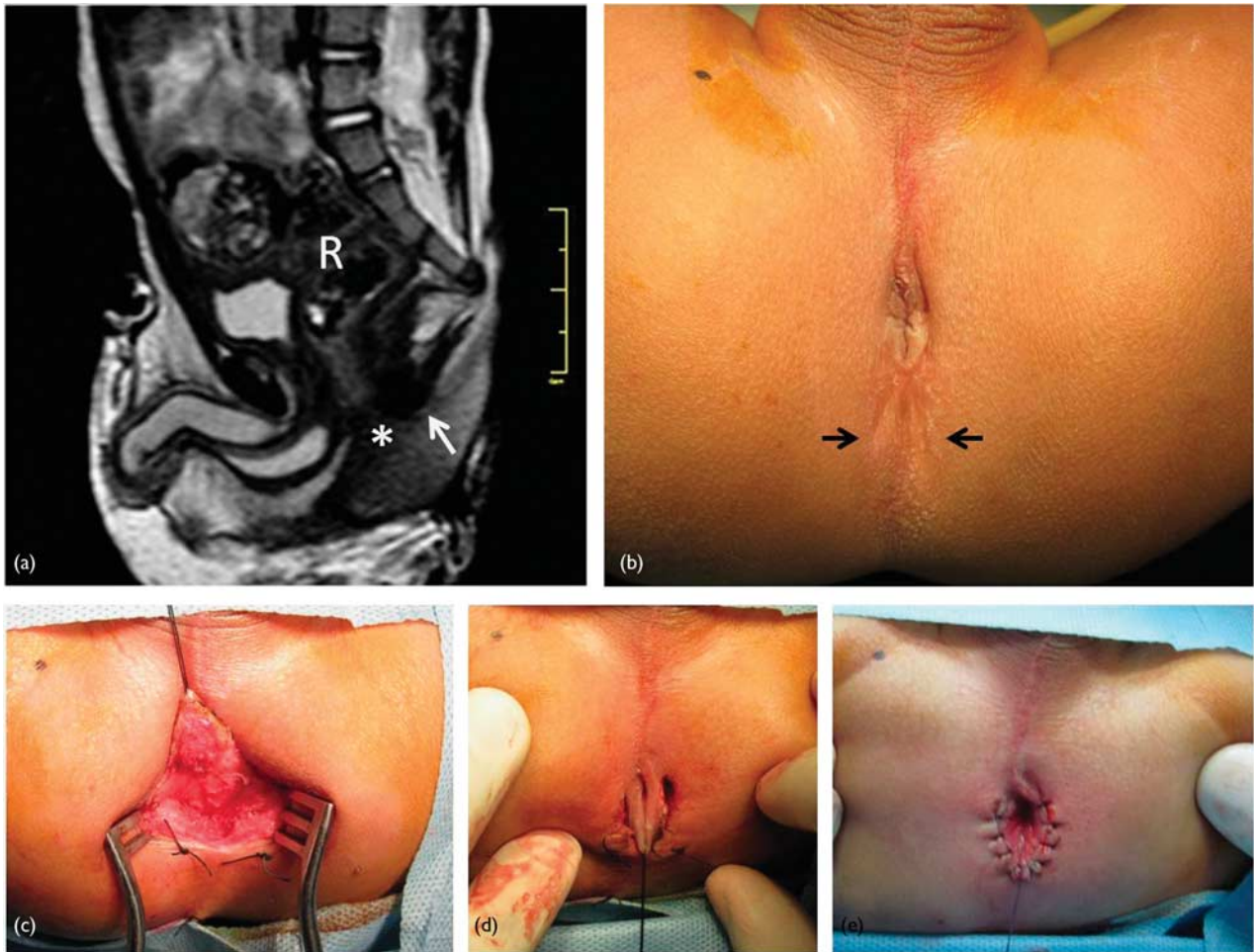
Straining and pain at defecation were relieved in all patients. Of the 13 patients, nine were relieved from their constipation and had regular bowel movements without medications. The remaining four (31%) showed partial improvement as regards the severity of constipation (more easily managed) (Tables 2 and 3). Follow-up ranged from 1 month to 5 years (median 4 months; mean 10 months).

Discussion

The first successful anoplasty for a case of imperforate anus was reported by Amussat in 1835 [11], and, since that time, preserving the potential for fecal continence after the operation has been a major concern among both patients and doctors. However, postoperative constipation was usually overlooked by the greater impact of fecal incontinence. In 1982, Peña and Devries [12] introduced their trans-sphincteric midline posterior sagittal approach, which has revolutionized the repair of anorectal anomalies with superior demonstration of the anatomy. Their technique was associated with widespread acceptance and improvement of the functional outcome as regards fecal continence. Consequently, the other unresolved functional problem 'constipation' began to rise to the surface of attention, especially following the repair of low anorectal anomalies [3]. In certain situations, constipation has been shown to cause considerable distress among these patients in the form of severe straining at defecation and pseudoincontinence [4].

The anorectum lies in the center of the pelvis and is surrounded by a complex arrangement of muscles, sphincters, and ligaments [13]. The integrated action of these

Fig. 3



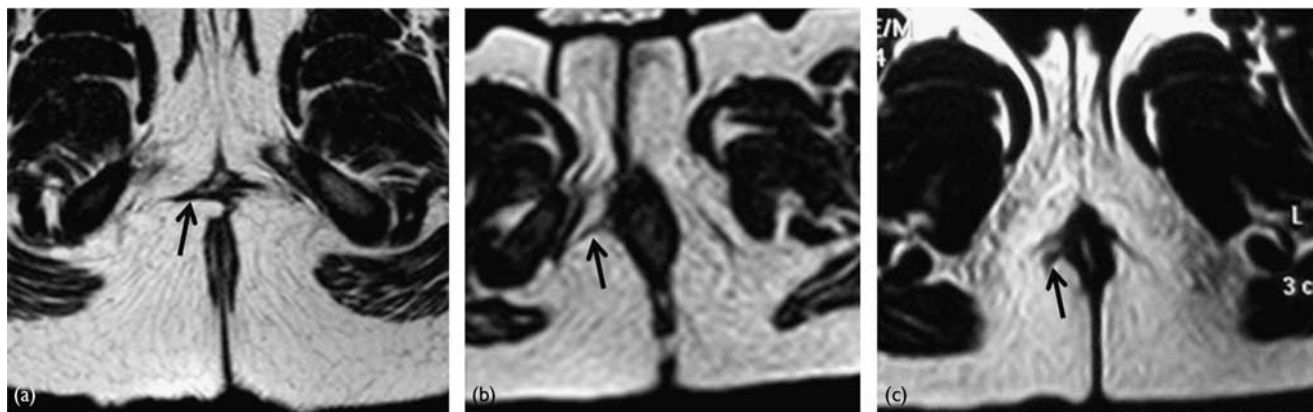
Posterior anoplasty procedure for a 1-year-old boy presenting with constipation after previous Y-V plasty for a 'bucket-handle' anorectal anomaly (case 5; Table 2). (a) MRI (midsagittal T2WI) showing a loaded rectum (R). The anal canal (*) is seen descending in front of the hypointense muscle complex (white arrow). Note the sacral fusion between S2-S3 and S4-S5. (b) The anus is located anterior to the center of the muscle complex (confirmed by electrical muscle stimulator). Black arrows point to the posterior limit of the muscle complex, which is then marked on the skin by means of silk stitches. (c) The postanal midline incision is deepened splitting the muscle complex open. The incision extends backward to the posterior limit of the muscle complex (marked on the skin by means of silk stitches). (d,e) The posterior wall of the anal canal is pulled backward within the split open muscle complex, and the anocutaneous anastomosis is completed in the new orthotopic position.

muscles is responsible for achieving fecal continence and facilitating defecation when appropriate. It is quite expected that a deviation from this precise pelvic arrangement would disturb the directions of the muscle vector forces around the anal canal, resulting in some sort of anorectal dysfunction [8,13]. Surgical dissection during the repair of anorectal anomalies (confirmed by electrical muscle stimulation) has demonstrated a dissociation between bowel termination (displaced forward) and the sphincter muscle complex, which is found 'orthotopically' at the predestined site of the anal canal (probably due to their different embryological origin). This is well consistent with the MRI findings in these patients. In minor forms of the anomaly (rectoperineal fistula), this dissociation is subtle and distal, which we could demonstrate in a previous study [8] as a separation between the bowel termination (anal canal) and its outer muscle coat. Van Beers *et al.* [14] have shown this outer muscle coat to be consistent of two muscles (the external sphincter and the longitudinal muscle) [8]. The anteriorly displaced anal canal is crossing with the vertical fibers of the longitudinal muscle with a variable angle of inclination corresponding to the

degree of anterior anal displacement [8]. During defecation, contraction of the longitudinal muscle will squeeze and close the anteriorly displaced anal canal obstructing defecation [8], instead of shorting the canal to facilitate expulsion of feces [15,16]. We hypothesized that bringing the bowel termination backward will restore its normal alignment within the outer muscle cuff, which can help in regaining normal anorectal defecatory function [8]. This can provide explanation for the reported relief of constipation in patients with anteriorly displaced anus who were treated with posterior anoplasty [1,2].

On the basis of the above-mentioned hypothesis, we surgically treated a group of patients suffering from constipation after previous repair of low anorectal anomalies and with residual anterior anal misplacement, by bringing their ani backward to an orthotopic position. Relief of constipation was achieved in nine patients (69%) who were able to defecate spontaneously without medications. Their parents showed much appreciation and were very glad having their children relieved from

Fig. 4



Axial cuts of MRI at the level of the distal anal canal demonstrating the residual anterior anal misplacement in patients presenting with constipation following the repair of low anorectal anomalies (b,c) as compared with a normal control (a). Note the position of the transversus perineal muscles (black arrow), which normally meet in front of the anal canal marking for its normal anterior limit (a).

their usual suffering at defecation. This successful outcome was seen in patients operated at different age groups (even in late childhood), with a follow-up ranging from 1 month up to 5 years (mean 10 months). Less satisfactory results were obtained in the remaining 31% of patients (four patients) who remained in need for regular laxatives to evacuate. Failure to achieve the same success in all patients would confirm the multifactorial etiology of constipation; however, the anatomical factor due to anterior anal misplacement in these patients remains a major and 'correctable' cause.

Looking through the current surgical techniques used in the repair of low anorectal anomalies, we have noticed three main factors contributing to suboptimal correction and resulting in residual anterior anal displacement. The first is related to the repair of what is known as 'bucket-handle deformity' in male patients. This anomaly, which is a variant of rectoperineal fistula, is occasionally treated with a simple Y-V plasty to dilate the narrow orifice (as if it were just anal stenosis), while leaving the bowel termination in its ectopic position anterior to the center of the external muscle cuff. The second factor is related to the repair of rectoperineal/vestibular fistulae in female patients using the anterior sagittal approach. Trying to preserve the continence mechanism, there is a tendency not to complete the splitting through the muscle complex backward. Okada *et al.* [17] and Kulshrestha *et al.* [18] recommended cutting only through the anterior fibers while carefully preserving the posterior part of the muscle complex, which we believe will necessarily end with a neoanus anterior to the center of the muscle complex. The third factor is related to the degree of anorectal mobilization during sagittal anorectoplasties. Insufficient dissection of the rectum off the anterior structures (vagina or bulbospongiosum) will result in excess tension on the anocutaneous anastomosis, with subsequent increased incidence of wound disruption and anterior anal retraction.

The decision to reoperate in this group of constipated patients with a degree of residual anterior anal misplacement was not free of controversies. One opposing opinion

argued the benefit of reoperation in these patients who will anyway remain constipated [3], and that the expected benefit does not outweigh the risk for wound disruption and the possible need for a covering colostomy [4]. Another concern was the risk of compromising the continence mechanism by incising through the sphincters during repositioning of the anorectum backward, and researchers opined that constipation is by far better compared with incontinence. To answer these questions, first we have to agree on some concepts. In the presence of an anatomical abnormality, constipation becomes more intractable and distressing due to the existence of mechanical rather than just functional obstruction. Restoring the normal anatomy (normal alignment of the anal canal within the outer muscle cuff) can help in relieving constipation to a great extent (69% of our cases), or at least make it more manageable. As regards the need for a covering colostomy, we did not find this to be necessary in any of our patients; a low incidence of postoperative wound complications can usually be achieved, not only with the simple posterior anoplasty [4] but also with the more extensive sagittal anorectoplasties (provided that effective anorectal mobilization is performed to avoid tension at the anocutaneous anastomosis) [7,10,18–21]. Lastly, none of our patients turned to be incontinent; the trans-sphincteric sagittal approach for treating anorectal anomalies (introduced by Dr Peña) is a famous technique that has been already tested in many centers all over the world and has proved to be safe and effective in preserving continence.

In their study on the long-term outcomes among operated cases of low anorectal anomalies, the Finland group reported a significant decline in the prevalence of constipation with age (from 45 to 12%) [22]. Among those patients more than 12 years of age, the prevalence of constipation was still higher but not significantly different from controls of the same age [21]. We believe our study group was different in terms of the degree of constipation being more severe and disabling, probably due to the presence of residual anatomical abnormality. Our patients

showed obvious clinical improvement following the surgical intervention, which appears to be a real attractive option for both patients and their parents, instead of spending years suffering from intractable constipation and the related bowel management programs.

Reoperations to improve bowel control (fecal continence) after the repair of anorectal anomalies are frequently described in the literature [23,24]. However, this report highlights another indication for reoperation, which is correction of constipation. We do agree that situations in which redo operations are needed should be avoided whenever possible, as the primary operation represents the patient's best chance for a good functional outcome. In this report, the exact etiology for suboptimal correction with residual anterior anal misplacement has not been sufficiently addressed due to some missing data of the primary operations; however, the studied group probably represents a minority from a large pool of successfully repaired anomalies. Although the study is limited by the small number of cases, the results are encouraging as regards the clinical improvement and the low incidence of complications. Further studies with larger number of cases at different centers are required to confirm the efficacy and reproducibility of the technique.

Conclusion

Among patients with low anorectal anomalies, suboptimal correction with residual anterior anal misplacement represents one 'correctable' cause for persistence of constipation.

Acknowledgements

Conflicts of interest

There are no conflicts of interest.

References

- Hendren WH. Constipation caused by anterior location of the anus and its surgical correction. *J Pediatr Surg* 1978; **13**:505–512.
- Leape LL, Ramenofsky ML. Anterior ectopic anus: a common cause of constipation in children. *J Pediatr Surg* 1978; **13** (6D): 627–630.
- Peña A, Bischoff A, eds. Rectoperineal fistula. *Surgical treatment of anorectal problems in children*. Springer (eBook); 2015. pp. 107–127.
- Pakarinen MP, Rintala RJ. Management and outcome of low anorectal malformations. *Pediatr Surg Int* 2010; **26**:1057–1063.
- Van Meegdenburg MM, Heineman E, Broens PM. Dyssynergic defecation may aggravate constipation: results of mostly pediatric cases with congenital anorectal malformation. *Am J Surg* 2015; **210**:357–364.
- Peña A, El Behery M. Megacigmoid: a source of pseudocontinence in children with repaired anorectal malformations. *J Pediatr Surg* 1993; **28**:199–203.
- Wakhlou A, Pandey A, Prasad A, Kureel SN, Tandon RK, Wakhlou AK. Anterior sagittal anorectoplasty for anorectal malformations and perineal trauma in the female child. *J Pediatr Surg* 1996; **31**:1236–1240.
- Abouzeid AA, Mohammad SA, Khairy KT. MRI anatomy of anteriorly displaced anus: what obstructs defecation? *Pediatr Radiol* 2014; **44**:831–838.
- Levitt MA, Peña A. Operative management of anomalies in males. In: Holschneider AM, Hutson JM, editors. *Anorectal malformations in children*. Berlin Heidelberg: Springer-Verlag; 2006. pp. 295–302.
- Abouzeid AA. Securing the mucocutaneous anastomosis in the repair of low-anorectal anomalies. *Ann Pediatr Surg* 2015; **11**:185–191.
- Peña A, Bischoff A, eds. History of treatment of anorectal malformations. *Surgical treatment of anorectal problems in children*. Springer (eBook); 2015. pp. 1–16.
- Peña A, Devries PA. Posterior sagittal anorectoplasty: important technical considerations and new applications. *J Pediatr Surg* 1982; **17**:796–811.
- Petros P, Swash M. The musculo-elastic theory of anorectal function and dysfunction. *Pelviperrineology* 2008; **27**:89–93.
- Van Beers BE, Kartheuser A, Delos MA, Grandin C, Detry R, Jamart J, Pringot J. MRI of the anal canal: correlation with histological examination. *Magn Reson Imaging* 1996; **14**:151–156.
- Lunniss PJ, Phillips RK. Anatomy and function of the anal longitudinal muscle. *Br J Surg* 1992; **79**:882–884.
- Shafik A. A new concept of the anatomy of the anal sphincter mechanism and the physiology of defecation. III. The longitudinal anal muscle: anatomy and role in anal sphincter mechanism. *Invest Urol* 1976; **13**:271–277.
- Okada A, Kamata S, Imura K, Fukuzawa M, Kubota A, Yagi M, et al. Anterior sagittal anorectoplasty for rectovestibular and anovestibular fistula. *J Pediatr Surg* 1992; **27**:85–88.
- Kulshrestha S, Kulshrestha M, Singh B, Sarkar B, Chandra M, Gangopadhyay AN. Anterior sagittal anorectoplasty for anovestibular fistula. *Pediatr Surg Int* 2007; **23**:1191–1197.
- Kumar B, Kandpal DK, Sharma SB, Agrawal LD, Jhamariya VN. Single-stage repair of vestibular and perineal fistulae without colostomy. *J Pediatr Surg* 2008; **43**:1848–1852.
- Levitt MA, Peña A. Complications after the treatment of anorectal malformations and redo operations. In: Holschneider AM, Hutson JM, editors. *Anorectal malformations in children*. Berlin Heidelberg: Springer-Verlag; 2006. pp. 319–325.
- Wakhlou A, Kureel SN, Tandon RK, Wakhlou AK. Long-term results of anterior sagittal anorectoplasty for the treatment of vestibular fistula. *J Pediatr Surg* 2009; **44**:1913–1919.
- Kyrklund K, Pakarinen MP, Taskinen S, Rintala RJ. Bowel function and lower urinary tract symptoms in males with low anorectal malformations: an update of controlled, long-term outcomes. *Int J Colorectal Dis* 2015; **30**:221–228.
- Peña A, Bischoff A, eds. Reoperations. *Surgical treatment of anorectal problems in children*. Springer (eBook); 2015. pp. 349–360.
- Holschneider AM, Holschneider P. Operations to improve continence after previous surgery. In: Holschneider AM, Hutson JM, editors. *Anorectal malformations in children*. Berlin Heidelberg: Springer-Verlag; 2006. pp. 391–413.