

Abdominoplasty for Ladd's procedure: optimizing access and esthetics

Rachel Aliotta^a, Neilendu Kundu^a, Anthony Stallion^b
and Christi Cavaliere^a

Rotational anomalies occur when there is an abnormal arrest of rotation in the embryonic gut during development. The characteristic population affected is considered to be infants or young children, but in clinical practice, can be found in older children and adults as well. In these patients, the Ladd procedure is performed, whereby the abdomen is opened using traditional incisions, such as the midline laparotomy, for full visualization of the abdominal cavity. Despite providing excellent visualization, approaches such as this carry both increased surgical-site morbidity and an often-displeasing incision and visible scar. In this case report, we advocate consideration of the low transverse Pfannenstiel incision and approach used traditionally in cosmetic and reconstructive abdominoplasty for surgical access to the abdomen for Ladd's procedure. We believe that this alternative approach provides superior

visualization without compromising the integrity or the esthetics of the abdominal wall in appropriate populations desiring to minimize the morbidity and visibility of their scar. *Ann Pediatr Surg* 13:220–224 © 2017 Annals of Pediatric Surgery.

Annals of Pediatric Surgery 2017, 13:220–224

Keywords: adult, adolescent, aesthetics, abdominoplasty, Ladd procedure, open

^aDepartment of Plastic Surgery, Dermatology and Plastic Surgery Institute and ^bDepartment of Pediatric Surgery, Digestive Disease Institute, Cleveland Clinic Foundation, Cleveland, Ohio, USA

Correspondence to Christi Cavaliere, MD, Department of Plastic Surgery, Plastic Surgery and Dermatology Institute, Cleveland Clinic Foundation, Cleveland, OH 44115, USA
Tel: +1 216 444 6900; fax: +1 216 445 4487; e-mail: cavalic1@ccf.org

Received 15 December 2015 accepted 27 October 2016

Introduction

Rotational anomalies occur when there is an arrest of the normal embryonic gut rotation during the fourth through eight weeks of development, and occurs on average in 1/200 to 1/500 live births, with no sex preference [1]. In contrast with the traditional dogma, intestinal malrotation in older children and adults is relatively common, but may have a variable and often insidious presentation [2–7]. In older children, the symptoms may be vague and at times seem unconnected, including early satiety, bloating, dyspepsia, and emesis [6,8–10]. The anatomic basis for the clinical symptoms found in malrotation patients is because of both the narrow mesenteric base from which the small bowel is held, providing increased freedom and propensity to the volvulus, as well as the Ladd bands, which cross the duodenum, increasing the risk for obstruction [5,11].

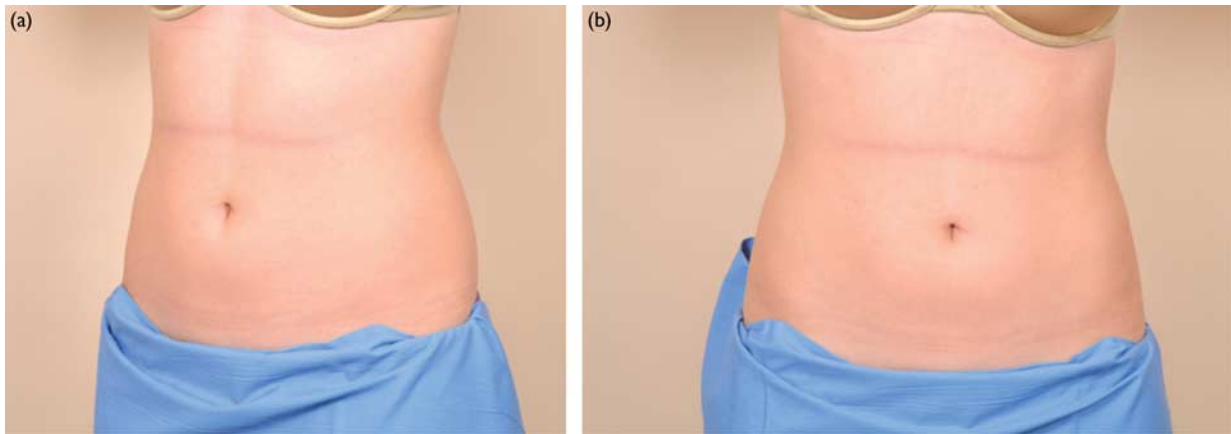
With exception to the laparoscopic approach, the Ladd procedure has remained largely unchanged since its inception and is traditionally performed by making a midline laparotomy or an omega incision. This ensures adequate visualization of the entire abdominal cavity for detorsing of the bowel and allows for dividing of any overlying bands from the bowel [12,13]. However, the midline incision is not without its own morbidity, mainly the risk of wound dehiscence and the occurrence of hernia [14–17]. Further, in patients where esthetics is of marked concern (e.g. adolescent females) presenting with congenital malrotation necessitating the Ladd procedure, these highly visible surgical approaches can become somewhat distressing, given the breadth of the traditional incision required to gain adequate surgical access needed.

The traditional abdominoplasty technique requires an incision within the patient's natural suprapubic crease that is taken laterally angled toward the anterior superior iliac spine. A circumumbilical incision is made and the inferior incision is dissected to the level of muscle fascia. The abdominal flap is elevated superiorly around the umbilicus and superiorly to the xiphoid and costal margins [18]. This approach provides theoretical access to and provides visualization of the entire abdominal compartment through a midline incision without compromising the cosmesis of the external abdominal wall; despite this, the approach is seldom utilized when gaining access to the abdominal compartment for general surgery procedures. Here, we present an abdominoplasty approach for Ladd's procedure as an effective and superior way to create an adequate visual field for bowel correction while preserving abdominal wall integrity and minimizing scar in a young woman.

Case presentation

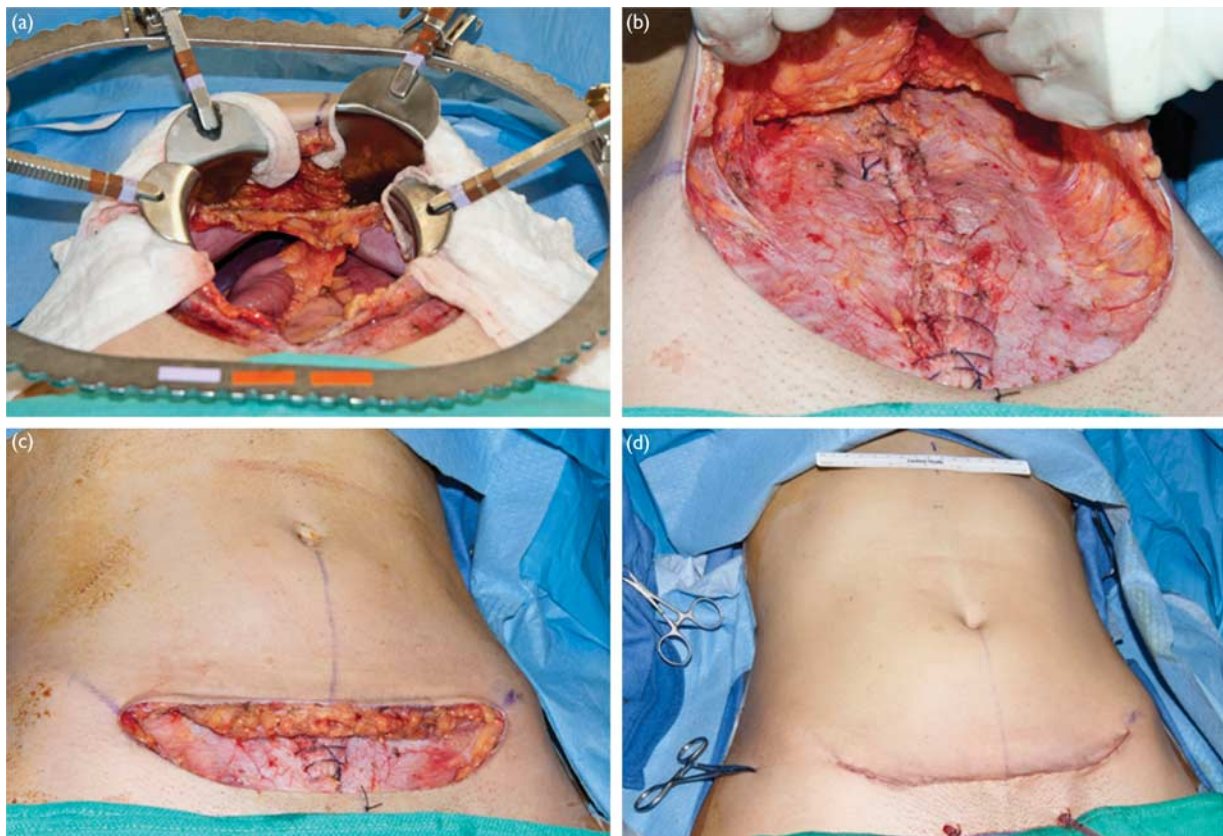
An otherwise healthy 19-year-old female college student presented to the General Surgery Clinic with a 1-year history of intermittent left lower quadrant abdominal pain with radiation to her back. She also noted intermittent epigastric pain that would oscillate in intensity and provide pain-free periods for weeks at a time. Her pain was accompanied by diarrhea and a strong urge to defecate with meals, with which she reported a five-pound weight loss. One month earlier, she had been seen in an outside hospital emergency department, where an abdominal computed tomography scan showed a probable small bowel intussusception in the right mid-abdomen at the inferior margin of the liver and lateral to the inferior pole of the right kidney. On physical exam,

Fig. 1



A thin 17-year-old female presented with a history and symptoms of intestinal torsion requiring Ladd's procedure [(a) oblique and (b) frontal view] and expressed concern that a traditional laparotomy incision would leave a disfiguring scar on her thin and youthful abdomen for life.

Fig. 2

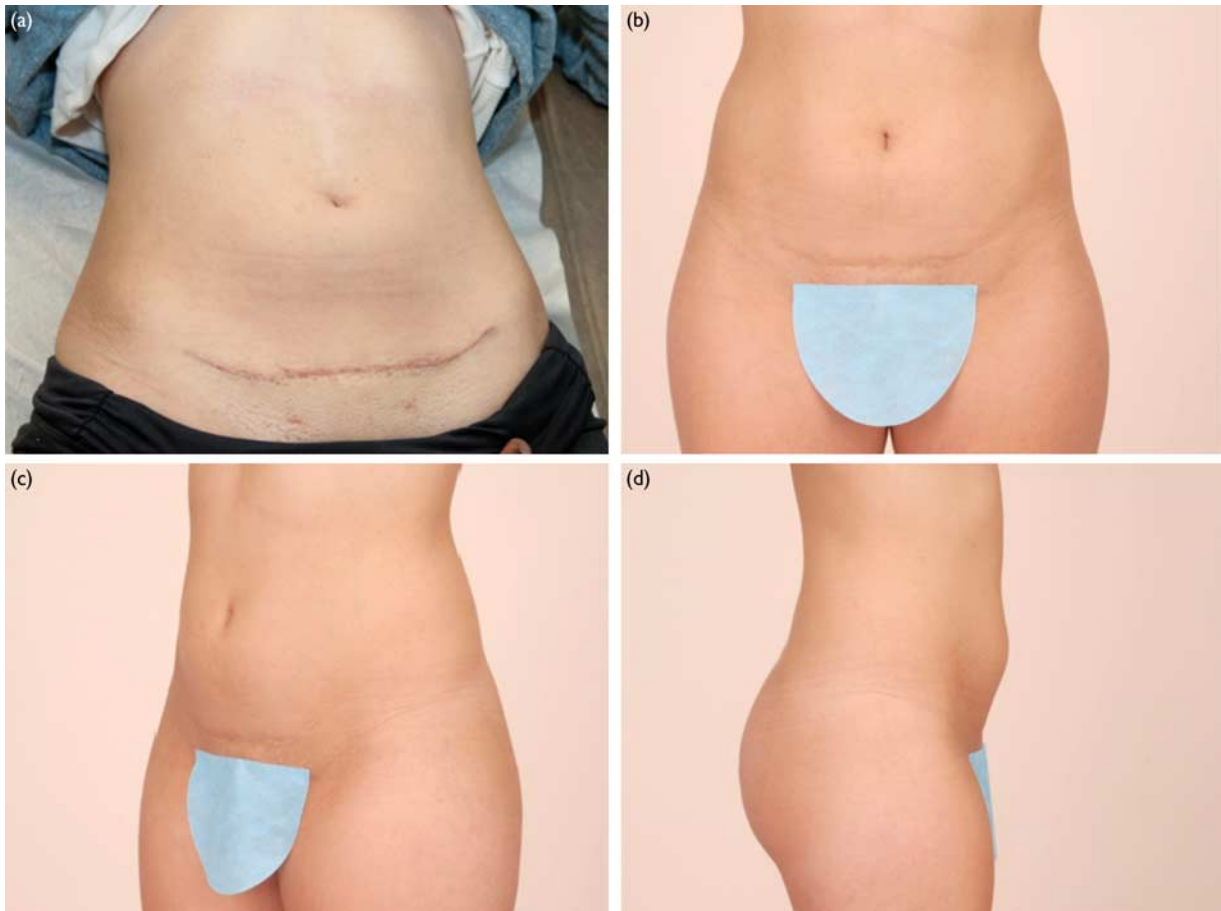

The patient underwent Ladd's procedure with access established through a low transverse pfannenstiell incision typically used in cosmetic abdominoplasty; the incision was made across the low abdomen down to the fascia and a longitudinal incision was then made through the fascia and peritoneum to gain unobstructed access to the entire abdominal cavity's contents (a); the fascia was closed with running heavy suture (b) and the abdominoplasty incision was closed in a layered manner (c) with fine suture with the placement of two suprapubic drains (d).

her abdomen was soft and mildly tender in the epigastrium and the left lower quadrant, but was nondistended and without palpable organomegaly or masses (Fig. 1). Because of the atypical age of her presentation, an esophagogastroduodenoscopy, pelvic

ultrasound, and computed tomography enterography were obtained, indicating malrotation. A discussion of the Ladd procedure ensued with the patient and family, who were concerned with the pending incision and abdominal scarring, thus prompting discussion about a possible novel

Fig. 3



At follow-up 1 month later, the patient was asymptomatic, with minimal sporadic abdominal pain relieved by ibuprofen; examination indicated a well-healing low transverse scar with no issues with dehiscence or soft tissue compromise (a) and with some expected darkening along the incisional scar. The patient returned 3 years later and happily reported that she remained symptom free and was pleased with her nearly invisible low-lying scar (b–d).

approach with the Plastic Surgery Team. Together, the patient underwent a traditional Ladd's procedure utilizing the abdominoplasty approach 4 months later (Fig. 2a–d). The postoperative course was unremarkable, she was tolerating an oral diet with regular bowel movements, and both Jackson–Pratt drains maintained minimal serosanguinous output and were removed before she was discharged home on postoperative day 4 from the regular nursing floor. All abdominal skin remained viable, with no evidence of hematoma, seroma, or surgical-site infection along the incisions. She was evaluated in both the Plastic Surgery and the Pediatric Surgery Clinic postoperatively at weeks 1 and 6 after the initial procedure, at which time it was noted that she was making remarkable progress after her operation (Fig. 3a), noting only occasional periumbilical abdominal pain, nonradiating and not related to meals, relieved with oral ibuprofen. Three years later, now in college, the patient returned for follow-up, stating that she was extremely pleased with both the functional improvement as well as her esthetic outcome, stating that she felt that her scar was 'nearly invisible' (Fig. 3b–d).

Operative technique

On inspection, the patient had a flat abdomen with no existing scars and no palpable hernias (Fig. 1). A low abdominoplasty-type incision was marked below the pubic hairline within a transverse crease and extended up laterally to within a few centimeters of the anterior superior iliac spine. The skin and subcutaneous tissue were elevated along the abdominal wall fascia within the areolar layer. Care was taken to avoid any damage to the abdominal wall fascia. The umbilicus was floated by transecting across the base with a combination of sharp and blunt dissection. The dissection was carried out to the costal margin in a regular abdominoplasty-type manner, creating visualization and access to the entire intra-abdominal compartment (Fig. 2a). After completion of the midline fascial closure following the Ladd procedure (Fig. 2b), the wound cavity was copiously irrigated and inspected. Hemostasis was achieved and the skin was excised. The umbilicus appeared viable and was tacked to the abdominal wall in the midline using an interrupted absorbable monofilament suture. The scarpa layer was closed with an interrupted monofilament in a

figure-of-eight manner and two 10-mm suprapubic drains were placed. The deep dermal layer was closed with an interrupted absorbable monofilament and a running subcuticular suture was placed (Fig. 2c,d).

Discussion

The morbidity associated with the midline laparotomy, primarily wound failure – including early wound dehiscence and incisional hernia formation, remains a significant problem in abdominal surgery, and has been discussed at length elsewhere in the literature. The incidence of abdominal wound dehiscence ranges from 0.25 to 3% and is associated with a mortality of up to 25%, most often seen at around 1 week after surgery [15–17]. Early laparotomy wound failure is a well-known mechanism for incisional hernia formation [14]; these incisional wound hernias are the most common complication of abdominal surgery that leads to reoperation today and is often accompanied by significant morbidity [19]. The use of autologous tissue for primary closure carries a reherniation rate of 60% [20] and despite advances in modern mesh products developed for reinforcement, incisional hernia reoperation rates continue to push unacceptable numbers up to 30% [21].

With the introduction of the minimally invasive laparoscopic approach in 1995 [22], its use has been predominantly advocated for use in malrotation without midgut volvulus; as in cases with volvulus, the bowel is often friable and vulnerable to perforation and because of the expedient nature of the surgery for survival [23,24]. In these cases, the open technique is often preferred. Advocates of the laparoscopic approach cite decreased postoperative pain and more rapid return of bowel function, and a shortened hospital stay, and many consider older children excellent candidates for laparoscopy compared with a neonate population [25–30].

However, given the increased complexity of malrotation, there is the potential difficulty with proper orientation of the bowel when performed laparoscopically either emergently or electively. Improper or incomplete detorsion of the midgut and incomplete lysis of congenital bands may be present, and performing the operation laparoscopically can prove to be technically challenging. It is logistically difficult with the access from a minimally invasive technique to obtain adequate and complete visualization of the mesenteric pedicle and all loops of the bowel. As cited by other advocates and in this case, it was felt by our institution surgeon's experience that open correction of malrotation is often more effective in preventing recurrent volvulus by inciting the secondary formation of new intra-abdominal adhesions, a secondary effect that may not be found as often when using laparoscopy [29].

Furthermore, in patients where esthetics is of particular concern, such as in adolescent and young adult women, the traditional open surgical approaches can become somewhat distressing when supraumbilical transverse or midline incisions in older patients must be made to gain adequate surgical access. The low transverse abdominoplasty approach adds minimal additional time to the case and confers little risk to the skin flaps created because of the

robust nature of the blood supply to the abdominal wall. In instances in which laparoscopic approaches can diminish some esthetic concerns, but are unable to address the intra-abdominal pathology present, the abdominoplasty approach for the Ladd's Procedure is an effective way to achieve both aims; in these cases, a superior way should be considered to create an adequate visual field for bowel correction while preserving abdominal wall integrity and minimizing scar in healthy young adults.

Conflicts of interest

There are no conflicts of interest.

References

- 1 Kluth D, Jaeschke-Melli S, Fiegel H. The embryology of gut rotation. *Semin Pediatr Surg* 2003; **12**:275–279.
- 2 Powell DM, Othersen HB, Smith CD. Malrotation of the intestines in children: the effect of age on presentation and therapy. *J Pediatr Surg* 1989; **24**:777–780.
- 3 Rescorla FJ, Shedd FJ, Grosfeld JL, Vane DW, West KW. Anomalies of intestinal rotation in childhood: analysis of 447 cases. *Surgery* 1990; **108**:710–715. [discussion 715–6].
- 4 Pickhardt PJ, Bhalla S. Intestinal malrotation in adolescents and adults: spectrum of clinical and imaging features. *Am J Roentgenol* 2002; **179**:1429–1435.
- 5 Wang CA, Welch CE. Anomalies of intestinal rotation in adolescents and adults. *Surgery* 1963; **54**:839–855.
- 6 Nehra D, Goldstein AM. Intestinal malrotation: varied clinical presentation from infancy through adulthood. *Surgery* 2011; **149**:386–393.
- 7 Maxson RT, Franklin PA, Wagner CW. Malrotation in the older child: surgical management, treatment, and outcome. *Am Surg* 1995; **61**:135–138.
- 8 Gamblin TC, Stephens RE, Johnson RK, Rothwell M. Adult malrotation: a case report and review of the literature. *Curr Surg* 2003; **60**:517–520.
- 9 Hsu SD, Yu JC, Chou SJ, Hsieh HF, Chang TH, Liu YC. Midgut volvulus in an adult with congenital malrotation. *Am J Surg* 2008; **195**:705–707.
- 10 Von Flüe M, Herzog U, Ackermann C, Tondelli P, Harder F. Acute and chronic presentation of intestinal nonrotation in adults. *Dis Colon Rectum* 1994; **37**:192–198.
- 11 Kanazawa T, Kasugai K, Miyata M, Miyashita M, Mizuno M, Nagase F, et al. Midgut malrotation in adulthood. *Intern Med* 2000; **39**:626–631.
- 12 Ladd WE. Congenital obstruction of the duodenum in children. *N Engl J Med* 1932; **206**:277–283.
- 13 Ladd WE, Gross RE. *Abdominal surgery of infancy and childhood*. Philadelphia, London: W. B. Saunders company; 1941.
- 14 Xing L, Culbertson EJ, Wen Y, Franz MG. Early laparotomy wound failure as the mechanism for incisional hernia formation. *J Surg Res* 2013; **182**:e35–e42.
- 15 Spiliotis J, Tsvieriotis K, Datsis AD, Vaxevanidou A, Zacharis G, Giafis K, et al. Wound dehiscence: is still a problem in the 21st century: a retrospective study. *World J Emerg Surg* 2009; **4**:12.
- 16 Waqar SH, Malik ZI, Razzaq A, Abdullah MT, Shaima A, Zahid MA. Frequency and risk factors for wound dehiscence/burst abdomen in midline laparotomies. *J Ayub Med Coll Abbottabad* 2005; **17**:70–73.
- 17 Rodriguez-Hermosa JI, Codina-Cazador A, Ruiz B, Gironès J, Pujadas M, Pont J, et al. Risk factors for acute abdominal wall dehiscence after laparotomy in adults. *Cir Esp* 2005; **77**:280–286.
- 18 Thorne C, Grabb WC, Smith JW. *Grabb and Smith's plastic surgery*, 6th ed. Philadelphia, PA: Wolters Kluwer Health/Lippincott Williams & Wilkins; 2007. p. 929.
- 19 Luijendijk RW, Hop WC, van den Tol MP, de Lange DC, Brasskma MM, IJzermans JN, et al. A comparison of suture repair with mesh repair for incisional hernia. *N Engl J Med* 2000; **343**:392–398.
- 20 Burger JW, Luijendijk RW, Hop WCJ, Halm JA, Verdaasdonk EGG, Jeekel J. Long-term follow-up of a randomized controlled trial of suture versus mesh repair of incisional hernia. *Ann Surg* 2004; **240**:578–583. [discussion 583–5].
- 21 Flum DR, Horvath K, Koepsell T. Have outcomes of incisional hernia repair improved with time? a population-based analysis. *Ann Surg* 2003; **237**:129–135.
- 22 Van Der Zee DB, Bax NM. Laparoscopic repair of acute volvulus in a neonate with malrotation. *Surg Endosc* 1995; **9**:1123–1124.
- 23 Draus JM Jr, Foley DS, Bond SJ. Laparoscopic Ladd procedure: a minimally invasive approach to malrotation without midgut volvulus. *Am Surg* 2007; **73**:693–696.
- 24 Gross E, Chen MK, Lobe TE. Laparoscopic evaluation and treatment of intestinal malrotation in infants. *Surg Endosc* 1996; **10**:936–937.

- 25 Matzke GM, Dozois EJ, Larson DW, Moir CR. Surgical management of intestinal malrotation in adults: comparative results for open and laparoscopic Ladd procedures. *Surg Endosc* 2005; **19**: 1416–1419.
- 26 Bass KD, Rothenberg SS, Chang JH. Laparoscopic Ladd's procedure in infants with malrotation. *J Pediatr Surg* 1998; **33**:279–281.
- 27 Hsiao M, Langer JC. Surgery for suspected rotation abnormality: selection of open vs laparoscopic surgery using a rational approach. *J Pediatr Surg* 2012; **47**:904–910.
- 28 Yamashita H, Kato H, Uyama S, Kanata T, Nishizawa F, Kotegawa H, *et al*. Laparoscopic repair of intestinal malrotation complicated by midgut volvulus. *Surg Endosc* 1999; **13**:1160–1162.
- 29 Chen LE, Robert, Langer, Jacob C. Laparoscopic versus open surgery for malrotation without volvulus. *Pediatr Endosurg Innov Tech* 2003; **7**: 433–438.
- 30 Oldham KT, Colombani PM, Foglia RP. *Malrotation Surgery of infants and children: scientific principles and practice*. Philadelphia, New York: Lippincott Raven Publishers; 1997.