

Recurrence of floor of the mouth dysontogenic cyst in childhood

Marcos Prada-Arias^a, Ana Lema-Carril^a, Margarita Montero-Sánchez^a, Alberto Pérez-Pedrosa^b, Jorge Mañas-Uxo^d and José R. Fernández-Lorenzo^c

The dysontogenic cysts of the floor of the mouth, which probably derive from pluripotent ectodermal cells entrapped during midline fusion of the branchial arches, include three histological subtypes: epidermoid, dermoid, and teratoid. The teratoid cyst, composed of ectodermal, endodermal, and mesodermal structures, is rare, with 26 cases reported in the English literature, most of them detected during childhood. We present a case of a teratoid cyst of the floor of the mouth in an 8-month-old boy, which was initially operated on the suspicion of ranula. A year after the operation a recurrent teratoid cyst was detected, with a sinus tract to the floor of the mouth. A recurrent dysontogenic cyst is very rare, with only five cases reported, and only one during childhood. The presence of

tracts or adhesions not identified during the primary excision could explain the recurrence. *Ann Pediatr Surg* 13:43–46 © 2017 Annals of Pediatric Surgery.

Annals of Pediatric Surgery 2017, 13:43–46

Keywords: children, dysontogenic cyst, floor of the mouth, recurrence, teratoid cyst

Departments of ^aPediatric Surgery, ^bPathology, ^cPediatrics and ^dRadiology, University Hospital Álvaro Cunqueiro, Vigo, Spain

Correspondence to Marcos Prada-Arias, MD, Department of Pediatric Surgery, University Hospital Álvaro Cunqueiro, Carretera Clara Campoamor 341, 36312 Vigo, Spain
Tel: +34 677 355 936; e-mail: marcospradaarias@gmail.com

Received 30 August 2014 accepted 20 June 2016

Introduction

The dysontogenic cyst (DC) can occur anywhere in the body, and ~6.5% occur on the floor of the mouth [1]. Although they are usually detected in older children and adults, they can appear at any age and can be mistaken with other more frequent types of intraoral cysts [2]. Three different histological subtypes have been described: epidermoid, dermoid, and teratoid [3]. The recurrent DC is very rare, with only five cases reported, and only one during childhood [4–6]. We present a new case of recurrent DC on the floor of the mouth in a child, and review this rare complication in the English literature.

Clinical case

An 8-month-old boy, without relevant medical antecedents, was referred to our department with a sublingual mass detected by his mother. Physical examination revealed a submucous right mass on the floor of the mouth, 1 cm in diameter, which raised the tongue, suggestive of ranula. Ultrasonography showed a cystic image with possible mucous content. Intraoral surgical excision was performed, finding a rounded, soft, and well-encapsulated yellowish cyst, 1 cm in diameter. Pathologic examination revealed a multilocular cyst with the cystic wall lined by ciliate cylindrical epithelium of respiratory-type alternant with stratified squamous epithelium, with dermal appendages (hair follicles and sebaceous glands), surrounding a cavity full of keratin and sebaceous material. The definitive diagnosis was teratoid cyst. The patient made an uneventful recovery. A year later, the patient presented an asymptomatic swelling in the sublingual region that raised the tongue. MRI showed a sublingual multilocular mass of 1.9 × 2 cm with a well-defined capsule and a sinus prolongation to the floor of the mouth, suggestive of recurrent DC (Fig. 1). Intraoral surgical excision was performed, finding a soft and well-encapsulated yellowish cyst, 2 cm in diameter, with a sinus tract to the floor of the mouth without contact with the hyoid bone body or the

mandibular bone. The cyst with the sinus tract was completely excised. Pathologic examination revealed a teratoid cyst with the same characteristics of the previous cyst. The postoperative course was uneventful. The patient was followed up for 2 years without detecting recurrence.

Discussion

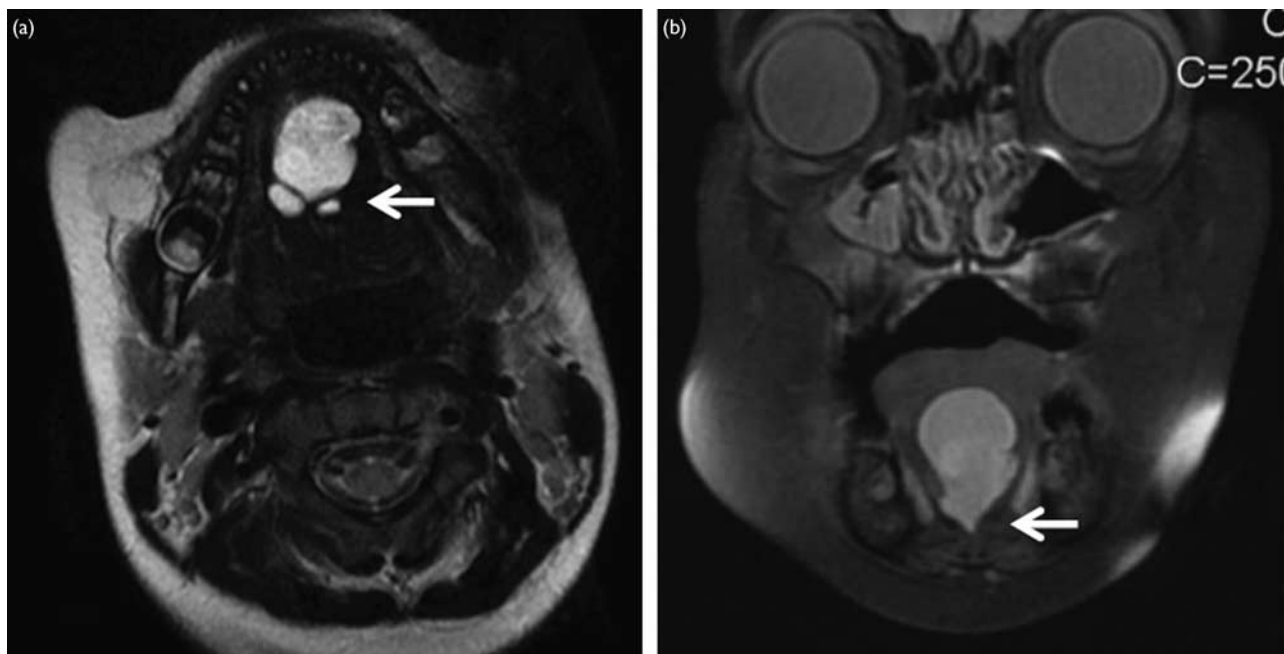
Most reported cases of intraoral DC are located on the floor of the mouth, although there are rare cases on the tongue, lips, oral mucosa, and bone of the maxilla and mandible [2,4].

The pathogenesis of DC is not well established and three theories have been proposed: (a) the congenital or dysontogenic theory suggests that DC results from entrapped midline pluripotent cells during fusion of the mandibular (first) and hyoid (second) branchial arches between the third and fourth weeks of intrauterine life. These cells can develop into mature tissues derived from endodermal, mesodermal, and ectodermal germinal layers [7,8]; (b) the acquired or traumatic theory postulates that DC results from a surgical or accidental trauma that causes epithelial cell implantation into deep tissues, which explains the location of some DC at sites away from the midline [2,9]; (c) a possible embryological relation with thyroglossal duct cyst has been proposed, so that the DC of the floor of the mouth would be a variant form of this cyst with ectodermal elements predominating [2].

The congenital or dysontogenic is the most accepted theory to explain the pathogenesis of DC on the floor of the mouth, and some authors have suggested a change in terminology for the more specific term, congenital germline fusion cyst of the floor of the mouth [10].

On the basis of histological criteria, DC has been classified as epidermoid, dermoid, and teratoid [3]. The epidermoid type or simple DC is lined by stratified squamous epithelium without dermal appendages. The dermoid type or compound DC, in addition to stratified

Fig. 1



(a) T2-weighted axial magnetic resonance image shows a floor of the mouth cystic lesion with internal septa (arrow). (b) T1-weighted coronal magnetic resonance image shows a floor of the mouth cystic lesion with caudal sinus prolongation between genioglossus and geniohyoid muscles (arrow).

squamous epithelium, contains dermal appendages (hair follicles and sebaceous and sweat glands). The teratoid cyst or complex DC is composed of ectodermal, endodermal, and usually mesodermal structures, being lined by stratified squamous and respiratory and/or gastrointestinal epithelium, often accompanied by connective tissue derivatives, such as muscle, bone, and teeth. The cavity of all three types of DCs contains keratin and sebaceous material [3,8]. In our case, the DC was lined by stratified squamous and respiratory epithelium, with dermal appendages but without mesodermal structures. According to the reported cases, the dermoid type is the most common (67.1%), followed by the epidermoid type (27.2%) and the teratoid type (5.7%), which is very rare [4].

The teratoid cyst is similar to a mature teratoma and the distinction between the two is rather arbitrary, as lesions with similar histological features are considered mature teratomas (true germ cell neoplasms) in the ovary, but referred to as teratoid in the head and neck region, to indicate their congenital origin from entrapped pluripotential somatic cells. However, subtle differences do exist between the two entities; for example, neuroglial elements are common in mature teratomas, but uncommon in teratoid cysts [7].

The DC of the floor of the mouth can appear at any age, and according to the literature 66% of patients are 16 years or older, 20% are children 1–15 years of age, and 14% are children under the age of 1 year, with similar sex distribution [4]. Teratoid cysts are a special group with

only 26 cases reported, most of them detected during childhood [4,6–8,10–14].

The DC of the floor of the mouth generally appears as a unique asymptomatic mass, soft and well encapsulated, of slow and progressive growth, though there are five cases of multiple cysts reported, all them in children [2,4]. Depending on its size and location it can generate symptoms. The DC can raise the tongue and produce difficulty in mastication, swallowing, speaking, and breathing; therefore, the patients usually present with dysphagia, dysphonia, and dyspnea. Rarely the DC presents intraoral or cutaneous fistulas, a consequence of secondary infections, with only four cases reported, all them of iatrogenic origin after surgical manipulation of the cyst [2,8,9].

Ultrasonography, computer tomography, and MRI allow the evaluation of the different structures of the neck and head region and establishment of the location and relations of the cyst, which is useful for making the differential diagnosis and for planning the surgical treatment, but none of them offer characteristic findings that allow a certain preoperative diagnosis. Ultrasonography is the first choice of imaging because it is reliable, economical, and without radiographic exposure. The DC appears as a well-circumscribed mass that can be either purely cystic or heterogeneous because of its internal content. Computer tomographic scan shows a mass with a well-defined capsule, which can be enhanced with contrast material. MRI characteristics are variable, usually being isointense or hypointense to the muscle on

Table 1 Reported cases of recurrent floor of the mouth dysontogenic cyst

References	Age first excision	Moment recurrence since first excision	Tract	Histology
Foster [16]	12 years	5 years	No	Dermoid
Leveque et al. [15]	20 years	4 years	Yes	Dermoid
Blenkinsopp and Rowe [17]	18 years	13 years	No	Epidermoid
Faerber et al. [5]	25 months	3 months	Yes	Teratoid
Shigematsu et al. [6]	16 years	18 years	No	Teratoid
This study	8 months	1 year	Yes	Teratoid

T1-weighted images and hyperintense or heterogeneous on T2-weighted images, depending on its internal content, and MRI can delineate multiple cysts and tracts [2,4,14]; in our case, the magnetic resonance shows a multilocular cyst with a sinus prolongation to the floor of the mouth. The cytological examination is the only way to achieve a certain preoperative diagnosis, but the fine-needle aspiration biopsy is rarely diagnostic [9].

The differential diagnosis of a DC on the floor of the mouth includes different entities such as ranula, mucocele, hemangioma, lymphangioma, lingual thyroid, congenital retention cyst of the sublingual gland, thyroglossal cyst, branchial cyst, salivary calculi obstructing the submandibular duct, oral alimentary cyst, mesenchymal, and salivary gland tumors [2,9]. There are seven cases reported of the simultaneous presence of DC and cysts of a different pathological diagnosis, all of them in children [4].

Surgical excision of the DC of the floor of the mouth is the treatment of choice and must be performed as soon as possible, especially in newborns and infants, to avoid possible complications [2,4,8,9]. The location of the DC is an important factor in determining the surgical approach, and hence most authors recommend the intraoral approach for the sublingual cyst, and the extraoral approach, through the submental and suprahyoid region, for submandibular and submental cysts. Large cysts that appear in two or more spaces can require both intraoral and extraoral incisions to provide direct visualization of important adjacent structures [2]. Partial aspiration of the DC has been performed to relieve airway compromise and to permit easier intubation and to provide easier access and better exposure for dissection. No complications have been reported after aspiration, but this method should never be considered definitive treatment [2].

There are 16 cases reported with tracts or fibrous attachments identified to the mandibular symphysis, hyoid bone, genial tubercles, floor of the mouth, tongue dorsum, submental skin, and hypopharynx, which can hinder the total excision, and some of them with tracts to more than one location [4,5,15]. According to the literature, the presence of tracts or adhesions not identified during the primary excision could explain the recurrence of these cysts [6,7,15], and a complete excision with meticulous dissection, including all tracts and adhesions, must be performed [2,4]. Nevertheless, there are only five cases of recurrence of DC reported in the English literature. Of these five cases, only two tracts were found in the second excision, only two corresponded to teratoid cysts, and in only one did the recurrence occur

during childhood (Table 1) [5,6,15–17]. Our case is a new case of recurrent teratoid DC during childhood, with a sinus tract to the floor of the mouth, which was not identified during the primary excision.

The DC of the floor of the mouth is a benign entity. The malignancy of DC is a long-term and exceptional complication. There are only two cases reported of malignant transformation of DC of the floor of the mouth in adults – a case of squamous cell carcinoma developing from a dermoid cyst and another case of intestinal-type adenocarcinoma arising from a teratoid cyst [7,18] – but there are cases of malignant transformation of DC in other neck and head regions, some of them during childhood [19].

Conclusion

The DC must be considered in the differential diagnosis of the sublingual masses in children of any age. MRI is useful to establish the location, relations, and possible sinuses or tracts of the DC and to plan the surgical treatment. A complete excision as soon as possible, including all tracts and adhesions, is necessary to avoid complications and recurrence, which can occur several years before the excision.

Acknowledgements

Conflicts of interest

There are no conflicts of interest.

Inform consent

Inform consent was obtained from patient's parents.

References

- Taylor BW, Erich JB, Dockerty MB. Dermoids of the head and neck. *Minn Med* 1966; **49**:1535–1540.
- King RC, Smith BR, Burk JL. Dermoid cyst in the floor of the mouth. Review of the literature and case reports. *Oral Surg Oral Med Oral Pathol* 1994; **78**:567–576.
- Meyer I. Dermoid cysts (dermoids) of the floor of the mouth. *Oral Surg Oral Med Oral Pathol* 1955; **8**:1149–1164.
- MacNeil SD, Moxham JP. Review of floor of mouth dysontogenic cysts. *Ann Otol Rhinol Laryngol* 2010; **119**:165–173.
- Faerber TH, Hiatt WR, Dunlap C. Congenital teratoid cyst of the floor of the mouth. *J Oral Maxillofac Surg* 1988; **46**:487–490.
- Shigematsu H, Dobashi A, Suzuki S, Kusama K, Sakashita H. Delayed recurrence of teratoid cyst 17 years after enucleation. *Oral Surg Oral Med Oral Pathol Oral Radiol Endod* 2001; **92**:539–542.
- Agaimy A, Raab B, Bonkowsky V, Wunsch PH. Intestinal-type adenocarcinoma arising in a congenital sublingual teratoid cyst. *Virchows Arch* 2007; **450**:479–481.
- Gan K, Fung E, Idikio H, El-Hakim H. A floor of mouth teratoid cyst with tract in a newborn: case report and English literature review unravelling erroneous quotes and citations. *Int J Pediatr Otorhinolaryngol* 2008; **72**:1275–1279.
- Göl IH, Kiyici H, Yildirim E, Arda IS, Hiçsönmez A. Congenital sublingual teratoid cyst: a case report and literature review. *J Pediatr Surg* 2005; **40**:e9–e12.

- 10 Gordon PE, Faquin WC, Lahey E, Kaban LB. Floor-of-mouth dermoid cysts: report of 3 variants and a suggested change in terminology. *J Oral Maxillofac Surg* 2013; **71**:1034–1041.
- 11 Bonilla JA, Szeremeta W, Yellon RF, Nazif MM. Teratoid cyst of the floor of the mouth. *Int J Pediatr Otorhinolaryngol* 1996; **38**:71–75.
- 12 Harada H, Kusakawa J, Kameyama T. Congenital teratoid cyst of the floor of the mouth – a case report. *Int J Oral Maxillofac Surg* 1995; **24**:361–362.
- 13 Nagar H, Baratz M. Congenital sublingual teratoid cyst. Case report. *Int J Oral Maxillofac Surg* 1993; **22**:44–45.
- 14 Liang Y, Yang YSh, Zhang Y. Retrospective analysis of ten cases of congenital sublingual teratoid cyst. *Eur J Paediatr Dent* 2012; **13**:333–336.
- 15 Leveque H, Saraceno CA, Tang CK, Blanchard CL. Dermoid cysts of the floor of the mouth and lateral neck. *Laryngoscope* 1979; **89** (Pt 1):296–305.
- 16 Foster BA. Radiographic demonstration of a sublingual dermoid cyst. Report of a case. *Br Dent J* 1968; **124**:468–469.
- 17 Blenkinsopp PT, Rowe NL. Recurrent dermoid cyst of the floor of the mouth. *Br J Oral Surg* 1980; **18**:34–39.
- 18 Devine JC, Jones DC. Carcinomatous transformation of a sublingual dermoid cyst. A case report. *Int J Oral Maxillofac Surg* 2000; **29**:126–127.
- 19 Magliocca KR, Marx RE, Stone IE, Cohen DM, Bhattacharyya I. Malignant cystic teratoid lesion of the mandible. *J Oral Maxillofac Surg* 2012; **70**: 636–642.